

- COMPU. PATHOLOGY • ALLERGY TESTING
- DIGITAL WHOLE BODY X-RAYS
- DIGITAL 3D SONOGRAPHY
- DIGITAL WHOLE BODY COLOUR DOPPLER
- DIGITAL 2-D ECHO WITH COLOUR DOPPLER
- E.C.G. • LUNG FUNCTION TEST
- MAMMOGRAPHY & BONE MINERAL DENSITOMETRY

- COMPUTERISED STRESS TEST
- DENTAL
- ADVANCED DENTISTRY
- PHYSIOTHERAPY
- AUDIOMETRY & SPEECH THERAPY
- FULL BODY HEALTH CHECK-UPS
- CORPORATE HEALTH CHECKUPS



HEALTHCARE

MEDICAL CENTRE & DIAGNOSTICS

Patient's Name : MRS VANDANA SHRIVASTAVA
Referred By Dr : MEDIWHEEL
Sex : FEMALE Age : 55 Years
Collected At : YOGI NAGAR MAIN BRANCH

Lab No. : LKD4670 *LKD4670*
Reg. Date : 15-Nov-2024 9:02 am
Report Date : 15-Nov-2024 3:47 pm
Print Date : 19-Nov-2024 3:03 pm

URINE ROUTINE & MICROSCOPY

TEST	RESULT
<u>PHYSICAL EXAMINATION</u>	
Quantity	15 ml
Colour	Pale yellow
Appearance	Slightly Hazy
Deposit	Absent
pH	Acidic (5.0)
Specific Gravity	1.015
<u>CHEMICAL EXAMINATION</u>	
Proteins	Absent
Sugar	Absent
Ketone	Absent
Occult Blood	Absent
Bile Pigment	Absent
Bile Salts	Absent
Urobilinogen	Normal
<u>MICROSCOPIC EXAMINATION OF CENTRIFUGED DEPOSIT</u>	
Red Blood Cells	Absent
Pus Cells	1-2/ hpf
Epithelial Cells	1-2/ hpf
Casts	Not seen
Crystals	Not seen
Yeast	Not seen
Bacteria	Absent

----- End of Report -----

Printed By : RUPALI

Checked By
JAY

DR. BHAVINI KAMDAR
MD (PATH) MUM

- BORIVALI CENTRE** 1ST FLR., YOGI AVENUE, YOGI NAGAR, BORIVALI (W), MUMBAI - 400092. • TEL.: 2899 6565 / 2899 1376 • MOB.: 90222 39301
- KANDIVALI CENTRE** MAHAVIR SURYADARSHAN SOC., SATYANAGAR RD., MAHAVIR NAGAR, KANDIVALI (W), MUMBAI - 67. • TEL.: 2868 0090 / 6522 6565 / 2869 7808 • MOB.: 90220 54458
- KANDIVALI CENTRE** SHOP NO. 44/49, EMP 71, EVERSHINE MILLENNIUM PARADISE, THAKUR VILLAGE, 120 FEET ROAD, KANDIVALI (E) MUMBAI - 400101. • TE.: 2885 7171 / 89288 41541
- DAHISAR CENTRE** NILANGI APARTMENT, KANDERPADA JUNCTION, DAHISAR (W), MUMBAI - 400068. • TEL.: 2893 3427 • MOB.: 90220 58504
- GORAI CENTRE** VICTORY HEIGHTS, GORAI MAIN ROAD, OPP. SUVIDYA SCHOOL, BORIVALI (W), MUMBAI - 400092. • TEL.: 2809 6556 • MOB.: 90224 80354 / 72080 02565
- GOREGAON CENTRE** M.G. ROAD, NEAR JAIN MANDIR, GOREGAON (W), MUMBAI - 400062. • Tel.: 2873 3030 / 2873 3131 • MOB.: 93213 83806

Website : www.healthcarediag.com • E-mail : healthcare.medicals@gmail.com
 "Home Visit Facility Call On 76667 66307"

Health Check up Booking Request(22S38991)

2 messages

Mediwheel <wellness@mediwheel.in>
To: healthcare.medicals@gmail.com
Cc: customercare@mediwheel.in

Thu, Nov 14, 2024 at 2:01 PM



011-41195959

Dear Healthcare Medical Centre and Diagnostics

We have received a booking request with the following details. Provide your confirmation by clicking on the Yes button.

You confirm this booking? Yes No

Name : Anupam Shrivastava

Contact Details : 9424419421

Hospital Package Name : Mediwheel Full Body Health Checkup Female Above 40

Location : 1st Floor, Yogi Avenue, Yogi Nagar, behind Vakharia institute, Borivali (W)

Appointment Date : 15-11-2024

Member Information		
Booked Member Name	Age	Gender
Vandana shrivastava	55 year	Female

Tests included in this Package

- Stool Test
- Liver Profile
- Kidney Profile
- Lipid Profile
- CBC
- Urine Sugar PP
- Urine Sugar Fasting
- Blood Glucose (Post Prandial)
- Blood Group
- Blood Glucose (Fasting)
- ESR
- Thyroid Profile
- TMT OR 2D ECHO (Any 1) Chosen By Candidate
- Chest X-ray
- ECG
- USG Whole Abdomen
- Mammography//Sonomammography
- Eye Check-up Consultation
- General Physician Consultation
- Dental Consultation
- Gynae Consultation

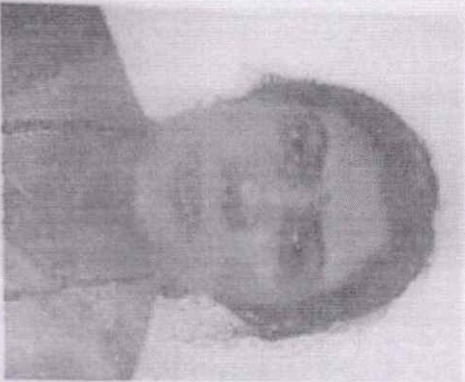65663 65990 5916

जेरा आधार, जेरी पहचान



भारत सरकार

Government of India




Vandana Shrivastava

DOB : 02/10/1969

Female

65663 65990 5916

जेरा आधार, जेरी पहचान



Dr. NUPUR RAI
MBBS, DIB, CMB, CARDIOLOGY (FACCG)
Reg. No.: 2018115643

HEALTHCARE
Medical Centre And Diagnostics
Yogi Avenue, Yogi Nagar
Borivli (West), Mumbai - 400 099
Tel.: 29990523 / 29990525

- COMPU. PATHOLOGY • ALLERGY TESTING
- DIGITAL WHOLE BODY X-RAYS
- DIGITAL 3D SONOGRAPHY
- DIGITAL WHOLE BODY COLOUR DOPPLER
- DIGITAL 2-D ECHO WITH COLOUR DOPPLER
- E.C.G. • LUNG FUNCTION TEST
- MAMMOGRAPHY & BONE MINERAL DENSITOMETRY

- COMPUTERISED STRESS TEST
- DENTAL
- ADVANCED DENTISTRY
- PHYSIOTHERAPY
- AUDIOMETRY & SPEECH THERAPY
- FULL BODY HEALTH CHECK-UPS
- CORPORATE HEALTH CHECKUPS



HEALTHCARE

MEDICAL CENTRE & DIAGNOSTICS

NAME	MRS VANDANA SHRIVASTAVA	DATE	15-11-24
HEIGHT-163CM	WEIGHT- 77KG	AGE	55YRS
REFERRED BY	MEDIWHEEL	SEX	FEMALE

PRESENT COMPLAINT: NIL

PAST HISTORY: K/C/O HTN / HTN SINCE 2 MONTH ON TAB TELMA 20 IHS AND TAB TELMA 40 (1--0-0). UNDER WENT ANGIOGRAPHY S/O NORMAL.

ALLERGY: NIL HABIT- NIL APPETITE: GOOD

BLADDER: NAD BOWEL: CONSTIPATION

FAMILY HISTORY: FATHER : EXPIRED K/C/O HTN / DM / IHD. MOTHER: EXPIRED WAS K/C/O HTN / DM.

GYNEAC HISTORY- LMP -- MENOPAUSE / G4P2A2L2-FTND.

GENERAL EXAMINATION: ADVICE-

P-80/ MIN BP-150/80MMHG *↓ salt intake.*

PALLOR: NIL ICTERUS: NIL *To continue Hthe medicine*

OEDEMA: PEDAL OEDEMA + OTHERS: NAD *To keep regular check on BP*

RS: AEBE CVS-NAD

PA: SOFT CNS-CONSCIOUS

INVESTIGATION:

DR. Y. J. MEHTA (M.D.)

DR. Y. J. MEHTA RAI
 MBBS, B.PH.D. RADIOLOGY (PGDCC)
 Reg. No. 2018115643

HEALTHCARE
 Medical Centre And Diagnostics
 Yogi Avenue, Yogi Chowk, Borivli
 Borivli (West), Mumbai - 401 092.
 Tel.: 28996585 / 28938435

- COMPU. PATHOLOGY • ALLERGY TESTING
- DIGITAL WHOLE BODY X-RAYS
- DIGITAL 3D SONOGRAPHY
- DIGITAL WHOLE BODY COLOUR DOPPLER
- DIGITAL 2-D ECHO WITH COLOUR DOPPLER
- E.C.G. • LUNG FUNCTION TEST
- MAMMOGRAPHY & BONE MINERAL DENSITOMETRY

- COMPUTERISED STRESS TEST
- DENTAL
- ADVANCED DENTISTRY
- PHYSIOTHERAPY
- AUDIOMETRY & SPEECH THERAPY
- FULL BODY HEALTH CHECK-UPS
- CORPORATE HEALTH CHECKUPS



HEALTHCARE

MEDICAL CENTRE & DIAGNOSTICS

NAME	MRS VANDANA SHRIVASTAVA	DATE	15..11.2024
INVESTIGATION	MAMMOGRAPHY	AGE	55 YRS
REF. BY DR.	MEDIWHEEL	SEX	FEMALE

SONOMAMMOGRAPHY OF BOTH BREASTS

Breast tissue is normal in echogenicity.

There is no focal hypo or hyperechoic solid / cystic lesion in both breast.

No dilated tubular structure seen.

There is no appreciable lymphnode in both axillas.

IMPRESSION:

Normal findings.

DR.SUDHANSHU SAXENA

CONS.RADIOLOGIST.

Note : Investigations have their limitations. Solitary radiological investigations never confirm the final diagnosis. They only help in diagnosing the disease in correlation to clinical symptoms and other related tests. USG is known to have interobserver variation. Further / Follow-up imaging may be needed in some cases for confirmation of USG findings.Please interpret accordingly.

- COMPU. PATHOLOGY • ALLERGY TESTING
- DIGITAL WHOLE BODY X-RAYS
- DIGITAL 3D SONOGRAPHY
- DIGITAL WHOLE BODY COLOUR DOPPLER
- DIGITAL 2-D ECHO WITH COLOUR DOPPLER
- E.C.G. • LUNG FUNCTION TEST
- MAMMOGRAPHY & BONE MINERAL DENSITOMETRY

- COMPUTERISED STRESS TEST
- DENTAL
- ADVANCED DENTISTRY
- PHYSIOTHERAPY
- AUDIOMETRY & SPEECH THERAPY
- FULL BODY HEALTH CHECK-UPS
- CORPORATE HEALTH CHECKUPS



HEALTHCARE

MEDICAL CENTRE & DIAGNOSTICS

Patient's Name : MRS VANDANA SHRIVASTAVA

Referred By Dr : MEDIWHEEL

Sex : FEMALE Age : 55 Years

Collected At : YOGI NAGAR MAIN BRANCH

Lab No. : LKD4670*LKD4670*

Reg. Date : 15-Nov-2024 9:02 am

Report Date: 15-Nov-2024 10:09 am

Print Date : 15-Nov-2024 12:33 pm

Copyright © The McGraw-Hill Companies, Inc. Permission required for reproduction or display.

X-RAY CHEST P. A. VIEW

The lungs on the either side show equal translucency.

The peripheral pulmonary vasculature is normal.

No focal lung lesion is seen.

The pleural spaces are normal.

Both hila are normal in size, have equal density and bear normal relationship.

The heart and trachea are central in position.

No mediastinal abnormality is visible.

The cardiac size is normal.

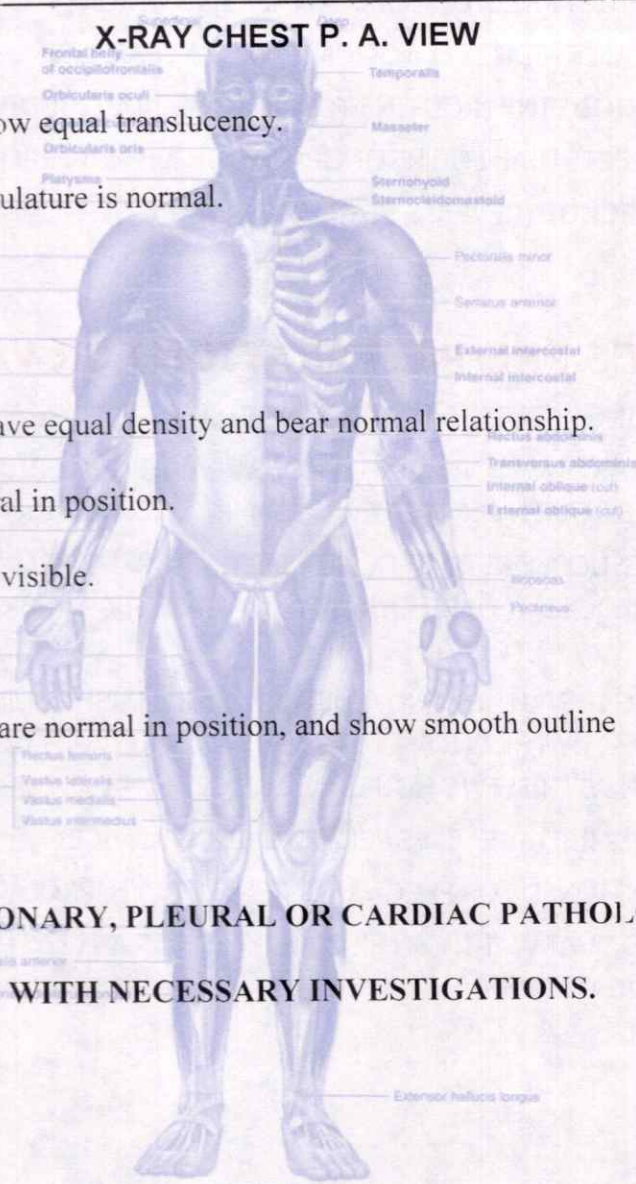
The domes of the diaphragms are normal in position, and show smooth outline

Ribs appear normal.

IMPRESSION :

NO EVIDENCE OF PULMONARY, PLEURAL OR CARDIAC PATHOLOGY IS NOTED.

CLINICAL CORELATION WITH NECESSARY INVESTIGATIONS.



Shangale
DR. SHAIKESH SANGALE
 CONS. RADIOLOGIST

DR. SHRIKANT BODKE
 CONS. RADIOLOGIST

DR. NIKUNJ KOTHIA
 CONS. RADIOLOGIST

DR. BHAGYA SANNANANJA
 CONS. RADIOLOGIST

- COMPU. PATHOLOGY • ALLERGY TESTING
- DIGITAL WHOLE BODY X-RAYS
- DIGITAL 3D SONOGRAPHY
- DIGITAL WHOLE BODY COLOUR DOPPLER
- DIGITAL 2-D ECHO WITH COLOUR DOPPLER
- E.C.G. • LUNG FUNCTION TEST
- MAMMOGRAPHY & BONE MINERAL DENSITOMETRY

- COMPUTERISED STRESS TEST
- DENTAL
- ADVANCED DENTISTRY
- PHYSIOTHERAPY
- AUDIOMETRY & SPEECH THERAPY
- FULL BODY HEALTH CHECK-UPS
- CORPORATE HEALTH CHECKUPS



HEALTHCARE

MEDICAL CENTRE & DIAGNOSTICS

NAME	MRS VANDANA SHRIVASTAVA	DATE	15.11.2024
	Copyright © The McGraw-Hill Companies, Inc. Permission required for reproduction.	AGE	55 YRS
REF. BY DR	MEDIWHEEL	SEX	FEMALE

REAL TIME ABDOMINAL SONOGRAPHY SHOWS,

LIVER : Liver is normal in size showing bright parenchymal echotexture . There is no evidence of solid or cystic mass .The portal and the hepatic venous system appears normal.

Gall bladder : The Gall bladder is well distended .The gall bladder wall of normal thickness . No evidence of gall stones.

PANCREAS : Pancreas is normal in size with smooth margin and homogenous parenchymal echotexture. No focal lesion seen.

KIDNEYS : Both kidneys are normal in size and shows homogenous cortical echotexture. Central calyceal echoes appear normal. There is no evidence of hydronephrosis or renal calculus.

(a) Right kidney measures: 11.2 x 4.0 cms

(b) Left kidney measures: 10.3 x 4.9 cms.

SPLEEN : The spleen is normal in size with homogenous parenchymal echotexture. No focal lesion are seen.

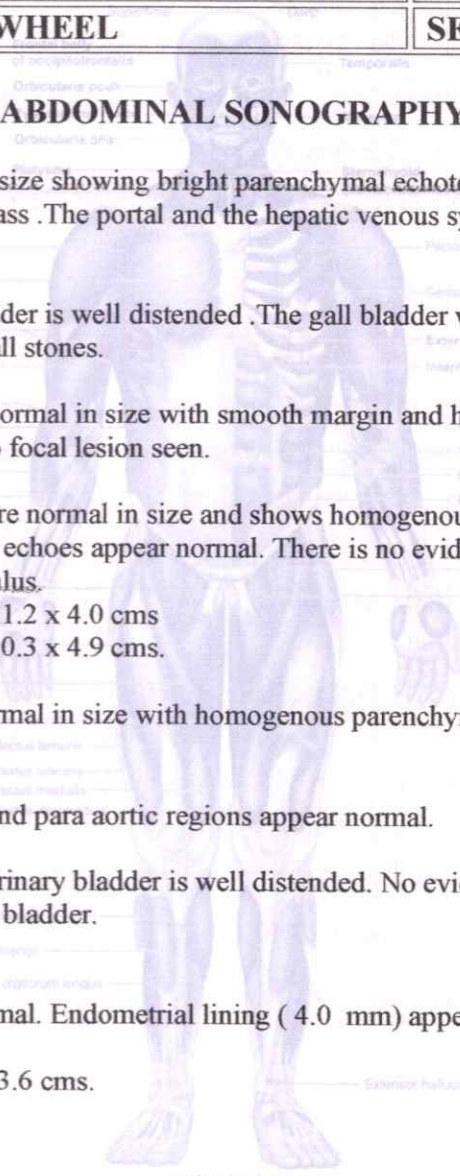
AORTA : The upper aorta and para aortic regions appear normal.

URINARY BLADDER : Urinary bladder is well distended. No evidence of calculus or intraluminal mass seen in the bladder.

UTERUS (TAS):

Uterus is anteverted and normal. Endometrial lining (4.0 mm) appears normal. No evidence of focal lesion.

Uterus measures: 5.7 x 3.8 x 3.6 cms.



(a) Anterior view

- COMPU. PATHOLOGY • ALLERGY TESTING
- DIGITAL WHOLE BODY X-RAYS
- DIGITAL 3D SONOGRAPHY
- DIGITAL WHOLE BODY COLOUR DOPPLER
- DIGITAL 2-D ECHO WITH COLOUR DOPPLER
- E.C.G. • LUNG FUNCTION TEST
- MAMMOGRAPHY & BONE MINERAL DENSITOMETRY

- COMPUTERISED STRESS TEST
- DENTAL
- ADVANCED DENTISTRY
- PHYSIOTHERAPY
- AUDIOMETRY & SPEECH THERAPY
- FULL BODY HEALTH CHECK-UPS
- CORPORATE HEALTH CHECKUPS



HEALTHCARE

MEDICAL CENTRE & DIAGNOSTICS

NAME	MRS VANDANA SHRIVASTAVA	DATE	15.11.2024
INVESTIGATION	2 D ECHO	AGE	55 YRS
REF. BY DR.	MEDIWHEEL	SEX	FEMALE

2D-ECHOCARDIOGRAPHY & DOPPLER FINDINGS:

Normal sized LA, RA, RV and LV,
 2DEF= 60%
 No hypertrophy seen
 No evidence of hypokinesia
 All Valves morphologically normal
 No stenosis or regurgitation seen
 IAS and IVs intact. No shunt lesion seen
 No evidence of clot/ thrombus/ vegetation seen
 Normal RV function
 TAPSE=1.93cms , MSPSE= 1.30cms
 Pericardium normal. No pericardial effusion.
 No diastolic dysfunction
 Normal LV systolic function.

M-MODE MEASUREMENT:

LEFT VENTRICULAR	
IVSd	10 mm
IVSs	18 mm
LVIDd	51 mm
LVIDs	26 mm
LVPWd	08 mm
LVPWs	13 mm
EF (Teich)	60 %
% FS	33 %

Cont on page 2....

- COMPU. PATHOLOGY • ALLERGY TESTING
- DIGITAL WHOLE BODY X-RAYS
- DIGITAL 3D SONOGRAPHY
- DIGITAL WHOLE BODY COLOUR DOPPLER
- DIGITAL 2-D ECHO WITH COLOUR DOPPLER
- E.C.G. • LUNG FUNCTION TEST
- MAMMOGRAPHY & BONE MINERAL DENSITOMETRY

- COMPUTERISED STRESS TEST
- DENTAL
- ADVANCED DENTISTRY
- PHYSIOTHERAPY
- AUDIOMETRY & SPEECH THERAPY
- FULL BODY HEALTH CHECK-UPS
- CORPORATE HEALTH CHECKUPS



HEALTHCARE

MEDICAL CENTRE & DIAGNOSTICS

NAME	MRS VANDANA SHRIVASTAVA	DATE	15.11.2024
INVESTIGATION	2 D ECHO	AGE	55 YRS
REF. BY DR.	MEDIWHEEL	SEX	FEMALE

AORTA	
AO	30 mm
LA	38 mm
AVO	17

MITRAL	VALVE
DE	1.78 cm
EF SLOPE	0.11


• DOPPLER STUDY:

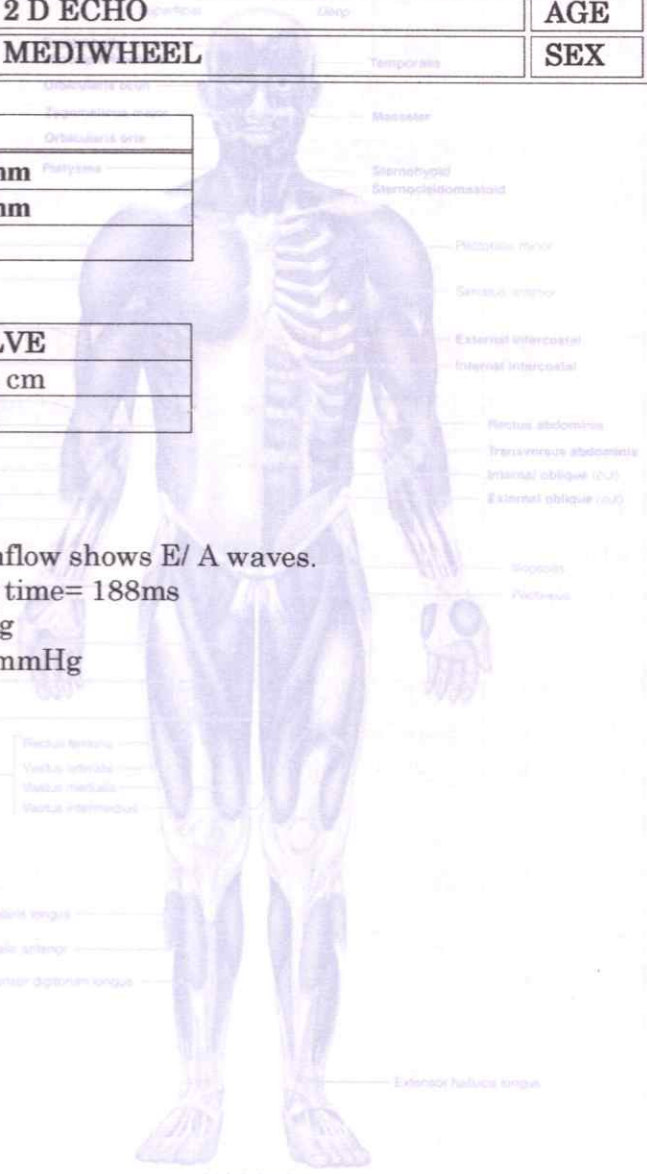
PWD left ventricular inflow shows E/ A waves.

Mitral valve: E>A, Dec time= 188ms

Aortic valve: 4.64mmHg

Pulmonary valve: 2.13mmHg


DR. NUPUR RAI
 MBBS, D CARD



- COMPU. PATHOLOGY
- DIGITAL X-RAY
- DIGITAL SONOGRAPHY
- DIGITAL COLOR DOPPLER
- 2D ECHO CARDIOGRAPHY
- MAMMOGRAPHY & BONE MINERAL DENSITOMETRY (BMD)
- ECG ■ PFT
- COMPU. TREADMILL TEST
- PHYSIOTHERAPY
- DENTAL
- HEALTH CHECK-UP



MEDICAL CENTRE & DIAGNOSTICS

MRS VANDANA SHRIVASTAV

ELKD4670 15-Nov-2024



ECG

ELECTROCARDIOGRAM (ECG)

PATIENT MRS VANDANA SHRIVASTAV AGE. 55 SEX F

REF. BY DR. MEDS WHEEL DATE 15/11/2024

INTERPRETATION : hru

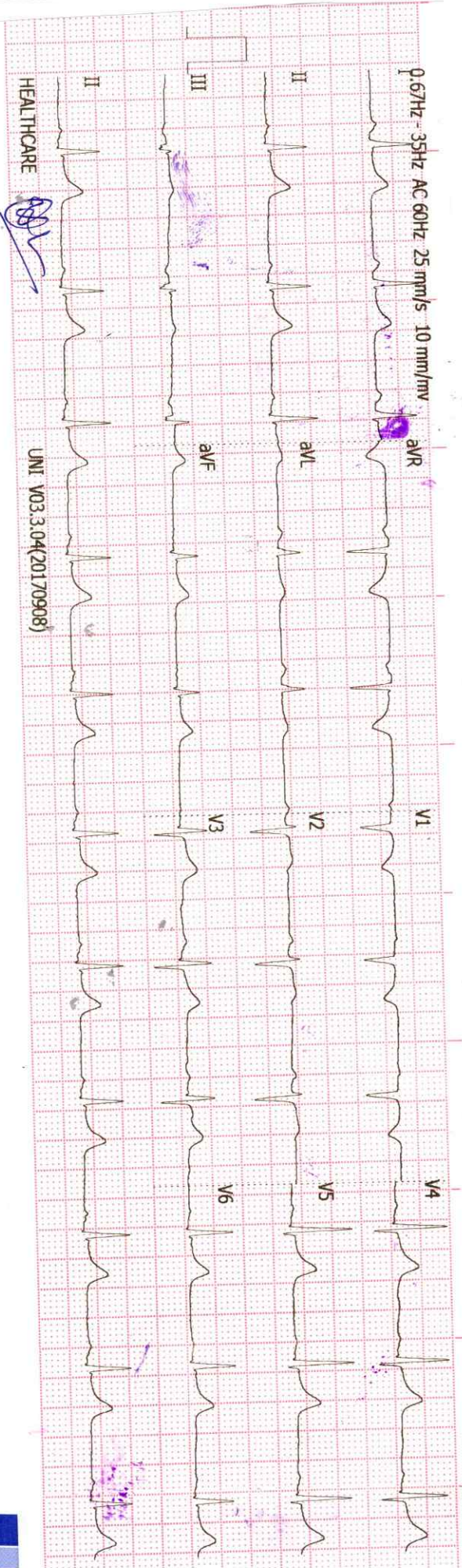
HEALTHCARE
 Medical Centre And Diagnostics
 Yogi Avenue, Yogi Nagar,
 Borivli (West), Mumbai - 400 092
 Tel.: 28998565 / 20596535

Dr. 

DR. MANOJUR RAI
 MBS & DYS RIMA CARDIOLOGY (PGDCC)
 Reg. No.: 2018115643



0.67Hz - 35Hz AC 60Hz 25 mm/s 10 mm/mV



HEALTHCARE

UNI V03.3.04(20170908)

History :

B.P. :

Drugs :

Standard :

Auricular Rate :

Ventricular Rate :

Rhythm :

Mechanism :

Voltage :

Axis :

P. Waves :

PR Interval :

Q. Waves :

QRS Interval :

ST Segment :

T. Waves :

QT Interval :

Extra Systoles :

REMARKS & CONCLUSIONS : *normal*

.....

78 bpm

B

(2)