



భారత ప్రభుత్వం
GOVERNMENT OF INDIA




కారంచెట్టి సుధా రాణి

Karamchetti Sudha Rani

పుట్టిన తేదీ/ DOB: 03/04/1987

స్త్రీ / FEMALE

2113 8381 0622



ఆధార్ - సామాన్యుని హక్కు



భారత విశిష్ట గుర్తింపు ప్రాధికార సంస్థ

Unique Identification Authority of India

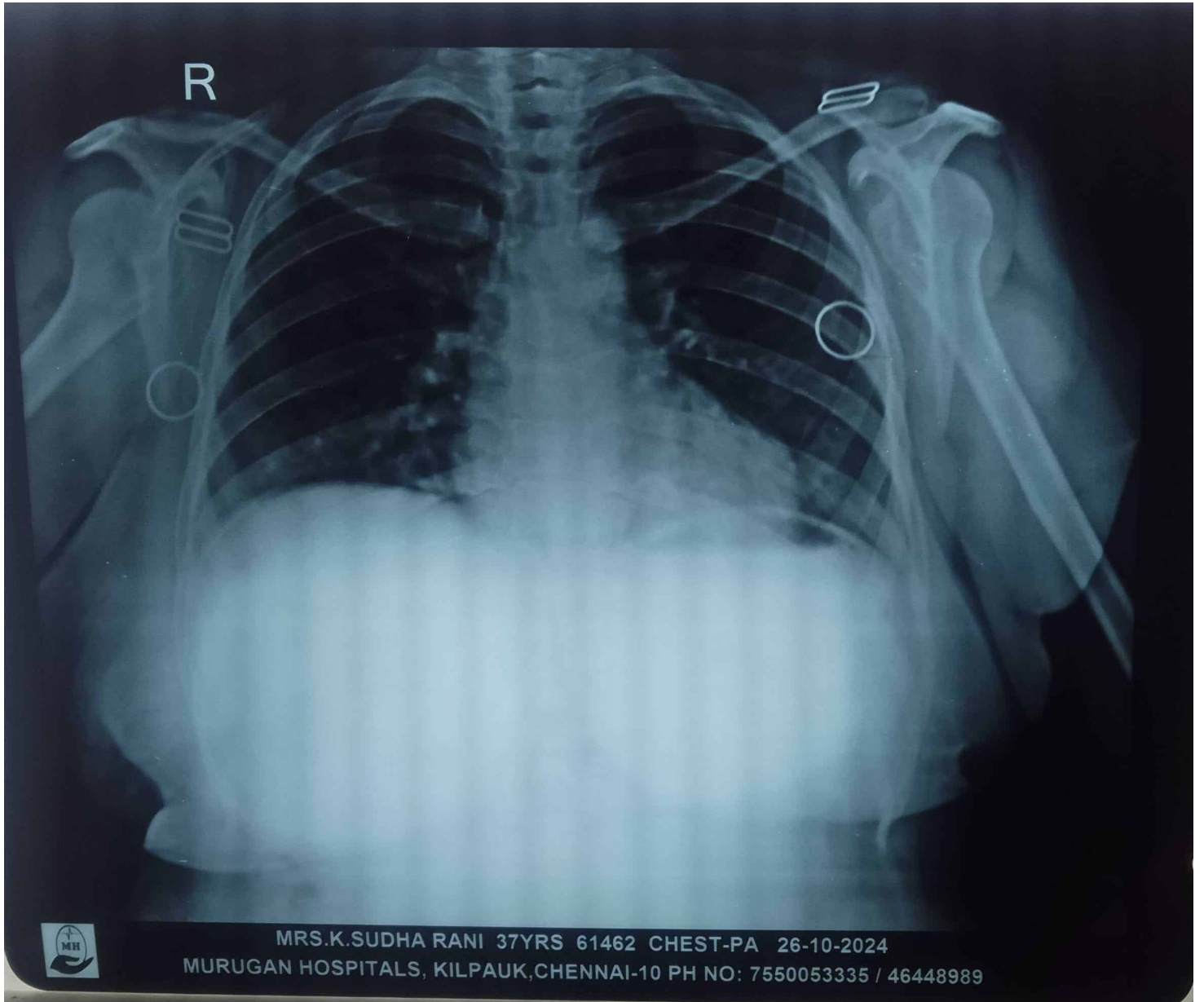
చిరునామా:

W/O కిశోర్ బాబు, 2-230,
లింగంగుంట్ల, లింగంగుంట్ల,
లింగంగుంట్ల, గుంటూరు,
ఆంధ్ర ప్రదేశ్ - 522402

Address:

W/O Kishore Babu, 2-230,
Lingamgunta, Lingamgunta,
Lingamgunta, Guntur,
Andhra Pradesh - 522402

2113 8381 0622



MRS.K.SUDHA RANI 37YRS 61462 CHEST-PA 26-10-2024
MURUGAN HOSPITALS, KILPAUK, CHENNAI-10 PH NO: 7550053335 / 46448989



MURUGAN HOSPITALS

HEALING HANDS



SCAN REPORT

NAME	: MRS. K.SUDHA RANI	PATIENT ID	: MH20240061462
AGE/SEX	: 37-Years / Female	IP / OP NO	: OP21100683
CONSULTANT	: DR. ARUN PRAKASH	DATE	: 26/10/2024

ULTRA SOUND SCAN OF ABDOMEN

LIVER: Normal in size and measures- 12.4 cm and normal in echotexture. No focal lesions are seen. No dilatation of intra-hepatic biliary radicals present. Hepatic veins and IVC appear normal. Portal vein is normal in caliber. Common bile duct is normal in caliber.

GALL BLADDER: Contracted

PANCREAS: Head and body normal tail, obscured by bowel gas.

PARA AORTIC AREAS: Aorta and IVC appear normal. No evidence of para aortic lymphadenopathy.

SPLEEN: Normal in size. Normal in echotexture. No evidence of focal lesions.

RIGHT KIDNEY: Measures 9.3 x 5.0 cm and is normal in size and echotexture. Cortico medullary differentiation is well maintained. There is no hydronephrosis or mass.

LEFT KIDNEY: Measures 8.4 x 4.6 cm and is normal in size and echotexture. Cortico medullary differentiation is well maintained. There is no calculus or hydronephrosis or mass.

Healing Hearts and Lives

264/125, Kilpauk Garden Road, Kilpauk, Chennai - 600 010. Phone : +91 44 4644 8989 / 75500 53335
Email : muruganhosp@gmail.com | Website : www.muruganhospitals.in

URINARY BLADDER: Minimally distended

UTERUS AND OVARIES: Could not be assessed due to minimally distended bladder.

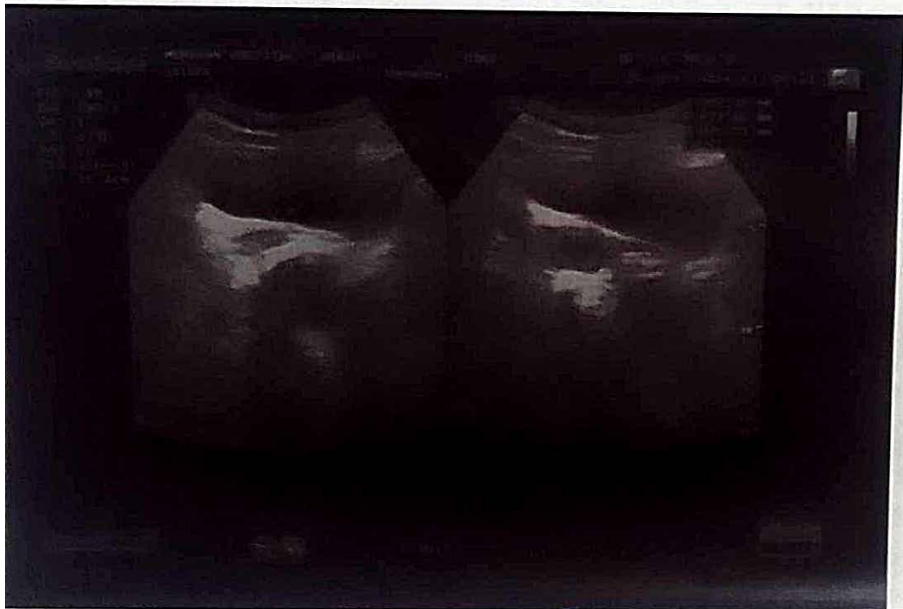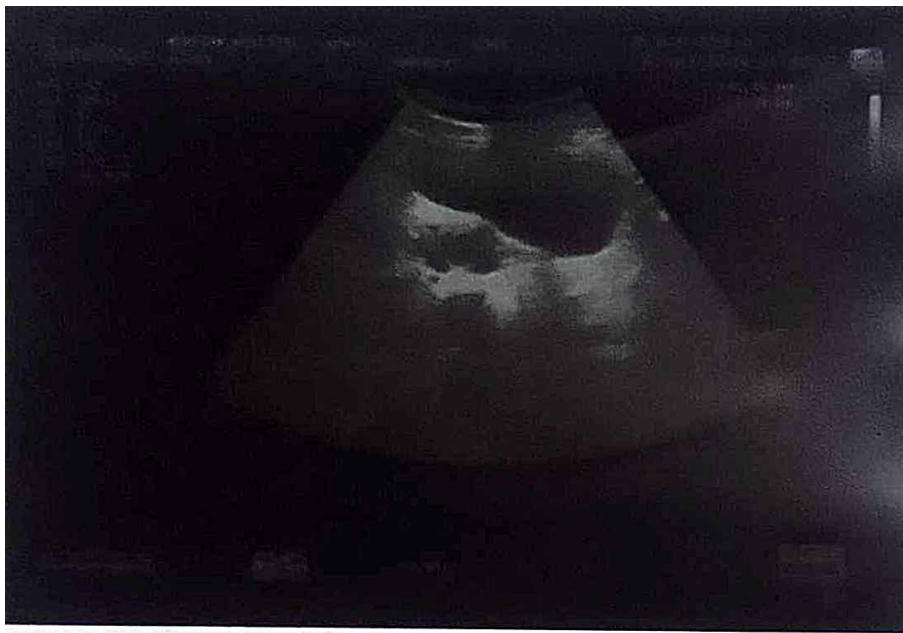No ascites present. No retroperitoneal lymphadenopathy present.

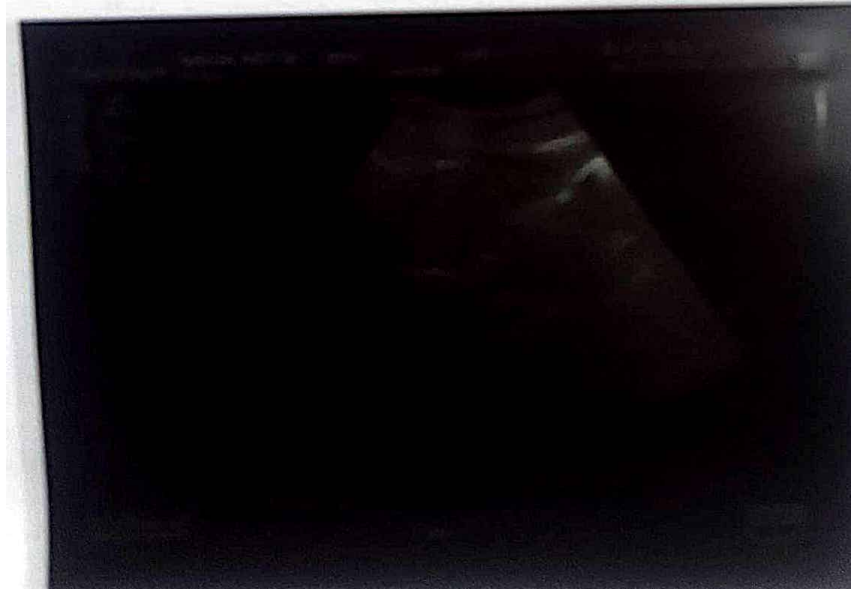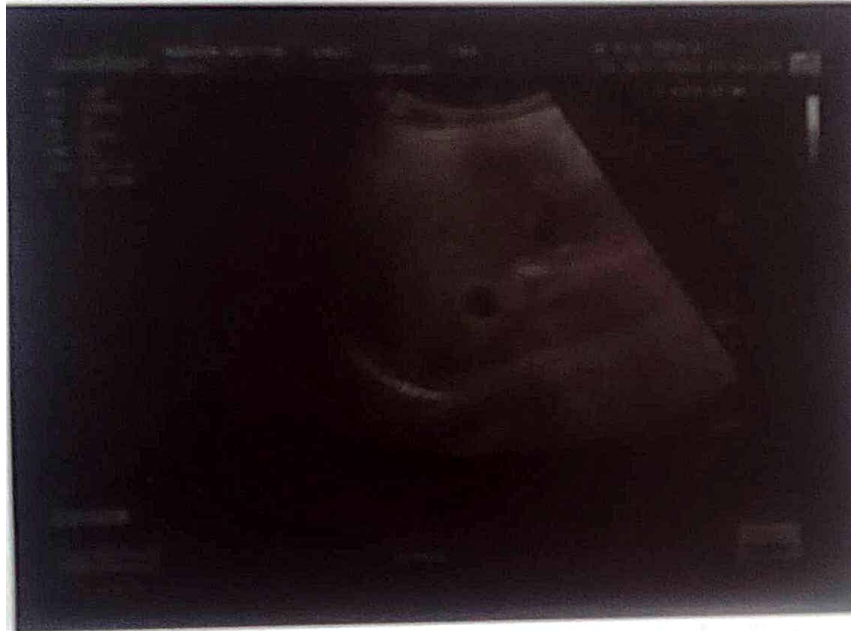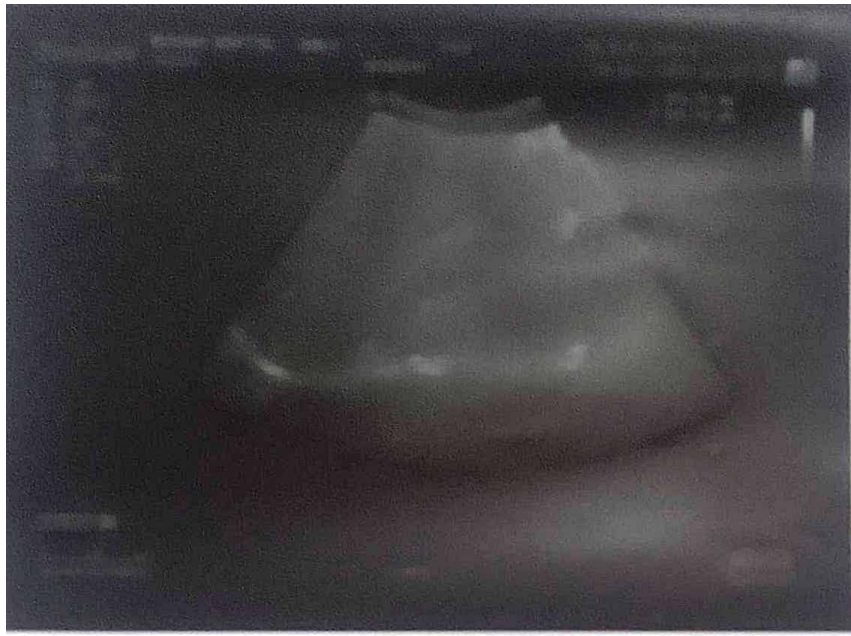IMPRESSION:

No significant abnormality detected in the visualized abdominal organs.



CONSULTANT RADIOLOGIST,







MURUGAN HOSPITALS

HEALING HANDS



ECHO CARDIOGRAM REPORT

NAME : MRS. K.SUDHA RANI PATIENT ID : MH20240061462
AGE/SEX : 37-Years / Female IP / OP NO : OP21100683
CONSULTANT: DR. ARUN PRAKASH DATE : 26/10/2024

2D PLAX (mm)

RV - 24 mm
AO - 34 mm
LA - 24 mm

COLOR DOPPLER

Normal

M-Mode (mm)

IVS - 09 mm
PW - 10 mm
LVD - 42 mm
LVS - 26 mm
EF - 67 %
FS - 37 %

DOPPLER (m/sec)

MITRAL E - 0.8 m/s
MITRAL A - 0.4 m/s
PULMONARY - 0.9 m/s
AORTIC - 1.2 m/s
TRICUSPID - 0.4 m/s

IMPRESSION:

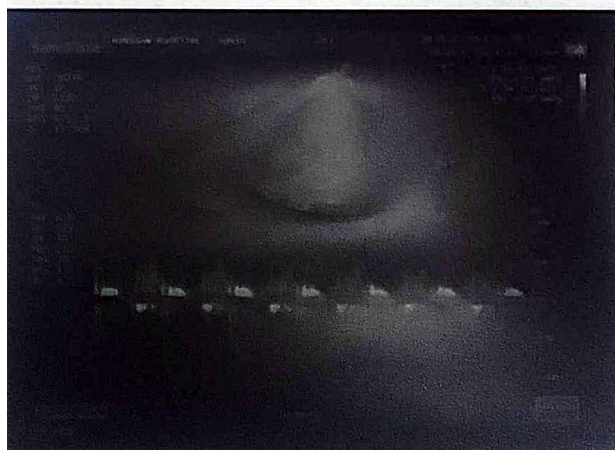
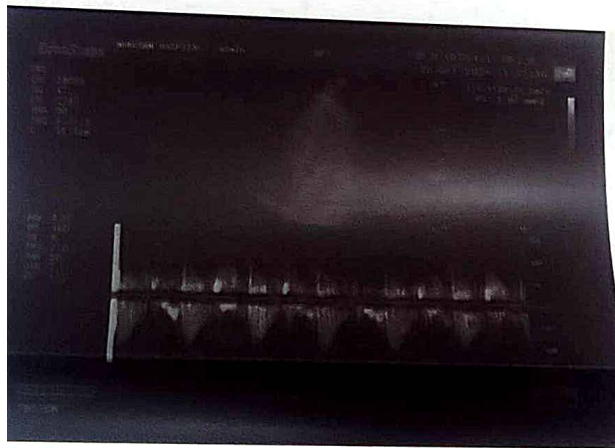
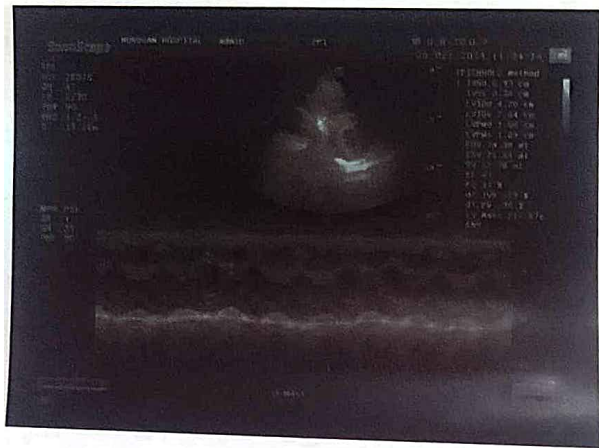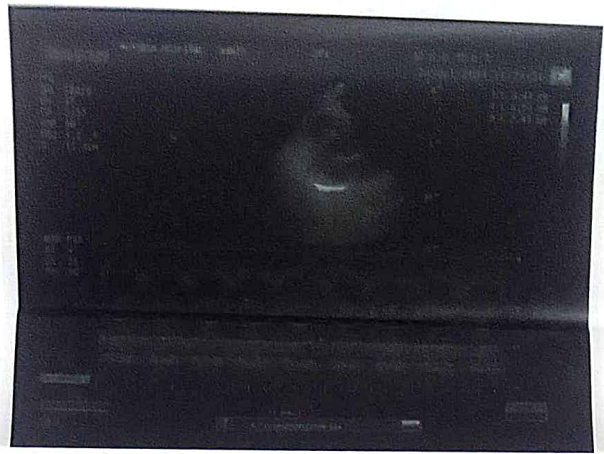
No RWMA
Normal biventricular function
No pulmonary hypertension
No pericardial effusion
No clot/ Vegetation.

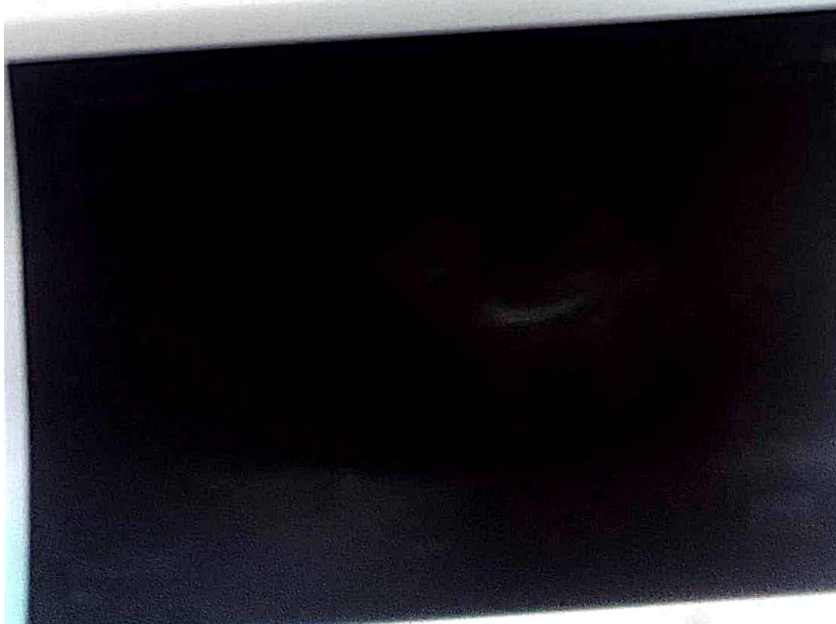
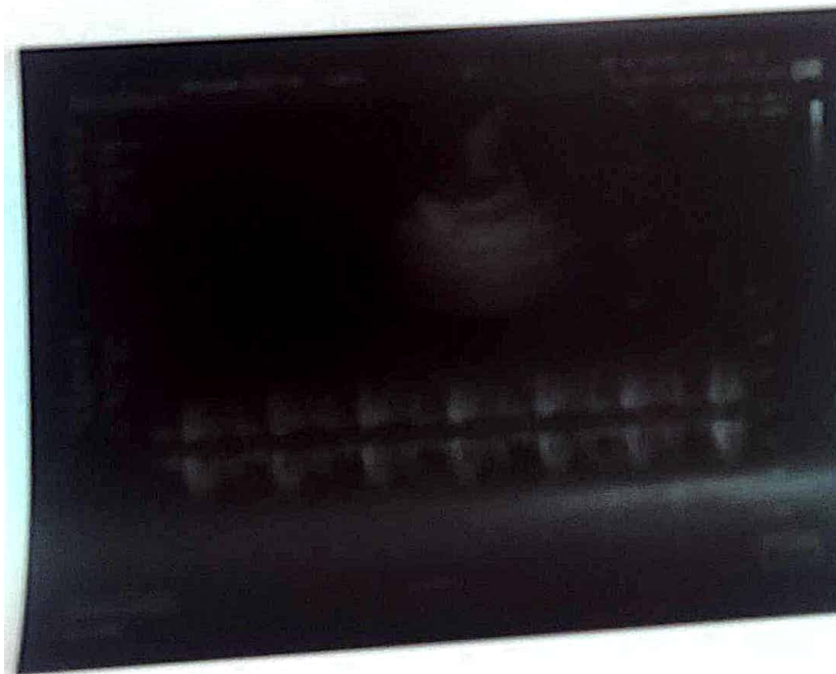
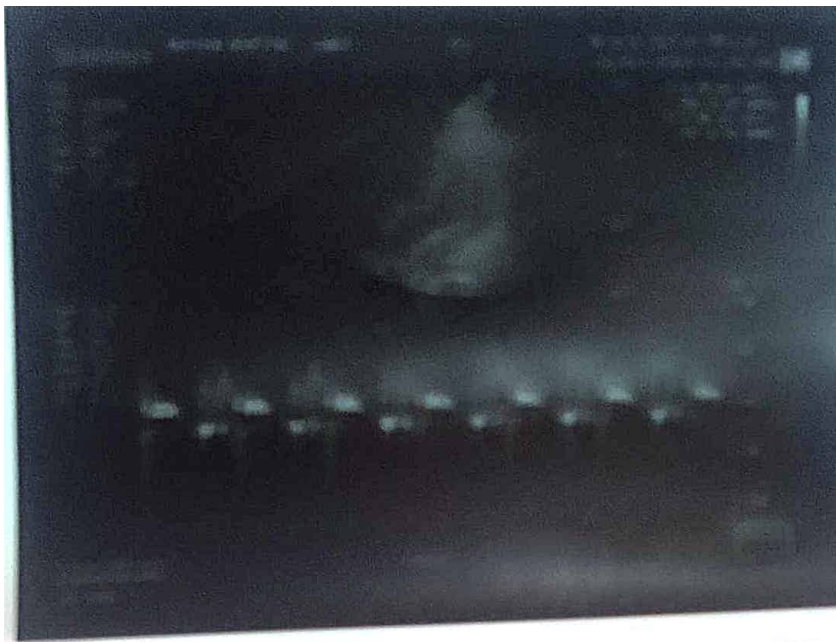
CONSULTANT CARDIOLOGIST

Healing Hearts and Lives

264/125, Kilpauk Garden Road, Kilpauk, Chennai - 600 010.
Phone : +91 44 4644 8989 / 75500 53335 | Email : muruganhosp@gmail.com
Website : www.muruganhospitals.in



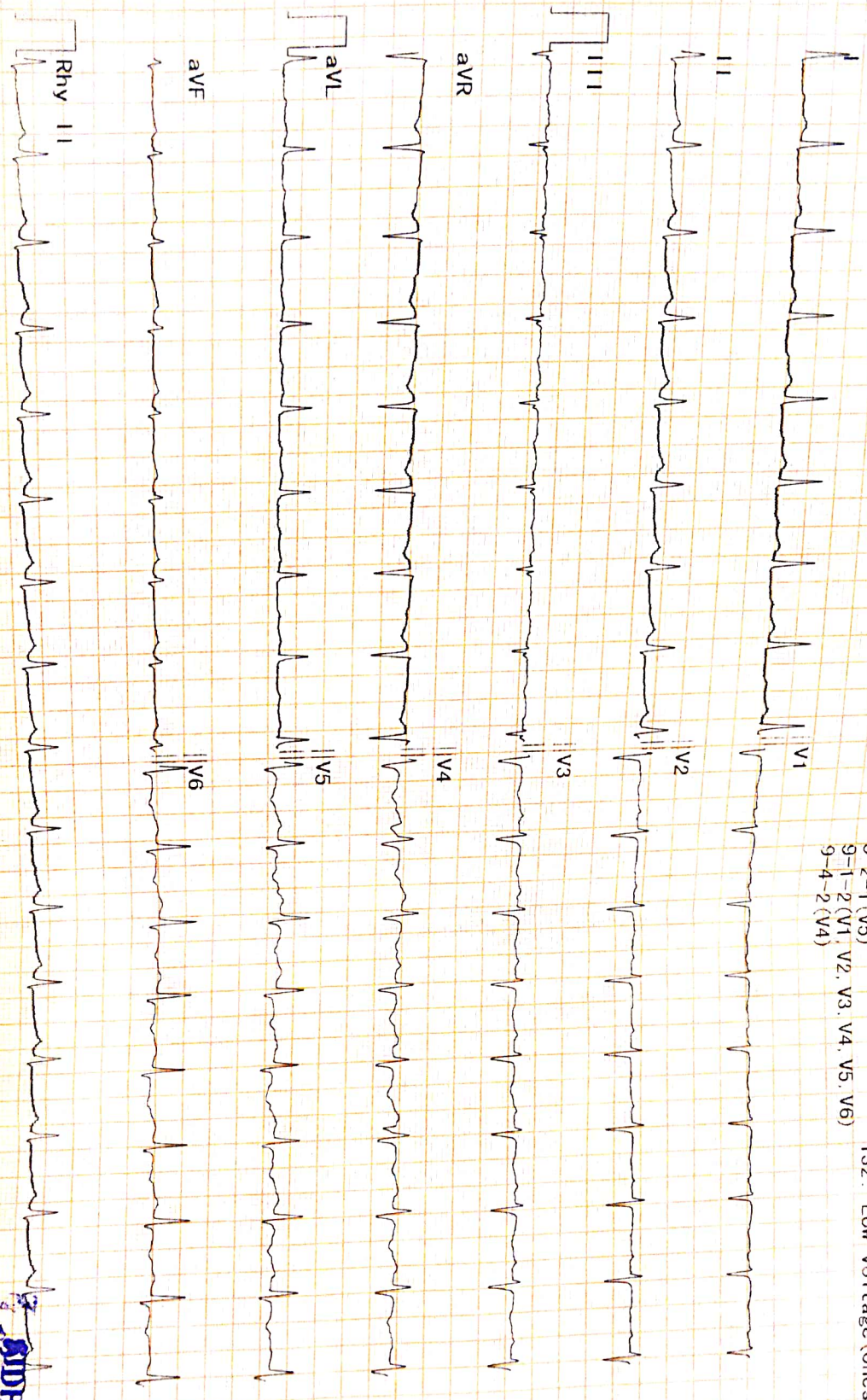


Sex :
 Divisions :
 HR 101bpm
 P Dur PR int 101/155ms
 QRS Dur 102ms
 QT QTc int 334/433 ms
 P QRS T axis 51/13/157°

Age : 2024-10-26 11:23
 BP : mmHg
 Bed No. :
 RV5 SV1 amp 0.535V
 RV5+SV1 amp 0.971mV
 RV6 SV2 amp 0.677V
 0.536mV

PatientID :
 Height : cm
 Weight : kg
 Hospital No. :
 Minnesota Code
 8-7-3
 4-5-0 (I, aVL)
 5-2-1 (V5)
 9-1-2 (V1, V2, V3, V4, V5, V6)
 9-4-2 (V4)

Hospital :
 Diagnosis Info
 812: Sinus Tachycardia
 621: Negative T (V5)
 132: Low Voltage (Chest Leads)



Diagnosis for reference, ask your doctor to confirm
 AUTO PRINT 6X2+1R 101bpm 10 mm mV 0.50Hz-25Hz AG 50Hz 25 mm sec Confirmed By:

SIDHARTHAN MD
 Consultant Cardiologist
 Reg. No. - 62976



MURUGAN HOSPITALS

HEALING HANDS



LAB REPORT

Patient Name : Mrs. K.SUDHA RANI
Age / Gender : 37-Years / Female
UHID ID : MH20240061462
Doctor Name : Dr. ARUN PRAKASH

OP Report No. : INVA2117758
Bill No. : INV2407714
Sample Date : 26/10/2024 - 09:30 AM
Report Date : 26/10/2024 - 04:05 PM

Test Name	Result	Units	Reference Interval
-----------	--------	-------	--------------------

HAEMATOLOGY

COMPLETE BLOOD CELL COUNT(CBC)

HAEMOGLOBIN	<u>8.1</u>	gms/dl	male :13.0 - 17.0 female :12.0 - 15.0
PACKED CELL VOLUME	<u>27.4</u>	%	male : 40 - 50 female : 36 - 46
RBC COUNT	4.11	millions cells/cu.mm	female: 3.8 - 4.8 male : 4.5 - 5.5
TOTAL WBC	6,940	Cells/Cumm	4,000 - 11,000
Differential Count			
NEUTROPHILS	58.7	%	40 - 65
LYMPHOCYTES	36.1	%	30-50
EOSINOPHILS	<u>0.5</u>	%	01-06
MONOCYTES	4.7	%	1-10
BASOPHILS	00	%	0-2
ESR 60 MTS	19	mm	5 - 20
PLATELET COUNT	2.84	Lakhs/cumm	1.5 - 4.5
MCV	<u>66.6</u>	fL	76 - 96
MCH	<u>19.6</u>	pg	27 - 32
MCHC	<u>29.4</u>	gms/dl	30 - 36
BLOOD GROUPING & RH TYPING	" B " POSITIVE		

Page 1 of 4

Healing Hearts and Lives

264/125, Kilpauk Garden Road, Kilpauk, Chennai - 600 010.
Phone : +91 44 4644 8989 / 75500 53335 | Email : muruganhosp@gmail.com
Website : www.muruganhospitals.in



MURUGAN HOSPITALS

HEALING HANDS



LAB REPORT

Patient Name : Mrs. K.SUDHA RANI
Age / Gender : 37-Years / Female
UHID ID : MH20240061462
Doctor Name : Dr. ARUN PRAKASH

OP Report No. : INVA2117758
Bill No. : INV2407714
Sample Date : 26/10/2024 - 09:30 AM
Report Date : 26/10/2024 - 04:05 PM

Test Name	Result	Units	Reference Interval
LIVER FUNCTION TEST			
BILLIRUBIN(TOTAL)	0.4	mg/dl	0.0 -1.0
BILLIRUBIN(DIRECT)	0.2	mg/dl	0.1- 0.30
BILLIRUBIN(INDIRECT)	0.2	mg/dl	0.2-0.8
SGOT	16	IU/L	0-38
SGPT	17	IU/L	0.0-40
ALKALINE PHOSPHATASE	94	IU/L	40-140 4-6Years 93-309 13-15Years 74-390
TOTAL PROTEIN	7.8	gm/dl	6.6-8.7
ALBUMIN	4.0	gm/dl	3.5 - 5.5
GLOBULIN	<u>3.8</u>	gm/dl	2.0-3.5
AG RATIO	1.0		
GAMMA G T	11.4	U/L	< 55 U/ L
BLOOD UREA NITROGEN	7.6	mg/dl	7-21
HBA1C	5.6	%	normal: <6.0 good control: 6.1-7.0 fair control: 7.1- 8.0 poor control:8.1 -10.0 unsatisfactory: >10.0

Healing Hearts and Lives

264/125, Kilpauk Garden Road, Kilpauk, Chennai - 600 010.
Phone : +91 44 4644 8989 / 75500 53335 | Email : muruganhosp@gmail.com
Website : www.muruganhospitals.in



MURUGAN HOSPITALS

HEALING HANDS



LAB REPORT

Patient Name : Mrs. K.SUDHA RANI
 Age / Gender : 37-Years / Female
 UHID ID : MH20240061462
 Doctor Name : Dr. ARUN PRAKASH

OP Report No. : INVA2117758
 Bill No. : INV2407714
 Sample Date : 26/10/2024 - 09:30 AM
 Report Date : 26/10/2024 - 04:05 PM

Test Name	Result	Units	Reference Interval
-----------	--------	-------	--------------------

CLINICAL PATHOLOGY

URINE SUGAR (F)	NIL		
URINE SUGAR (PP)	NIL		
URINE ROUTINE			
COLOUR	PALE YELLOW		
APPEARANCE	CLEAR		
REACTION	ACIDIC		
SUGAR	NIL		
ALBUMIN	NIL		
DEPOSITES			
PUS CELLS	3 - 4	/ HPF	
EPI CELLS	1 - 2	/ HPF	
RBC COUNT	NIL	/ HPF	
CAST	NIL		
CRYSTALS	NIL		
OTHERS	NIL		

KAVIYARASAN

Verified by

*** End of Report ***



Healing Hearts and Lives

264/125, Kilpauk Garden Road, Kilpauk, Chennai - 600 010.
 Phone : +91 44 4644 8989 / 75500 53335 | Email : muruganhosp@gmail.com
 Website : www.muruganhospitals.in



MURUGAN HOSPITALS

HEALING HANDS



LAB REPORT

Patient Name : Mrs. K.SUDHA RANI
Age / Gender : 37-Years / Female
UHID ID : MH20240061462
Doctor Name : Dr. ARUN PRAKASH

OP Report No. : INVA2117758
Bill No. : INV2407714
Sample Date : 26/10/2024 - 09:30 AM
Report Date : 26/10/2024 - 11:50 PM

Test Name	Result	Units	Reference Interval
-----------	--------	-------	--------------------

ENDOCRINOLOGY

T3	0.893	ng/ml	0.52-1.85
T4	10.608	ug/dl	5.0 -13.0 ug/dl
TSH	3.712	uIU/ml	0.39 - 6.16 uiu/ml

KAVIYARASAN

Verified by

*** End of Report ***



Healing Hearts and Lives

264/125, Kilpauk Garden Road, Kilpauk, Chennai - 600 010.
Phone : +91 44 4644 8989 / 75500 53335 | Email : muruganhosp@gmail.com
Website : www.muruganhospitals.in



MURUGAN HOSPITALS

HEALING HANDS



NAME : MRS.K.SUDHA RANI
AGE / SEX : 37Y/FEMALE
CONSULTANT: DR.ARUN PRAKASH

UHID : MH202400601462
OP/IP : OP
DATE : 26.10.2024

CHEST XRAY PA VIEW

- Trachea is in midline.
- Hila appear Normal.
- Mediastinal shadow appears normal.
- Costophrenic&Cardiophrenic angles appear free.
- Cardiothoracic ratio is within normal limits.
- Lungs fields appear clear
- Bony thorax and soft tissue appear normal

IMPRESSION:

- No significant abnormality noted.

CONSULTANT RADIOLOGIST



264/125, Kilpauk Garden Road, Kilpauk, Chennai - 600 010.

☎ : +91 44 46448989 / 7550053335

email : muruganhospitals@gmail.com