


**UNION OF INDIA Driving Licence** (GJ) (NT+T)  
GUJARAT STATE  
GJ10 20200010534

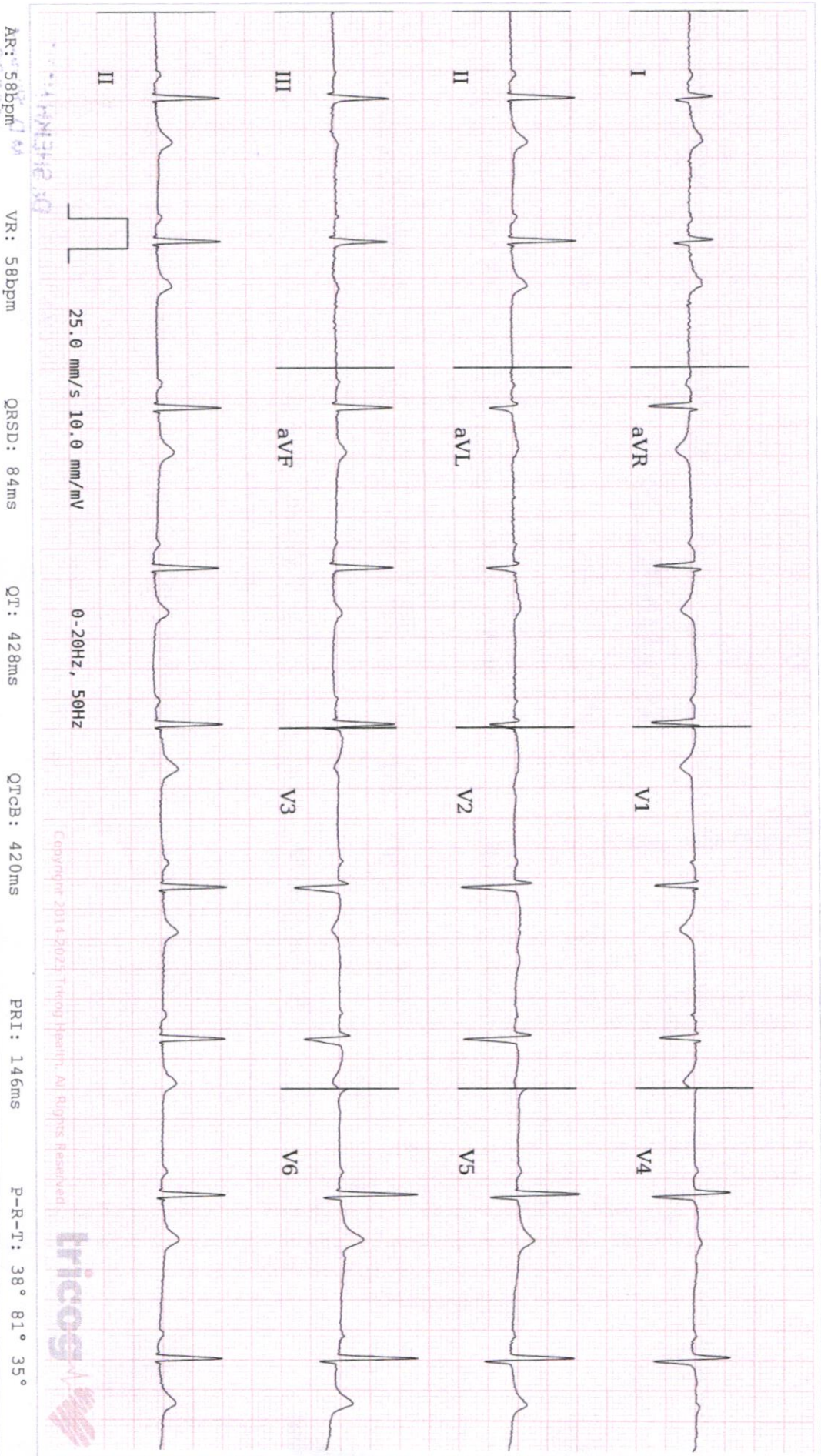
Date of First Issue: 18-08-2020  
Validity: 04-03-2034  
CDOI: 18/08/2020  
Date of Birth: 05-03-1994  
Blood Group: A+ VE

Name: **DIVYA VERMA**  
Son/Daughter/Wife of: **BHANU PRATAPVERMA**



*Divya*

**MALIK RADIX HEALTH CARE PVT. LTD.**  
C-217, C-218, Nirman Vihar,  
Delhi-110092  
Ph.: 011-49287456, 011-61381379  
Regd. No. 607





# Malik Radix HealthCare.

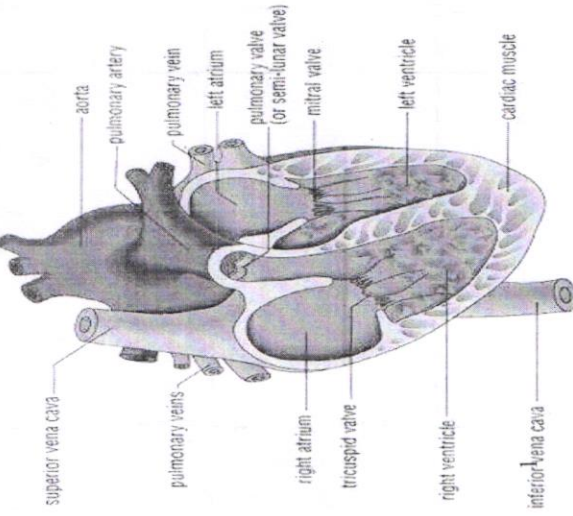
## ELECTROCARDIOGRAM

Name: MRS.DIIVYA VERMA

Age & Sex: 31YRS/FEMALE

Ref by: MEDIWHEEL

DATE: 08/03/2025



### EKG FINDINGS:

Rate 58 bpm Rhythm Sinus Sinus Mechanism Normal

Axis Normal Wave Normal PR Interval 0.14/Sec

QRS Complex Normal QT Interval Normal Q Wave Normal

ST Segment Normal T Wave Normal

Conclusion Sinus Rhythm (HR- 58 bpm), Normal Axis, To be correlate.

Doctors Signature Dr. SHEKHAN  
 M.D. Physician  
 PGDCC  
 DMC-46499




## Echocardiogram Report

Patient Name	MRS. DIVYA VERMA
Date of Test	08/03/2025
Age	31YRS/FEMALE
Ref. by	MEDIWHEEL

Dimensions	Result	Normal Range
AO (ed)	2.2 cm	( 2.1 -3.7cm)
LA (es)	2.4 cm	(2.1 -3.7cm)
RVID (ed)	2.2 cm	(1.1-3.0cm)
LVID (ed)	3.5 cm	(3.6 – 5.5 cm)
LVID (es)	2.4 cm	(2.3-3.9cm)
IVS (ed)	1.0 cm	(0.6 – 1-2 cm)
LVPW (ed)	1.1 cm	(0.6 – 1-2 cm)
EF	59 %	
FS	31 %	(28 % - 42 %)

### Impression:

- NO REGIONAL WALL MOTION ABNORMALITY SEEN.
- LVEF= 59 %
- NORMAL CHAMBER DIMENSIONS.
- NORMAL MIP.
- NORMAL COLOR FLOW
- NO INTRA CARDIAC CLOT/MASS/ VEGETATION/PERICARDIAL EFFUSION SEEN.

  
 Dr. Sheikh Nazir Ahmed  
 M.D. "Physician" PGDCC  
 (Consultant Non – Invasive Cardiologist)

### Facilities Available

- Multispeciality Hospital - 24 Hours Emergency - X-Ray/ ECG/ Ultrasound/ CT Scan - Dental- Fully Equipped Operation Theatre  
 - Fully Functional Lab - 24/7 Casualty/ ICU-Nursery 24/7 Pharmacy - Labrour Room - All Speciality OPD - Laproscopic Surgery -  
 ECHO - Plastic Surgery





## EYE EXAMINATION (AHC)

Name: Mrs. Divya Verma	Age & Gender: 31 / F
Ref.by: Medicheel	Date: 08/03/25

Without Correction		With Correction	
Distance - Right	6/8	Distance - Right	Left
Distance - Left	6/8	Distance - Right	Left
Near - Right	NG	Near - Right	Left
Near - Left	NG	Near - Right	Left

Color Vision: Normal  Abnormal

Diagnosis: No Error

Treatment Recommended: \_\_\_\_\_

*Dr. Nidhi Gupta*  
**Dr. Nidhi Gupta**  
 MBBS, MS, DNB  
 Casualty Ophthalmologist  
 Malik Radix Healthcare Pvt. Ltd.  
 DMC No. 121661

### Facilities Available

- Multispeciality Hospital - 24 Hours Emergency - X-Ray/ ECG/ Ultrasound/ CT Scan - Dental- Fully Equipped Operation Theatre
- Fully Functional Lab - 24/7 Casualty/ ICU-Nursery 24/7 Pharmacy - Labour Room - All Speciality OPD - Laproscopic Surgery - ECHO - Plastic Surgery



# RADIX COSMO DENTAL

(UNIT OF MALIK RADIX HEALTHCARE PVT. LTD.)  
C-216, 217, 218, Nirman Vihar, Vikas Marg, Delhi - 110092  
Ph. : 011-22508272, 22520249 • M. : 9999254639  
E-mail : radixhealthcare@yahoo.co.in • www.radixhealthcare.org



- CONSULTANTS ON PANEL**
- PAEDIATRICS**  
Dr Ravi Malik (MBBS, MD)  
Dr Harit Prasad (MBBS, MD, Pfd)  
Dr Ritu Jain (MBBS, MD)
- GYNAECOLOGY**  
Dr Renu Malik (MBBS, MD)  
Dr Meena Malhotra (MBBS, MD)  
Dr Rajni (MBBS, MD)  
Dr Manju Gupta (MBBS, MS)  
Dr Vaishali Saini (MBBS, DGO)  
Dr Rupam Arora (MBBS, MD)
- DENTAL**  
Dr Shruti Malik (BDS, MDS)  
Dr Annu Saini (BDS, MDS)  
Dr Rachit Thukral (BDS, MDS)  
Dr Mohit Mangla (BDS, MDS)  
Dr Tarun Mittal (BDS, MDS)  
Dr Geetika Sharma (BDS)  
Dr Shilpa Verma (BDS)
- CHILD GASTROENTEROLOGY**  
Dr S. K Mittal (MBBS, MD)
- MEDICINE**  
Dr A S Talwar (MBBS, MD)  
Dr Sunny Uppal (MBBS, MD)  
Dr Surendra Rajpal (MBBS, MD)
- RESPIRATORY MEDICINE /PULMONOLOGY**  
Dr Abhinav Bhanot (MBBS, DNB)
- LAPAROSCOPY SURGERY**  
Dr Ajay Jain (MBBS, MS)  
Dr Deepak Saran (MBBS, MS)  
Dr Pradeep Saini (MBBS, MS)  
Dr G. S Garg (MBBS, MS)
- ORTHOPAEDICS**  
Dr Vikas Bhardwaj (MBBS, MS ORTHO, DNB)  
Dr Prabhakar Aggarwal (MBBS, MS ORTHO)  
Dr KB Tiwari (MBBS, MS ORTHO)  
Dr Deepak Kumar Arora (MBBS, MS ORTHO)
- EYE/OPTHALMOLOGY**  
Dr Nidhi Gupta (MBBS, MS, DNB, PGDM)  
Dr Himanshu Singh Pundir (MBBS, MS)
- ENT**  
Dr Sharad Kumar Singhi (MBBS, MS)  
Dr Prateek Sharma (MBBS, MS)  
Dr Ashok Singh (MBBS, MS)  
Dr A K Lahiri (MBBS, MS)
- RADIOLOGY(ULTRASOUND)**  
Dr K K Sinha (MBBS DNRB)  
Dr T K Vohra (MBBS, MD)  
Dr Rajesh Malhotra (MBBS, MD)  
Dr Ashish Tomar (MBBS, MD)
- PATHOLOGY**  
Dr Reema Dahiya (MBBS, MD PATH)  
Dr Meenu Aggarwal (MBBS, MD PATH)
- ANAESTHESIA**  
Dr Rajesh Dhall (MBBS, MD)  
Dr Rakesh Atray (MBBS, MD)  
Dr R K Arora (MBBS, MD)  
Dr Swaraj Garg (MBBS, MD)
- DERMATOLOGY**  
Dr Niharika Jha (MBBS, MD)
- PLASTIC & COSMETIC SURGERY**  
Dr Ayush Jain (MBBS, MS, MCh)
- PAEDIATRIC SURGERY**  
Dr Dharmendra Singh (MBBS, MS, M.Ch)  
Dr Satish Aggarwal (MBBS, MS, M.Ch)
- PAEDIATRIC NEPHROLOGY**  
Dr A S Vasudev (MD, Dip.in. Paed.)
- NEPHROLOGY**  
Dr Javed (MBBS, MD, Nephro)
- CARDIOLOGY**  
Dr Nishant Tyagi (MBBS, MD)
- NEUROLOGY**  
Dr Amit Batra (MBBS, MD)
- GASTROENTEROLOGY**  
Dr Deepak Lahoti (MBBS, MD)  
Dr Naresh Aggarwal (MBBS, MD)  
Dr Ashok Goyal (MBBS, MD)  
Dr Ankur Singhal (MBBS, MD)
- UROLOGY**  
Dr Nikhil Sharma (MBBS, Mch)  
Dr Ankur Singhal (MBBS, MD)
- PSYCHIATRY**  
Dr Mohit Sharma (MBBS, MD)
- PHYSIOTHERAPY**  
Dr Kirti Dwivedi  
Dr Ravi Kumar
- NUTRITIONIST**  
Dr Deepika Kohli  
Dr Sakshi Rana
- CLINICAL PSYCHOLOGIST**  
Dr. Sarika Singh

**Dr. Shruti Malik**  
BDS, MDS (Endodontics)  
(+91-9899561092)

Name : Divya verma  
Age/Sex : 31y / F  
Date : 8/03/2025

**Timings : 10:00 am. to 2:00 pm.**  
**6:00 pm. to 8:30 pm.**

**For Appointment**  
**011-45152510**  
**+91-9999254639**

**CLINICAL EXAMINATION:-**

*Regular health check up.*

**1. TMJ:-**

*M/M - N.B.H. (Rheumatoid Arthritis)*

**2. DENTAL STATUS:**

- a. Caries Teeth : 0/E=
- b. Fracture Teeth : 0/E=
- c. Root Stumps : 0/E=
- d. Gingivitis : -
- e. Periodontitis : -
- f. Impacted Teeth : -
- g. Malaligned Teeth : -

*- Calculus + + Stains + +*

*- carious 8 / 8*

**3. ORAL LESIONS:-**

*Adv mouthwash, Periogard 2x 3 months*

**4. DIAGNOSIS:-**

**5. TREATMENT PLANNING:**

*- Scaling and Polishing*

**6. FOLLOW UP:-**

**Referral To Other Consultant: Yes/ No**

If Yes, please mention the Name: .....

Doctor's Signature ..... *Sarika Singh 8/03/2025*

**Facilities Available :**

- ★ MULTI-SPECIALITY HOSPITAL ★ MODULAR FULLY EQUIPPED OT ★ NURSERY ★ LAPROSCOPIC SURGERY
- ★ 24X7 EMERGENCY ★ OPG ★ DENTAL ★ 24X7 DIAGNOSTICS ★ LABOUR ROOM ★ ECHO ★ EEG ★ DIGITAL X-RAY ★ CT SCAN
- ★ ECG ★ ULTRASOUND ★ RICU/ICU ★ ALL SPECIALITY OPD ★ PLASTIC & COSMETIC SURGERY ★ DIALYSIS ★ PHARMACY





**LAB REPORT**

Reg. Date	08/03/2025	Patient Id	2503080007	DOB.
Name	MRS. DIVYA VERMA	Gender	F	Perm. ID
Age	31 Yrs.	Panel	MEDIWHEEL	Reported
Ref. By	MEDIWHEEL			08/03/2025 18:30:53

Test Name	Result	Units	Ref. Range
MEDIWHEEL ANNUAL PLUS CHECK			

**HAEMATOLOGY**

**COMPLETE HAEMOGRAM**

HAEMOGLOBIN (HB%)	13.0	gm/dl	12 - 15
TOTAL LEUCOCYTE COUNT (TLC)	7,130	/cumm	4000 - 11000
<b>DIFFERENTIAL LEUCOCYTE COUNT (DLC)</b>			
NEUTROPHIL	54.9	%	40 - 80
LYMPHOCYTE	35.6	%	28 - 55
MONOCYTE	4.2	%	02 - 10
EOSINOPHIL	4.6	%	01 - 06
BASOPHIL	0.7	%	0 - 0
ESR (WESTEGREN'S METHOD)	12	mm/1st hr.	0 - 15
R B C COUNT	5.23	Millions/cmm	4.5 - 5.5
P.C.V / HAEMATOCRIT	42.6	%	35 - 45
M C V	81.5	fl.	80 - 100
M C H	24.9	Picogram	27.0 - 31.0
M C H C	30.5	gm/dl	33 - 37
PLATELET COUNT	2.56	Lakh/cu mm	1.50 - 4.50
BLOOD GROUP ABO	" A "		
RH TYPING	Positive		
BLOOD SUGAR FASTING	90.64	mg/dl	70 - 100
BLOOD SUGAR PP	95.59	mg/dl	90 - 140
HB A1C	5.80	%	04 - 5.7

**Interpretation**

Checked by : \_\_\_\_\_  
Page 1 Contd...2

If test results are alarming or unexpected, patient is advised to contact the laboratory immediately for possible remedial action.

**Facilities Available**

- Multispeciality Hospital - 24 Hours Emergency - X-Ray/ ECG/ Ultrasound/ CT Scan - Dental- Fully Equipped Operation Theatre
- Fully Functional Lab - 24/7 Casualty/ ICU-Nursery 24/7 Pharmacy - Labour Room - All Speciality OPD - Laproscopic Surgery - ECHO - Plastic Surgery





**LAB REPORT**

Reg. Date	08/03/2025	Patient Id	2503080007	DOB.	
Name	MRS. DIVYA VERMA	Gender	F	Perm. ID	
Age	31 Yrs.	Panel	MEDIWHEEL	Reported	08/03/2025 18:30:53
Ref. By	MEDIWHEEL				

Test Name	Result	Units	Ref. Range
NON- DIABETIC	:<5.7 %		
PRE DIABETES	: 5.7- 6.4%		
DIABETES	: >6.5%		
GOOD CONTROL DIABETES	: <7 %		

The Glycosylated haemoglobin assay has been validated as a reliable indicator Of mean blood glucose levels for a period of 8-12 week period. ADA recommended the testing twice a year in patients with stable blood glucose and quarterly. If treatment change, or if blood glucose levels are unstable.

TO BE CORRELATED CLINICALLY.

**THYROID PROFILE**

Free T3 ELFA	1.09	ng/ml	02 - 04
Free T4 ELFA	1.22	ug/dl	0.8 - 2.7
TSH Serum/ELFA	1.130	uIU/ml	0.25 - 5.50 uIU/ml

**Interpretation**

**Clinical Use**

- Diagnose Hypothyroidism and Hyperthyroidism
- Monitor T4 replacement or T4 suppressive Therapy
- Quantify TSH levels in the subnormal range

Increased Levels : Primary Hypothyroidism Subclinical Hypothyroidism, TSH dependent, Thyroid Hormone Resistance.

Checked by : \_\_\_\_\_  
 Page 2 Contd...3

If test results are alarming or unexpected, patient is advised to contact the laboratory immediately for possible remedial action.

**Facilities Available**

- Multispeciality Hospital - 24 Hours Emergency - X-Ray/ ECG/ Ultrasound/ CT Scan - Dental- Fully Equipped Operation Theatre
- Fully Functional Lab - 24/7 Casualty/ ICU-Nursery 24/7 Pharmacy - Labour Room - All Speciality OPD - Laproscopic Surgery - ECHO - Plastic Surgery





**LAB REPORT**

Reg. Date	08/03/2025	Patient Id	2503080007	DOB.
Name	MRS. DIVYA VERMA	Gender	F	Perm. ID
Age	31 Yrs.	Panel	MEDIWHEEL	Reported
Ref. By	MEDIWHEEL			08/03/2025 18:30:53

Test Name	Result	Units	Ref. Range
Decreased Levels : Grave's Disease, Autonomous Thyroid Hormone Secretion, TSH Deficiency			

**LIPID PROFILE**

TOTAL CHOLESTEROL	143.96	mg/dL	130.0 - 200.0 (<200)
TRIGLYCERIDES	99.40	mg/dL	80.5 - 150.0 (<150)
H D L CHOLESTEROL DIRECT	43.85	mg/dL	42.0 - 60.0 (<40->59)
V L D L	19.9	mg/dL	4.0 - 30. (23-45)
L D L CHOLESTEROL	80.2	mg/dL	50.0 - 150.0 (50-150)
TOTAL CHOLESTEROL / HDL RATIO	3.3		3.3 - 5.1
LDL / HDL CHOLESTEROL RATIO	1.8		1.5 - 3.5

**LIVER FUNCTION TEST (LFT)**

BILIRUBIN TOTAL	0.45	mg/dl	0.2 - 1.2
CONJUGATED (D. BILIRUBIN)	0.16	mg/dl	0.00 - 0.3
UNCONJUGATED (I.D.BILIRUBIN)	0.29	mg/dl	0.2 - 0.9
SGOT / AST	19.80	IU/L	0 - 35
SGPT / ALT	16.7	IU/L	0 - 35
ALKALINE PHOSPHATASE	88.20	U/L	64 - 306
TOTAL PROTEIN	6.70	gm/dl	6.0 - 8.3
ALBUMIN	4.29	gm/dl	3.2 - 5.0
GLOBULIN	2.41	gm/dl	2.5 - 5.6
A/G RATIO	1.78		0.9 - 2.0
GAMMA GT	15.20	IU/L	0.0 - 35.0

Checked by : \_\_\_\_\_  
Page 3 Contd...4

If test results are alarming or unexpected, patient is advised to contact the laboratory immediately for possible remedial action.

**Facilities Available**

- Multispeciality Hospital - 24 Hours Emergency - X-Ray/ ECG/ Ultrasound/ CT Scan - Dental- Fully Equipped Operation Theatre  
- Fully Functional Lab - 24/7 Casualty/ ICU-Nursery 24/7 Pharmacy - Labour Room - All Speciality OPD - Laproscopic Surgery -  
ECHO - Plastic Surgery





**LAB REPORT**

Reg. Date	08/03/2025	Patient Id	2503080007	DOB.	
Name	MRS. DIVYA VERMA	Gender	F	Perm. ID	
Age	31 Yrs.	Panel	MEDIWHEEL	Reported	08/03/2025 18:30:53
Ref. By	MEDIWHEEL				

Test Name	Result	Units	Ref. Range
SERUM CREATININE	0.55	mg/dl	0.6 - 1.2
SERUM URIC ACID	2.93	mg/dl	2.4 - 6.0
BLOOD UREA NITROGEN (BUN)	18.90	mg/dl	6.0 - 21.0
BUN/CREAT RATIO	34.3	mg/dl	10 - 20

*Dr. Reema Dahiya*  
**Dr. REEMA DAHIYA**  
M.B.B.S, MD (Path)  
Malik Radix Healthcare Pvt. Ltd.  
C-217, C-218, Nirman Vihar,  
Delhi-110092

**DR. MEENU AGGARWAL**  
M.B.B.S, MD (Path.)

If test results are alarming or unexpected, patient is advised to contact the laboratory immediately for possible remedial action.

**Facilities Available**

- Multispeciality Hospital - 24 Hours Emergency - X-Ray/ ECG/ Ultrasound/ CT Scan - Dental- Fully Equipped Operation Theatre
- Fully Functional Lab - 24/7 Casualty/ ICU-Nursery 24/7 Pharmacy - Labour Room - All Speciality OPD - Laproscopic Surgery - ECHO - Plastic Surgery



R

VERMA 31YF PT236180 CHEST PA 08 03 2025  
MADIX JH of VERMA C 100 FIRMATA VERMA C 100



UHID	PT236480	LAB No.	XRY2423384
Name	Mrs. DIVYA VERMA	Regn. No.	GEN2445988
Age / Sex	31 Yrs / F	Receiving Dt/Time	08-Mar-2025 10:53
		Reporting Dt/Time	08-Mar-2025 05:30 PM



**XRAY**

CHEST (PA)

Both lung fields are normal.

Cp angles are clear.

Hila are normal...

Heart size appears within normal limits.

Soft tissue shadows and bony thorax are normal.

Advised....please correlate clinically.

\*\*\*\*\* END OF REPORT \*\*\*\*\*

Approved By :

Approval Date : 00:00:00

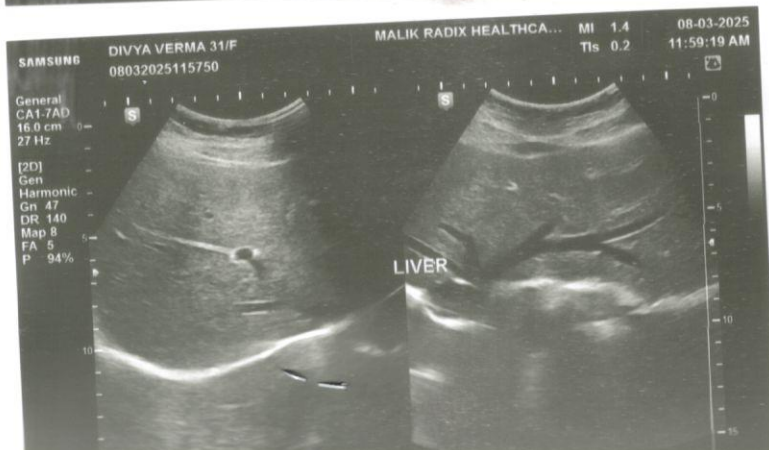
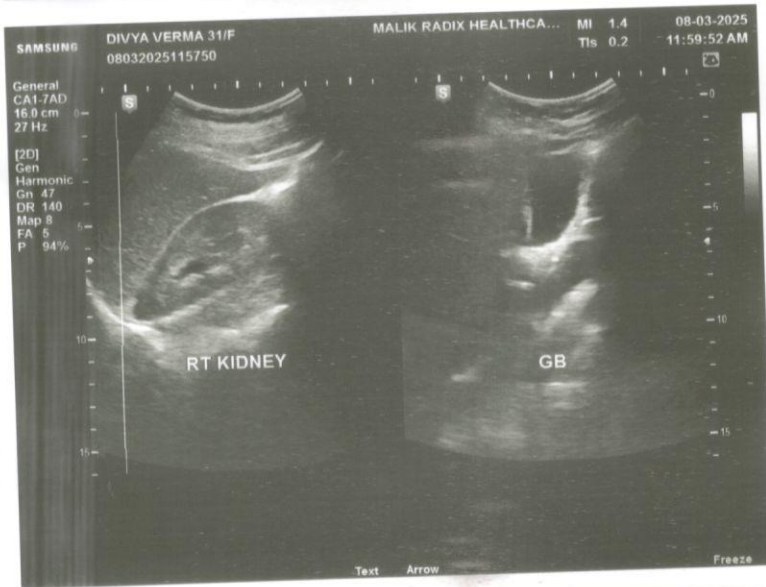
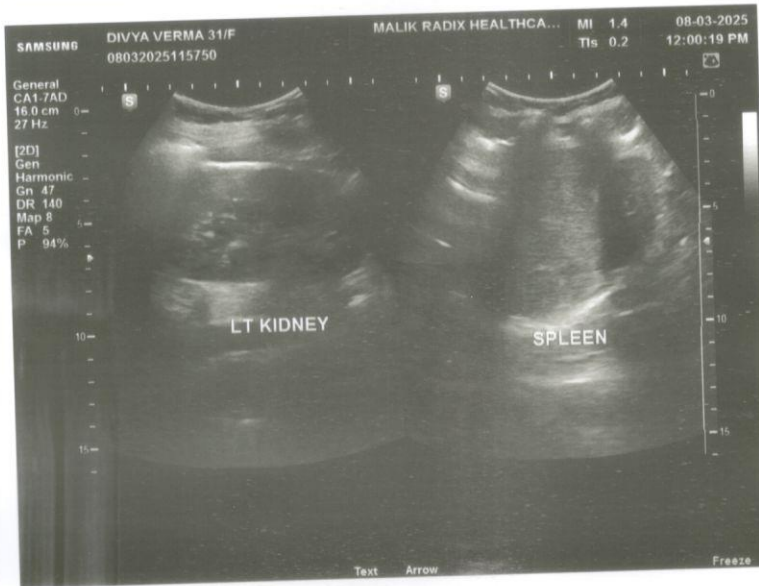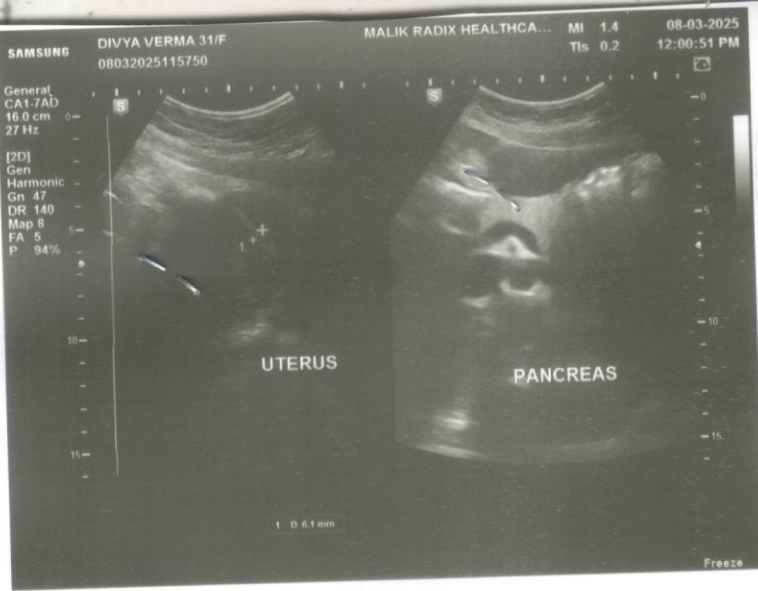~~DR. K. K. SINHA  
 M.B.B.S., D.M.R.D.  
 SENIOR CONSULTANT  
 Reg. No. 29437 (DMC)~~

DR. T. K VOHRA  
 MD (RADIOLOGYSIS)  
 SENIOR CONSULTANT  
 Reg. No. 3272 (DMC)

DR MUKESH KOSHAL  
 MBBS, MD (RADIOLOGY)  
 CONSULTANT RADIOLOGY  
 Reg.No.DMC10407

**Facilities Available**







**RADIX  
HEALTH  
care**



Radix Healthcare

**Malik Radix Healthcare**

C/217, C/218, Vikas Marg, Nirman Vihar, New Delhi-110092  
A Unit of Malik Radix Healthcare  
Toll Free - 1800-120-5457, Tel. : 011 49287456, 61381379  
Whatsapp No. - 9811550650  
E-mail: radixhealthcare@yahoo.co.in  
Website: www.radixhealthcare.org



<b>NAME</b>	<b>MRS DIVYA VERMA</b>	<b>AGE</b>	<b>31 Y/F</b>
<b>REFD. BY.</b>	<b>HEALTH CHCEK UP</b>	<b>DATE</b>	<b>08.03.25</b>

**Ultrasound Examination of Whole Abdomen & Pelvis:**

**Liver:** Liver shows normal parenchymal echotexture. No focal SOL is seen in liver. IHBR & portal radicles are normal.

**Gallbladder:** Gallbladder shows normal anechoic pattern. No evidence of cholecystitis or cholelithiasis seen. Common bile duct is normal in course & caliber.

**Pancreas:** Pancreas shows normal size & echotexture.

**Spleen:** Spleen shows normal size, outline & echotexture.

**Kidneys:** Kidneys show normal size, shape, position & echotexture. No calculus, hydronephrosis or SOL is seen in kidneys. Cortico- medullary differentiation and cortical thickness is normal on both sides.

No supra- renal mass seen.

Great abdominal vessels are normal.

Domes of diaphragm are seen to move normally & synchronously in respiration. No supra- or infra diaphragmatic collection is seen.

No ascites or pericardial effusion seen.

No para aortic lymph nodes seen.

**Urinary bladder:** Urinary bladder shows normal anechoic pattern. No calculus, SOL or diverticulum seen.

**Uterus:** Uterus is anteverted and normal in size & echotexture. No intrinsic SOL is seen in uterus. Endometrial thickness is 6.1 mm.

**Adnexa:** Adnexal regions including the ovaries are sonographically normal.

Normal study.

Regards.

**Dr Mukesh Koshal MD (Rad- diag)**

Regn. No. DMC 10407

**RADIOLOGIST :**

**Facilities Available**

- Multispeciality Hospital - 24 Hours Emergency - X-Ray/ ECG/ Ultrasound/ CT Scan - Dental- Fully Equipped Operation Theatre  
- Fully Functional Lab - 24/7 Casualty/ ICU-Nursery 24/7 Pharmacy - Labour Room - All Speciality OPD - Laproscopic Surgery -  
ECHO - Plastic Surgery