


MEESHA DIAGNOSTICS & POLYCLINIC

La view building, 1st floor, Mahalaxmi, Mumbai - 400 011
7710084305/ 022-23053534



NAME : Vaibhav Musale. AGE/SEX : 41 YEARS / M

REFERRED BY : Mediwheel DATE : 7/3/25

Details to be filled by Patient

PERSONAL HISTORY:

Sleep	Disturbed/Sound	Acidity	Intermittent
Appetite	Good/Reduced/Increased	Exercise	Yoga / walk / gym - <u>cricket</u>
Micturition	Burning/Normal	Diet	Veg / Non Veg / <u>mixed</u> / vegan
Bowel Movement	Regular/Irregular/Constipation	Marital Status	Unmarried / <u>married</u>
Water Intake	<u>3-4 litres/day</u>		

PAST HISTORY:

Any Allergies	} Nil	Coronary Heart Disease	} Nil
Hypertension		Any Operations Surgery	
Diabetes		Treatment/Medication History	
Tuberculosis		Hospitalization	
Thyroid		Thalassemia	
Asthama		Stress / depression	
		Others	

SOCIAL HISTORY: -

Drinking	<u>Occasionally.</u>
Smoking	<u>Nil</u>

FAMILY HISTORY:

RELATIONSHIP	ALIVE/NOT ALIVE	IF ALIVE GIVE PRESENT STATE OF HEALTH/ IF NOT ALIVE SPECIFY CAUSE OF DEATH
Father	<u>Alive</u>	<u>Healthy</u>
Mother	<u>Alive</u>	<u>HTN, DM</u>
Sister		
Brother	<u>Elder</u>	<u>Healthy</u>
Wife/Husband	<u>wife</u>	<u>Healthy</u>
Children	<u>1 son</u>	<u>Healthy</u>

ONLY FOR FEMALE PATIENTS

Frequency & Regularity of Periods _____ Any Children _____
Contraception _____ Full Term / Premature _____
Pregnancy / Miscarriage / Termination _____

Details to be filed by Medical Practitioner

VITAL SIGNS:-

Temperature 98°F
Respiratory Rate 12/min
Pulse rate / rhythm 1
Blood Pressure 140/90 mmHg

Basic Measurements
Height 167 cm
Weight 71.65 kg
BMI 25.5

PHYSICAL EXAMINATION:

ABDOMINAL EXAMINATION: No Hepatosplenomegaly, No Tenderness.

Inspection	} (N)	Spleen	} (N)
Palpation		Other	
Liver		Tenderness	

NERVOUS SYSTEM: All reflexes and cranial nerves are normal. No sensory / motor deficit detected.

Reflexes	} (N)	Sensory Nerve	} (N)
Cranial Nerve		Motor System	
Sensory Nerve		Others	

CARDIO VASCULAR SYSTEM: Heart Sounds Normal. No other abnormality detected.

HEART SOUNDS:-			
Heart Sound 1	} S1S2 (H)	Murmur	Nil
Heart Sound 2		Other Findings	

RESPIRATORY SYSTEM: Air entry normal and equal on both sides. No added sounds or other abnormality detected.


Inspection of Thorax	} (N)	Breathing	} (N)
Auscultation		Added Sounds	
Air Entry		Other Findings	

SUGGESTIONS:

Fit

RECOMMENDATION:-

Fit.

Dr. Name: 


DR. VARUN DEODHAR
MBBS
MASTERS EMERGENCY MEDICINE/PHYSICIAN
(MUM/USA)
Reg. No. 2013010115


भारत निवडणूक आयोग
ऑळखपत्र
ELECTION COMMISSION OF INDIA
IDENTITY CARD
TDW4871133

मतदाराचे नांव : वैभव जगन्नाथ मुसळे
Elector's Name : Vaibhav Jaganath Musale
वडिलांचे नांव : जगन्नाथ मुसळे
Father's Name : Jaganath Musale
लिंग / Sex : पुरुष / MALE
जन्म तारीख / Date of Birth : 14/05/1983

Self Attested


3/3/2025



Patient ID:	56373	Patient Name:	VAIBHAV MUSALE
Age:	41	Sex:	MALE
Study Date:	7/3/2025 9:25:20 AM	Ref. By:	MEDIBUDDY

X-RAY CHEST PA VIEW

FINDING

Both lung fields are clear.

Both costophrenic angles appear normal.

The hila, mediastinal and diaphragmatic outlines appear normal.

Cardiac silhouette appears normal.

The bony thoracic cage and soft tissues are normal.

IMPRESSION

No significant abnormality is seen.

Shardul
Dr Shardul Gund
MD RADIOLOGY
MMC 2018030488



Patient:

VRIBHARV MUSALE

HR 98/min

Axix: 60°

SINUS RHYTHM

LEFT ATRIAL ABNORMALITY

INCOMPLETE RIGHT BUNDLE BRANCH BLOCK

41 year / M
167 cm / 71 kg
140/90 mmHg

Intervals:	P	60°
RR	QRS	32°
P	T	39°
PR	P (II)	0.14 mV
QRS	S (V1)	-1.16 mV
QT	R (V5)	2.34 mV
QTc	Sokol.	3.49 mV

DR. VARUN D. DHAR

MBBS.

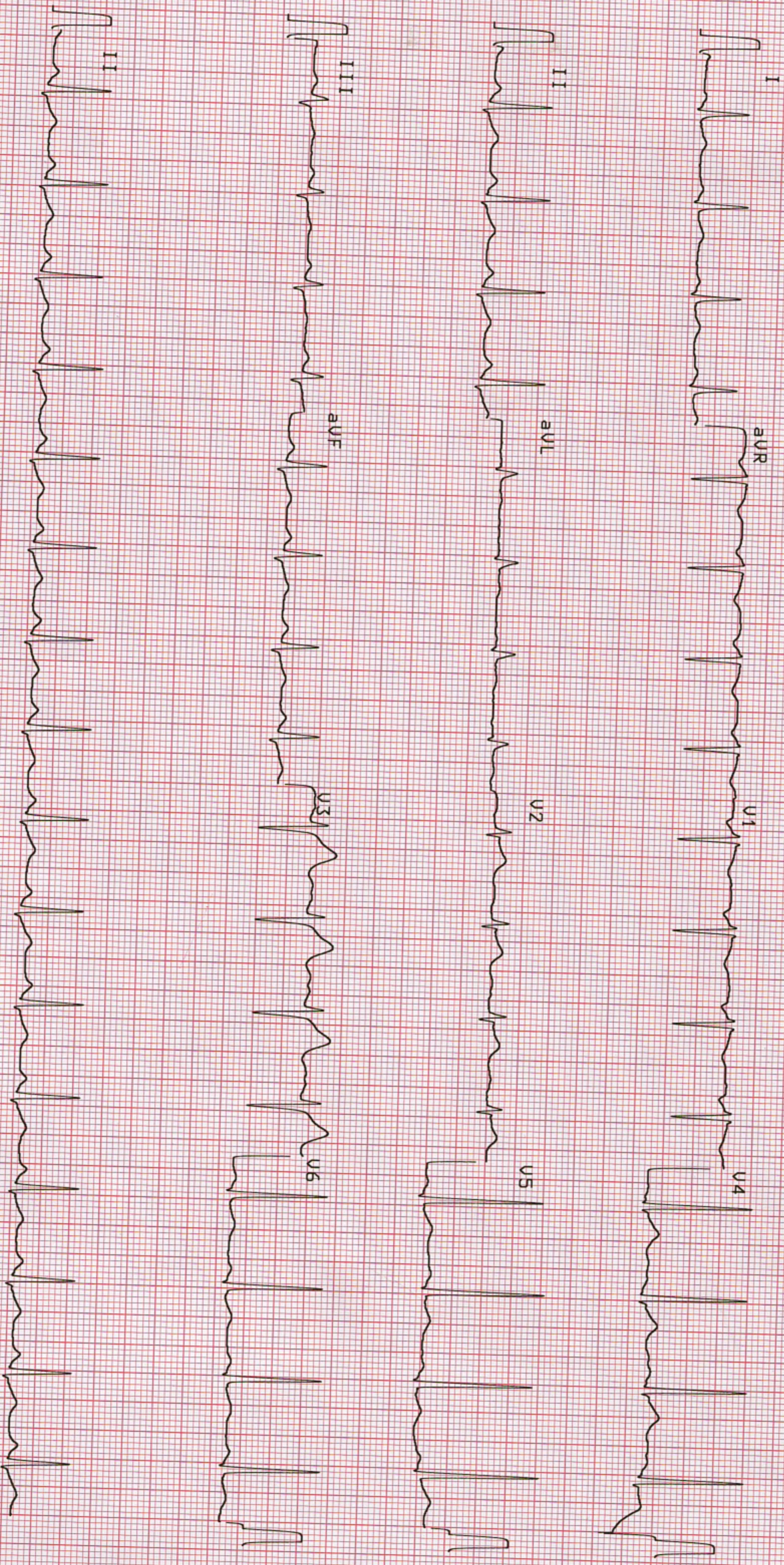
MASTERS EMERGENCY MEDICINE/PHYSICIAN

(MUM/USA)

Reg. No. 2013010115

10 mm/mV

10 mm/mV



25 mm/s

0.05-25Hz FS0 55F SBS Fr 07-MAR-25 14:12:53

SCHILLER

MEESHA DIAGNOSTICS/POLYCLINIC

AT-2plus 4.14 CM

NAME:- Mr. Vaibhav Musak
DATE:- 07/03/2025
REFERRED BY:-

REF No. :-
AGE/SEX:- 41/M

EYE CHECKUP

HISTORY OF EYE RELATED COMPLAINTS: Routine check up

HISTORY OF SYSYEMIC ILLNESS : Nil

EXAMINATION		RIGHT	LEFT																																					
Distance vision	Without correction	6/6	6/6																																					
	With correction																																							
Near Vision	Without correction	N6	N6																																					
	With correction																																							
ANTERIOR SEGMENT		WNL	WNL																																					
LENS																																								
POSTERIOR SEGMENT		undilated - WNL	undilated - WNL																																					
ROPLAS																																								
TENSION																																								
COLOR VISION		WNL	WNL																																					
DAIGNOSIS	Presbyopia																																							
ADVICE : - Glasses for near sos. - Eye check up annually																																								
	<table border="1"> <thead> <tr> <th></th> <th colspan="4">RIGHT</th> <th colspan="4">LEFT</th> </tr> <tr> <th></th> <th>SPH</th> <th>CYL</th> <th>AXIS</th> <th>Vn</th> <th>SPH</th> <th>CYL</th> <th>AXIS</th> <th>Vn</th> </tr> </thead> <tbody> <tr> <td>DISTANCE</td> <td>—</td> <td></td> <td></td> <td>6/6</td> <td>—</td> <td></td> <td></td> <td>6/6</td> </tr> <tr> <td>NEAR</td> <td>+1.00</td> <td></td> <td></td> <td>N6</td> <td>+1.00</td> <td></td> <td></td> <td>N6</td> </tr> </tbody> </table>					RIGHT				LEFT					SPH	CYL	AXIS	Vn	SPH	CYL	AXIS	Vn	DISTANCE	—			6/6	—			6/6	NEAR	+1.00			N6	+1.00			N6
	RIGHT				LEFT																																			
	SPH	CYL	AXIS	Vn	SPH	CYL	AXIS	Vn																																
DISTANCE	—			6/6	—			6/6																																
NEAR	+1.00			N6	+1.00			N6																																

CONCLUSION:

DR. LANIN CHEN
(OPHTHALMOLOGIST)

DR. LANIN CHEN
MBBS, M.S. (Ophthal.), F.V.R.S.
Consultant Ophthalmologist
MMC2014052338
+91 8369213821



ISO : 9001:2015 Certified

Right Diagnosis, Right Treatment, Right Place



YOUR PARTNER IN HEALTH

Patient Name : MR. VAIBHAV MUSALE
Age : 41 YEARS
Ref. By : MEDIWHEEL

Mahalaxmi Centre :
1st Floor, La View, B.J. Marg, Jacob Circle,
Mahalaxmi, Mumbai - 400 011
Tel.: 2305 3534 / 36 / 77100 84305
info@meeshahealth.net
www.meeshahealth.net

BKC Centre:
310, Trade Centre, 3rd floor, BKC,
Kolivery Village, MMRDA Area, Kalina,
Bandra East, Mumbai - 400 051
Tel.: 3540 5567 / 3540 5983 /
77108 47491 / 77108 47305
Email: info.bkc@meeshahealth.net
www.meeshahealth.net

ID No : 56373
Sex : MALE
Date : 07.03.2025

ULTRASONOGRAPHY OF THE ABDOMEN AND PELVIS :

Liver

Is normal in size measures 14.3 cm and *it reveals bright echotexture.*

No focal or diffuse lesion is seen.

The biliary tree and portal vein radicals are normal.

Portal vein measures 9.3 mm.

Gall bladder

Is physiologically distended and reveals an anechoic lumen .

No gallstone or evidence of cholecystitis is seen. Common bile duct measures 4.0 mm.

Pancreas

Reveals a homogenous normal parenchymal echotexture and appears normal in size.

No solid or cystic mass lesion is seen. No pancreatic calcification or duct dilatation is seen.

Spleen

Is normal in size measures 8.5 cm . The parenchymal echotexture is normal.

No focal mass lesion is seen.

Kidneys

The right kidney measures 10.3 X 4.2 cms. The left kidney measures 9.0 X 4.6 cms.

Appear normal in size, shape and reveal normal differentiation of cortex, medulla and central echo complex.

No hydronephrosis, calculus or scarring is seen.

Urinary bladder

Was distended and revealed no intrinsic abnormality.

No para aortic lymphadenopathy or ascites is seen.

Prostate is normal in size and echotexture. It measures 3.5 X 3.1 X 2.7 cms and volume 16 cc. No obvious focal mass lesion is seen.

IMPRESSION :

- **Grade I fatty infiltration of liver.**

Dr. TARIQUE MOHAMMED KHAN
MBBS, MD (Radio Diagnosis)
Consultant Radio Diagist
Reg No - 2016/11/4918

DR. KHAN MOHAMMED TARIQUE
MBBS. MD (RADIOLOGIST).
CONSULTANT RADIOLOGIST

ISO : 9001:2015 Certified

Right Diagnosis, Right Treatment, Right Place

Patient

ID 07032025-090831AM
Name VAIBHAV MUSALE/ 41YRS
Birth Date
Gender Male

Exam

Accession #
Exam Date 07-03-2025
Description
Operator DR.TARIQUE KHAN

