

Dr. ARPITA AGARWAL

MBBS, MS, FLVPEI (GLAUCOMA AND CATARACT.)
 CATARACT, GLAUCOMA AND REFRACTIVE SURGEON
 EX FELLOW AND CONSULTANT LV PRASAD EYE INSTITUTE, HYDERABAD
 EX CONSULTANT PEOPLES'S HOSPITAL, BHOPAL
 EX CONSULTANT ASG EYE HOSPITAL, BHOPAL

NAME Mrs. Poojika AGE 361 F

DATE 25/10/2020

C/O. MHC

VN	UNAIDED	WITH GLASS	PINHOLE
RE	6/6		
LE	6/6		

AR	SPH	CYL	AXIS
RE	-0.0		
LE	-0.0		

REFRACTION;

u
 Nision X 38188 BR

SUB	SPH	CYL	AXIS	VN	PG
RE					RE
LE					LE
NV	+				

near

vision N16 BR

(50) 10000
 ad eye exam 4km
 x 1000

Agarwal



NAME	Mr. Pratiksha Shrivastava	UHID NUMBER:-	ASHB.0000054239	
REF. BY	ASH.	DATE	25.10.2024	AGE/SEX:- 36y/M

X-RAY CHEST (PA VIEW)

Both lung fields are clear. No active pleural or parenchymal lesion is seen.

The hila, mediastinum, bony thoracic cage and the diaphragmatic domes are normal.

The costophrenic and cardiophrenic angles are clear.

The cardiac silhouette is unremarkable.

IMP:- RADIOGRAPHIC IMAGE REVEALS:-

Normal findings are seen.

Thanks for Ref



DR. HARI SANTOSH
CONSULTANT RADIOLOGIST




25.10.2024 11:22:19

Female

QRS : 80 ms
 QT / QTcBaz : 378 / 444 ms
 PR : 104 ms
 P : 54 ms
 RR / PP : 720 / 722 ms
 P / QRS / T : 26 / 11 / 8 degrees

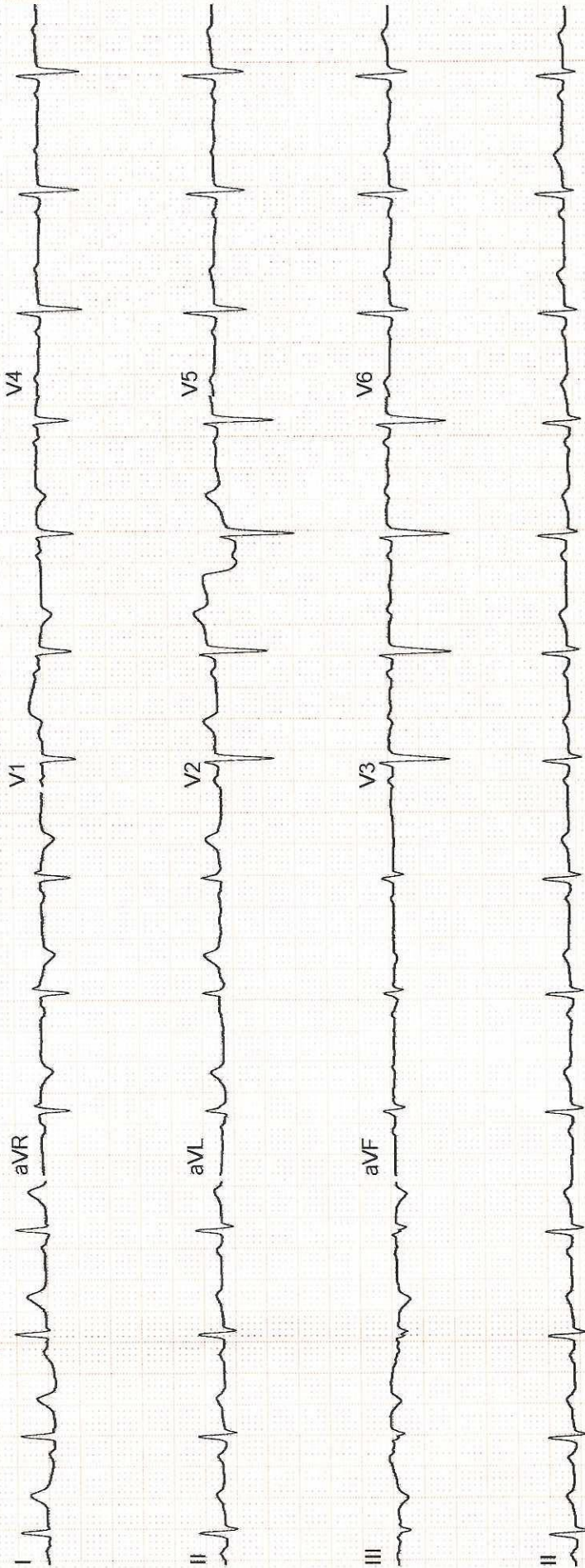
Sinus rhythm with sinus arrhythmia with short PR
 Otherwise normal ECG



Technician:
 Ordering Ph:
 Referring Ph:
 Attending Ph:

Location:
 Order No.:
 Indication:
 Medication 1:
 Medication 2:
 Medication 3:

83 bpm
 -- / -- mmHg



ULTRA SONOGRAPHY ABDOMEN

NAME	Mrs. Pratiksha Shrivastava	UHID NUMBER:- ASHB.0000054239		
REF. BY	AHC	DATE	25.10.2024	AGE/SEX:- 36y/F

Liver:- is normal in size and echotexture. Portal and hepatic venous system appears normal. Intra and extra hepatic biliary radicals are not dilated.

Gall Bladder:- is normal in size and shape. Its lumen is echofree.

Pancreas is normal in size outline and echopattern.

Spleen is normal in size and echopattern.

Both kidneys are normal in size, shape and echogenicity. Central pelvicalyceal sinus and corticomedullary ratio are normal. Few small echogenic foci are seen in mid and lower pole region of left kidney.

Right kidney measures:- 10.6x4.2cm

Left kidney measures:- 10.2x4.7cm

No evidence of ascites is seen.

Urinary bladder is normal in shape and contour. Its wall is normal.

Uterus and ovaries:- is bulky and shows focal partial calcified hypoechoic lesion measuring ~ 3.0x0.7cm identified along the lower anterior uterine wall in body region. Another small hypoechoic lesion measuring ~ 11.2x7.9mm identified in the posterior uterine wall. Cervix shows normal echopattern. No adnexal mass. No free fluid in POD.

Uterus measures:- 10.9x6.8x3.3cm

Right ovary measures 2.2x2.0cm.

Left ovary measures 1.8x1.6cm.

IMPRESSION:- Sonography Study Reveals:-

- Mild bulky uterus with intramural partial calcified fibroid and seedling uterine fibroid.
- Few left renal concretion (3mm).

ADV:- Clinical Correlation.

Nohitas

DR. HARI SANTOSH
CONSULTANT RADIOLOGIST



