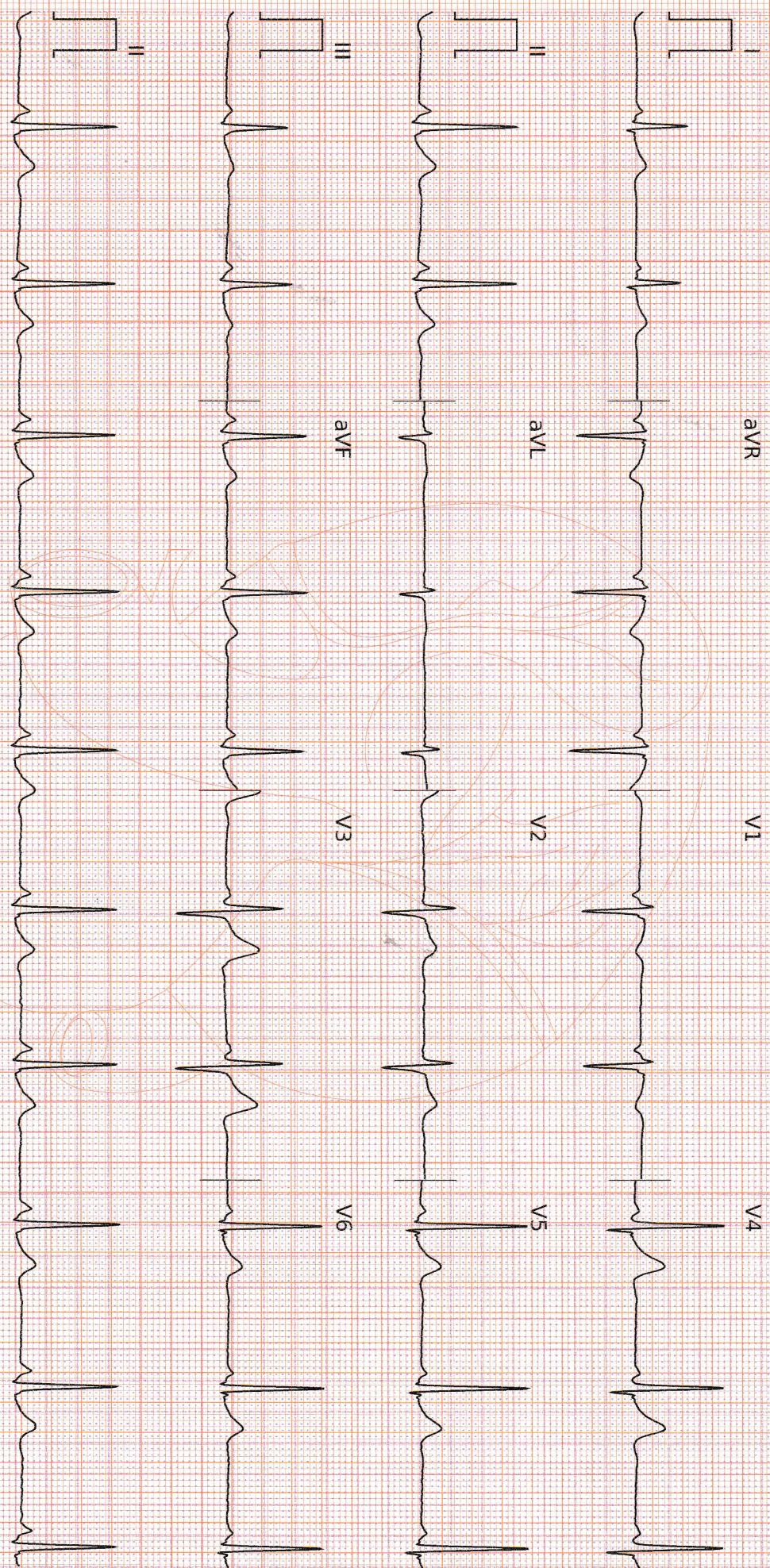


Patient Name: Sukrit Swamy
Gender: M, Age: 41 Years
Pat ID:

Recording Date: 08-Mar-2025 12:29:33
Attended by: New Vrundavan Daycare Centre
Remote Viewer: Dr Shalok D Naik

Vent. Rate: 59BPM
Avg. RR: 1012ms PR: 100ms
QRS dur: 94ms ST dur: 80ms



Dr Shalok D Naik (08-Mar-2025 12:40:10):
Findings: Within Normal Limits

Filter: 0.5Hz - 35Hz Scale: 10mm/mV, 25mm/Sec

DR. SHALOK NAIK
MBBS
GMC Reg. No. 3770

Dr Shalok D Naik
MBBS
3770

NOTE 1: Diagnosis required to verify and measure all shown measurements: Vent. Rate, Avg RR, PR, QRS dur, ST dur, QT/QTc, P-R-T Axes.
Version: ERG 0.1.D.0

mobmon

Product by Kalows Engineering India

Name : SUKRIT SWAMY
Age : 41 yrs/ MALE
Date : 08/03/2025

X-RAY CHEST PA VIEW

Bony cage is normal
Trachea is central
Heart shadow is normal
Both the domes of diaphragms are normally placed
Both cardio phrenic angles are clear
Both costo-phrenic angles are clear
Lungs fields are normal
Soft tissues appears normal

IMPRESSION:

- CHEST X-RAY APPEARS WITHIN NORMAL LIMITS.

DR. SIGNATURE

