

**DAKSH HOSPITAL**

396 - 397, Gandhi Nagar, Scheme No. 8, ALWAR -301001

Ref. No.

Date.....

MEDICAL EXAMINATION REPORT

Mediwheel (BOB)


Name: Mr Aman Saveda Age: 27 yrs Sex: Male

Date: 26/10/2024

General Physical Examination

Height	:	185 cm.	Weight	:	90.8 kg
Pulse	:	66 bpm	BP	:	120/70 mm/hg.
Temp.	:	97.6 F	Respiration SpO2	:	93 %
BMI	:	26.5			

Systemic Exam:- NORMALDental Check up :- NORMALEye check-up :- NORMALSkin Check up:- NORMALENT Check up:- NORMALGenae Check up:-Impression:- NORMALRecommendation:- NO

  
Dr. Mukesh Kumar Gupta  
MD Gen. Medicine  
Reg. No 5423/16262

डॉ० मुकेश गुप्ता  
M.D.F.C.C.S.  
फिजिशियन एवं मधुमेह रोग विशेषज्ञ  
दक्ष हॉस्पिटल, अलवर  
रजि० नं०-5423/16262

## Results

Run Date 26/10/2024 09:24:48 AM

Operator DAKSH

Last Name

Sample ID 3

First Name MR. AMAN SEVADA

Department

Gender Male Age

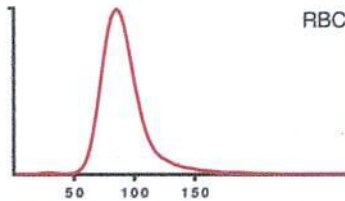
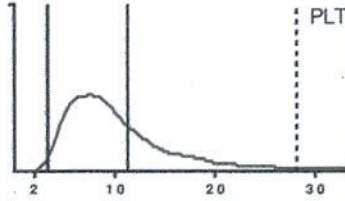
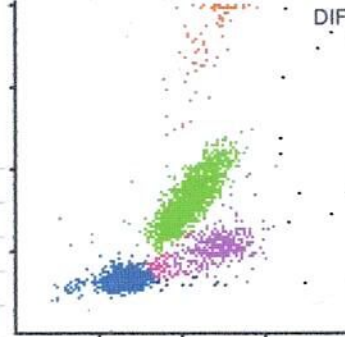
Physician DR. MUKESH GUPTA M.D

Patient ID AUTO\_PID26056

Type Man

Date of birth

Sample comments

			Range		
RBC	4.44	10 <sup>6</sup> /μL	3.80 - 5.50	 <p>RBC</p>	
HGB	13.6	g/dL	13.0 - 17.0		
HCT	39.6	%	39.0 - 52.0		
MCV	89.2	μm <sup>3</sup>	76.0 - 100.0		
MCH	30.6	pg	26.0 - 34.0		
MCHC	34.3	g/dL	32.0 - 35.0		
RDW-CV	16.1	%	11.0 - 16.0		
RDW-SD	57.3	μm <sup>3</sup>	37.0 - 49.0		
PLT	265	10 <sup>3</sup> /μL	150 - 450		 <p>PLT</p>
PCT	0.26	%	0.15 - 0.40		
MPV	9.8	μm <sup>3</sup>	8.0 - 11.0		
PDW	14.5	μm <sup>3</sup>	11.0 - 22.0		
P-LCC	78	10 <sup>3</sup> /μL	44 - 140		
P-LCR	29.5	%	18.0 - 50.0		
WBC	5.30	10 <sup>3</sup> /μL	3.50 - 10.00	 <p>DIF</p>	
	#	Range	%		Range
NEU	2.61	1.60 - 7.00	49.4		40.0 - 75.0
LYM	2.26	1.00 - 3.00	42.8		20.0 - 45.0
MON	0.17	0.20 - 0.80	3.3		2.0 - 10.0
EOS	0.14	0.00 - 0.50	2.6		1.0 - 6.0
BAS	0.10	0.00 - 0.15	1.9		0.0 - 1.0
LIC	0.02	0.00 - 0.10	0.3		0.0 - 1.0



**Dr. R.S. GUPTA**  
 MD (Pathology) (MAHE)  
 RMC No. 7924/19778

Date :- 26/10/2024 Name :- MR. AMAN SEVADA

Age & Sex :- 27 Yrs / male

Refd. :- Dr Mukesh Gupta M.D.

	TEST NAME	RESULT	REFERENCE RANGE
	ESR	12	00 -20 mm/hrs
	Blood Group & Rh Factor	A <sup>+</sup> POSITIVE	
	HbA1C	5.0	4 - 5.6%
	Blood Sugar (F)	87.3	< 70 - 100 mg/dl
	Blood Sugar (PP)	-	< 140 mg/dl
	Urine Sugar (F)	NIL	-
	Urine Sugar (PP)	-	-
<b>LIVER</b>	S.Bilirubin Total	0.90	0.30 - 1.20 mg/dl
	S.Bilirubin Direct	0.20	0.10 - 0.30 mg/dl
	S.Bilirubin Indirect	0.70	0.30 - 0.90 mg/dl
	S.G.O.T.	17	> 37 u/l
	S.G.P.T.	25	> 40 u/l
	S.Alk. Phosp.	184	80 - 306 u/l
	G.G.T.	25.0	5 -40 u/l
	Total Protein	7.0	6.5 - 8.5 gm/dl
	Albumin	4.0	3.8 - 5.4 gm/dl
	Globulin	3.0	2.3 - 3.5 gm/dl
	A/G Ratio	1.3	-
	AST/ALT Ratio	0.6	-
<b>KIDNEY</b>	Blood Urea	31.2	15 -45 mg/dl
	S.Creatinine	1.1	0.60 - 1.30 mg/dl
	BUN	17.0	6 -24 mg/dl
	S.Uric Acid	5.1	M 3.1 - 7.0, F 2.5 - 5.6 mg/dl
	BUN/Creatinine Ratio	15.4	-
<b>LIPID PROFILE</b>	Total Cholesterol	150.0	Up to 200 mg/dl
	S.HDL	44.0	30 - 70 mg/dl
	S.LDL	80.1	Up to 170 mg/dl
	S.VLDL	26.1	5.0 - 40 mg/dl
	S. Triglycerides	130.0	Up to 170 mg/dl
	LDL/HDL Ratio	1.8	-
	Total Cholesterol/ HDL Ratio	3.4	-
<b>THYROID</b>	T3	110.2	40 - 181 ng/dl
	T4	7.6	4.6 - 10.5 µg/dl
	TSH	5.44	0.30 - 5.0 mlu/l
	URINE EXAMINATION		Microscopic Examination:
<b>General/Chemical Examination:</b>			RBC Absent
	<b>Colour</b>	<b>Pale Yellow</b>	<b>WBC</b> 1-2
	Reaction	Acidic	Epithelial Cells 0-1
	Specific Gravity	QNS	Cast Absent
	Appearance	Clear	Crystal Absent
	Albumin	TRACE	Spermatozoa Absent
	Sugar	Nil	Amorphous Sediments Absent
			Other Absent
<b>X-RAY CHEST</b>	NORMAL STUDY		

*R.S. Gupta*

**Dr. R.S. GUPTA**  
MD (Pathology) (MAHE)

Doc. No. 7924/19778

**TECHNOLOGIST**

All investigation have their own limitations regarding the sensitivity & specificity of individual assay procedures, isolated laboratory investigations never confirm the final diagnosis of the disease. They only help in arriving at a diagnosis in conjunction with clinical presentation and other related investigations. Report is not valid for medico-legal purpose subject to ALWAR jurisdiction only.



# दक्ष हॉस्पिटल

396, गाँधी नगर स्कीम नं.8, अलवर (राज०) ☎ 0144-2703340

## Sonography / 2D Echo Cardiography / Doppler Report

### 2D/ ECHO REPORT

Name: - Mr AMAN SAVEDA

Age: - 27 Yrs

Date: - 26-Oct-24

Reg. No.:- Alw/2009/04  
BOB health checkup

#### PROCEDURES:

M-MODE/2D/DOPPLER/COLOR/CONTRAST B.A.S. M<sup>2</sup>


MEASUREMENT:			DOPPLER:			
AOD	20	NORMAL (20-37mm)	MV	0.8	NORMAL (cm/sec.)	
LA	22	(19-40mm)	AV	1.5	MR	No
AVO	16	(12-25mm)	TV	0.6	AR	No
RVDd.	11.6	(03-09mm)	PV	0.8	TR	No
					PR	No
LVDd	51	(37-56mm)	MITRAL VALVE-			
LVDs	32	(22-40mm)			AML	Normal
IVS d	10	(06-12mm)			PML	Normal
IVS s	13.6		AORTIC VALVE			
PWd	5.8	(05-10mm)				Normal
LV FUNCTION			TV & PV are normal.			
M- E- S Separation		<0.9cm				
Minor		24.42%				
LV Ejection Fraction	66%	65 +/- 12%				

LV WALL MOTION: NO RWMA  
ALL CARDIAC CHAMBERS ARE NORMAL  
ALL VALVES ARE NORMAL  
NO CLOT, VEGETATION, PERICARDIAL EFFUSION

FINAL DIAGNOSIS: NORMAL STUDY

Adv: - Follow up/ review at higher center for confirmation

Note:- Please Correlate clinically. Due to technical limitations as well as inaccuracies inherent in the laboratory and statistical analysis of biological process. Diagnostic accuracy of ECHO is up to 95% only.  
Report is not valid for medico-legal purpose.

  
Dr. Mukesh Kumar Gupta  
DR. MUKESH GUPTA  
PHYSICIAN  
RM 5423/16262



"भ्रूण लिंग परीक्षण की शिकायत  
104 टोल फ्री सेवा पर भी की  
जा सकती है"

भ्रूण लिंग परीक्षण की शिकायत 104 टोल फ्री सेवा पर भी की जा सकती है।



# दक्ष हॉस्पिटल

396, गाँधी नगर स्कीम नं.8, अलवर ( राज० ) ☎ 0144-2703340

## Sonography / 2D Echo Cardiography / Doppler Report

Name: MR. AMAN SEVADA /M/27 YRS

Date: 26-Oct-24

BOB HEALTH CHECK UP

### U.S.G. OF ABDOMEN & PELVIS

#### LIVER

Liver is normal in size shape with normal echo-texture. Intra hepatic biliary radicals are not dilated. No evidence of focal or diffuse lesion.

#### GALL BLADDER

Gall bladder is partially distended, visualized Lumen appear clear. Wall thickness normal. CBD normal

#### PANCREAS

Pancreas is normal in size, shape & echo-texture.

#### SPLEEN

Normal in size with normal shape & echo- texture.

#### BOTH KIDNEY

Both kidney normal shape, size & echo texture. CMD maintained

PROSTATE is normal shape, size & echo texture..

URINARY BLADDER is well distended, visualized lumen appear clear. Wall thickness normal.

### Advice- X Ray KUB / URINE EXAM

Please correlate clinically. USG accuracy is 95 % due to technical limitations as well as inaccuracies inherent in the laboratory and statistical analysis biological process.

This report is not valid for medico-legal cases.

  
DR. MUKESH GUPTA  
SONOLOGIST  
Dr. ~~Mukesh~~ Kumar Gupta  
Physician & Sonologist  
RM 5423/16262



"भ्रूण लिंग परीक्षण की शिकायत  
104 टोल फ्री सेवा पर भी की  
जा सकती है।"

भ्रूण लिंग परीक्षण की शिकायत 104 टोल फ्री सेवा पर भी की जा सकती है।


ID: 3

MR. AMAN SAVEDA

Female 27 Years

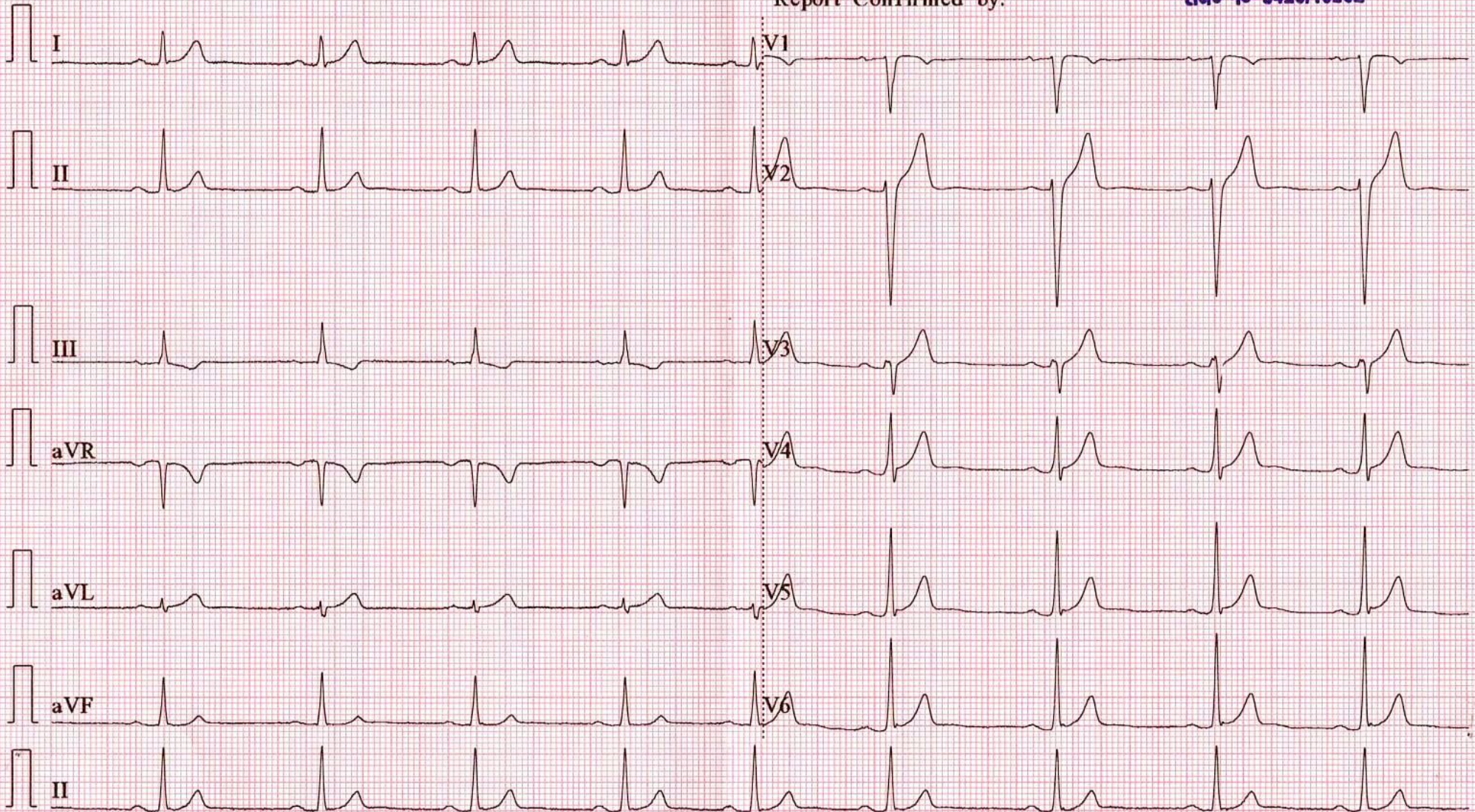
HR : 56 bpm  
 P : 117 ms  
 PR : 194 ms  
 QRS : 92 ms  
 QT/QTc : 365/353 ms  
 P/QRS/T : 39/60/18 °  
 RV5/SV1 : 1.549/0.937 mV

Diagnosis Information:  
 Sinus Bradycardia  
 Poor R Wave Progression(V3)



डॉ० मुकेश गुप्ता  
 M.D.F.C.C.S.  
 फिजिशियन एवं मधुमेह रोग विशेषज्ञ  
 दक्ष हॉस्पिटल, अलवर  
 रजि० नं०-5423/16262

Report Confirmed by:



R

