



# Shree Ram Multispeciality Hospital (SRMH)

Lokah Samasta Sukhino Bhavantu



OPD - ID : 02024 - 2025-0002120  
UH-ID : SRMH-25022086

PT. TYPE : FREE OPD  
PRINT DATE : 22-02-2025 / 09:04:44



6874554

|               |  |              |                          |
|---------------|--|--------------|--------------------------|
| PATIENT NAME  | : MR SOURAV KUMAR BEHERA                     | OPD-DATE     | : 22-Feb-2025 - 09:04 AM |
| AGE / SEX     | : 34-Y 5-M 18-D / MALE                       | DEPARTMENT   | : GENERAL MEDICINE       |
| DOB           | : 07-09-1990                                 | CONSULTANT   | : DR. AJIT KUMAR         |
| MOB-NO        | : 9586847829                                 | COMPANY NAME | : MEDIWHEEL              |
| GUARDIAN NAME | : S/o JAYANT KUMAR BEHERA                    | OPD PAID FEE | : 0.00                   |
| ADDRESS       | : BRHMAPUR SADAR GANJAM ORISSA, RAIPUR, C.G. |              |                          |

Weight : 95.1 kg Height : 5'7 Temp : 97.1 F B.P. : 137/84 Pulse : 65 b/min SPO2 98%

Came for routine health check up  
as reported one strain in neck  
& he had history of snoring.  
Advised for pulmonary exam for  
further evaluation.

*[Signature]*

Near Railway Under Bridge, Basant Vihar Gate No. 1, Gondwara Chowk,  
Gudhiyari, Raipur (Chhattisgarh)

☎ 0771-43 43 161, 0771-43 40 162, 📞 8404 8404 79





# Shree Ram Multispeciality Hospital (SRMH)

Lokah Samasta Sukhino Bhavantu



NAME : MR SOURAV KUMAR BEHERA  
 PHONE NO : 9586847829 TEST NO 1398  
 ORDERED BY : DR. AJIT KUMAR  
 ORDERED BY : SELF

AGE / SEX : 34Y 5M 18D/MALE  
 UH ID NO. : SRMH-25022086  
 COLLECTION : 22-02-2025  
 REPORTING : 22-Feb-2025

## HAEMATOLOGY

| TEST NAME | RESULT | UNIT | NORMAL VALUES |
|-----------|--------|------|---------------|
|-----------|--------|------|---------------|

### BLOOD GROUPING AND RH TYPING


|             |          |  |   |
|-------------|----------|--|---|
| BLOOD GROUP | "A"      |  | - |
| RH FACTOR   | POSITIVE |  | - |

### CBC (COMPLETE BLOOD COUNT)

|                           |      |                 |              |
|---------------------------|------|-----------------|--------------|
| HAEMOGLOBIN (Hb)          | 11.2 | gm%             | 13.5 - 17.5  |
| TOTAL RBC COUNT           | 6.25 | Million/cumm    | 4.5 - 5.9    |
| HAEMATOCRIT (PCV)         | 33.6 | %               | 41.5 - 50.4  |
| <b>RBC INDICES</b>        |      |                 |              |
| MCV                       | 63.5 | fl              | 78 - 96      |
| MCH                       | 17.9 | pg              | 27 - 32      |
| MCHC                      | 28.2 | %               | 33 - 37      |
| RDW                       | 14.1 | %               | 11 - 16      |
| TOTAL WBC COUNT (TLC)     | 8400 | /cumm           | 4000 - 11000 |
| <b>DIFFERENTIAL COUNT</b> |      |                 |              |
| NEUTROPHILS               | 69   | %               | 40 - 70      |
| LYMPHOCYTES               | 26   | %               | 22 - 48      |
| EOSINOPHILS               | 02   | %               | 0 - 6        |
| MONOCYTES                 | 03   | %               | 0 - 8        |
| BASOPHILS                 | 00   | %               | 00 -         |
| PLATELET COUNT            | 2.57 | /cumm           | 1.50 - 4.50  |
| <b>PLATELET INDICES</b>   |      |                 |              |
| PCT                       | 0.25 | %               | 0.10 - 0.28  |
| MPV(MEAN PLATELET VOLUME) | 9.9  | µm <sup>3</sup> | 8 - 11       |
| PDW                       | 15.6 | %               | 11 - 18      |

-- End Of Report --

TECHNICIAN

  
 Dr. Dhananjay Prasad  
 MBBS, MD (Pathologist)

This Report is not for medicolegal purpose

Near Railway Under Bridge, Basant Vihar Gate No. 1, Gondwara Chowk,  
 Gudhiyari, Raipur (Chhattisgarh)

☎ 0771-43 43 161, 0771-43 40 162, 📞 8404 8404 79

✉ shreeramhospital.op@gmail.com 🌐 www.srmhraipur.com



# SHREE RAM MULTISPECIALITY HOSPITAL

Lokah Samasta Sukhino Bhavantu



Near Railway Under Bridge, Basant Vihar Gate No. 1, Gondwara Chowk, Gudhiyari, Raipur (C.G.)  
 Phone: 0771-4343161, 08404840479 Email: Shreeramhospitalop@gmail.com

|                        |                             |         |
|------------------------|-----------------------------|---------|
| MR SOURAV KUMAR BEHERA | AGE / SEX : 34Y 5M 18D/MALE | TEST NO |
| 9586847829             | UH ID NO. : SRMH-25022086   | 1398    |
| DR. AJIT KUMAR         | COLLECTION : 22-02-2025     |         |
| SELF                   | REPORTING : 22-Feb-2025     |         |

## BIOCHEMISTRY

| TEST NAME                        | RESULT | UNIT    | NORMAL VALUES |
|----------------------------------|--------|---------|---------------|
| <b>LIVER FUNCTION TEST (LFT)</b> |        |         |               |
| BILIRUBIN TOTAL                  | 0.62   | mg/dL   | 0.2 - 1       |
| BILIRUBIN DIRECT                 | 0.31   | mg / dl | 0.1 - 0.6     |
| BILIRUBIN INDIRECT               | 0.31   | mg / dl | 0.1 - 0.4     |
| SGOT                             | 35.2   | U / L   | 0 - 46        |
| SGPT                             | 31.3   | U / L   | 0 - 40        |
| ALKALINE PHOSPHATASE             | 189.4  | U / L   | 0 - 240       |
| TOTAL PROTEIN                    | 6.42   | g / dl  | 6 - 8         |
| ALBUMIN                          | 3.84   | g/dl    | 3.5 - 5.0     |
| GLOBULIN                         | 2.58   | g / dl  | 2 - 3.5       |
| A/G RATIO                        | 1.48   |         | 1 - 2.5       |

### Clinical Significance

**Alanine transaminase (ALT)**  
 ALT is an enzyme found in the liver that helps your body metabolize protein. When the liver is damaged, ALT is released into the bloodstream and levels increase.


**Aspartate transaminase (AST)**  
 AST is an enzyme that helps metabolize alanine, an amino acid. Like ALT, AST is normally present in blood at low levels. A rise in AST levels may indicate liver damage or muscle damage.


**Alkaline phosphatase (ALP)**  
 ALP is an enzyme in the liver, bile ducts and bone. Higher-than-normal levels of ALP may indicate liver damage or disease, such as a blocked bile duct, or certain bone diseases.

**Albumin and total protein**  
 Albumin is one of several proteins made in the liver. Your body needs these proteins to fight infections and to perform other functions. Lower-than-normal levels of albumin and total protein might indicate liver damage or disease.

**Bilirubin**  
 Bilirubin is a substance produced during the normal breakdown of red blood cells. Bilirubin passes through the liver and is excreted in stool. Elevated levels of bilirubin (jaundice) might indicate liver damage or disease or certain types of anemia.

-- End Of Report --

  
 TECHNICIAN

  
 Dr. Dhananjay Prasad  
 MBBS, MD (Pathologist)

This Report is not for medicolegal purpose

# SHREE RAM MULTISPECIALITY HOSPITAL

Lokah Samasta Sukhino Bhavantu



Near Railway Under Bridge, Basant Vihar Gate No. 1, Gondwara Chowk, Gudhiyari, Raipur (C.G.)  
 Phone: 0771-4343161, 08404840479 Email: Shreeramhospitalop@gmail.com

MR SOURAV KUMAR BEHERA  
 9586847829  
 DR. AJIT KUMAR  
 SELF

AGE / SEX : 34Y 5M 18D/MALE  
 UH ID NO. : SRMH-25022086  
 COLLECTION : 22-02-2025  
 REPORTING : 22-Feb-2025  
 TEST NO : 1398

## BIOCHEMISTRY

| NAME | RESULT | UNIT | NORMAL VALUES |
|------|--------|------|---------------|
|------|--------|------|---------------|

### LIPID PROFILE

|                         |       |         |           |
|-------------------------|-------|---------|-----------|
| CHOLESTEROL             | 219.4 | mg / dl | 150 - 220 |
| SERUM TRYGLYCERIDE      | 114.5 | mg / dl | 60 - 165  |
| HDL                     | 35.6  | mg / dl | 35 - 80   |
| LDL                     | 183.8 | mg/dL   | 90 - 160  |
| VLDL                    | 22.9  | mg/dL   | 20 - 50   |
| CHOLESTEROL / HDL RATIO | 6.16  | mg/dL   | 3.5 - 5.5 |
| LDL/HDL Ratio           | 5.16  | mg / dl | 2.5 - 3.5 |

## PATHOLOGY

| TEST NAME | RESULT | UNIT | NORMAL VALUES |
|-----------|--------|------|---------------|
|-----------|--------|------|---------------|

### GGT (GAMMA GLUTAMYL TRANSFERASE)

|     |      |       |               |
|-----|------|-------|---------------|
| GGT | 16.2 | U / L | 12.00 - 18.00 |
|-----|------|-------|---------------|

-- End Of Report --

*A*  
 TECHNICIAN

*Dr. Dhananjay Prasad*  
 Dr. Dhananjay Prasad  
 MBBS, MD (Pathologist)

: This Report is not for medicolegal purpose

# SHREE RAM MULTISPECIALITY HOSPITAL

Lokah Samasta Sukhino Bhavantu



Near Railway Under Bridge, Basant Vihar Gate No. 1, Gondwara Chowk, Gudhiyari, Raipur (C.G.)  
Phone: 0771-4343161, 08404840479 Email: Shreeramhospitalop@gmail.com

NAME : MR SOURAV KUMAR BEHERA  
PHONE NO : 9586847829  
REFERRED BY : DR. AJIT KUMAR  
ORDERED BY : SELF

AGE / SEX : 34Y 5M 18D/MALE  
UH ID NO. : SRMH-25022086  
COLLECTION : 22-02-2025  
REPORTING : 22-Feb-2025  
TEST NO : 1398

## BIOCHEMISTRY

| TEST NAME                        | RESULT | UNIT    | NORMAL VALUES |
|----------------------------------|--------|---------|---------------|
| <b>BUN (BLOOD UREA NITROGEN)</b> |        |         |               |
| BUN                              | 14.6   | mg / dl | 7.00 - 20.00  |
| Serum Creatinine                 | 0.81   | mg / dl | 0.55 - 1.20   |
| BUN / Creatinine Ratio           | 18.0   |         | 10.1 - 20.1   |

## UREA AND CREATININE

|                  |      |       |           |
|------------------|------|-------|-----------|
| SERUM CREATININE | 0.81 | mg/dL | 0.6 - 1.2 |
| SERUM URIC ACID  | 4.89 | mg/dL | 3.6 - 7.7 |


## IMMUNOASSAY

| TEST NAME              | RESULT | UNIT  | NORMAL VALUES |
|------------------------|--------|-------|---------------|
| <b>SERUM PSA TOTAL</b> |        |       |               |
| PSA (TOTAL )           | 1.23   | ng/mL | 0 - 4         |

-- End Of Report --

TECHNICIAN

This Report is not for medicolegal purpose

  
Dr. Dhananjay Prasad  
MBBS, MD (Pathologist)

# SHREE RAM MULTISPECIALITY HOSPITAL

L o k a h S a m a s t a S u k h i n o B h a v a n t u

Near Railway Under Bridge, Basant Vihar Gate No. 1, Gondwara Chowk, Gudhiyari, Raipur (C.G.)  
Phone: 0771-4343161, 08404840479 Email: Shreeramhospital.op@gmail.com



|                               |                             |         |
|-------------------------------|-----------------------------|---------|
| NAME : MR SOURAV KUMAR BEHERA | AGE / SEX : 34Y 5M 18D/MALE | TEST NO |
| NO : 9586847829               | UH ID NO. : SRMH-25022086   | 1398    |
| R : DR. AJIT KUMAR            | COLLECTION : 22-02-2025     |         |
| ED BY : SELF                  | REPORTING : 22-Feb-2025     |         |

## HAEMATOLOGY

| TEST NAME | RESULT | UNIT | NORMAL VALUES |
|-----------|--------|------|---------------|
|-----------|--------|------|---------------|

### ESR (ERYTHROCYTE SEDIMENTATION RATE)

|     |    |                  |        |
|-----|----|------------------|--------|
| ESR | 10 | mm at end of 1 h | 0 - 20 |
|-----|----|------------------|--------|

## IMMUNOASSAY


| TEST NAME | RESULT | UNIT | NORMAL VALUES |
|-----------|--------|------|---------------|
|-----------|--------|------|---------------|

### THYROID PROFILE (T3, T4, TSH)

|                       |      |        |              |
|-----------------------|------|--------|--------------|
| T3 (TRIIODOTHYRONINE) | 1.02 | ng/ml  | 0.8 - 2      |
| T4 (THYROXINE)        | 10.4 | ug/dl  | 5.13 - 14.06 |
| TSH                   | 0.94 | uIU/ml | 0.27 - 4.2   |

-- End Of Report --

  
TECHNICIAN

  
Dr. Dhananjay Prasad  
MBBS, MD (Pathologist)

This Report is not for medicolegal purpose

# SHREE RAM MULTISPECIALITY HOSPITAL

Lokah Samasta Sukhino Bhavantu



Near Railway Under Bridge, Basant Vihar Gate No. 1, Gondwara Chowk, Gudhiyari, Raipur (C.G.)  
Phone: 0771-4343161, 08404840479 Email: Shreeramhospitalop@gmail.com

NAME : MR SOURAV KUMAR BEHERA  
BILE NO : 9586847829  
CTOR : DR. AJIT KUMAR  
ERED BY : SELF

AGE / SEX : 34Y 5M 18D/MALE  
UH ID NO. : SRMH-25022086  
COLLECTION : 22-02-2025  
REPORTING : 22-Feb-2025

TEST NO  
1398

## HAEMATOLOGY

| TEST NAME | RESULT | UNIT | NORMAL VALUES |
|-----------|--------|------|---------------|
|-----------|--------|------|---------------|

### ESR (ERYTHROCYTE SEDIMENTATION RATE)

|     |    |                  |        |
|-----|----|------------------|--------|
| ESR | 10 | mm at end of 1 h | 0 - 20 |
|-----|----|------------------|--------|

## IMMUNOASSAY

| TEST NAME | RESULT | UNIT | NORMAL VALUES |
|-----------|--------|------|---------------|
|-----------|--------|------|---------------|

### THYROID PROFILE (T3, T4, TSH)

|                       |      |        |              |
|-----------------------|------|--------|--------------|
| T3 (TRIIODOTHYRONINE) | 1.02 | ng/ml  | 0.8 - 2      |
| T4 (THYROXINE)        | 10.4 | ug/dl  | 5.13 - 14.06 |
| TSH                   | 0.94 | uIU/ml | 0.27 - 4.2   |

-- End Of Report --

TECHNICIAN

This Report is not for medicolegal purpose

Dr. Dhananjay Prasad  
MBBS, MD (Pathologist)

# SHREE RAM MULTISPECIALITY HOSPITAL

Lokah Samasta Sukhino Bhavantu

Near Railway Under Bridge, Basant Vihar Gate No. 1, Gondwara Chowk, Gudhiyari, Raipur (C.G.)  
Phone: 0771-4343161, 08404840479 Email: Shreeramhospital.op@gmail.com



|                               |                             |         |
|-------------------------------|-----------------------------|---------|
| NAME : MR SOURAV KUMAR BEHERA | AGE / SEX : 34Y 5M 18D/MALE | TEST NO |
| LE NO : 9586847829            | UH ID NO. : SRMH-25022086   | 1398    |
| FOR : DR. AJIT KUMAR          | COLLECTION : 22-02-2025     |         |
| ORDERED BY : SELF             | REPORTING : 22-Feb-2025     |         |

## BIOCHEMISTRY

| TEST NAME | RESULT | UNIT | NORMAL VALUES |
|-----------|--------|------|---------------|
|-----------|--------|------|---------------|

### BLOOD SUGAR - FASTING AND PP

|                     |       |       |          |
|---------------------|-------|-------|----------|
| BLOOD SUGAR FASTING | 91.2  | mg/dL | 70 - 110 |
| BLOOD SUGAR PP      | 106.8 | mg/dL | 80 - 140 |

### HbA1c -Glycosylated hemoglobin

|                                  |       |       |  |
|----------------------------------|-------|-------|--|
| HbA1c -Glycosylated hemoglobin   | 4.64  | %     | Normal Range : <6%<br>Good Control : 6-7%<br>fair Control : 7-8%<br>Unsatisfactory Control :<br>8-10%<br>Poor Control : >10% -<br>80 - 120 |
| Estimated average plasma glucose | 87.88 | mg/dl |  |

## CLINICAL PATHOLOGY

| TEST NAME | RESULT | UNIT | NORMAL VALUES |
|-----------|--------|------|---------------|
|-----------|--------|------|---------------|


### URINE SUGAR FASTING AND PP

|                     |        |  |          |
|---------------------|--------|--|----------|
| URINE SUGAR FASTING | Absent |  | Absent - |
| URINE SUGAR PP      | Absent |  | Absent - |

-- End Of Report --

  
TECHNICIAN

Note: This Report is not for medicolegal purpose

  
Dr. Dhananjay Prasad  
MBBS, MD (Pathologist)



# SHREE RAM MULTISPECIALITY HOSPITAL

Lokah Samasta Sukhino Bhavantu

Near Railway Under Bridge, Basant Vihar Gate No. 1, Gondwara Chowk, Gudhiyari, Raipur (C.G.)  
 Phone: 0771-4343161, 08404840479 Email: Shreeramhospital.op@gmail.com



|  |  |                 |
|--|--|-----------------|
| NAME : MR SOURAV KUMAR BEHERA<br>NO : 9586847829<br>R : DR. AJIT KUMAR<br>ED BY : SELF | AGE / SEX : 34Y 5M 18D/MALE<br>UH ID NO. : SRMH-25022086<br>COLLECTION : 22-02-2025<br>REPORTING : 22-Feb-2025 | TEST NO<br>1398 |
|--|--|-----------------|

## CLINICAL PATHOLOGY

| NAME | RESULT | UNIT | NORMAL VALUES |
|------|--------|------|---------------|
|------|--------|------|---------------|

### URINE ROUTINE AND MICROSCOPY

#### PHYSICAL EXAMINATION

|            |             |    |               |
|------------|-------------|----|---------------|
| QUANTITY   | 20          | ml | -             |
| COLOUR     | Pale Yellow |    | Pale Yellow - |
| APPEARANCE | Clear       |    | Clear -       |
| REACTION   | Acitic      |    | Acitic -      |

#### CHEMICAL EXAMINATION


|              |        |  |          |
|--------------|--------|--|----------|
| ALBUMIN      | Absent |  | Absent - |
| SUGAR        | Absent |  | Absent - |
| KETONE       | Absent |  | Absent - |
| BILE SALT    | Absent |  | Absent - |
| BILE PIGMENT | Absent |  | Absent - |

#### MICROSCOPIC EXAMINATION

|                  |     |      |       |
|------------------|-----|------|-------|
| PUS CELLS        | 2-3 | /hpf | 2 - 5 |
| EPITHELIAL CELLS | 1-2 | /hpf | 1 - 5 |
| RBC              | Nil | /hpf | 0 - 3 |
| CAST             | Nil | /lpf | Nil - |
| YEAST            | Nil |      | Nil - |
| CRYSTAL          | Nil | /lpf | Nil - |
| BACTERIA         | Nil |      | Nil - |
| OTHERS           | -   |      | -     |

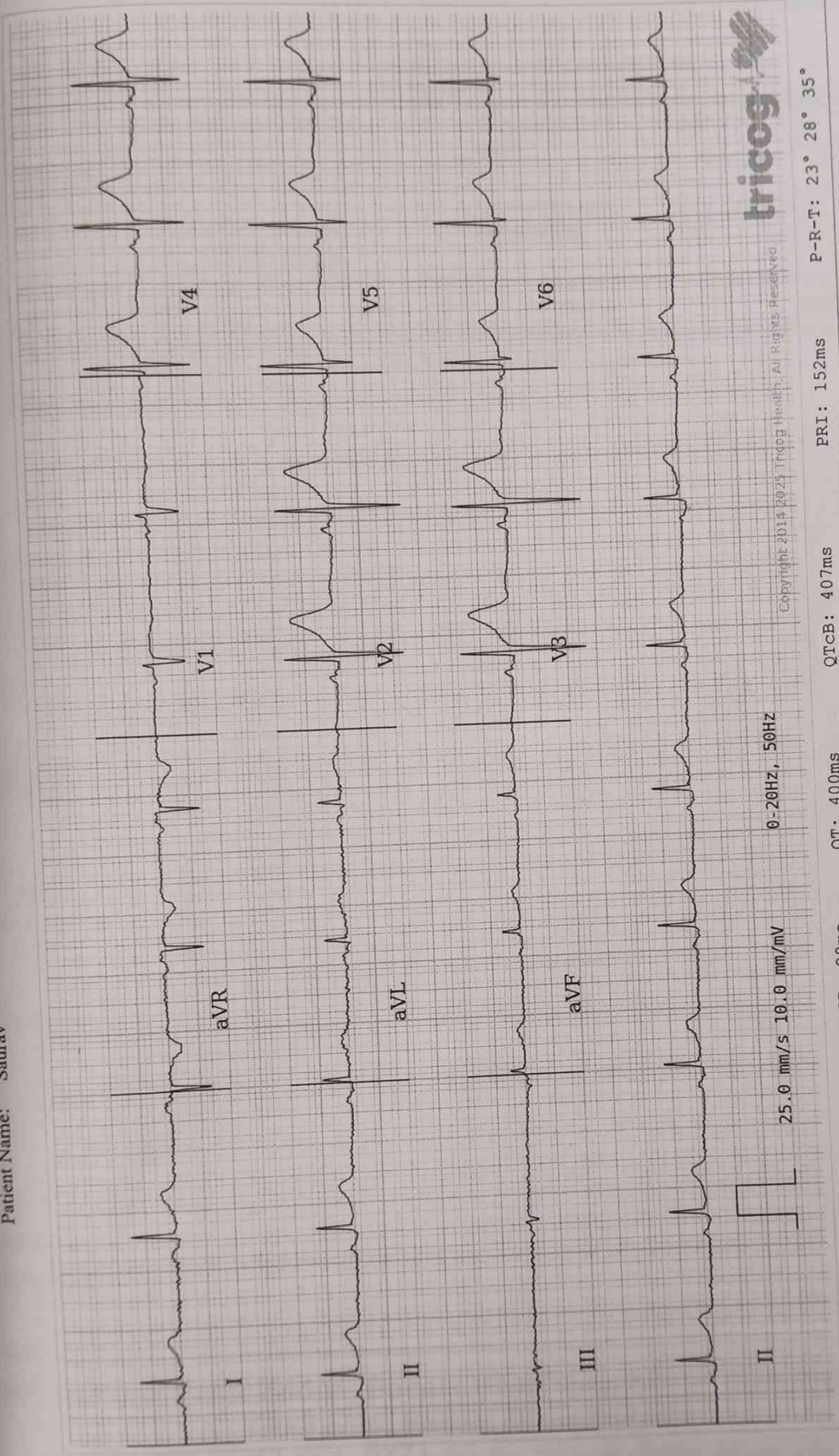
-- End Of Report --

  
 TECHNICIAN

  
 Dr. Dhananjay Prasad  
 MBBS, MD (Pathologist)

This Report is not for medicolegal purpose

Age / Gender: 34/Male  
Patient ID: 1  
Patient Name: Saurav



Copyright © 2014-2023 Tricog Health. All Rights Reserved

P-R-T: 23° 28° 35°

PRI: 152ms

QTcB: 407ms

0-20Hz, 50Hz

QT: 400ms

QRSD: 80ms

VR: 62bpm

AR: 61bpm

Disclaimer: Analysis in this report is based on ECG alone and should only be used as an adjunct to clinical history, symptoms and results of other invasive and non-invasive tests and must be interpreted by a qualified physician.



# Shree Ram Multispeciality Hospital (SRMH)

L o k a h S a m a s t a S u k h i n o B h a v a n t u



D - ID : 02024-2025-0002120  
 -ID : SRMH-25022086  
 PT.TYPE : NEW REGISTRATION  
 PRINTDATE : 22-02-2025/10:00AM  
 TOKENNO. : 1

|              |                                |             |             |
|--------------|--------------------------------|-------------|-------------|
| PATIENTNAME  | : MR. SOURAVKUMAR BEHERA       | DEPARTMENT  | : ENT       |
| AGE/SEX      | : 34 / 5 M 18 D / MALE         | DOB         | :           |
| CONSULT-DATE | : 22/02/2025                   | COMPANYNAME | : MEDIWHEEL |
| PHB-NO       | : 9586847829                   | OPDPAIDFEE  | : 0.00      |
| WARDIANNAME  | : S/O JAYANT KUMAR BEHERA      |             |             |
| ADDRESS      | : BRHMAPUR SADAR GANJAM ORISSA |             |             |

Weight :                      Temp :                      B.P. :                      Pulse :                      SPO2 :

Please indicate whether you are presently suffering from anyone of the following symptoms:

Nose, Mouth, Throat

|                             |   |                                     |
|-----------------------------|---|-------------------------------------|
| Ear pain                    | 0 | <input checked="" type="checkbox"/> |
| Ear itch                    | 0 | <input checked="" type="checkbox"/> |
| Ear drainage                | 0 | <input checked="" type="checkbox"/> |
| Dizziness/ Loss of balance  | 0 | <input checked="" type="checkbox"/> |
| Loss of Hearing             | 0 | <input checked="" type="checkbox"/> |
| Whispering Noise            | 0 | <input checked="" type="checkbox"/> |
| Tinnitus                    | 0 | <input checked="" type="checkbox"/> |
| Ear bleeds                  | 0 | <input checked="" type="checkbox"/> |
| Ear-nasal Drip              | 0 | <input checked="" type="checkbox"/> |
| Ear pain                    | 0 | <input checked="" type="checkbox"/> |
| Ear pressure                | 0 | <input checked="" type="checkbox"/> |
| Nasal congestion            | 0 | <input checked="" type="checkbox"/> |
| Loss of smell/taste         | 0 | <input checked="" type="checkbox"/> |
| Ear redness                 | 0 | <input checked="" type="checkbox"/> |
| Raw Throat                  | 0 | <input checked="" type="checkbox"/> |
| Throat tickle               | 0 | <input checked="" type="checkbox"/> |
| Hoarseness / Mouth / Throat | 0 | <input checked="" type="checkbox"/> |
| Throat clearing             | 0 | <input checked="" type="checkbox"/> |
| Coughing                    | 0 | <input checked="" type="checkbox"/> |

*Primary coming for surgery.*

Present chief complaints:-

Signature

FOLLOW-UP DATE

ADVICE FOR ADMISSION

Near Railway Under Bridge, Basant Vihar Gate No. 1, Gondwara Chowk, Gudhiyari, Raipur (Chhattisgarh)

☎ 0771-43 43 161, 0771-43 40 162, 📞 8404 8404 79

✉ shreeramhospital.op@gmail.com 🌐 www.srmhraipur.com





# Bhawani

## DIAGNOSTIC CENTRE

Near Wallfort Ozone, Fafadih Chowk,  
Raipur (C.G.) Ph.: 0771-4017333

www.bhawanidiagnostic.com

PT. NAME: MR. SOURAV

AGE/SEX: 34 Y/M

REF. DR. BY : SHREE RAM SHANTI HOSPITAL

DATE 22/02/2025

### USG STUDY OF WHOLE ABDOMEN

#### OBSERVATIONS :

**LIVER:-** The liver is normal in size, shape and has smooth margins. It has increased echotexture, has normally distributed and normal size biliary and portal radicals and is without solid or cystic mass lesion or calcification.

**PORTAL VEIN :-** It measures normal in size & is normal in its intra & extra hepatic course . It shows normal variation in size during respiration.

**GALL BLADDER:-** The gall bladder is seen as a well distended, pear shaped bag with uniformly thin and regular walls, without, gall stones or mass lesions.

**COMMON BILE DUCT:-** The common bile duct is normal in caliber. Its measures 2.1 mm at porta hepatis. No evidence of calculus is noted in common bile duct.

**PANCREAS:-** The pancreas is normal in size, shape, contours and echotexture. No evidence of solid or cystic mass lesion is noted.

**KIDNEYS:-** The Right kidney measures: 10.4 X 4.3 cm. Normal in Size, Shape & Echotexture. No Evidence Of Calculi or hydronephrosis seen , Corticomedullary Differentiation Normal.

The Left kidney measures:- 10.0 x 5.1 cm. Normal in Size, Shape & Echotexture. No Evidence Of Calculi or hydronephrosis seen. Corticomedullary Differentiation Normal.

**URINARY BLADDER:-** The urinary bladder is well distended. It shows uniformly thin walls and sharp mucosa. No evidence of calculus is seen. No evidence of mass or diverticulum is noted.

**SPLEEN:** The spleen is normal in size, shape. Its echotexture is homogeneous. No evidence of focal lesion is noted.

**PROSTATE:-** Appear normal in size. Normal in shape and echotexture.

- \* No ASCITES, No pleural effusion.
- \* No ABDOMINAL lymphadenopathy.

**IMPRESSION:-** GRADE I FATTY LIVER.

DR. UJJWALA GOSWAMI  
MD  
RADIOLOGIST & SONOLOGIST



3 Tesla M.R.I.



96 Slice CT Scan



5D Color Doppler Sonography



Digital X-Ray O.P.G./CEPH.



Dexa-Scan/BMD



Mammography




Hi-Tech Pathology



EEG, EMG



Spirometry



E.C.G.

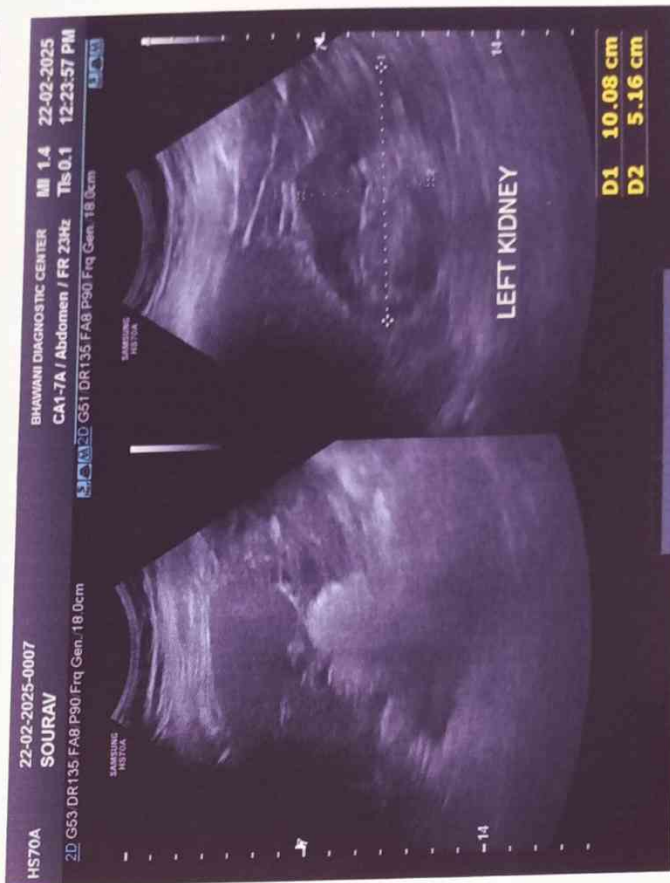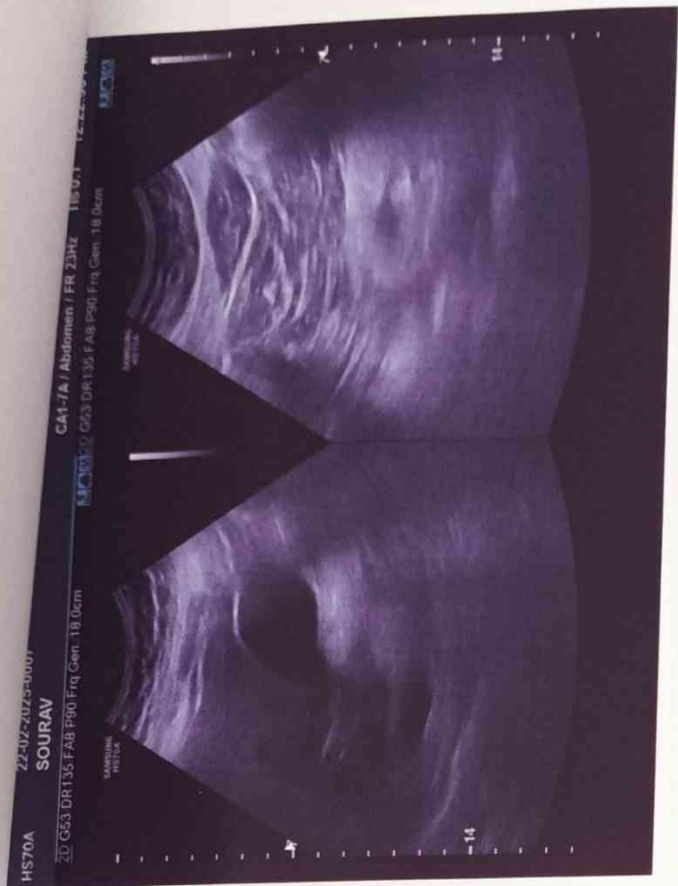

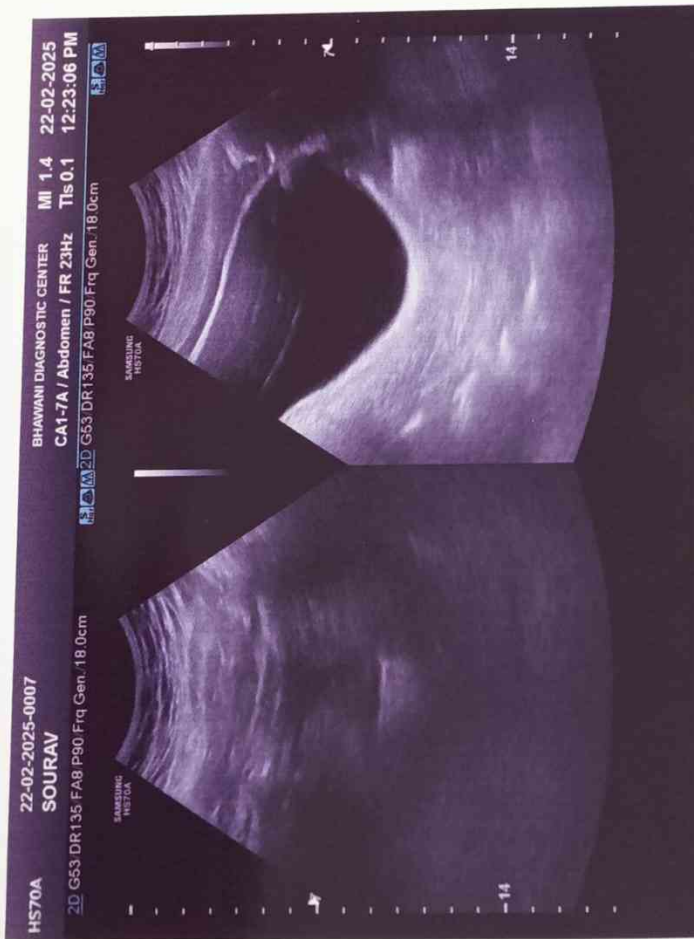
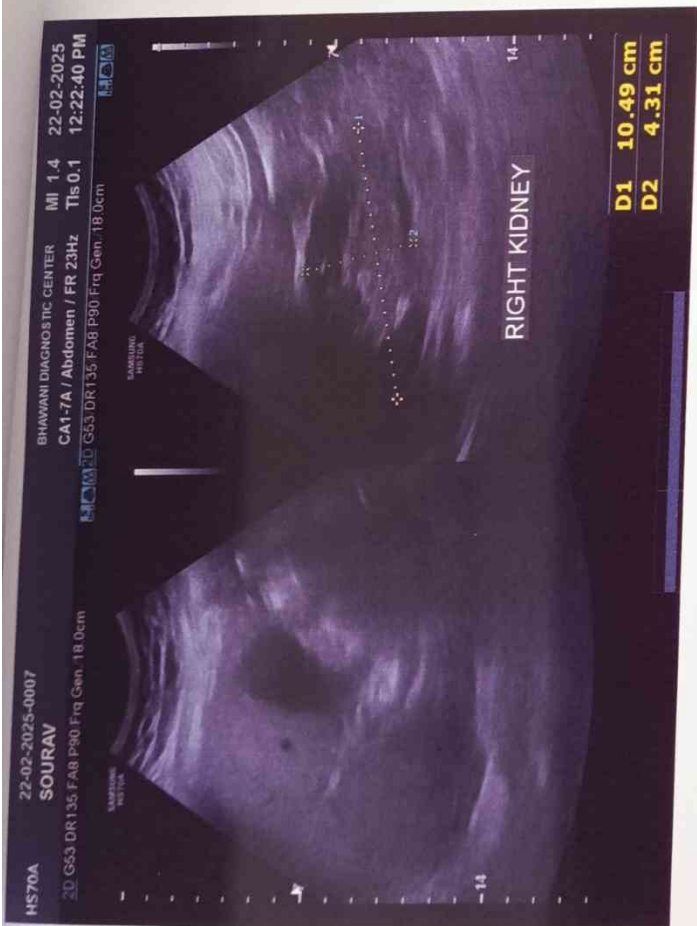HOTRIPSY

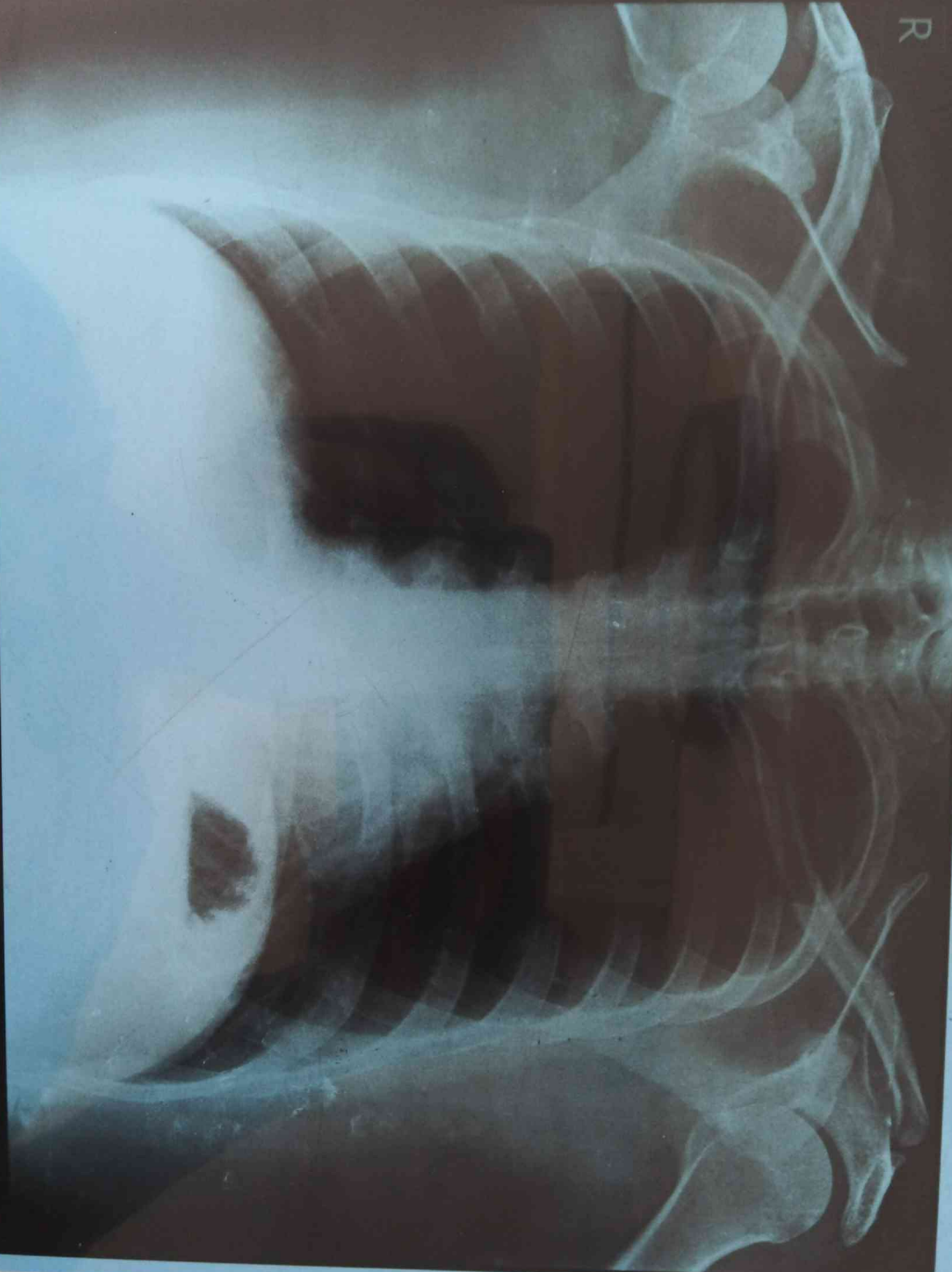


flowmetry

3 Tesla M.R.I. ♦ 96 Slice CT-Scan ♦ 5D Color Doppler Sonography ♦ Dexa Scan/BMD ♦ Digital X-Ray ♦ Hi-Tech Pathology ♦ Mammography ♦ NTA-SCAN ♦ Video E.E.G. E.M.G./VEP/NCV E.C.G./T.M.T. ♦ Spirometry/PFT ♦ Audiometry/Bera ♦ O.P.G./Ceph. ♦ F.N.A.C./ Biospy ♦ Lithotripsy



R



MR. SAURAV KUMAR

REF BY:

SHREE RAM MULTISPECIALITY HOSPITAL, INFRONT GONDWARA UNDERBRIDGE, GUDHIYARI, RAIPUR . PH: 0771-4343161

34 Year(s)

Male

Chest Chest PA

22/02/2025 10:18:59 AM