




भारत सरकार
Government of India

बिरेन्द्र कुमार सिंह
Birendra Kumar Singh
जन्म तारीख/DOB: 31/12/1971
पुरुष/ MALE

Issue Date: 07/10/2015

3373 9092 3052
VID : 9107 1460 5640 0172

[Handwritten Signature]
08/03/2025

आधार
Unique Identification Authority of India

संख्या: 3373 9092 3052

पिता/माता का नाम: उमाशंकर सिंह, S/O: Umashankar Singh.
माधवपुर, चिहताली, सिवान, Madhwapur, Chhitauli, Siwan.
हसनपुरा, बिहार, 841203 Hasanpura, Bihar, 841203

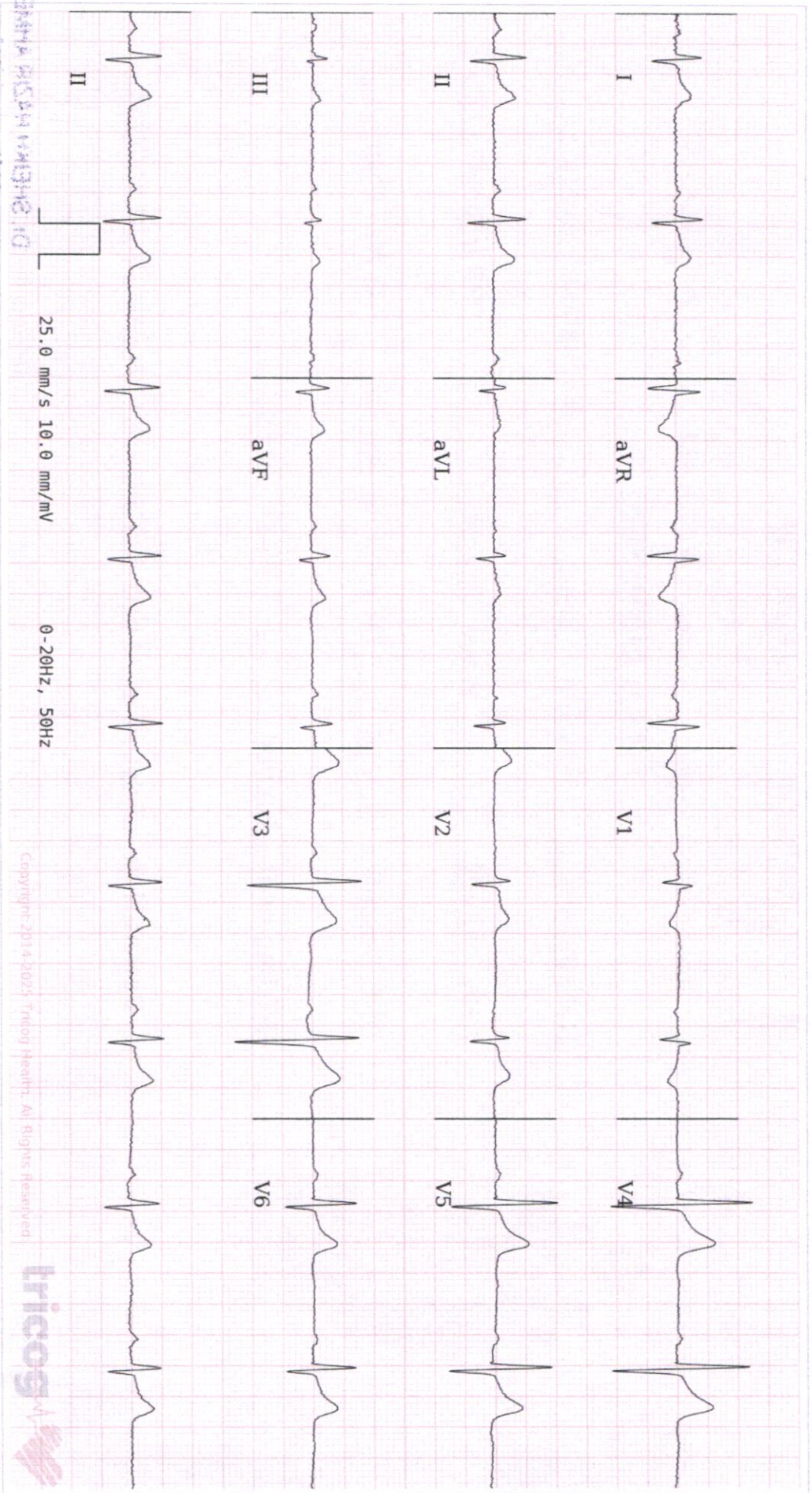
1947
1900 900 4947
help@uidai.gov.in

MALIK RADIX HEALTH CARE PVT. LTD.
C-217, C-218, Nirman Vihar,
Delhi-110092
Ph.: 011-49287456, 011-61381379
Regd. No. 607



Age / Gender: 55/Male
Patient ID: 9687650716

Date and Time: 8th Mar 25 10:39 AM



Malik Radix HealthCare.

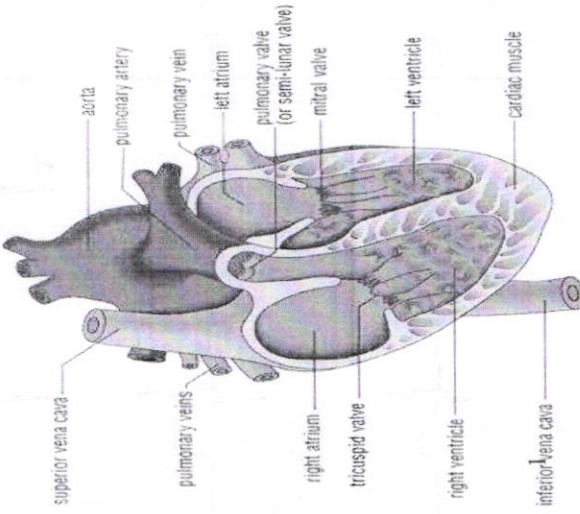
ELECTROCARDIOGRAM

Name: MR. BIRENDRA KUMAR SINGH

Age & Sex: 53 YRS/MALE

Ref by: MEDIWHEEL

DATE: 08/03/2025



ECG FINDINGS:

Rate 56 bpm Rhythm Sinus Mechanism Normal


Axis Normal Wave Normal PR Interval 0.17/Sec

QRS Complex Normal QT Interval Normal Q Wave Normal

ST Segment Normal T Wave Normal

Conclusion Sinus Rhythm (HR- 56 bpm), Normal Axis, To be correlate.

Doctors Signature: 
 HEIKH NAZIR AHMED
 M.D. Physician
 DMC-3499



EYE EXAMINATION (AHC)

| | |
|---------------------------------------|-----------------------------|
| Name: Mr. <u>Birendra Kumar Singh</u> | Age & Gender: <u>53 / M</u> |
| Ref.by: <u>Mediwheel.</u> | Date: <u>08/03/25</u> |

| Without Correction | | With Correction | |
|------------------------------|-----------------|-----------------------------|-----------------|
| Distance - Right <u>6/12</u> | Left <u>6/9</u> | Distance - Right <u>6/6</u> | Left <u>6/6</u> |
| Near - Right <u>N8</u> | Left <u>N8</u> | Near - Right <u>N6</u> | Left <u>N6</u> |

Color Vision: Normal Abnormal

Diagnosis: Refractive Error & Presbyopia

Treatment Recommended: Nil

Dr. Nidhi Gupta
 MBBS, MS, DNB
 Casualty Ophthalmologist
 Malik Radix Healthcare Pvt. Ltd.
 DMC No. 121661

Facilities Available

- Multispeciality Hospital - 24 Hours Emergency - X-Ray/ ECG/ Ultrasound/ CT Scan - Dental- Fully Equipped Operation Theatre
- Fully Functional Lab - 24/7 Casualty/ ICU-Nursery 24/7 Pharmacy - Labour Room - All Speciality OPD - Laproscopic Surgery - ECHO - Plastic Surgery




Echocardiogram Report

| | |
|--------------|--------------------------|
| Patient Name | MR. BIRENDRA KUMAR SINGH |
| Date of Test | 08/03/2025 |
| Age | 54YRS/MALE |
| Ref. by | MEDIWHEEL |

| Dimensions | Result | Normal Range |
|------------|--------|----------------|
| AO (ed) | 3.3 cm | (2.1 -3.7cm) |
| LA (es) | 2.7 cm | (2.1 -3.7cm) |
| RVID (ed) | 2.2 cm | (1.1-3.0cm) |
| LVID (ed) | 3.9 cm | (3.6 – 5.5 cm) |
| LVID (es) | 2.8 cm | (2.3-3.9cm) |
| IVS (ed) | 1.1 cm | (0.6 – 1-2 cm) |
| LVPW (ed) | 1.1 cm | (0.6 – 1-2 cm) |
| EF | 57 % | |
| FS | 29 % | (28 % - 42 %) |

Impression:

- NO REGIONAL WALL MOTION ABNORMALITY SEEN.
- LVEF= 57 %
- NORMAL CHAMBER DIMENSIONS.
- STAGE I LV DIASTOLIC DYSFUNCTION.
- NORMAL COLOR FLOW
- NO INTRA CARDIAC CLOT/MASS/ VEGETATION/PERICARDIAL EFFUSION SEEN.


 Dr. Sheikh Nazir Ahmed
 M.D. "Physician" PGDCC
 (Consultant Non – Invasive Cardiologist)

Facilities Available

- Multispeciality Hospital - 24 Hours Emergency - X-Ray/ ECG/ Ultrasound/ CT Scan - Dental- Fully Equipped Operation Theatre
 - Fully Functional Lab - 24/7 Casualty/ ICU-Nursery 24/7 Pharmacy - Labour Room - All Speciality OPD - Laproscopic Surgery -
 ECHO - Plastic Surgery



CONSULTANTS ON PANEL

PAEDIATRICS

Dr Ravi Malik (MBBS, MD)
Dr Harit Prasad (MBBS, MD, Pfd)
Dr Ritu Jain (MBBS, MD)

GYNAECOLOGY

Dr Renu Malik (MBBS, MD)
Dr Meena Malhotra (MBBS, MD)
Dr Rajni (MBBS, MD)
Dr Manju Gupta (MBBS, MS)
Dr Vaishali Saini (MBBS, DGO)
Dr Rupam Arora (MBBS, MD)

DENTAL

Dr Shruti Malik (BDS, MDS)
Dr Amu Saini (BDS, MDS)
Dr Rachit Thukral (BDS, MDS)
Dr Mohit Mangla (BDS, MDS)
Dr Tarun Mittal (BDS, MDS)
Dr Geetika Sharma (BDS)
Dr Shilpa Verma (BDS)

CHILD GASTROENTEROLOGY

Dr S. K Mittal (MBBS, MD)

MEDICINE

Dr A S Talwar (MBBS, MD)
Dr Sunny Uppal (MBBS, MD)
Dr Surendra Rajpal (MBBS, MD)

RESPIRATORY MEDICINE /PULMONOLOGY

Dr Abhinav Bhanot (MBBS, DNB)

LAPAROSCOPY SURGERY

Dr Ajay Jain (MBBS, MS)
Dr Deepak Saran (MBBS, MS)
Dr Pradeep Saini (MBBS, MS)
Dr G. S Garg (MBBS, MS)

ORTHOPAEDICS

Dr Vikas Bhardwaj (MBBS, MS ORTHO, DNB)
Dr Prabhakar Aggarwal (MBBS, MS ORTHO)
Dr KB Tiwari (MBBS, MS ORTHO)
Dr Deepak Kumar Arora (MBBS, MS ORTHO)

EYE/OPHTHALMOLOGY

Dr Nidhi Gupta (MBBS, MS, DNB, PGDM)
Dr Himanshu Singh Pundir (MBBS, MS)

ENT

Dr Sharad Kumar Singhi (MBBS, MS)
Dr Prateek Sharma (MBBS, MS)
Dr Ashok Singh (MBBS, MS)
Dr A K Lahiri (MBBS, MS)

RADIOLOGY(ULTRASOUND)

Dr K K Sinha (MBBS DNRB)
Dr T K Vohra (MBBS, MD)
Dr Rajesh Malhotra (MBBS, MD)
Dr Ashish Tomar (MBBS, MD)

PATHOLOGY

Dr Reema Dahiya (MBBS, MD PATH)
Dr Meenu Aggarwal (MBBS, MD PATH)

ANAESTHESIA

Dr Rajesh Dhall (MBBS, MD)
Dr Rakesh Atrey (MBBS, MD)
Dr R K Arora (MBBS, MD)
Dr Swaraj Garg (MBBS, MD)

DERMATOLOGY

Dr Niharika Jha (MBBS, MD)

PLASTIC & COSMETIC SURGERY

Dr Ayush Jain (MBBS, MS, MCh)

PAEDIATRIC SURGERY

Dr Dharmendra Singh (MBBS, MS, M.Ch)
Dr Satish Aggarwal (MBBS, MS, M.Ch)

PAEDIATRIC NEPHROLOGY

Dr A S Vasudev (MD, Dip.in. Paed.)

NEPHROLOGY

Dr Javed (MBBS, MD, Nephro)

CARDIOLOGY

Dr Nishant Tyagi (MBBS, MD)

NEUROLOGY

Dr Amit Batra (MBBS, MD)

GASTROENTEROLOGY

Dr Deepak Lahoti (MBBS, MD)
Dr Naresh Aggarwal (MBBS, MD)
Dr Ashok Goyal (MBBS, MD)
Dr Ankur Singhal (MBBS, MD)

UROLOGY

Dr Nikhil Sharma (MBBS, Mch)
Dr Ankur Singhal (MBBS, MD)

PSYCHIATRY

Dr Mohit Sharma (MBBS, MD)

PHYSIOTHERAPY

Dr Kirti Dwivedi
Dr Ravi Kumar

NUTRITIONIST

Dr Deepika Kohli
Dr Sakshi Rana

CLINICAL PSYCHOLOGIST

Dr. Sarika Singh

Dr. Shruti Malik

BDS, MDS (Endodontics)

+91-9899561092

**Timings : 10:00 am. to 2:00 pm.
6:00 pm. to 8:30 pm.**

Name : Birender Kumar

Age/Sex : 53y/M

Date : 8/03/2025

For Appointment

011-45152510

+91-9999254639

CLINICAL EXAMINATION:-

Regular checkup.

1. TMJ:-

M/M? - Ayurvedic medicine

2. DENTAL STATUS:-

- a. Caries Teeth : *0/E? - Calculus ++ Stains ++*
- b. Fracture Teeth : *0/E? - Calculus ++ Stains ++*
- c. Root Stumps :
- d. Gingivitis :
- e. Periodontitis : *- Previous FPD 21/12*
- f. Impacted Teeth :
- g. Malaligned Teeth :

3. ORAL LESIONS:-

Adn - mouthwash - Hexidine

4. DIAGNOSIS:-

x 3 months.

5. TREATMENT PLANNING:

- Scaling and Polishing

6. FOLLOW UP:-

Referral To Other Consultant: Yes/ No

If Yes, please mention the Name:

Doctor's Signature

Safna
8/03/2025

Facilities Available :

- ★ MULTI-SPECIALITY HOSPITAL ★ MODULAR FULLY EQUIPPED OT ★ NURSERY ★ LAPROSCOPIC SURGERY
- ★ 24X7 EMERGENCY ★ OPG ★ DENTAL ★ 24X7 DIAGNOSTICS ★ LABOUR ROOM ★ ECHO ★ EEG ★ DIGITAL X-RAY ★ CT SCAN
- ★ ECG ★ ULTRASOUND ★ RICU/ICU ★ ALL SPECIALITY OPD ★ PLASTIC & COSMETIC SURGERY ★ DIALYSIS ★ PHARMACY



LAB REPORT

| | | | | | |
|-----------|--------------------------|------------|------------|----------|---------------------|
| Reg. Date | 08/03/2025 | Patient Id | 2503080009 | DOB. | |
| Name | MR. BIRENDRA KUMAR SINGH | Gender | M | Perm. ID | |
| Age | 53 Yrs. | Panel | MEDIWHEEL | Reported | 08/03/2025 18:37:39 |
| Ref. By | MEDIWHEEL | | | | |

| Test Name | Result | Units | Ref. Range |
|------------------------|--------|-------|------------|
| ANNUAL PLUS ABOVE 50 M | | | |

HAEMATOLOGY

COMPLETE HAEMOGRAM

| | | | |
|---|-------|--------------|--------------|
| HAEMOGLOBIN (HB%) | 16.6 | gm/dl | 13 - 18 |
| TOTAL LEUCOCYTE COUNT (TLC) | 6,400 | /cumm | 4000 - 11000 |
| DIFFERENTIAL LEUCOCYTE COUNT (DLC) | | | |
| NEUTROPHIL | 58.2 | % | 40 - 80 |
| LYMPHOCYTE | 33.4 | % | 28 - 55 |
| MONOCYTE | 4.5 | % | 02 - 10 |
| EOSINOPHIL | 3.6 | % | 01 - 06 |
| BASOPHIL | 0.3 | % | 0 - 0 |
| ESR (WESTEGREN'S METHOD) | 12 | mm/1st hr. | 0 - 10 |
| R B C COUNT | 5.49 | Millions/cmm | 4.5 - 5.5 |
| P.C.V / HAEMATOCRIT | 51.1 | % | 40 - 54 |
| M C V | 93.1 | fl. | 80 - 100 |
| M C H | 30.2 | Picogram | 27.0 - 31.0 |
| M C H C | 32.5 | gm/dl | 33 - 37 |
| PLATELET COUNT | 1.87 | Lakh/cu mm | 1.50 - 4.50 |

Urine Routine Examination

PHYSICAL EXAMINATION

| | | | |
|------------------|-------|-----|-------------|
| QUANTITY | 30 | ml. | |
| COLOUR | Straw | | Pale Yellow |
| TRANSPARENCY | Clear | | |
| SPECIFIC GRAVITY | 1.010 | | |
| PH | 6.0 | | |

Checked by : _____
Page 1 Contd...2

If test results are alarming or unexpected, patient is advised to contact the laboratory immediately for possible remedial action.

Facilities Available

- Multispeciality Hospital - 24 Hours Emergency - X-Ray/ ECG/ Ultrasound/ CT Scan - Dental- Fully Equipped Operation Theatre
- Fully Functional Lab - 24/7 Casualty/ ICU-Nursery 24/7 Pharmacy - Labour Room - All Speciality OPD - Laproscopic Surgery - ECHO - Plastic Surgery



LAB REPORT

| | | | | | |
|-----------|--------------------------|------------|------------|----------|---------------------|
| Reg. Date | 08/03/2025 | Patient Id | 2503080009 | DOB. | |
| Name | MR. BIRENDRA KUMAR SINGH | Gender | M | Perm. ID | |
| Age | 53 Yrs. | Panel | MEDIWHEEL | Reported | 08/03/2025 18:37:39 |
| Ref. By | MEDIWHEEL | | | | |

| Test Name | Result | Units | Ref. Range |
|--------------------------------|----------|-------|------------|
| CHEMICAL EXAMINATION | | | |
| ALBUMIN | Nil | | |
| SUGAR | Nil | | |
| MICROSCOPIC EXAMINATION | | | |
| PUS CELLS | 1-2 | /HPF | |
| RBC'S | Nil | /HPF | |
| CASTS | Nil | | |
| CRYSTALS | NIL | | |
| EPITHELIAL CELLS | 1-2 | /HPF | |
| BACTERIA | Nil | | |
| OTHERS | Nil | | |
| BLOOD GROUP ABO | " B " | | |
| RH TYPING | Negative | | |
| BLOOD SUGAR FASTING | 117.79 | mg/dl | 70 - 100 |
| BLOOD SUGAR PP | 173.60 | mg/dl | 90 - 140 |
| HB A1C | 6.0 | % | 04 - 5.7 |

Interpretation

| | |
|-----------------------|-------------|
| NON- DIABETIC | :<5.7 % |
| PRE DIABETES | : 5.7- 6.4% |
| DIABETES | : >6.5% |
| GOOD CONTROL DIABETES | : <7 % |

Checked by : _____
 Page 2 Contd...3

If test results are alarming or unexpected, patient is advised to contact the laboratory immediately for possible remedial action.

Facilities Available

- Multispeciality Hospital - 24 Hours Emergency - X-Ray/ ECG/ Ultrasound/ CT Scan - Dental- Fully Equipped Operation Theatre
- Fully Functional Lab - 24/7 Casualty/ ICU-Nursery 24/7 Pharmacy - Labour Room - All Speciality OPD - Laproscopic Surgery - ECHO - Plastic Surgery



LAB REPORT

| | | | | |
|-----------|--------------------------|------------|------------|---------------------|
| Reg. Date | 08/03/2025 | Patient Id | 2503080009 | DOB. |
| Name | MR. BIRENDRA KUMAR SINGH | Gender | M | Perm. ID |
| Age | 53 Yrs. | Panel | MEDIWHEEL | Reported |
| Ref. By | MEDIWHEEL | | | 08/03/2025 18:37:39 |

| Test Name | Result | Units | Ref. Range |
|-----------|--------|-------|------------|
|-----------|--------|-------|------------|

The Glycosylated haemoglobin assay has been validated as a reliable indicator Of mean blood glucose levels for a period of 8-12 week period. ADA recommended the testing twice a year in patients with stable blood glucose and quarterly. If treatment change, or if blood glucose levels are unstable.

TO BE CORRELATED CLINICALLY.

THYROID PROFILE

| | | | |
|-------------------|-------|--------|--------------------|
| Free T3 ELFA | 1.30 | ng/ml | 02 - 04 |
| Free T4 ELFA | 1.71 | ug/dl | 0.8 - 2.7 |
| TSH Serum/ELFA | 3.530 | uIU/ml | 0.25 - 5.50 uIU/ml |

Interpretation

Clinical Use

- Diagnose Hypothyroidism and Hyperthyroidism
- Monitor T4 replacement or T4 suppressive Therapy
- Quantify TSH levels in the subnormal range

Increased Levels : Primary Hypothyroidism Subclinical Hypothyroidism, TSH dependent, Thyroid Hormone Resistance.

Decreased Levels : Grave's Disease, Autonomous Thyroid Hormone Secretion, TSH Deficiency

LIPID PROFILE

| | | | |
|-------------------|--------|-------|-------------------------|
| TOTAL CHOLESTEROL | 224.79 | mg/dL | 130.0 - 200.0 (<200) |
| TRIGLYCERIDES | 191.26 | mg/dL | 80.5 - 150.0 (<150) |

Checked by : _____
Page 3 Contd...4

If test results are alarming or unexpected, patient is advised to contact the laboratory immediately for possible remedial action.

Facilities Available

- Multispeciality Hospital - 24 Hours Emergency - X-Ray/ ECG/ Ultrasound/ CT Scan - Dental- Fully Equipped Operation Theatre
- Fully Functional Lab - 24/7 Casualty/ ICU-Nursery 24/7 Pharmacy - Labour Room - All Speciality OPD - Laproscopic Surgery - ECHO - Plastic Surgery



LAB REPORT

| | | | | | |
|-----------|--------------------------|------------|------------|----------|---------------------|
| Reg. Date | 08/03/2025 | Patient Id | 2503080009 | DOB. | |
| Name | MR. BIRENDRA KUMAR SINGH | Gender | M | Perm. ID | |
| Age | 53 Yrs. | Panel | MEDIWHEEL | Reported | 08/03/2025 18:37:39 |
| Ref. By | MEDIWHEEL | | | | |

| Test Name | Result | Units | Ref. Range |
|---|--------|-------|--------------------------|
| H D L CHOLESTEROL DIRECT | 27.24 | mg/dL | 35.0 - 60.0 (<40->59) |
| V L D L | 38.3 | mg/dL | 4.0 - 30. (23-45) |
| L D L CHOLESTEROL | 159.2 | mg/dL | 50.0 - 150.0 (50-150) |
| TOTAL CHOLESTEROL / HDL RATIO | 8.3 | | 3.3 - 5.1 |
| LDL / HDL CHOLESTEROL RATIO | 5.8 | | 1.5 - 3.5 |
| SERUM URIC ACID | 4.88 | mg/dl | 3.4 - 7.0 |
| BLOOD UREA NITROGEN (BUN) | 9.29 | mg/dl | 6.0 - 21.0 |
| SERUM CREATININE | 0.81 | mg/dl | 0.7 - 1.4 |
| BUN/CREAT RATIO | 11.46 | mg/dl | 10 - 20 |
| <u>LIVER FUNCTION TEST (LFT)</u> | | | |
| BILIRUBIN TOTAL | 1.03 | mg/dl | 0.2 - 1.2 |
| CONJUGATED (D. BILIRUBIN) | 0.27 | mg/dl | 0.00 - 0.3 |
| UNCONJUGATED (I.D. BILIRUBIN) | 0.76 | mg/dl | 0.2 - 0.9 |
| SGOT / AST | 17.10 | IU/L | 0 - 35 |
| SGPT / ALT | 17.0 | IU/L | 0 - 35 |
| ALKALINE PHOSPHATASE | 71.80 | U/L | 64 - 306 |
| TOTAL PROTEIN | 7.50 | gm/dl | 6.0 - 8.3 |
| ALBUMIN | 4.34 | gm/dl | 3.2 - 5.0 |
| GLOBULIN | 3.16 | gm/dl | 2.5 - 5.6 |
| A/G RATIO | 1.37 | | 0.9 - 2.0 |
| GAMMA GT | 19.60 | IU/L | 0.0 - 45.0 |
| TOTAL PSA Chemiluminescence | 0.84 | ng/ml | |

INTERPRETATION :
Expected Values :

Checked by : _____
Page 4 Contd...5

If test results are alarming or unexpected, patient is advised to contact the laboratory immediately for possible remedial action.

Facilities Available

- Multispeciality Hospital - 24 Hours Emergency - X-Ray/ ECG/ Ultrasound/ CT Scan - Dental- Fully Equipped Operation Theatre
- Fully Functional Lab - 24/7 Casualty/ ICU-Nursery 24/7 Pharmacy - Labour Room - All Speciality OPD - Laproscopic Surgery - ECHO - Plastic Surgery



LAB REPORT

| | | | | | |
|-----------|--------------------------|------------|------------|----------|---------------------|
| Reg. Date | 08/03/2025 | Patient Id | 2503080009 | DOB. | |
| Name | MR. BIRENDRA KUMAR SINGH | Gender | M | Perm. ID | |
| Age | 53 Yrs. | Panel | MEDIWHEEL | Reported | 08/03/2025 18:37:39 |
| Ref. By | MEDIWHEEL | | | | |

| | | |
|-----|-----------------------------------|-----------------|
| 99% | : of Healthy males | 0.0-4.0 ng/ml |
| 80% | : of Benign prostatic hypertrophy | 0.0-4.0 ng/ml |
| 81% | : of Prostatic Carcinomas | Above 4.0 ng/ml |

PSA is reliable tumour marker for already diagnosed prostatic carcinomas. It is uniquely associated only with prostatic tissue, and therefore is specific for it. Baseline levels measured prior to therapeutic intervention and followed later by serial periodical measurements will predict the outcome of therapy. It also helps in early discovery of recurrences, relapses and metastases.

Dr. Reema Dahiya
Dr. REEMA DAHIYA
M.B.B.S., MD (Path)
Checked by
Malik Radix Healthcare Pvt. Ltd.
C-217, C-218, Nirman Vihar,
Delhi-110092

DR. MEENU AGGARWAL
M.B.B.S, MD (Path.)

If test results are alarming or unexpected, patient is advised to contact the laboratory immediately for possible remedial action.

Facilities Available

- Multispeciality Hospital - 24 Hours Emergency - X-Ray/ ECG/ Ultrasound/ CT Scan - Dental- Fully Equipped Operation Theatre
- Fully Functional Lab - 24/7 Casualty/ ICU-Nursery 24/7 Pharmacy - Labour Room - All Speciality OPD - Laproscopic Surgery - ECHO - Plastic Surgery

R

IRENDRA KUMAR 59Y/M PT236175 CHEST PA 08 03 2025 10
RADIOX HEALTH CARE C-218 HIGHWAY 101/102 JH 2011196



| | | | |
|-----------|--------------------------|-------------------|----------------------|
| UHID | PT236475 | LAB No. | XRY2423380 |
| Name | Mr. BIRENDRA KUMAR SINGH | Regn. No. | GEN2445976 |
| Age / Sex | 53 Yrs / M | Receiving Dt/Time | 08-Mar-2025 10:12 |
| | | Reporting Dt/Time | 08-Mar-2025 05:13 PM |



XRAY

CHEST (PA)

Both lung fields are normal.

Cp angles are clear.

Hila are normal...

Heart size appears within normal limits.

Soft tissue shadows and bony thorax are normal.

Advised....please correlate clinically.

***** END OF REPORT *****

Approved By :

Approval Date : 00:00:00

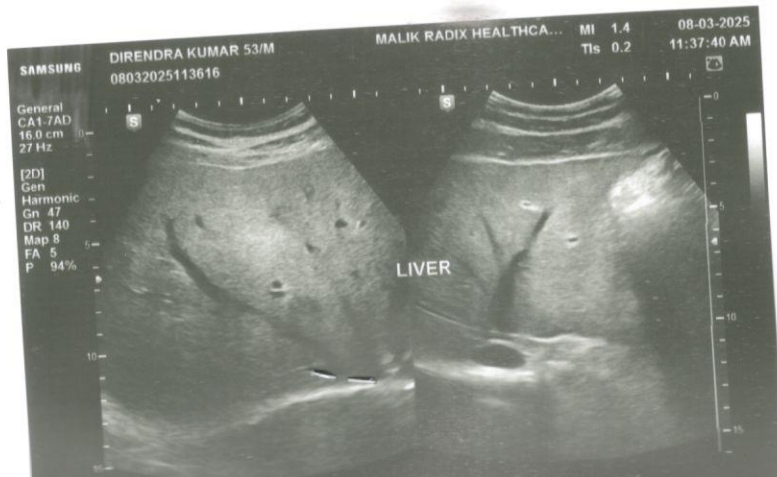
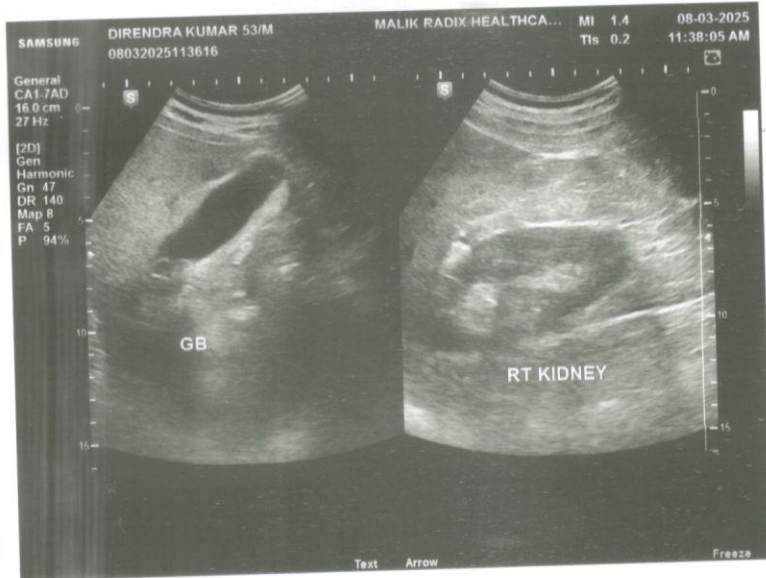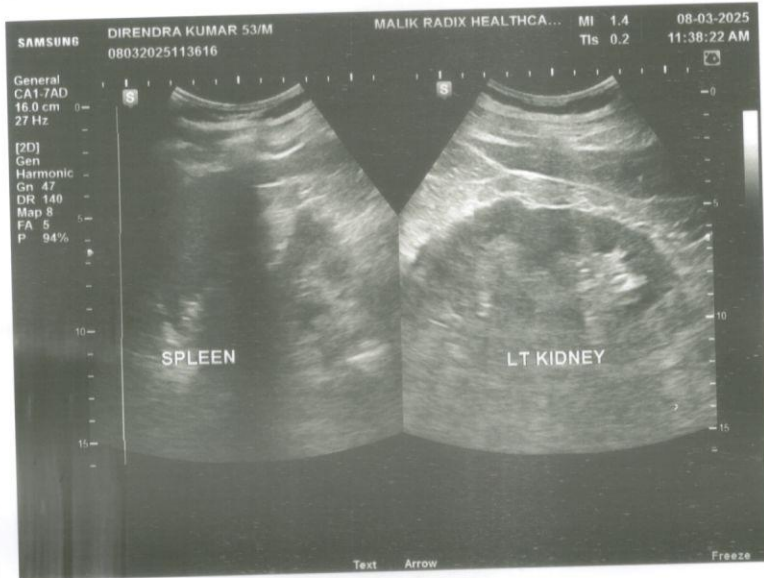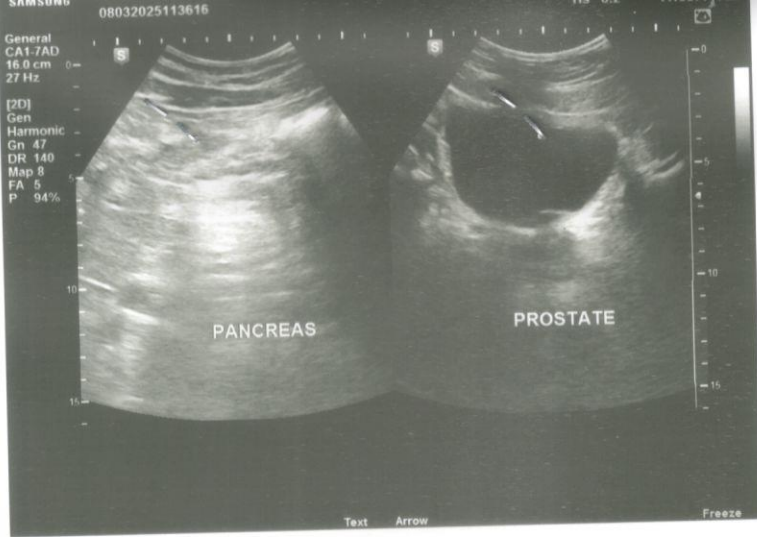
~~DR. K.K. SINHA
M.B.B.S. D.M.R.D.
SENIOR CONSULTANT
Reg. No. 25937 (DMC)~~

DR. T. K VOHRA
MD (RADIOLOGICAL DIAGNOSIS)
SENIOR CONSULTANT
Reg. No. 3272 (DMC)

DR. MUKESH KOSHAL
MBBS, MD (RADIOLOGY)
CONSULTANT RADIOLOGY
Reg.No.DMC10407

Facilities Available

- Multispeciality Hospital - 24 Hours Emergency - X-Ray/ ECG/ Ultrasound/ CT Scan - Dental- Fully Equipped Operation Theatre
- Fully Functional Lab - 24/7 Casualty/ ICU-Nursery 24/7 Pharmacy - Labour Room - All Speciality OPD - Laproscopic Surgery - ECHO - Plastic Surgery



RADIX
HEALTH
care



Malik Radix Healthcare

C/217, C/218, Vikas Marg, Nirman Vihar, New Delhi-110092
A Unit of Malik Radix Healthcare
Toll Free - 1800-120-5457, Tel. : 011 49287456, 61381379
Whatsapp No. - 9811550650
E-mail: radixhealthcare@yahoo.co.in
Website: www.radixhealthcare.org



| | | | |
|-----------|----------------------------|------|----------|
| NAME | MR BIRENDRA KUMAR SINGH | AGE | 53 YRS/M |
| REFD. BY. | HEALTH CHECK UP | DATE | 08.03.25 |

Ultrasound Examination of Whole Abdomen & Pelvis:

Liver: Grade-I fatty liver. No focal SOL is seen in liver. IHBR & portal radicles are normal.

Gallbladder: Gallbladder shows normal anechoic pattern. No evidence of cholecystitis or cholelithiasis seen. Common bile duct is normal in course & caliber.

Pancreas: Pancreas shows normal size & echotexture.

Spleen: Spleen shows normal size, outline & echotexture.

Kidneys: Kidneys show normal size, shape, position & echotexture. No calculus, hydronephrosis or SOL is seen in kidneys. Cortico- medullary differentiation and cortical thickness is normal on both sides.

No supra- renal mass seen.

Great abdominal vessels are normal.

Domes of diaphragm are seen to move normally & synchronously in respiration. No infra- or supradiaphragmatic collection seen.

No ascites or pericardial effusion seen.

No para-aortic lymph nodes seen.

Urinary bladder: Urinary bladder shows normal anechoic pattern. No calculus, SOL or diverticulum seen.

Prostate: Prostate and seminal vesicles are sonographically normal.

IMP:- Grade-I fatty liver.

Regards.

Dr Mukesh Koshal MD (Rad- diag)

Regn. No. DMC 10407

RADIOLOGIST :

Facilities Available

- Multispeciality Hospital - 24 Hours Emergency - X-Ray/ ECG/ Ultrasound/ CT Scan - Dental- Fully Equipped Operation Theatre
- Fully Functional Lab - 24/7 Casualty/ ICU-Nursery 24/7 Pharmacy - Labour Room - All Speciality OPD - Laproscopic Surgery -
ECHO - Plastic Surgery