

Patient Name : Mrs.POLISETTY NIROSHA
Age/Gender : 32 Y 3 M 30 D/F
UHID/MR No : CMYS.0000062543
Visit ID : CMYSOPV131293
Ref Doctor : Self
Emp/Auth/TPA ID : 22S38023

Collected : 09/Nov/2024 08:33AM
Received : 09/Nov/2024 10:10AM
Reported : 09/Nov/2024 11:52AM
Status : Final Report
Sponsor Name : ARCOFEMI HEALTHCARE LIMITED

DEPARTMENT OF HAEMATOLOGY

ARCOFEMI - MEDIWHEEL - FULL BODY HEALTH ANNUAL PLUS CHECK - FEMALE - 2D ECHO - PAN INDIA - FY2324

PERIPHERAL SMEAR , WHOLE BLOOD EDTA



Dr. PAVAN KUMAR M
M.B.B.S,M.D(Pathology)
Consultant Pathologist

SIN No:MYS241100386



Patient Name : Mrs.POLISETTY NIROSHA	Collected : 09/Nov/2024 08:33AM
Age/Gender : 32 Y 3 M 30 D/F	Received : 09/Nov/2024 10:10AM
UHID/MR No : CMYS.0000062543	Reported : 09/Nov/2024 01:14PM
Visit ID : CMYSOPV131293	Status : Final Report
Ref Doctor : Self	Sponsor Name : ARCOFEMI HEALTHCARE LIMITED
Emp/Auth/TPA ID : 22S38023	

DEPARTMENT OF HAEMATOLOGY

ARCOFEMI - MEDIWHEEL - FULL BODY HEALTH ANNUAL PLUS CHECK - FEMALE - 2D ECHO - PAN INDIA - FY2324

Test Name	Result	Unit	Bio. Ref. Interval	Method
HEMOGRAM , WHOLE BLOOD EDTA				
HAEMOGLOBIN	12.5	g/dL	12.5-15	Spectrophotometer
PCV	37.10	%	36-46	Electronic pulse & Calculation
RBC COUNT	4.66	Million/cu.mm	3.8-4.8	Electrical Impedance
MCV	79.6	fL	83-101	Calculated
MCH	26.8	pg	27-32	Calculated
MCHC	33.7	g/dL	31.5-34.5	Calculated
R.D.W	12.4	%	11.6-14	Calculated
TOTAL LEUCOCYTE COUNT (TLC)	5,140	cells/cu.mm	4000-10000	Electrical Impedance
DIFFERENTIAL LEUCOCYTIC COUNT (DLC)				
NEUTROPHILS	51	%	40-80	Electrical Impedance
LYMPHOCYTES	40	%	20-40	Electrical Impedance
EOSINOPHILS	4	%	1-6	Electrical Impedance
MONOCYTES	4	%	2-10	Electrical Impedance
BASOPHILS	1	%	0-2	Electrical Impedance
ABSOLUTE LEUCOCYTE COUNT				
NEUTROPHILS	2621.4	Cells/cu.mm	2000-7000	Calculated
LYMPHOCYTES	2056	Cells/cu.mm	1000-3000	Calculated
EOSINOPHILS	205.6	Cells/cu.mm	20-500	Calculated
MONOCYTES	205.6	Cells/cu.mm	200-1000	Calculated
BASOPHILS	51.4	Cells/cu.mm	0-100	Calculated
Neutrophil lymphocyte ratio (NLR)	1.28		0.78- 3.53	Calculated
PLATELET COUNT	228000	cells/cu.mm	150000-410000	Electrical impedance
ERYTHROCYTE SEDIMENTATION RATE (ESR)	80	mm at the end of 1 hour	0-20	Modified Westergren
PERIPHERAL SMEAR				

R.B.C: Majority are normocytic normochromic.
W.B.C: Are normal in number,morphology and distribution.
Platelets: Adequate and are seen in singles and clumps.
Hemoparasites: Not seen.

Page 2 of 16



Dr. PAVAN KUMAR M
M.B.B.S,M.D(Pathology)
Consultant Pathologist

SIN No:MYS241100386




Patient Name	: Mrs.POLISETTY NIROSHA	Collected	: 09/Nov/2024 08:33AM
Age/Gender	: 32 Y 3 M 30 D/F	Received	: 09/Nov/2024 10:10AM
UHID/MR No	: CMYS.0000062543	Reported	: 09/Nov/2024 01:14PM
Visit ID	: CMYSOPV131293	Status	: Final Report
Ref Doctor	: Self	Sponsor Name	: ARCOFEMI HEALTHCARE LIMITED
Emp/Auth/TPA ID	: 22S38023		

DEPARTMENT OF HAEMATOLOGY

ARCOFEMI - MEDIWHEEL - FULL BODY HEALTH ANNUAL PLUS CHECK - FEMALE - 2D ECHO - PAN INDIA - FY2324

IMPRESSION: NORMOCYTIC NORMOCHROMIC BLOOD PICTURE.



Dr. PAVAN KUMAR M
M.B.B.S,M.D(Pathology)
Consultant Pathologist

SIN No:MYS241100386



Patient Name	: Mrs.POLISETTY NIROSHA	Collected	: 09/Nov/2024 08:33AM
Age/Gender	: 32 Y 3 M 30 D/F	Received	: 09/Nov/2024 10:10AM
UHID/MR No	: CMYS.0000062543	Reported	: 09/Nov/2024 01:14PM
Visit ID	: CMYSOPV131293	Status	: Final Report
Ref Doctor	: Self	Sponsor Name	: ARCOFEMI HEALTHCARE LIMITED
Emp/Auth/TPA ID	: 22S38023		

DEPARTMENT OF HAEMATOLOGY

ARCOFEMI - MEDIWHEEL - FULL BODY HEALTH ANNUAL PLUS CHECK - FEMALE - 2D ECHO - PAN INDIA - FY2324

Test Name	Result	Unit	Bio. Ref. Interval	Method
BLOOD GROUP ABO AND RH FACTOR , WHOLE BLOOD EDTA				
BLOOD GROUP TYPE	AB			Forward & Reverse Grouping with Slide/Tube Aggluti
Rh TYPE	POSITIVE			Forward & Reverse Grouping with Slide/Tube Agglutination



Dr. PAVAN KUMAR M
M.B.B.S,M.D(Pathology)
Consultant Pathologist

SIN No: MYS241100386



Patient Name : Mrs.POLISETTY NIROSHA	Collected : 09/Nov/2024 08:33AM
Age/Gender : 32 Y 3 M 30 D/F	Received : 09/Nov/2024 10:10AM
UHID/MR No : CMYS.0000062543	Reported : 09/Nov/2024 10:51AM
Visit ID : CMYSOPV131293	Status : Final Report
Ref Doctor : Self	Sponsor Name : ARCOFEMI HEALTHCARE LIMITED
Emp/Auth/TPA ID : 22S38023	

DEPARTMENT OF BIOCHEMISTRY

ARCOFEMI - MEDIWHEEL - FULL BODY HEALTH ANNUAL PLUS CHECK - FEMALE - 2D ECHO - PAN INDIA - FY2324

Test Name	Result	Unit	Bio. Ref. Interval	Method
GLUCOSE, FASTING , NAF PLASMA	77	mg/dl	74-106	GOD, POD


Comment:

As per American Diabetes Guidelines, 2023

Fasting Glucose Values in mg/dL	Interpretation
70-100 mg/dL	Normal
100-125 mg/dL	Prediabetes
≥126 mg/dL	Diabetes
<70 mg/dL	Hypoglycemia

Note:

- 1.The diagnosis of Diabetes requires a fasting plasma glucose of > or = 126 mg/dL and/or a random / 2 hr post glucose value of > or = 200 mg/dL on at least 2 occasions.
2. Very high glucose levels (>450 mg/dL in adults) may result in Diabetic Ketoacidosis & is considered critical.



Dr. PAVAN KUMAR M
M.B.B.S,M.D(Pathology)
Consultant Pathologist

SIN No:MYS241100383



Patient Name : Mrs.POLISETTY NIROSHA	Collected : 09/Nov/2024 12:14PM
Age/Gender : 32 Y 3 M 30 D/F	Received : 09/Nov/2024 02:36PM
UHID/MR No : CMYS.0000062543	Reported : 09/Nov/2024 03:04PM
Visit ID : CMYSOPV131293	Status : Final Report
Ref Doctor : Self	Sponsor Name : ARCOFEMI HEALTHCARE LIMITED
Emp/Auth/TPA ID : 22S38023	


DEPARTMENT OF BIOCHEMISTRY

ARCOFEMI - MEDIWHEEL - FULL BODY HEALTH ANNUAL PLUS CHECK - FEMALE - 2D ECHO - PAN INDIA - FY2324

Test Name	Result	Unit	Bio. Ref. Interval	Method
GLUCOSE, POST PRANDIAL (PP), 2 HOURS , SODIUM FLUORIDE PLASMA (2 HR)	84	mg/dl	70-140	GOD, POD

Comment:

It is recommended that FBS and PPBS should be interpreted with respect to their Biological reference ranges and not with each other.
Conditions which may lead to lower postprandial glucose levels as compared to fasting glucose levels may be due to reactive hypoglycemia, dietary meal content, duration or timing of sampling after food digestion and absorption, medications such as insulin preparations, sulfonylureas, amylin analogues, or conditions such as overproduction of insulin.



Dr. PAVAN KUMAR M
M.B.B.S,M.D(Pathology)
Consultant Pathologist

SIN No:MYS241100500



Patient Name : Mrs.POLISETTY NIROSHA	Collected : 09/Nov/2024 08:33AM
Age/Gender : 32 Y 3 M 30 D/F	Received : 09/Nov/2024 12:41PM
UHID/MR No : CMYS.0000062543	Reported : 09/Nov/2024 12:43PM
Visit ID : CMYSOPV131293	Status : Final Report
Ref Doctor : Self	Sponsor Name : ARCOFEMI HEALTHCARE LIMITED
Emp/Auth/TPA ID : 22S38023	

DEPARTMENT OF BIOCHEMISTRY

ARCOFEMI - MEDIWHEEL - FULL BODY HEALTH ANNUAL PLUS CHECK - FEMALE - 2D ECHO - PAN INDIA - FY2324

Test Name	Result	Unit	Bio. Ref. Interval	Method
HBA1C (GLYCATED HEMOGLOBIN) , WHOLE BLOOD EDTA				
HBA1C, GLYCATED HEMOGLOBIN	5.0	%		HPLC
ESTIMATED AVERAGE GLUCOSE (eAG)	97	mg/dL		Calculated

Comment:

Reference Range as per American Diabetes Association (ADA) 2023 Guidelines:

REFERENCE GROUP	HBA1C %
NON DIABETIC	<5.7
PREDIABETES	5.7 – 6.4
DIABETES	≥ 6.5
DIABETICS	
EXCELLENT CONTROL	6 – 7
FAIR TO GOOD CONTROL	7 – 8
UNSATISFACTORY CONTROL	8 – 10
POOR CONTROL	>10

Note: Dietary preparation or fasting is not required.

1. HbA1c is recommended by American Diabetes Association for Diagnosing Diabetes and monitoring Glycemic Control by American Diabetes Association guidelines 2023.

2. Trends in HbA1c values is a better indicator of Glycemic control than a single test.

3. Low HbA1c in Non-Diabetic patients are associated with Anemia (Iron Deficiency/Hemolytic), Liver Disorders, Chronic Kidney Disease. Clinical Correlation is advised in interpretation of low Values.

4. Falsely low HbA1c (below 4%) may be observed in patients with clinical conditions that shorten erythrocyte life span or decrease mean erythrocyte age. HbA1c may not accurately reflect glycemic control when clinical conditions that affect erythrocyte survival are present.

5. In cases of Interference of Hemoglobin variants in HbA1c, alternative methods (Fructosamine) estimation is recommended for Glycemic Control

A: HbF >25%

B: Homozygous Hemoglobinopathy.

(Hb Electrophoresis is recommended method for detection of Hemoglobinopathy)



Dr. PAVAN KUMAR M
M.B.B.S,M.D(Pathology)
Consultant Pathologist

SIN No:MYS241100387



Patient Name : Mrs.POLISETTY NIROSHA	Collected : 09/Nov/2024 08:33AM
Age/Gender : 32 Y 3 M 30 D/F	Received : 09/Nov/2024 10:10AM
UHID/MR No : CMYS.0000062543	Reported : 09/Nov/2024 01:05PM
Visit ID : CMYSOPV131293	Status : Final Report
Ref Doctor : Self	Sponsor Name : ARCOFEMI HEALTHCARE LIMITED
Emp/Auth/TPA ID : 22S38023	

DEPARTMENT OF BIOCHEMISTRY

ARCOFEMI - MEDIWHEEL - FULL BODY HEALTH ANNUAL PLUS CHECK - FEMALE - 2D ECHO - PAN INDIA - FY2324

Test Name	Result	Unit	Bio. Ref. Interval	Method
LIPID PROFILE , SERUM				
TOTAL CHOLESTEROL	180	mg/dl	0-200	CHOD
TRIGLYCERIDES	67	mg/dl	0-150	GPO, Trinder
HDL CHOLESTEROL	54	mg/dL	40-60	CHOD
NON-HDL CHOLESTEROL	126	mg/dL	<130	Calculated
LDL CHOLESTEROL	112.15	mg/dL	<100	Calculated
VLDL CHOLESTEROL	13.44	mg/dL	<30	Calculated
CHOL / HDL RATIO	3.31		0-4.97	Calculated
ATHEROGENIC INDEX (AIP)	0.10		<0.11	Calculated

Comment:

Reference Interval as per National Cholesterol Education Program (NCEP) Adult Treatment Panel III Report.

	Desirable	Borderline High	High	Very High
TOTAL CHOLESTEROL	< 200	200 - 239	≥ 240	
TRIGLYCERIDES	<150	150 - 199	200 - 499	≥ 500
LDL	Optimal < 100 Near Optimal 100-129	130 - 159	160 - 189	≥ 190
HDL	≥ 60			
NON-HDL CHOLESTEROL	Optimal <130; Above Optimal 130-159	160-189	190-219	>220



Dr. PAVAN KUMAR M
M.B.B.S,M.D(Pathology)
Consultant Pathologist

SIN No:MYS241100385



Patient Name	: Mrs.POLISETTY NIROSHA	Collected	: 09/Nov/2024 08:33AM
Age/Gender	: 32 Y 3 M 30 D/F	Received	: 09/Nov/2024 10:10AM
UHID/MR No	: CMYS.0000062543	Reported	: 09/Nov/2024 12:58PM
Visit ID	: CMYSOPV131293	Status	: Final Report
Ref Doctor	: Self	Sponsor Name	: ARCOFEMI HEALTHCARE LIMITED
Emp/Auth/TPA ID	: 22S38023		

DEPARTMENT OF BIOCHEMISTRY

ARCOFEMI - MEDIWHEEL - FULL BODY HEALTH ANNUAL PLUS CHECK - FEMALE - 2D ECHO - PAN INDIA - FY2324

Test Name	Result	Unit	Bio. Ref. Interval	Method
LIVER FUNCTION TEST (LFT) , SERUM				
BILIRUBIN, TOTAL	0.62	mg/dl	0-1.2	NBD
BILIRUBIN CONJUGATED (DIRECT)	0.18	mg/dl	0-0.2	Diazotized sulfanilic acid
BILIRUBIN (INDIRECT)	0.44	mg/dL	0.0-1.1	Dual Wavelength
ALANINE AMINOTRANSFERASE (ALT/SGPT)	13	U/l	0-45	IFCC
ASPARTATE AMINOTRANSFERASE (AST/SGOT)	15.0	U/l	0-31	IFCC
AST (SGOT) / ALT (SGPT) RATIO (DE RITIS)	1.2		<1.15	Calculated
ALKALINE PHOSPHATASE	69.00	U/l	42-98	IFCC (AMP buffer)
PROTEIN, TOTAL	7.50	g/dl	6.4-8.3	Biuret
ALBUMIN	4.30	g/dl	3.5-5.2	Bromcresol Green
GLOBULIN	3.20	g/dL	2.0-3.5	Calculated
A/G RATIO	1.34		0.9-2.0	Calculated

Comment:

LFT results reflect different aspects of the health of the liver, i.e., hepatocyte integrity (AST & ALT), synthesis and secretion of bile (Bilirubin, ALP), cholestasis (ALP, GGT), protein synthesis (Albumin) Common patterns seen:

1. Hepatocellular Injury:

*AST – Elevated levels can be seen. However, it is not specific to liver and can be raised in cardiac and skeletal injuries.*ALT – Elevated levels indicate hepatocellular damage. It is considered to be most specific lab test for hepatocellular injury. Values also correlate well with increasing BMI. Disproportionate increase in AST, ALT compared with ALP. AST: ALT (ratio) – In case of hepatocellular injury AST: ALT > 1 In Alcoholic Liver Disease AST: ALT usually >2. This ratio is also seen to be increased in NAFLD, Wilsons’s diseases, Cirrhosis, but the increase is usually not >2.

2. Cholestatic Patten:*ALP – Disproportionate increase in ALP compared with AST, ALT. ALP elevation also seen in pregnancy, impacted by age and sex.*Bilirubin elevated- predominantly direct , To establish the hepatic origin correlation with elevated GGT helps.

3. Synthetic function impairment:*Albumin- Liver disease reduces albumin levels, Correlation with PT (Prothrombin Time) helps.

4. Associated tests for assessment of liver fibrosis - Fibrosis-4 and APRI Index.



Dr. PAVAN KUMAR M
M.B.B.S,M.D(Pathology)
Consultant Pathologist

SIN No:MYS241100385




Patient Name	: Mrs.POLISETTY NIROSHA	Collected	: 09/Nov/2024 08:33AM
Age/Gender	: 32 Y 3 M 30 D/F	Received	: 09/Nov/2024 10:10AM
UHID/MR No	: CMYS.0000062543	Reported	: 09/Nov/2024 01:21PM
Visit ID	: CMYSOPV131293	Status	: Final Report
Ref Doctor	: Self	Sponsor Name	: ARCOFEMI HEALTHCARE LIMITED
Emp/Auth/TPA ID	: 22S38023		

DEPARTMENT OF BIOCHEMISTRY

ARCOFEMI - MEDIWHEEL - FULL BODY HEALTH ANNUAL PLUS CHECK - FEMALE - 2D ECHO - PAN INDIA - FY2324

Test Name	Result	Unit	Bio. Ref. Interval	Method
RENAL PROFILE/KIDNEY FUNCTION TEST (RFT/KFT) , SERUM				
CREATININE	0.57	mg/dL	0.51-1.04	Enzymatic colorimetric
UREA	18.51	mg/dl	13-43	Urease, UV
BLOOD UREA NITROGEN	8.6	mg/dL	8.0 - 23.0	Calculated
URIC ACID	5.60	mg/dL	2.6-6	Uricase
CALCIUM	9.40	mg/dl	8.6-10.3	Arsenazo III
PHOSPHORUS, INORGANIC	3.95	mg/dl	2.7-4.5	Molybdate
SODIUM	139	mmol/L	135-145	Direct ISE
POTASSIUM	4.2	mmol/L	3.5-5.1	Direct ISE
CHLORIDE	104	mmol/L	98 - 107	Direct ISE
PROTEIN, TOTAL	7.50	g/dl	6.4-8.3	Biuret
ALBUMIN	4.30	g/dl	3.5-5.2	Bromcresol Green
GLOBULIN	3.20	g/dL	2.0-3.5	Calculated
A/G RATIO	1.34		0.9-2.0	Calculated



Dr. PAVAN KUMAR M
M.B.B.S,M.D(Pathology)
Consultant Pathologist

SIN No:MYS241100385




Patient Name : Mrs.POLISETTY NIROSHA	Collected : 09/Nov/2024 08:33AM
Age/Gender : 32 Y 3 M 30 D/F	Received : 09/Nov/2024 10:10AM
UHID/MR No : CMYS.0000062543	Reported : 09/Nov/2024 12:58PM
Visit ID : CMYSOPV131293	Status : Final Report
Ref Doctor : Self	Sponsor Name : ARCOFEMI HEALTHCARE LIMITED
Emp/Auth/TPA ID : 22S38023	

DEPARTMENT OF BIOCHEMISTRY

ARCOFEMI - MEDIWHEEL - FULL BODY HEALTH ANNUAL PLUS CHECK - FEMALE - 2D ECHO - PAN INDIA - FY2324

Test Name	Result	Unit	Bio. Ref. Interval	Method
GAMMA GLUTAMYL TRANSPEPTIDASE (GGT) , SERUM	18.00	U/l	0-38	IFCC



Dr. PAVAN KUMAR M
M.B.B.S,M.D(Pathology)
Consultant Pathologist

SIN No:MYS241100385



Patient Name : Mrs.POLISETTY NIROSHA	Collected : 09/Nov/2024 08:33AM
Age/Gender : 32 Y 3 M 30 D/F	Received : 09/Nov/2024 10:10AM
UHID/MR No : CMYS.0000062543	Reported : 09/Nov/2024 11:41AM
Visit ID : CMYSOPV131293	Status : Final Report
Ref Doctor : Self	Sponsor Name : ARCOFEMI HEALTHCARE LIMITED
Emp/Auth/TPA ID : 22S38023	

DEPARTMENT OF IMMUNOLOGY

ARCOFEMI - MEDIWHEEL - FULL BODY HEALTH ANNUAL PLUS CHECK - FEMALE - 2D ECHO - PAN INDIA - FY2324

Test Name	Result	Unit	Bio. Ref. Interval	Method
THYROID PROFILE TOTAL (T3, T4, TSH) , SERUM				
TRI-iodothyronine (T3, TOTAL)	0.86	ng/mL	0.87-1.78	CLIA
THYROXINE (T4, TOTAL)	12.06	µg/dL	6.09-12.23	CLIA
THYROID STIMULATING HORMONE (TSH)	3.200	µIU/mL	0.38-5.33	CLIA

Comment:

For pregnant females	Bio Ref Range for TSH in uIU/ml (As per American Thyroid Association)
First trimester	0.1 - 2.5
Second trimester	0.2 – 3.0
Third trimester	0.3 – 3.0

- TSH is a glycoprotein hormone secreted by the anterior pituitary. TSH activates production of T3 (Triiodothyronine) and its prohormone T4 (Thyroxine). Increased blood level of T3 and T4 inhibit production of TSH.
- TSH is elevated in primary hypothyroidism and will be low in primary hyperthyroidism. Elevated or low TSH in the context of normal free thyroxine is often referred to as sub-clinical hypo- or hyperthyroidism respectively.
- Both T4 & T3 provides limited clinical information as both are highly bound to proteins in circulation and reflects mostly inactive hormone. Only a very small fraction of circulating hormone is free and biologically active.
- Significant variations in TSH can occur with circadian rhythm, hormonal status, stress, sleep deprivation, medication & circulating antibodies.

TSH	T3	T4	FT4	Conditions
High	Low	Low	Low	Primary Hypothyroidism, Post Thyroidectomy, Chronic Autoimmune Thyroiditis
High	N	N	N	Subclinical Hypothyroidism, Autoimmune Thyroiditis, Insufficient Hormone Replacement Therapy.
N/Low	Low	Low	Low	Secondary and Tertiary Hypothyroidism
Low	High	High	High	Primary Hyperthyroidism, Goitre, Thyroiditis, Drug effects, Early Pregnancy
Low	N	N	N	Subclinical Hyperthyroidism
Low	Low	Low	Low	Central Hypothyroidism, Treatment with Hyperthyroidism
Low	N	High	High	Thyroiditis, Interfering Antibodies
N/Low	High	N	N	T3 Thyrotoxicosis, Non thyroidal causes

Page 12 of 16



Dr. PAVAN KUMAR M
M.B.B.S, M.D (Pathology)
Consultant Pathologist

SIN No: MYS241100384



Patient Name	: Mrs.POLISETTY NIROSHA	Collected	: 09/Nov/2024 08:33AM
Age/Gender	: 32 Y 3 M 30 D/F	Received	: 09/Nov/2024 10:10AM
UHID/MR No	: CMYS.0000062543	Reported	: 09/Nov/2024 11:41AM
Visit ID	: CMYSOPV131293	Status	: Final Report
Ref Doctor	: Self	Sponsor Name	: ARCOFEMI HEALTHCARE LIMITED
Emp/Auth/TPA ID	: 22S38023		

DEPARTMENT OF IMMUNOLOGY

ARCOFEMI - MEDIWHEEL - FULL BODY HEALTH ANNUAL PLUS CHECK - FEMALE - 2D ECHO - PAN INDIA - FY2324

High	High	High	High	Pituitary Adenoma; TSHoma/Thyrotropinoma
------	------	------	------	--



Dr. PAVAN KUMAR M
M.B.B.S,M.D(Pathology)
Consultant Pathologist

SIN No: MYS241100384



Patient Name : Mrs.POLISETTY NIROSHA	Collected : 09/Nov/2024 08:33AM
Age/Gender : 32 Y 3 M 30 D/F	Received : 09/Nov/2024 11:12AM
UHID/MR No : CMYS.0000062543	Reported : 09/Nov/2024 12:30PM
Visit ID : CMYSOPV131293	Status : Final Report
Ref Doctor : Self	Sponsor Name : ARCOFEMI HEALTHCARE LIMITED
Emp/Auth/TPA ID : 22S38023	

DEPARTMENT OF CLINICAL PATHOLOGY

ARCOFEMI - MEDIWHEEL - FULL BODY HEALTH ANNUAL PLUS CHECK - FEMALE - 2D ECHO - PAN INDIA - FY2324

Test Name	Result	Unit	Bio. Ref. Interval	Method
COMPLETE URINE EXAMINATION (CUE) , URINE				
PHYSICAL EXAMINATION				
COLOUR	PALE YELLOW		PALE YELLOW	Visual
TRANSPARENCY	CLEAR		CLEAR	Physical Measurement
pH	5.5		5-7.5	Double Indicator
SP. GRAVITY	1.025		1.002-1.030	Bromothymol Blue
BIOCHEMICAL EXAMINATION				
URINE PROTEIN	NEGATIVE		NEGATIVE	Protein Error Of Indicator
GLUCOSE	NEGATIVE		NEGATIVE	Glucose Oxidase
URINE BILIRUBIN	NEGATIVE		NEGATIVE	Azo Coupling Reaction
URINE KETONES (RANDOM)	NEGATIVE		NEGATIVE	Sodium Nitro Prusside
UROBILINOGEN	NORMAL		NORMAL	Modified Ehrlich Reaction
NITRITE	NEGATIVE		NEGATIVE	Diazotization
LEUCOCYTE ESTERASE	NEGATIVE		NEGATIVE	Leucocyte Esterase
CENTRIFUGED SEDIMENT WET MOUNT AND MICROSCOPY				
PUS CELLS	2 - 3	/hpf	0-5	Microscopy
EPITHELIAL CELLS	5 - 7	/hpf	<10	Microscopy
RBC	NIL	/hpf	0-2	Microscopy
CASTS	NIL		0-2 Hyaline Cast	Microscopy
CRYSTALS	ABSENT		ABSENT	Microscopy

Comment:

All urine samples are checked for adequacy and suitability before examination. All abnormal chemical examination are rechecked and verified by manual methods. Microscopy findings are reported as an average of 10 high power fields.



Dr. PAVAN KUMAR M
M.B.B.S,M.D(Pathology)
Consultant Pathologist

SIN No:MYS241100381




Patient Name	: Mrs.POLISETTY NIROSHA	Collected	: 09/Nov/2024 08:33AM
Age/Gender	: 32 Y 3 M 30 D/F	Received	: 09/Nov/2024 11:12AM
UHID/MR No	: CMYS.0000062543	Reported	: 09/Nov/2024 11:54AM
Visit ID	: CMYSOPV131293	Status	: Final Report
Ref Doctor	: Self	Sponsor Name	: ARCOFEMI HEALTHCARE LIMITED
Emp/Auth/TPA ID	: 22S38023		

DEPARTMENT OF CLINICAL PATHOLOGY

ARCOFEMI - MEDIWHEEL - FULL BODY HEALTH ANNUAL PLUS CHECK - FEMALE - 2D ECHO - PAN INDIA - FY2324

Test Name	Result	Unit	Bio. Ref. Interval	Method
URINE GLUCOSE(POST PRANDIAL)	NEGATIVE		NEGATIVE	GOD-POD

Test Name	Result	Unit	Bio. Ref. Interval	Method
URINE GLUCOSE(FASTING)	NEGATIVE		NEGATIVE	GOD-POD



Dr. PAVAN KUMAR M
M.B.B.S,M.D(Pathology)
Consultant Pathologist

SIN No:MYS241100382



Patient Name : Mrs.POLISETTY NIROSHA	Collected : 09/Nov/2024 12:29PM
Age/Gender : 32 Y 3 M 30 D/F	Received : 10/Nov/2024 02:17PM
UHID/MR No : CMYS.0000062543	Reported : 11/Nov/2024 06:55PM
Visit ID : CMYSOPV131293	Status : Final Report
Ref Doctor : Self	Sponsor Name : ARCOFEMI HEALTHCARE LIMITED
Emp/Auth/TPA ID : 22S38023	

DEPARTMENT OF CYTOLOGY


ARCOFEMI - MEDIWHEEL - FULL BODY HEALTH ANNUAL PLUS CHECK - FEMALE - 2D ECHO - PAN INDIA - FY2324

LBC PAP SMEAR , CERVICAL SAMPLE

	CYTOLOGY NO.	24509/24
I	SPECIMEN	
a	SPECIMEN ADEQUACY	ADEQUATE
b	SPECIMEN TYPE	LIQUID-BASED PREPARATION (LBC)
	SPECIMEN NATURE/SOURCE	CERVICAL SMEAR
c	ENDOCERVICAL-TRANSFORMATION ZONE	ABSENT
d	COMMENTS	SATISFACTORY FOR EVALUATION
II	MICROSCOPY	Superficial and intermediate squamous epithelial cells with benign morphology. Inflammatory cells, predominantly neutrophils. Negative for intraepithelial lesion/malignancy.
III	RESULT	
a	EPITHEIAL CELL	
	SQUAMOUS CELL ABNORMALITIES	NOT SEEN
	GLANDULAR CELL ABNORMALITIES	NOT SEEN
b	ORGANISM	NIL
IV	INTERPRETATION	NEGATIVE FOR INTRAEPITHELIAL LESION OR MALIGNANCY

Pap Test is a screening test for cervical cancer with inherent false negative results. Regular screening and follow-up is recommended (Bethesda-TBS-2014) revised

*** End Of Report ***



Dr. Reshma Stanly
M.B.B.S, DNB(Pathology)
Consultant Pathologist

SIN No: MYS241100501




Patient Name : Mrs.POLISETTY NIROSHA
Age/Gender : 32 Y 3 M 30 D/F
UHID/MR No : CMYS.0000062543
Visit ID : CMYSOPV131293
Ref Doctor : Self
Emp/Auth/TPA ID : 22S38023

Collected : 09/Nov/2024 12:29PM
Received : 10/Nov/2024 02:17PM
Reported : 11/Nov/2024 06:55PM
Status : Final Report
Sponsor Name : ARCOFEMI HEALTHCARE LIMITED

TERMS AND CONDITIONS GOVERNING THIS REPORT

1. Reported results are for information and interpretation of the referring doctor or such other medical professionals, who understand reporting units, reference ranges and limitation of technologies. Laboratories not be responsible for any interpretation whatsoever.
2. It is presumed that the tests performed are, on the specimen / sample being to the patient named or identified and the verifications of particulars have been confirmed by the patient or his / her representative at the point of generation of said specimen.
3. The reported results are restricted to the given specimen only. Results may vary from lab to lab and from time to time for the same parameter for the same patient (within subject biological variation).
4. The patient details along with their results in certain cases like notifiable diseases and as per local regulatory requirements will be communicated to the assigned regulatory bodies.
5. The patient samples can be used as part of internal quality control, test verification, data analysis purposes within the testing scope of the laboratory.
6. This report is not valid for medico legal purposes. It is performed to facilitate medical diagnosis only.



Dr. Reshma Stanly
M.B.B.S, DNB(Pathology)
Consultant Pathologist



SIN No: MYS241100501

Apollo Health and Lifestyle Limited (CIN: U89107TG00000015819)
Regd. Office: 1-10-60/62, Ashoka Raghupathi Chambers, 5th Floor, Begumpet, Hyderabad, Telangana - 500 016 |
www.apollohl.com | Email ID: enquiry@apollohl.com, Ph No: 040-4904 7777, Fax No: 4904 7744

GSTIN: 29AAD007335173
Address: 22, 23, 24, 25/T01/3, Sree Rama Layout, BNR Complex,
OPP.RBI Layout, JP Nagar, 7th Phase, Bengaluru, Karnataka



APOLLO CLINICS NETWORK
Telangana: Hyderabad (AS Rao Nagar | Chanda Nagar | Kondapur | Nallakunta | Nizampet | Manikonda | Uppal) | Andhra Pradesh: Vizag (Seethamma Peta) | Karnataka: Bangalore (Basavanagudi | Bellandur | Electronics City | Fraser Town | HSR Layout | Indira Nagar | JP Nagar | Kundalahalli | Koramangala | Sarjapur Road) | Mysore (VV Mohalla) | Tamilnadu: Chennai (Annanagar | Kotturpuram | Mogappair | T Nagar | Valasaravakkam | Velachery) | Maharashtra: Pune (Aundh | Nigdi Pradhikaran | Viman Nagar | Wanowrie) | Uttar Pradesh: Ghaziabad (Indrapuram) | Gujarat: Ahmedabad (Satellite) | Punjab: Amritsar (Court Road) | Haryana: Faridabad (Railway Station Road)

Patient Name	: Mrs. POLISETTY NIROSHA	Age	: 32Yrs 4Mths 1Days
UHID	: CMYS.0000062543	OP Visit No.	: CMYSOPV131293
Printed On	: 10-11-2024 04:48 AM	Advised/Pres Doctor	: --
Department	: Radiology	Qualification	: --
Referred By	: Self	Registration No.	: --
Employeer Id	: 22S38023		

DEPARTMENT OF RADIOLOGY

LIVER: It is normal in size and is increased in echotexture. No focal lesions seen. IHBR are not dilated. CBD and Portal vein are normal.

GALL BLADDER: It is minimally distended and normal. No calculi seen.

SPLEEN: It is normal in size, outline and echopattern. No e/o focal lesions.

PANCREAS: It is normal.

RIGHT KIDNEY: It measures 9.4 cm with parenchymal thickness of 1.1cm. It is normal in size, outline and echotexture. No e/o calculus or hydronephrosis seen.

LEFT KIDNEY: It measures 9.6cm with parenchymal thickness of 1.1 cm. It is normal in size, outline and echotexture. No e/o calculus or hydronephrosis seen.

URINARY BLADDER: It is well distended. The UB wall is normal. No calculi seen.

UTERUS: It is anteverted and measures 6.7x3.4x5.4 cm with ET = 4.5mm. It is normal in size, outline and echotexture. No mass lesion.


Rt. OVARY: It measures 2.9x2 cm. It is normal. No mass lesion seen.

Lt. OVARY: It measures 2.8x2.1 cm. It is normal. No mass lesion seen.

OTHERS: No e/o free fluid in the abdomen. No e/o lymphadenopathy. No e/o gut wall thickening. No mass lesion seen in the abdomen.

IMPRESSION: GRADE I FATTY LIVER .

---End Of The Report---



Dr.CHETAN HOLEPPAGOL
MBBS, DNB(RADIO DIAGNOSIS)
90037
Radiology

Patient Name	: Mrs. POLISETTY NIROSHA	Age	: 32Yrs 4Mths 1Days
UHID	: CMYS.0000062543	OP Visit No.	: CMYSOPV131293
Printed On	: 10-11-2024 03:53 AM	Advised/Pres Doctor	: --
Department	: Cardiology	Qualification	: --
Referred By	: Self	Registration No.	: --
Employer Id	: 22S38023		

DEPARTMENT OF CARDIOLOGY


Observation :-

1. Sinus Rhythm.
2. Heart rate is 64 beats per minutes.

Impression:

NORMAL RESTING ECG.

---End Of The Report---



Dr. GURU PRASAD B V
MBBS, PGDCC
69949
Cardiology

Patient Name	: Mrs. POLISETTY NIROSHA	Age	: 32Yrs 4Mths 5Days
UHID	: CMYS.0000062543	OP Visit No.	: CMYSOPV131293
Printed On	: 14-11-2024 07:39 AM	Advised/Pres Doctor	: --
Department	: Cardiology	Qualification	: --
Referred By	: Self	Registration No.	: --
Employeer Id	: 22S38023		

DEPARTMENT OF CARDIOLOGY

2D ECHOCARDIOGRAPHY STUDY

Impression:

Normal chambers and valves
No regional wall motion abnormality
Normal left ventricular systolic function. EF 60 %
No clots. No pericardial effusion

??????

Findings

Left Ventricle: No RWMA
Right Ventricle Normal
Left Atrium Normal
Right Atrium Normal
Aorta Normal
Pulmonary Artery Normal
IAS Intact
IVS Intact
Valves Normal
Pericardium Normal
Doppler Normal

Patient's Name :Mrs. POLISETTY NIROSHA Age & Sex; 32Yrs /Female

Date : 09.11.2024

UHID No: 62543

Measurements

AO:2.1 cm

LA :2.4 cm

RV :1.9 cm

LVIDd 4.90 cm

LVIDs :3.30 cm

IVSd :0.62 cm

IVSs :0.80 cm

PWd :0.64 cm

PWs :1.11 cm

EF : 60.0 %

FS : 34.0 %


Doppler

MV TV AV PV

E :0.59m/sE --- m/sV max1.13m/sV max0.78m/s

A: 0.51 m/sA --- m/s

---End Of The Report---



Dr. GURU PRASAD B V
MBBS, PGDCC
69949
Cardiology

Name : Mrs. POLISETTY NIROSHA
Address : Mysore Mysore Karnataka INDIA 570001
Plan : ARCOFEMI MEDIWHEEL FEMALE AHC
CREDIT PAN INDIA OP AGREEMENT

Age : 32Y 3M 30D
sex : Female
60.6
156.
110/80

UHID : CMYS.0000062543



OP No: CMYSOPV131293
Bill No: CMYS-OCR-24655
Date: Nov 9th, 2024, 8:31 AM

Sno.	Service Type/Service Name	Department	
1	ARCOFEMI - MEDIWHEEL - FULL BODY HEALTH ANNUAL PLUS CHECK - FEMALE - 2D ECHO - PAN INDIA - FY2324		
1	ULTRASOUND - WHOLE ABDOMEN - P	Ultrasound Radiology	<input type="checkbox"/>
2	OPHTHAL BY GENERAL PHYSICIAN - P	Consultation	<input type="checkbox"/>
3	URINE GLUCOSE(POST PRANDIAL) - P	Clinical Pathology	<input type="checkbox"/>
4	GAMMA GLUTAMYL TRANSFERASE (GGT)	Biochemistry	<input type="checkbox"/>
5	HbA1c, GLYCATED HEMOGLOBIN	Biochemistry	<input type="checkbox"/>
6	GYNAECOLOGY CONSULTATION - P	Consultation	<input type="checkbox"/>
7	DIET CONSULTATION - P	General	<input type="checkbox"/>
8	BODY MASS INDEX (BMI)	General	<input type="checkbox"/>
9	ECG	Cardiology	<input type="checkbox"/>
10	THYROID PROFILE (TOTAL T3, TOTAL T4, TSH)	Biochemistry	<input type="checkbox"/>
11	2 D ECHO - P	Cardiology	<input type="checkbox"/>
12	BLOOD GROUP ABO AND RH FACTOR	Blood Bank	<input type="checkbox"/>
13	X-RAY CHEST PA	X Ray Radiology	<input type="checkbox"/>
14	URINE GLUCOSE(FASTING)	Clinical Pathology	<input type="checkbox"/>
15	LBC PAP TEST- PAPSURE -	Histopathology	<input type="checkbox"/>
16	FITNESS BY GENERAL PHYSICIAN - P	Consultation	<input type="checkbox"/>
17	GLUCOSE, POST PRANDIAL (PP), 2 HOURS (POST MEAL)	Biochemistry	<input type="checkbox"/>
18	GLUCOSE, FASTING	Biochemistry	<input type="checkbox"/>
19	ENT CONSULTATION - P	Consultation	<input type="checkbox"/>
20	LIPID PROFILE	Biochemistry	<input type="checkbox"/>
21	DENTAL CONSULTATION	Consultation	<input type="checkbox"/>
22	HEMOGRAM + PERIPHERAL SMEAR	Haematology	<input type="checkbox"/>
23	PERIPHERAL SMEAR	Haematology	<input type="checkbox"/>
24	COMPLETE URINE EXAMINATION	Clinical Pathology	<input type="checkbox"/>
25	RENAL PROFILE/RENAL FUNCTION TEST (RFT/KFT)	Biochemistry	<input type="checkbox"/>
26	LIVER FUNCTION TEST (LFT)	Biochemistry	<input type="checkbox"/>

CERTIFICATE OF MEDICAL FITNESS

This is to certify that I have conducted the clinical examination

of Mrs. Polisetty Nirosha on 24/11/24.

After reviewing the medical history and on clinical examination it has been found that he/she is

	Tick
<ul style="list-style-type: none"> • Medically Fit 	<input checked="" type="checkbox"/>
<ul style="list-style-type: none"> • Fit with restrictions/recommendations <p>Though following restrictions have been revealed, in my opinion, these are not impediments to the job.</p> <p>1.....</p> <p>2.....</p> <p>3.....</p> <p>However the employee should follow the advice/medication that has been communicated to him/her.</p> <p>Review after _____</p>	
<ul style="list-style-type: none"> • Currently Unfit. <p>Review after _____ recommended</p>	
<ul style="list-style-type: none"> • Unfit 	

Dr. J. Mukund
Medical Officer

Apollo Clinic
23, 1st Floor,
Kalidasa Road, Mysore - 02
Ph : 0821-4006040/41

This certificate is not meant for medico-legal purposes

Apollo Health and Lifestyle Limited

(CIN - U85110TG2000PLC115819)

Regd. Office: 1-10-60/62, Ashoka Raghupathi Chambers, 5th Floor, Begumpet, Hyderabad, Telangana - 500 016.

Ph No: 040-4904 7777, Fax No: 4904 7744 | Email ID: enquiry@apollohl.com | www.apollohl.com

APOLLO CLINICS NETWORK KARNATAKA

Bangalore (Basavanagudi | Bellandur | Electronic City | Fraser Town | HSR Layout | Indira Nagar | JP Nagar | Kundalahalli | Koramangala | Sarjapur Road) **Mysore** (VV Mohalla)

Online appointments: www.apolloclinic.com

TO BOOK AN APPOINTMENT

 **1860 500 7788**

[Phy]

Mrs. Polisetty Nirosha.

32yrs | Female

Dr. J. MUKUND

MBBS, MD (Internal
Medicine)

Height: 156 cm	Weight: 60.6 kg	BMI:	Waist Circum:
Temp:	Pulse:	Resp:	B.P: 110/80

General Examination /
Allergies History

Clinical Diagnosis & Management Plan

Routine health check up

No comorbidities

Reports - Noted.
No intervention

Follow up date:

J. Mukund

Doctor Signature

Apollo Clinic
23, 1st Floor,
Kalidasa Road, Mysore - 02
Ph : 0821-4006040/41

[Ophthal]

Date : 11/9/2024
Patient Name : Mrs. POLISETTY NIROSHA
UHID : CMYS.0000062543
Age / Gender : 32Yrs 3Mths 30Days/ Female
Consulation Timing : 9:34 AM

Department : General Practice
Doctor : Dr.SUJATHA T R
Registration No. : 69649
Qualification : MBBS, PGDMCH

Height : 156	Weight : 60.6	BMI :	Waist Circum :
Temp :	Pulse :	Resp :	B.P: 110/80

General Examination / Allergies History

Clinical Diagnosis & Management Plan

Distance vision

un { 6/6
6/6

Get near vision

NG

(CV) = normal

Colour vision

sub

(BE) = normal vision

Follow up date : 09/11/24

Sujatha
Doctor Signature

Apollo Clinic
23, 1st Floor,
Kalidasa Road, Mysore - 02
Ph : 0821-4006040/41

Date : 11/9/2024 Department : Dental
 Patient Name : Mrs. POLISETTY NIROSHA Doctor : Dr. JYOTHISHREE P V
 UHID : CMYS.0000062543 Registration No. : 33268A
 Age / Gender : 32Yrs 3Mths 30Days/ Female Qualification : B.D.S.[Bachelor of Dental Surgery]
 Consultation Timing : 9:35 AM

Height : 156	Weight : 60.6	BMI :	Waist Circum :
Temp :	Pulse :	Resp :	B.P : 110/80

General Examination /
Allergies History

Clinical Diagnosis & Management Plan

OK Gen. spacing noted on upper
& lower arch.

Adv. ortho intervention.

Curt, Sgt

Adv. oral prophylaxis

Follow up date :

Jyothisha

Doctor Signature

Apollo Clinie
 # 23, 1st Floor;
 Kalidasa Road, Mysore - 07
 Ph : 0821-4006040/41

Date : 11/9/2024 Department : ENT
 Patient Name : Mrs. POLISETTY NIROSHA Doctor : Dr. PRAVEEN KUMAR R
 UHID : CMYS.0000062543 Registration No. : 66012
 Age / Gender : 32Yrs 3Mths 30Days/ Female Qualification : MBBS, MS (ENT)
 Consultation Timing : 9:34 AM

Height : 156	Weight : 60.6	BMI :	Waist Circum :
Temp :	Pulse :	Resp :	B.P : 116/80

General Examination /
Allergies History

Clinical Diagnosis & Management Plan

Complaint for recurrent headache

Ear Bilateral OM - (a)

Nose - Nasal mass (a)

oral cavity & oropharynx - (a)

neck (a)

Adenoid tonsils

Follow up date :

Doctor Signature

Apollo Clinic
 # 23, 1st Floor,
 Kalidasa Road, Mysore - 02
 Ph : 0821-4006040/41

Date : 11/9/2024 Department : Nutrition & Dietetics
 Patient Name : Mrs. POLISETTY NIROSHA Doctor : Miss.MADHURA B P
 UHID : CMYS.0000062543 Registration No. : A104102
 Age / Gender : 32Yrs 3Mths 30Days/ Female Qualification : M.Sc. Nutrition and Dietetics
 Consultation Timing : 9:36 AM Ph.D*

IBW - 53kg

Height : 156	Weight : 60.6	BMI : 24.9 kg/m ²	Waist Circum : 80
Temp :	Pulse :	Resp :	B.P : 110/80

General Examination / Allergies History


ESR - 80
 LDL - 112.15
 T₃ Total - 0.86

Clinical Diagnosis & Management Plan

- Δ^{size} - Grade I fatty liver
- ⇒ Advised 'Balanced diet' with fiber rich food
 - ⇒ cooking oil - 1/2 liter / person / month. Use the combination of oils like groundnut oil, Mustard oil, coconut oil, Rice bran oil, Argemone oil & Olive. But do not mix the oils & soya.
 - ⇒ Avoid alcohol, sugar, too much of salt, baking soda & creams.
 - ⇒ Avoid bakery products, sweets, junk foods, deep fried foods, packed & processed foods.
 - ⇒ Avoid seed meat.
 - ⇒ Include skimmed / low fat milk instead of whole fat milk.

Follow up date :

Doctor Signature

 - B. P.

9/11/2024

Apollo Clinic
 # 23, 1st Floor,
 Kalidasa Road, Mysore - 02
 Ph : 0821-400604/41

Patient Name : Mrs. POLISETTY NIROSHA Age : 32Yrs 3Mths 30Days
UHID : CMYS.0000062543 OP Visit No. : CMYSOPV131293
Printed On : 09-11-2024 12:43 PM Advised/Pres Doctor : --
Department : Radiology Qualification : --
Referred By : Self Registration No. : --
Employee Id : 22S38023

DEPARTMENT OF RADIOLOGY

Lung fields are clear.

Cardio thoracic ratio is normal.

Apices, costo and cardio phrenic angles are free.


Cardio vascular shadow and hila show no abnormal feature.

Bony thorax shows no significant abnormality.

Domes of diaphragm are well delineated.

IMPRESSION: NORMAL STUDY .

---End Of The Report---



Dr.CHETAN HOLEPPAGOL
MBBS, DNB(RADIO DIAGNOSIS)
90037
Radiology

Patient Name: Mrs. POLISETTY NIROSHA	Date : 09.11 .2024	Referring Doctor: Dr. Self
Age / Sex: 32Yrs/Female	UHID No : 62543	Location : OP
ULTRASONOGRAPHY- ABDOMEN & PELVIS		

LIVER: It is normal in size and is increased in echotexture. No focal lesions seen. IHBR are not dilated. CBD and Portal vein are normal.

GALL BLADDER: It is minimally distended and normal. No calculi seen.

SPLEEN: It is normal in size, outline and echopattern. No e/o focal lesions.

PANCREAS: It is normal.

RIGHT KIDNEY: It measures 9.4 cm with parenchymal thickness of 1.1cm. It is normal in size, outline and echotexture. No e/o calculus or hydronephrosis seen.

LEFT KIDNEY: It measures 9.6cm with parenchymal thickness of 1.1 cm. It is normal in size, outline and echotexture. No e/o calculus or hydronephrosis seen.

URINARY BLADDER: It is well distended. The UB wall is normal. No calculi seen.

UTERUS: It is anteverted and measures 6.7x3.4x5.4 cm with ET= 4.5mm. It is normal in size, outline and echotexture. No mass lesion.

Rt. OVARY: It measures 2.9x2 cm. It is normal. No mass lesion seen.

Lt. OVARY: It measures 2.8x2.1 cm. It is normal. No mass lesion seen.

OTHERS: No e/o free fluid in the abdomen. No e/o lymphadenopathy. No e/o gut wall thickening. No mass lesion seen in the abdomen.

IMPRESSION: GRADE I FATTY LIVER .

Karthik
Dr. Karthik H V MDRD , DNB
Consultant Radiologist.

Apollo Health and Lifestyle Limited

CIN: U85110TG2000PLC1158191

Regd Office: 1-10-60/62, Ashoka Raghupathi Chambers, 5th Floor, Begumpet, Hyderabad, Telangana - 500 016

Ph No: (040) 4904 7777 Fax No: 4904 7744 | Email ID: enquiry@apollohl.com | www.apollohl.com

Apollo Clinics Network Karnataka

Bangalore (Basavanagudi | Bellandur | Electronic City | Fraser Town | HSR Layout | Indra Nagar | JP Nagar | Kundalahalli | Koramangala | Sarjapur Road) Mysore (VV Mohalla)

Online appointments: www.apolloclinic.com

TO BOOK AN APPOINTMENT

1860 500 7788

Patient's Name : Mrs. POLISETTY NIROSHA	Age & Sex; 32Yrs /Female
Date : 09.11.2024	UHID No: 62543

2D ECHOCARDIOGRAPHY STUDY

Impression:

- Normal chambers and valves
- No regional wall motion abnormality
- Normal left ventricular systolic function. EF 60 %
- No clots. No pericardial effusion

Findings

Left Ventricle:	No RWMA
Right Ventricle	Normal
Left Atrium	Normal
Right Atrium	Normal
Aorta	Normal
Pulmonary Artery	Normal
IAS	Intact
IVS	Intact
Valves	Normal
Pericardium	Normal
Doppler	Normal

Apollo Health and Lifestyle Limited

(CIN: U85110TG2000PLC115819)
Regd Office: 110-60/62, Ashoka Raghupathi Chambers, 5th Floor, Begumpet, Hyderabad, Telangana - 500 016
Ph. No: (040) 4904 7777 Fax No: 4904 7744 | Email ID: enquiry@apollohi.com | www.apollohi.com

APOLLO CLINICS NETWORK KARNATAKA
Bangalore: Basavanagudi | Bellandur | Electronic City | Fraser Town | HSR Layout | Indira Nagar | JP Nagar | Kundalahalli |
Koramangala | Sarjapur Road | Mysore (VV Mohalla)

Online appointments: www.apolloclinic.com

TO BOOK AN APPOINTMENT

 **1860 500 7788**

Patient's Name : Mrs. POLISETTY NIROSHA	Age & Sex; 32Yrs /Female
Date : 09.11.2024	UHID No: 62543

Measurements

AO : 2.1 cm
 LA : 2.4 cm

 RV : 1.9 cm
 LVIDd 4.90 cm
 LVIDs : 3.30 cm
 IVSd : 0.62 cm
 IVSs : 0.80 cm
 PWd : 0.64 cm
 PWs : 1.11 cm
 EF : 60.0 %
 FS : 34.0 %

Doppler
 MV TV AV PV
 E 0.69~~5~~ m/s E --- m/s V max 1.13 m/s V max 0.78 m/s
 :
 A: 0.51 m/s A --- m/s

Dr. GURU PRASAD. B. V, MBBS, PGDCC
CONSULTANT – NON-INVASIVE CARDIOLOGY

Apollo Health and Lifestyle Limited

(CIN U85110TG2000PLC115819)
 Regd Office 1 10-60 62, Ashoka Raghupathi Chambers, 5th Floor, Begumpet, Hyderabad, Telangana - 500 016
 Ph No (04) 4904 7777 Fax No 4904 7744 | Email ID enquiry@apollohl.com | www.apollohl.com

APOLLO CLINICS NETWORK KARNATAKA
 Bangalore (Basavanagudi) | Bellandur | Electronic City | Fraser Town | HSR Layout | Indira Nagar | JP Nagar | Kundalahalli |
 Koramangala | Sarjapur Road | Mysore (VV Mohalla)

Online appointments. www.apolloclinic.com

TO BOOK AN APPOINTMENT

1860 500 7788

Apollo Clinic

CONSENT FORM

Patient Name: Polisetty Nirosha Age: 32 years
UHID Number: 62543 Company Name: Arcofemi

I Mr/Mrs/Ms Polisetty Nirosha Employee of Arcofemi

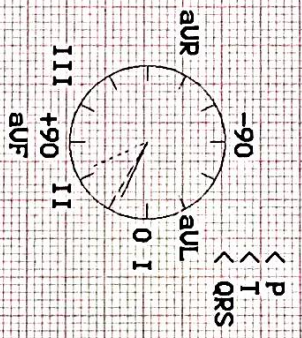
(Company) Want to inform you that I am not interested in getting Cyn Consultation

Tests done which is a part of my routine health check package.

And I claim the above statement in my full consciousness.

Patient Signature: P. Nirosha Date: 9/11/24

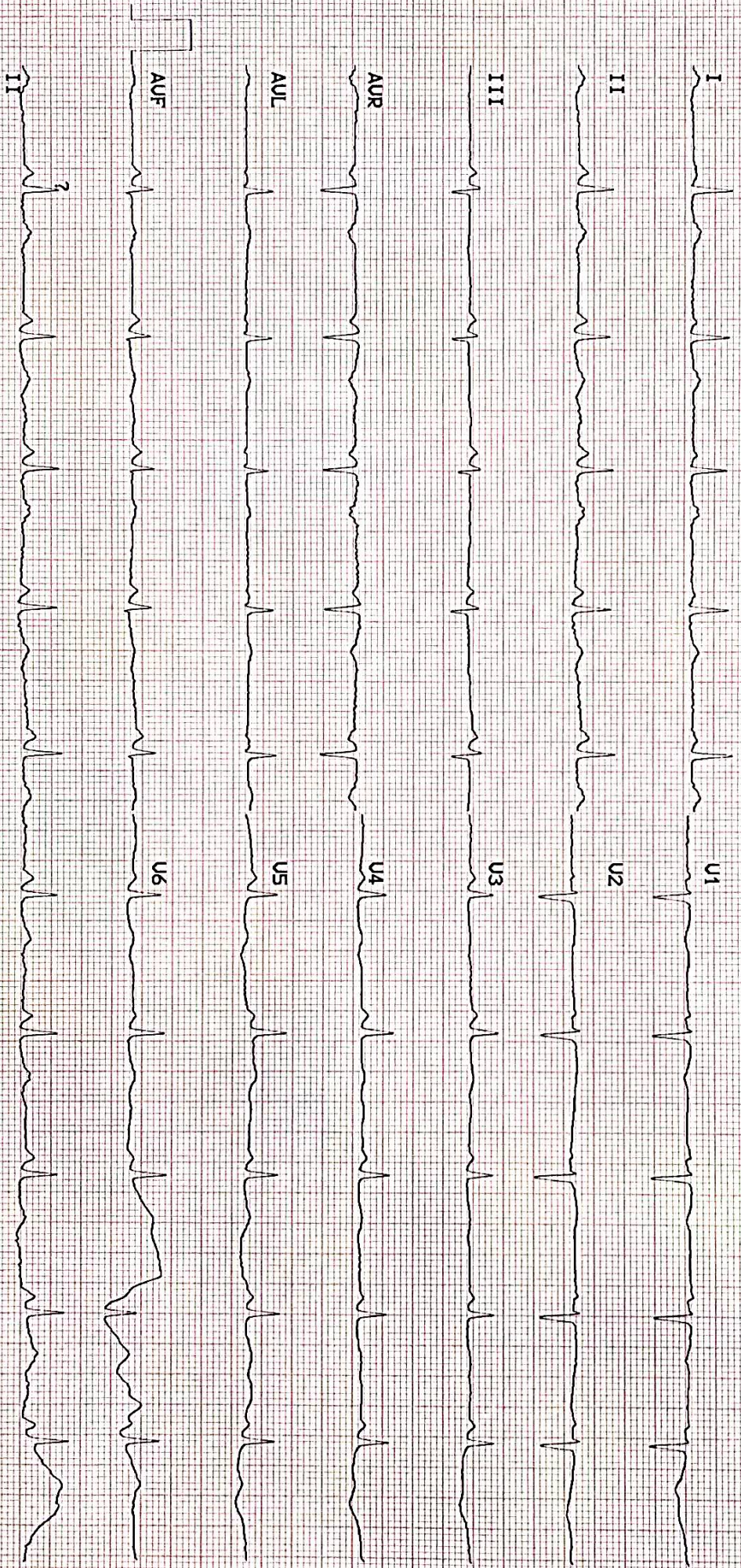
AGE: 32
 Measurement Results:
 QRS : 88 ms
 QT/QTcB : 420 / 434 ms
 PR : 128 ms
 P : 104 ms
 RR/PP : 938 / 935 ms
 P/QRS/T : 65 / 25 / 30 degrees
 QTd/QTcBD : 44 / 45 ms
 Sokolow : 1.1 mV
 NK : 8

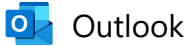


Interpretation:

Unconfirmed report.

Apollo Clinic
 # 23, 1st Floor,
 Kallidasa Road, Mysore - 02
 Ph : 0821-4006040/41





Your appointment is confirmed

From noreply@apolloclinics.info <noreply@apolloclinics.info>
Date Thu 07-11-2024 18:37
To raju.mca222@gmail.com <raju.mca222@gmail.com>
Cc Mysore Apolloclinic <mysore@apolloclinic.com>; Yogeesh KV <mkt.mysore@apolloclinic.com>; Syamsunder M <syamsunder.m@apollohl.com>



Dear nirosha polisetty,

Greetings from Apollo Clinics,

Your corporate health check appointment is confirmed at KALIDASA RAOD clinic on 2024-11-09 at 08:15-08:30.

Table with 2 columns: Field Name, Value. Fields include Payment Mode, Corporate Name (ARCOFEMI HEALTHCARE LIMITED), Agreement Name ([ARCOFEMI MEDIWHEEL FEMALE AHC CREDIT PAN INDIA OP AGREEMENT]), and Package Name ([ARCOFEMI - MEDIWHEEL - FULL BODY HEALTH ANNUAL PLUS CHECK - FEMALE - 2D ECHO - PAN INDIA - FY2324]).

"Kindly carry with you relevant documents such as HR issued authorization letter and or appointment confirmation mail and or valid government ID proof and or company ID card and or voucher as per our agreement with your company or sponsor."

Note: Video recording or taking photos inside the clinic premises or during camps is not allowed and would attract legal consequences.

Note: Also once appointment is booked, based on availability of doctors at clinics tests will happen, any pending test will happen based on doctor availability and clinics will be updating the same to customers.

Instructions to be followed for a health check:

- 1. Please ensure you are on complete fasting for 10-To-12-Hours prior to check.
2. During fasting time do not take any kind of alcohol, cigarettes, tobacco or any other liquids (except Water) in the morning. If any medications taken, pls inform our staff before health check.

3. Please bring all your medical prescriptions and previous health medical records with you.
4. Kindly inform our staff, if you have a history of diabetes and cardiac problems.

For Women:

1. Pregnant women or those suspecting are advised not to undergo any X-Ray test.
2. It is advisable not to undergo any health check during menstrual cycle.









For further assistance, please call us on our Help Line #: 1860 500 7788.

Clinic Address: 23, KALIDASA ROAD, VV MOHLLA, MYSORE.

Contact No: (0821) 400 6040 - 41.

P.S: Health Check-Up may take 4 - 5hrs for completion on week days & 5 - 6hrs on Saturdays, kindly plan accordingly, Doctor Consultation will be completed after all the Reports are ready.

Warm Regards,
Apollo Clinic

  <p style="text-align: center;">ಭಾರತ ಸರ್ಕಾರ Government of India</p> <p style="text-align: center;">ಭಾರತೀಯ ವಿಶಿಷ್ಟ ಗುರುತು ಪ್ರಾಧಿಕಾರ Unique Identification Authority of India</p> <p>ನೋಂದಣಿ ಸಂಖ್ಯೆ/ Enrolment No.: 0648/11128/05421</p> <p>To ಪಾಲಿಶೆಟ್ಟಿ ನಿರೋಷಾ Polisetty Nirosha C/O: Raju No 1/463 Chaithanya Colony Siripuram Medikonduru Guntur Siripuram Guntur Andhra Pradesh - 522401 9581669954</p> <p>Signature Not Verified</p>  <p>ನಿಮ್ಮ ಆಧಾರ್ ಸಂಖ್ಯೆ / Your Aadhaar No. : 6864 5746 5216 VID : 9146 0009 9476 1430 ನನ್ನ ಆಧಾರ್, ನನ್ನ ಗುರುತು</p>	  <p style="text-align: center;">ಮಾಹಿತಿ</p> <ul style="list-style-type: none"> ■ ಆಧಾರ್ ಗುರುತಿನ ಪುರಾವೆಯೇ ಹೊರತು ಪೌರತ್ವದಲ್ಲ ■ ಸುರಕ್ಷಿತ ಕ್ಯೂಆರ್ ಕೋಡ್/ಆಫ್ಲೈನ್ XML/ಆನ್ಲೈನ್ ದೃಢೀಕರಣ ಬಳಸಿ ಗುರುತನ್ನು ಪರಿಶೀಲಿಸಿ ■ ಎಲೆಕ್ಟ್ರಾನಿಕ್ ಪ್ರಕ್ರಿಯೆ ಮೂಲಕ ಮುದ್ರಿತವಾದ ವಿದ್ಯುನ್ಮಾನ ದಾಖಲೆ ಇದಾಗಿದೆ <p style="text-align: center;">INFORMATION</p> <ul style="list-style-type: none"> ■ Aadhaar is a proof of identity, not of citizenship. ■ Verify identity using Secure QR Code/ Offline XML Authentication. ■ This is electronically generated letter. <div style="border: 1px solid black; padding: 5px;"> <ul style="list-style-type: none"> ■ ಆಧಾರ್ ದೇಶದಾದ್ಯಂತ ಮಾನ್ಯತೆಯನ್ನು ಪಡೆದಿದೆ ■ ಸುಲಭವಾಗಿ ಸರ್ಕಾರಿ ಹಾಗೂ ಸರ್ಕಾರೇತರ ಸೇವೆಗಳನ್ನು ಪಡೆಯಲು ಆಧಾರ್ ಸಹಾಯವಾಗಲಿದೆ ■ ನಿಮ್ಮ ಮೊಬೈಲ್ ಸಂಖ್ಯೆ ಮತ್ತು ಇ-ಮೇಲ್ ಐಡಿ ಅನ್ನು ಆಧಾರ್ ನಲ್ಲಿ ನವೀಕರಿಸಿ ■ ಆಧಾರ್ ನ್ನು ನಿಮ್ಮ ಸ್ಮಾರ್ಟ್ ಫೋನ್ ನಲ್ಲಿ ಕೊಂಡೊಯ್ಯಿರಿ- mAadhaar ಅಪ್ಲಿಕೇಶನ್ ಬಳಸಿ </div> <ul style="list-style-type: none"> ■ Aadhaar is valid throughout the country ■ Aadhaar helps you avail various Government and non-Government services easily. ■ Keep your mobile number & email ID updated in Aadhaar. ■ Carry Aadhaar in your smart phone – mAadhaar App.
 <p style="text-align: center;">ಭಾರತ ಸರ್ಕಾರ Government of India</p> <div style="display: flex;">  <div style="margin-left: 10px;"> <p>ಪಾಲಿಶೆಟ್ಟಿ ನಿರೋಷಾ Polisetty Nirosha ಜನ್ಮ ದಿನಾಂಕ/DOB: 10/07/1992 ಸ್ತ್ರೀ/FEMALE</p> </div> </div> <p>Issue Date: 13/01/2012</p> <p style="text-align: center;">6864 5746 5216 VID : 9146 0009 9476 1430 ನನ್ನ ಆಧಾರ್, ನನ್ನ ಗುರುತು</p>	 <p style="text-align: center;">ಭಾರತೀಯ ವಿಶಿಷ್ಟ ಗುರುತು ಪ್ರಾಧಿಕಾರ Unique Identification Authority of India</p> <p>ವಿಳಾಸ: ಕೆ.ಆರ್. ಆರ್. ರಾಜು, ಸಂ 1/463 ಚೈತನ್ಯ ಕಾಲೋನಿ, ಸಿರಿಪುರಂ, ಮೆಡಿಕೊಂಡೂರು, ಗುಂಟೂರು, ಸಿರಿಪುರಂ, ಗುಂಟೂರು, ಆಂಧ್ರ ಪ್ರದೇಶ - 522401</p> <p>Address: C/O: Raju, No 1/463 Chaithanya Colony, Siripuram, Medikonduru, Guntur, Siripuram, Guntur, Andhra Pradesh - 522401</p> <p>Download Date: 06/06/2022</p> <p style="text-align: center;">6864 5746 5216 VID : 9146 0009 9476 1430</p> <p>1947 help@uidai.gov.in</p>