

# Shree Ram Multispeciality Hospital (SRMH)

L o k a h S a m a s t a S u k h i n o B h a v a n t u



OPD - ID : 02024 - 2025-0002015  
UH-ID : SRMH-25021970

PT. TYPE : FREE OPD  
PRINT DATE : 07-02-2025 / 09:06:55



PATIENT NAME	: MR. RAJESH SUNDI	OPD-DATE	: 07-Feb-2025 - 09:06 AM
AGE / SEX	: 51-Y 0-M 0-D / MALE	DEPARTMENT	: GENERAL MEDICINE
DOB	:	CONSULTANT	: DR. AJIT KUMAR
MOB-NO	: 9570014996	COMPANY NAME	: MEDIWHEEL
GUARDIAN NAME	: S/o PRADHAN SUNDI	OPD PAID FEE	: 0.00
ADDRESS	: PO. BARA GUIRA PS. MUFFASIL CHAIBASA BARA GUIRA DIURI SAI PASHCHIMI SINGHBHUM JHARKHAND, RAIP		

Weight : 65 kg Height : Temp : 96.7 °F B.P. :  $\frac{140}{90+6}$  mm Pulse : 78 b/m SPO2 : 100%

Near Railway Under Bridge, Basant Vihar Gate No. 1, Gondwara Chowk,  
Gudhiyari, Raipur (Chhattisgarh)

☎ 0771-43 43 161, 0771-43 40 162, 📞 8404 8404 79

✉ shreeramhospital.op@gmail.com 🌐 www.srmhraipur.com



# Shree Ram Multispeciality Hospital (SRMH)

Lokah Samasta Sukhino Bhavantu



OPD - ID : 02024-2025-0002015 PT. TYPE : NEWREGISTRATION  
 UH-ID : SRMH-25021970 PRINTDATE : 07-02-2025/09:17AM TOKENNO. : 2

PATIENTNAME	: MR. RAJESH SUNDI	DEPARTMENT	: ENT
AGE/SEX	: 51 Y O M O D / MALE	DOB	:
CONSULT-DATE	: 07/02/2025		
MOB-NO	: 9570014996	COMPANYNAME	: MEDIWHEEL
GUARDIANNAME	: S / O PRADHAN SUNDI	OPDPAIDFEE	: 0.00
ADDRESS	: PO. BARAGUIRA PS MUFFASIL CHAIBASA BARAGIRA DIURI SAI PASCHIMI SINGHBHUM JHARKHAND		
Weight :	Temp :	B.P. :	Pulse :
			SPO2 :

Please indicate whether you are presently suffering from anyone of the following symptoms:

Ears, Nose, Mouth, Throat

	Yes	No
Ear pain	0	0
Ear itch	0	0
Ear drainage	0	0
Dizziness/ Loss of balance	0	0
Loss of Hearing	0	0
Popping Noise	0	0
Tinnitus	0	0
Nosebleeds	0	0
Post-nasal Drip	0	0
Sinus pain	0	0
Sinus pressure	0	0
Nasal congestion	0	0
Loss of smell/taste	0	0
Hoarseness	0	0
Sore Throat	0	0
Throat tickle	0	0
Dry Mouth / Throat	0	0
Throat clearing	0	0
Snoring	0	0

Present chief complaints:-

Dr. Signature

FOLLOW-UP DATE \_\_\_\_\_  
 :ADVICEFORADMISSION



Near Railway Under Bridge, Basant Vihar Gate No. 1, Gondwara Chowk, Gudhiyari, Raipur (Chhattisgarh)

☎ 0771-43 43 161, 0771-43 40 162, 📞 8404 8404 79

✉ shreeramhospital.op@gmail.com 🌐 www.srmhraipur.com



# Shree Ram Multispeciality Hospital (SRMH)

Lokah Samasta Sukhino Bhavantu



PATIENT NAME : MR. RAJESH SUNDI  
MOBILE NO : 9570014996 TEST NO 1309  
DOCTOR : DR. AJIT KUMAR  
REFERRED BY : SELF

AGE / SEX : 51Y/MALE  
UH ID NO. : SRMH-25021970  
COLLECTION : 07-02-2025  
REPORTING : 07-Feb-2025

## HAEMATOLOGY

TEST NAME	RESULT	UNIT	NORMAL VALUES
<b>BLOOD GROUPING AND RH TYPING</b>			
BLOOD GROUP	"O"		-
RH FACTOR	POSITIVE		-
<b>CBC (COMPLETE BLOOD COUNT)</b>			
HAEMOGLOBIN (Hb)	12.1	gm%	12 - 16
TOTAL RBC COUNT	5.47	Million/cumm	4.5 - 5.1
HAEMATOCRIT (PCV)	36.3	%	35.9 - 44.6
<b>RBC INDICES</b>			
MCV	77.8	fl	78 - 96
MCH	22.2	pg	27 - 32
MCHC	28.6	%	33 - 37
RDW	13.2	%	11 - 16
TOTAL WBC COUNT (TLC)	6900	/cumm	4000 - 11000
<b>DIFFERENTIAL COUNT</b>			
NEUTROPHILS	73	%	40 - 70
LYMPHOCYTES	20	%	22 - 48
EOSINOPHILS	03	%	0 - 6
MONOCYTES	04	%	0 - 8
BASOPHILS	00	%	00 -
PLATELET COUNT	1.66	/cumm	1.50 - 4.50
PCT	0.21	%	0.10 - 0.28
MPV(MEAN PLATELET VOLUME)	13.0	µm <sup>3</sup>	8 - 11
PDW	16.4	%	11 - 18

-- End Of Report --

LAB TECHNICIAN

Dr. Dhananjay Prasad  
MBBS, MD (Pathologist)

Note : This Report is not for medicolegal purpose



Near Railway Under Bridge, Basant Vihar Gate No. 1, Gondwara Chowk,  
Gudhiyari, Raipur (Chhattisgarh)

☎ 0771-43 43 161, 0771-43 40 162, 📞 8404 8404 79

✉ shreeramhospital.op@gmail.com 🌐 www.srmhraipur.com



# SHREE RAM MULTISPECIALITY HOSPITAL

Lokah Samasta Sukhino Bhavantu

Near Railway Under Bridge, Basant Vihar Gate No. 1, Gondwara Chowk, Gudhiyari, Raipur (C.G.)  
Phone: 0771-4343161, 08404840479 Email: Shreeramhospitalop@gmail.com



NAME : MR. RAJESH SUNDI  
MOBILE NO : 9570014996  
DOCTOR : DR. AJIT KUMAR  
REFERRED BY : SELF

AGE / SEX : 51Y/MALE  
UH ID NO. : SRMH-25021970  
COLLECTION : 07-02-2025  
REPORTING : 07-Feb-2025

TEST NO  
1309

## BIOCHEMISTRY

TEST NAME	RESULT	UNIT	NORMAL VALUES
<b>BUN (BLOOD UREA NITROGEN)</b>			
BUN	14.5	mg / dl	7.00 - 20.00
Serum Creatinine	0.86	mg / dl	0.55 - 1.20
BUN / Creatinine Ratio	16.86		10.1 - 20.1

## UREA AND CREATININE

SERUM CREATININE	0.86	mg/dL	0.6 - 1.2
SERUM URIC ACID	5.19	mg/dL	3.6 - 7.7

## PATHOLOGY

TEST NAME	RESULT	UNIT	NORMAL VALUES
<b>GGT (GAMMA GLUTAMYL TRANSFERASE)</b>			
GGT	19.5	U / L	6.00 - 29.00

-- End Of Report --

LAB TECHNICIAN

Note : This Report is not for medicolegal purpose

Dr. Dhananjay Prasad  
MBBS, MD (Pathologist)



# SHREE RAM MULTISPECIALITY HOSPITAL

Lokah Samasta Sukhino Bhavantu

Near Railway Under Bridge, Basant Vihar Gate No. 1, Gondwara Chowk, Gudhiyari, Raipur (C.G.)  
Phone: 0771-4343161, 08404840479 Email: Shreeramhospitalop@gmail.com



PATIENT NAME : MR. RAJESH SUNDI  
MOBILE NO : 9570014996  
DOCTOR : DR. AJIT KUMAR  
REFERRED BY : SELF

AGE / SEX : 51Y/MALE  
UH ID NO. : SRMH-25021970  
COLLECTION : 07-02-2025  
REPORTING : 07-Feb-2025  
TEST NO : 1309

## BIOCHEMISTRY

TEST NAME	RESULT	UNIT	NORMAL VALUES
<b>HbA1c -Glycosylated hemoglobin</b>			
HbA1c -Glycosylated hemoglobin	4.51	%	Normal Range : <6% Good Control : 6-7% fair Control : 7-8% Unsatisfactory Control : 8-10% Poor Control : >10% - 80 - 120
Estimated average plasma glucose	83.25	mg/dl	


## LIPID PROFILE

CHOLESTEROL	201.6	mg / dl	150 - 220
SERUM TRYGLYCERIDE	110.5	mg / dl	60 - 165
HDL	36.2	mg / dl	35 - 80
LDL	165.4	mg/dL	90 - 160
VLDL	22.1	mg/dL	20 - 50
CHOLESTEROL / HDL RATIO	5.56	mg/dL	3.5 - 5.5
LDL/HDL Ratio	4.56	mg / dl	2.5 - 3.5

-- End Of Report --

LAB TECHNICIAN

Note : This Report is not for medicolegal purpose

  
Dr. Dhananjay Prasad  
MBBS, MD (Pathologist)

# SHREE RAM MULTISPECIALITY HOSPITAL

Lokah Samasta Sukhino Bhavantu

Near Railway Under Bridge, Basant Vihar Gate No. 1, Gondwara Chowk, Gudhiyari, Raipur (C.G.)  
Phone: 0771-4343161, 08404840479 Email: Shreeramhospitalop@gmail.com



PT. NAME : MR. RAJESH SUNDI  
MOBILE NO : 9570014996  
DOCTOR : DR. AJIT KUMAR  
REFERRED BY : SELF

AGE / SEX : 51Y/MALE  
UH ID NO. : SRMH-25021970  
COLLECTION : 07-02-2025  
REPORTING : 07-Feb-2025

TEST NO  
1309

## BIOCHEMISTRY

TEST NAME	RESULT	UNIT	NORMAL VALUES
<b>LIVER FUNCTION TEST (LFT)</b>			
BILIRUBIN TOTAL	0.54	mg/dL	0.2 - 1
BILIRUBIN DIRECT	0.23	mg / dl	0.1 - 0.6
BILIRUBIN INDIRECT	0.31	mg / dl	0.1 - 0.4
SGOT	35.2	U / L	0 - 46
SGPT	31.6	U / L	0 - 40
ALKALINE PHOSPHATASE	192.3	U / L	0 - 240
TOTAL PROTEIN	6.41	g / dl	6 - 8
ALBUMIN	3.79	g/dl	3.5 - 5.0
GLOBULIN	2.62	g / dl	2 - 3.5
A/G RATIO	1.44		1 - 2.5

### Clinical Significance

#### Alanine transaminase (ALT)

ALT is an enzyme found in the liver that helps your body metabolize protein. When the liver is damaged, ALT is released into the bloodstream and levels increase.

#### Aspartate transaminase (AST)

AST is an enzyme that helps metabolize alanine, an amino acid. Like ALT, AST is normally present in blood at low levels. A increase in AST levels may indicate liver damage or disease or muscle damage.

#### Alkaline phosphatase (ALP)

ALP is an enzyme in the liver, bile ducts and bone. Higher-than-normal levels of ALP may indicate liver damage or disease, such as a blocked bile duct, or certain bone diseases.

#### Albumin and total protein

Albumin is one of several proteins made in the liver. Your body needs these proteins to fight infections and to perform other functions. Lower-than-normal levels of albumin and total protein might indicate liver damage or disease.

#### Bilirubin

Bilirubin is a substance produced during the normal breakdown of red blood cells. Bilirubin passes through the liver and is excreted in stool. Elevated levels of bilirubin (jaundice) might indicate liver damage or disease or certain types of anemia.

-- End Of Report --

LAB TECHNICIAN

Note : This Report is not for medicolegal purpose

Dr. Dhananjay Prasad  
MBBS, MD (Pathologist)

# SHREE RAM MULTISPECIALITY HOSPITAL

Lokah Samasta Sukhino Bhavantu

Near Railway Under Bridge, Basant Vihar Gate No. 1, Gondwara Chowk, Gudhiyari, Raipur (C.G.)  
Phone: 0771-4343161, 08404840479 Email: Shreeramhospitalop@gmail.com



PT. NAME : MR. RAJESH SUNDI  
MOBILE NO : 9570014996  
DOCTOR : DR. AJIT KUMAR  
REFERRED BY : SELF

AGE / SEX : 51Y/MALE  
UH ID NO. : SRMH-25021970  
COLLECTION : 07-02-2025  
REPORTING : 07-Feb-2025  
TEST NO  
1309

## IMMUNOASSAY

TEST NAME	RESULT	UNIT	NORMAL VALUES
<b>SERUM PSA TOTAL</b>			
PSA (TOTAL )	1.21	ng/mL	0 - 4

### Clinical Significance :

- An aid in the early detection of Prostate cancer when used in conjunction with Digital rectal examination in males more than 50 years of age and in those with two or more affected first degree relatives.
- Follow up and management of Prostate cancer patients.
- Detect metastatic or persistent disease in patients following surgical or medical treatment of prostate cancer.
- An aid in the early detection of Prostate cancer when used in conjunction with Digital rectal examination in males more than 50 years of age and in those with two or more affected first degree relatives.
- Follow up and management of Prostate cancer patients.
- Detect metastatic or persistent disease in patients following surgical or medical treatment of prostate cancer.

### Increased Levels :

- Prostate cancer
- Benign Prostate Hyperplasia
- Prostatitis
- Genitourinary infections
- Prostate cancer
- Benign Prostate Hyperplasia
- Prostatitis
- Genitourinary infections

## THYROID PROFILE (T3, T4, TSH)

T3 (TRIIODOTHYRONINE)	0.99	ng/ml	0.8 - 2
T4 (THYROXINE)	9.16	ug/dl	5.13 - 14.06
TSH	2.01	uIU/ml	0.27 - 4.2

-- End Of Report --

LAB TECHNICIAN

Note : This Report is not for medicolegal purpose

Dr. Dhananjay Prasad  
MBBS, MD (Pathologist)

# SHREE RAM MULTISPECIALITY HOSPITAL

Lokah Samasta Sukhino Bhavantu



Near Railway Under Bridge, Basant Vihar Gate No. 1, Gondwara Chowk, Gudhiyari, Raipur (C.G.)  
Phone: 0771-4343161, 08404840479 Email: Shreeramhospitalop@gmail.com

PT. NAME : MR. RAJESH SUNDI  
MOBILE NO : 9570014996  
DOCTOR : DR. AJIT KUMAR  
REFERRED BY : SELF

AGE / SEX : 51Y/MALE  
UH ID NO. : SRMH-25021970  
COLLECTION : 07-02-2025  
REPORTING : 07-Feb-2025

TEST NO  
1309

## BIOCHEMISTRY

TEST NAME	RESULT	UNIT	NORMAL VALUES
<b>BLOOD SUGAR - FASTING AND PP</b>			
BLOOD SUGAR FASTING	91.5	mg/dL	70 - 110
BLOOD SUGAR PP	102.3	mg/dL	80 - 140

## CLINICAL PATHOLOGY

TEST NAME	RESULT	UNIT	NORMAL VALUES
<b>URINE SUGAR FASTING AND PP</b>			
URINE SUGAR FASTING	Absent		Absent -
URINE SUGAR PP	Absent		Absent -

## HAEMATOLOGY

TEST NAME	RESULT	UNIT	NORMAL VALUES
<b>ESR (ERYTHROCYTE SEDIMENTATION RATE)</b>			
ESR	10	mm at end of 1 h	0 - 20

-- End Of Report --

LAB TECHNICIAN

Note : This Report is not for medicolegal purpose

Dr. Dhananjay Prasad  
MBBS, MD (Pathologist)



# SHREE RAM MULTISPECIALITY HOSPITAL

Lokah Samasta Sukhino Bhavantu

Near Railway Under Bridge, Basant Vihar Gate No. 1, Gondwara Chowk, Gudhiyari, Raipur (C.G.)  
Phone: 0771-4343161, 08404840479 Email: Shreeramhospitalop@gmail.com



PT. NAME : MR. RAJESH SUNDI  
MOBILE NO : 9570014996  
DOCTOR : DR. AJIT KUMAR  
REFERRED BY : SELF

AGE / SEX : 51Y/MALE  
UH ID NO. : SRMH-25021970  
COLLECTION : 07-02-2025  
REPORTING : 07-Feb-2025

TEST NO  
1309

## CLINICAL PATHOLOGY


TEST NAME	RESULT	UNIT	NORMAL VALUES
<b>URINE ROUTINE AND MICROSCOPY</b>			
<b>PHYSICAL EXAMINATION</b>			
QUANTITY	20	ml	-
COLOUR	Pale Yellow		Pale Yellow -
APPEARANCE	Clear		Clear -
REACTION	Acitic		Acitic -
<b>CHEMICAL EXAMINATION</b>			
ALBUMIN	Absent		Absent -
SUGAR	Absent		Absent -
KETONE	Absent		Absent -
BILE SALT	Absent		Absent -
BILE PIGMENT	Absent		Absent -
<b>MICROSCOPIC EXAMINATION</b>			
PUS CELLS	2-3	/hpf	2 - 5
EPITHELIAL CELLS	1-2	/hpf	1 - 5
RBC	Nil	/hpf	0 - 3
CAST	Nil	/lpf	Nil -
YEAST	Nil		Nil -
CRYSTAL	Nil	/lpf	Nil -
BACTERIA	Nil		Nil -
OTHERS	-		-

-- End Of Report --

LAB TECHNICIAN

Note : This Report is not for medicolegal purpose

Dr. Dhananjay Prasad  
MBBS, MD (Pathologist)



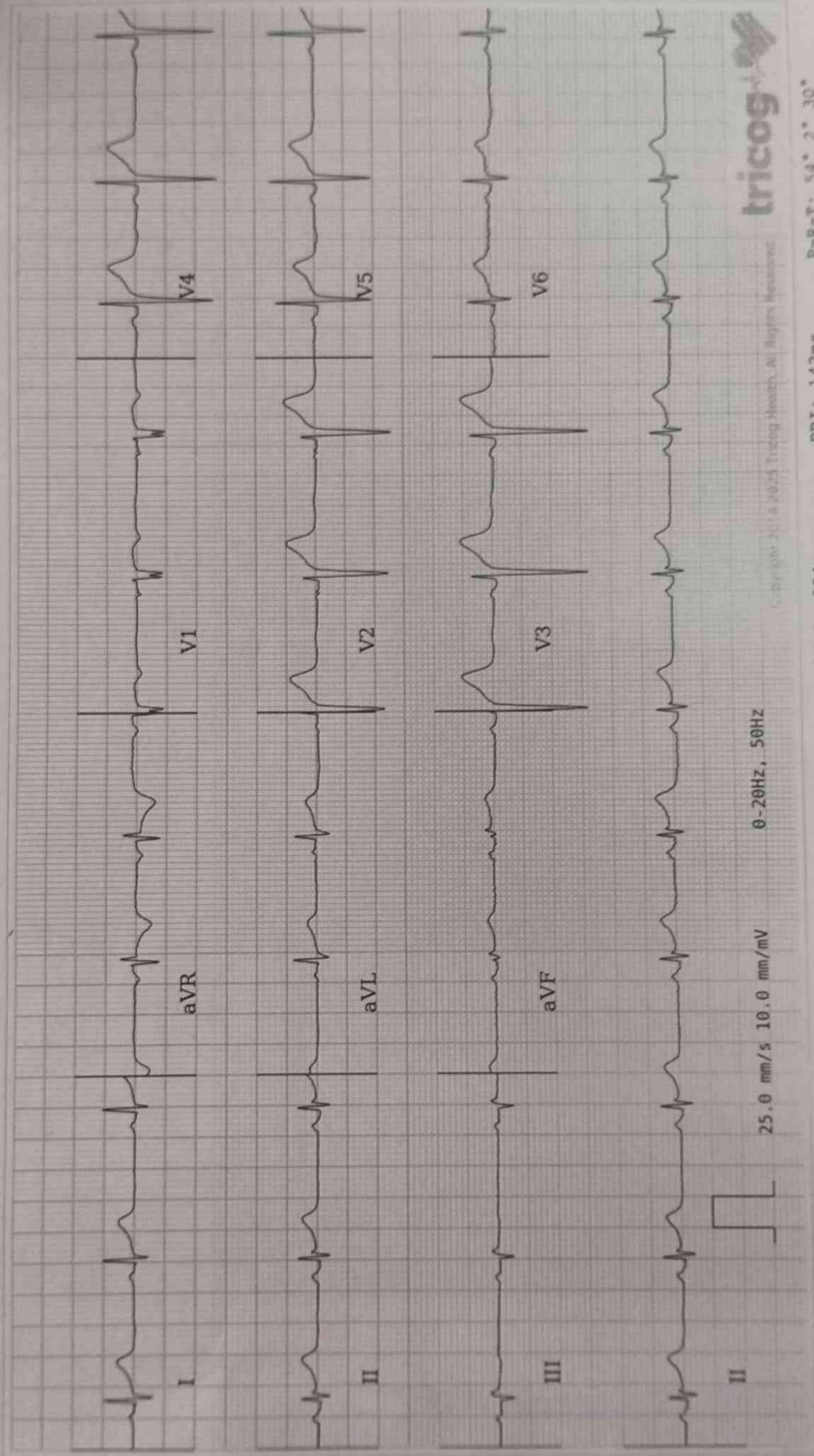
# SHREE RAM MULTI SPECIALITY HOSPITAL

Age / Gender: 51/Male

Patient ID: 25021970

Patient Name: Mr rajesh sundi

Date and Time: 7th Feb 25 9:24 AM



AR: 65 bpm

VR: 66 bpm

QRSD: 84ms

QT: 366ms

QTcB: 384ms

PRI: 142ms

P-R-T: 54° 2° 30°



**Bhawani**  
**DIAGNOSTIC CENTRE**

Near Wallfort Ozone, Fafadih Chowk,  
Raipur (C.G.) Ph.: 0771-4017333

www.bhawanidiagnostic.com




3 Tesla M.R.I.



96 Slice CT Scan



5D Color Doppler Sonography



Digital X-Ray  
O.P.G./CEPH.



Dexa-Scan/BMD



Mammography



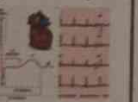Hi-Tech Pathology



EEG, EMG



Spirometry



E.C.G.



LITHOTRIPSY



Uroflowmetry

PT. NAME: MR. RAJESH SUNDI

AGE/SEX: 50 Y/M

REF. DR. BY : SHRI RAM MULTI HOS.

DATE 07/02/2025

**USG STUDY OF WHOLE ABDOMEN**

**OBSERVATIONS :**

**LIVER:-** The liver is normal in size, shape and has smooth margins. It is uniformly isoechoic, has normally distributed and normal size biliary and portal radicals and is without solid or cystic mass lesion or calcification.

**PORTAL VEIN :-** It measures normal in size & is normal in its intra & extra hepatic course . It shows normal variation in size during respiration.

**GALL BLADDER:-** The gall bladder is seen as a well distended, pear shaped bag with uniformly thin and regular walls, without, gall stones or mass lesions.

**COMMON BILE DUCT:-** The common bile duct is normal in caliber. Its measures 2.1 mm at porta hepatis. No evidence of calculus is noted in common bile duct.

**PANCREAS:-** The pancreas is normal in size, shape, contours and echotexture. No evidence of solid or cystic mass lesion is noted.

**KIDNEYS:-** The Right kidney measures: 10.2 X 4.8 cm. Normal in Size, Shape & Echotexture. No Evidence Of Calculi or hydronephrosis seen , Corticomedullary Differentiation Normal.

The Left kidney measures:- 9.8 X 4.4 cm. Normal in Size, Shape & Echotexture. No Evidence Of Calculi or hydronephrosis seen. Corticomedullary Differentiation Normal.

**URINARY BLADDER:-** The urinary bladder is well distended. It shows uniformly thin walls and sharp mucosa. No evidence of calculus is seen. No evidence of mass or diverticulum is noted.

**SPLEEN:-** The spleen is normal in size, shape. Its echotexture is homogeneous. No evidence of focal lesion is noted.

**PROSTATE:-** Appear normal in size. Normal in shape and echotexture.

\* No ASCITES, No pleural effusion.

\* No ABDOMINAL lymphadenopathy.

**IMPRESSION:-** No significant abnormality detected.

DR. UJJWALA GOSWAMI  
MD  
RADIOLOGIST & SONOLOGIST



