

Patient Name : Mr.KISHORE KOLLI RAMA	Collected : 09/Nov/2024 10:23AM
Age/Gender : 35 Y 4 M 10 D/M	Received : 09/Nov/2024 11:55AM
UHID/MR No : CKOR.0000259388	Reported : 09/Nov/2024 02:20PM
Visit ID : CKOROPV431235	Status : Final Report
Ref Doctor : Self	Sponsor Name : ARCOFEMI HEALTHCARE LIMITED
Emp/Auth/TPA ID : 22E32503	

DEPARTMENT OF HAEMATOLOGY

ARCOFEMI - MEDIWHEEL - FULL BODY ANNUAL PLUS MALE - 2D ECHO - PAN INDIA - FY2324


Test Name	Result	Unit	Bio. Ref. Interval	Method
HEMOGRAM , WHOLE BLOOD EDTA				
HAEMOGLOBIN	11.2	g/dL	13-17	Spectrophotometer
PCV	34.20	%	40-50	Electronic pulse & Calculation
RBC COUNT	5.21	Million/cu.mm	4.5-5.5	Electrical Impedence
MCV	65.7	fL	83-101	Calculated
MCH	21.5	pg	27-32	Calculated
MCHC	32.7	g/dL	31.5-34.5	Calculated
R.D.W	16.2	%	11.6-14	Calculated
TOTAL LEUCOCYTE COUNT (TLC)	4,450	cells/cu.mm	4000-10000	Electrical Impedence
DIFFERENTIAL LEUCOCYTIC COUNT (DLC)				
NEUTROPHILS	54.7	%	40-80	Electrical Impedence
LYMPHOCYTES	36.6	%	20-40	Electrical Impedence
EOSINOPHILS	1.6	%	1-6	Electrical Impedence
MONOCYTES	6.7	%	2-10	Electrical Impedence
BASOPHILS	0.4	%	<1-2	Electrical Impedence
ABSOLUTE LEUCOCYTE COUNT				
NEUTROPHILS	2434.15	Cells/cu.mm	2000-7000	Calculated
LYMPHOCYTES	1628.7	Cells/cu.mm	1000-3000	Calculated
EOSINOPHILS	71.2	Cells/cu.mm	20-500	Calculated
MONOCYTES	298.15	Cells/cu.mm	200-1000	Calculated
BASOPHILS	17.8	Cells/cu.mm	0-100	Calculated
Neutrophil lymphocyte ratio (NLR)	1.49		0.78- 3.53	Calculated
PLATELET COUNT	248000	cells/cu.mm	150000-410000	Electrical impedence
ERYTHROCYTE SEDIMENTATION RATE (ESR)	6	mm at the end of 1 hour	0-15	Modified Westegren method
PERIPHERAL SMEAR				

RBCs: Show crowding and mild anisocytosis with predominance of Microcytic hypochromic RBCs. Occasional poikilocytes like target cells are seen.

WBCs: are normal in total number with normal distribution and morphology.



Dr. Vidya Aniket Gore
M.B.B.S,M.D(Pathology)
Consultant Pathologist



Dr Priya Murthy
M.B.B.S,M.D(Pathology)
Consultant Pathologist



Patient Name : Mr.KISHORE KOLLI RAMA	Collected : 09/Nov/2024 10:23AM
Age/Gender : 35 Y 4 M 10 D/M	Received : 09/Nov/2024 11:55AM
UHID/MR No : CKOR.0000259388	Reported : 09/Nov/2024 02:20PM
Visit ID : CKOROPV431235	Status : Final Report
Ref Doctor : Self	Sponsor Name : ARCOFEMI HEALTHCARE LIMITED
Emp/Auth/TPA ID : 22E32503	

DEPARTMENT OF HAEMATOLOGY

ARCOFEMI - MEDIWHEEL - FULL BODY ANNUAL PLUS MALE - 2D ECHO - PAN INDIA - FY2324

PLATELETS: appear adequate in number.


HEMOPARASITES: negative

IMPRESSION: MICROCYTIC HYPOCHROMIC BLOOD PICTURE

Note: Kindly evaluate for incipient iron deficiency status/hemoglobinopathy.



Dr. Vidya Aniket Gore
M.B.B.S,M.D(Pathology)
Consultant Pathologist



Dr Priya Murthy
M.B.B.S,M.D(Pathology)
Consultant Pathologist

AND LIFESTYLE LIMITED- RRL BANGALORE



Patient Name : Mr.KISHORE KOLLI RAMA	Collected : 09/Nov/2024 10:23AM
Age/Gender : 35 Y 4 M 10 D/M	Received : 09/Nov/2024 11:55AM
UHID/MR No : CKOR.0000259388	Reported : 09/Nov/2024 02:57PM
Visit ID : CKOROPV431235	Status : Final Report
Ref Doctor : Self	Sponsor Name : ARCOFEMI HEALTHCARE LIMITED
Emp/Auth/TPA ID : 22E32503	

DEPARTMENT OF HAEMATOLOGY

ARCOFEMI - MEDIWHEEL - FULL BODY ANNUAL PLUS MALE - 2D ECHO - PAN INDIA - FY2324

Test Name	Result	Unit	Bio. Ref. Interval	Method
BLOOD GROUP ABO AND RH FACTOR , WHOLE BLOOD EDTA				
BLOOD GROUP TYPE	AB			Microplate Hemagglutination
Rh TYPE	Positive			Microplate Hemagglutination



Dr. Vidya Aniket Gore
M.B.B.S,M.D(Pathology)
Consultant Pathologist



Dr Priya Murthy
M.B.B.S,M.D(Pathology)
Consultant Pathologist

AND LIFESTYLE LIMITED- RRL BANGALORE



Patient Name : Mr.KISHORE KOLLI RAMA	Collected : 09/Nov/2024 01:28PM
Age/Gender : 35 Y 4 M 10 D/M	Received : 09/Nov/2024 05:29PM
UHID/MR No : CKOR.0000259388	Reported : 09/Nov/2024 05:58PM
Visit ID : CKOROPV431235	Status : Final Report
Ref Doctor : Self	Sponsor Name : ARCOFEMI HEALTHCARE LIMITED
Emp/Auth/TPA ID : 22E32503	

DEPARTMENT OF BIOCHEMISTRY

ARCOFEMI - MEDIWHEEL - FULL BODY ANNUAL PLUS MALE - 2D ECHO - PAN INDIA - FY2324

Test Name	Result	Unit	Bio. Ref. Interval	Method
GLUCOSE, FASTING , NAF PLASMA	90	mg/dL	70-100	HEXOKINASE

Comment:

As per American Diabetes Guidelines, 2023

Fasting Glucose Values in mg/dL	Interpretation
70-100 mg/dL	Normal
100-125 mg/dL	Prediabetes
≥126 mg/dL	Diabetes
<70 mg/dL	Hypoglycemia


Note:

- 1.The diagnosis of Diabetes requires a fasting plasma glucose of > or = 126 mg/dL and/or a random / 2 hr post glucose value of > or = 200 mg/dL on at least 2 occasions.
2. Very high glucose levels (>450 mg/dL in adults) may result in Diabetic Ketoacidosis & is considered critical.

Test Name	Result	Unit	Bio. Ref. Interval	Method
GLUCOSE, POST PRANDIAL (PP), 2 HOURS , SODIUM FLUORIDE PLASMA (2 HR)	93	mg/dL	70-140	HEXOKINASE

Comment:

It is recommended that FBS and PPBS should be interpreted with respect to their Biological reference ranges and not with each other. Conditions which may lead to lower postprandial glucose levels as compared to fasting glucose levels may be due to reactive hypoglycemia, dietary meal content, duration or timing of sampling after food digestion and absorption, medications such as insulin preparations, sulfonylureas, amylin analogues, or conditions such as overproduction of insulin.


Dr Priya Murthy
M.B.B.S.,M.D(Pathology)
Consultant Pathologist



Patient Name : Mr.KISHORE KOLLI RAMA	Collected : 09/Nov/2024 10:23AM
Age/Gender : 35 Y 4 M 10 D/M	Received : 09/Nov/2024 12:08PM
UHID/MR No : CKOR.0000259388	Reported : 09/Nov/2024 01:25PM
Visit ID : CKOROPV431235	Status : Final Report
Ref Doctor : Self	Sponsor Name : ARCOFEMI HEALTHCARE LIMITED
Emp/Auth/TPA ID : 22E32503	

DEPARTMENT OF BIOCHEMISTRY

ARCOFEMI - MEDIWHEEL - FULL BODY ANNUAL PLUS MALE - 2D ECHO - PAN INDIA - FY2324

Test Name	Result	Unit	Bio. Ref. Interval	Method
HBA1C (GLYCATED HEMOGLOBIN) , WHOLE BLOOD EDTA				
HBA1C, GLYCATED HEMOGLOBIN	6.1	%		HPLC
ESTIMATED AVERAGE GLUCOSE (eAG)	128	mg/dL		Calculated

Comment:

Reference Range as per American Diabetes Association (ADA) 2023 Guidelines:

REFERENCE GROUP	HBA1C %
NON DIABETIC	<5.7
PREDIABETES	5.7 – 6.4
DIABETES	≥ 6.5
DIABETICS	
EXCELLENT CONTROL	6 – 7
FAIR TO GOOD CONTROL	7 – 8
UNSATISFACTORY CONTROL	8 – 10
POOR CONTROL	>10

Note: Dietary preparation or fasting is not required.

1. HbA1c is recommended by American Diabetes Association for Diagnosing Diabetes and monitoring Glycemic Control by American Diabetes Association guidelines 2023.

2. Trends in HbA1c values is a better indicator of Glycemic control than a single test.

3. Low HbA1c in Non-Diabetic patients are associated with Anemia (Iron Deficiency/Hemolytic), Liver Disorders, Chronic Kidney Disease. Clinical Correlation is advised in interpretation of low Values.


4. Falsely low HbA1c (below 4%) may be observed in patients with clinical conditions that shorten erythrocyte life span or decrease mean erythrocyte age. HbA1c may not accurately reflect glycemic control when clinical conditions that affect erythrocyte survival are present.


5. In cases of Interference of Hemoglobin variants in HbA1c, alternative methods (Fructosamine) estimation is recommended for Glycemic Control

A: HbF >25%

B: Homozygous Hemoglobinopathy.

(Hb Electrophoresis is recommended method for detection of Hemoglobinopathy)


Dr. Govinda Raju N L
 MSc, PhD (Biochemistry)
 Consultant Biochemistry


Dr Priya Murthy
 M.B.B.S, M.D (Pathology)
 Consultant Pathologist



THIS TEST HAS BEEN PERFORMED AT APOLLO HEALTH AND LIFESTYLE LIMITED- RRL BANGALORE
 SIN No: KOR241100556

Apollo Health and Lifestyle Limited

(CIN - U06110TC2000PHG115819)

This test has been performed at Apollo Health & Lifestyle Ltd, RRL BANGALORE Laboratory,
 Regd. Office: 1-10-60/62, Ashoka Raghupathi Chambers, 5th Floor, Begumpet, Hyderabad, Telangana - 500 016 |

www.apollohl.com | Email ID: enquiry@apollohl.com, Ph No: 040-4904 7777, Fax No: 4904 7744

Address:
 32, 4th/125, Doddabangla Village, Neeladri Main Road,
 Neeladri Nagar, Electronic city, Bengaluru,
 Karnataka - 560034


1860 500 7788
 www.apolloclinic.com

APOLLO CLINICS NETWORK

Telangana: Hyderabad (AS Rao Nagar | Chanda Nagar | Kondapur | Nallakunta | Nizampet | Manikonda | Uppal) | Andhra Pradesh: Vizag (Seethamma Peta) | Karnataka: Bangalore (Basavanagudi | Bellandur | Electronics City | Fraser Town | HSR Layout | Indira Nagar | JP Nagar | Kundalahalli | Koramangala | Sarjapur Road) | Mysore (VV Mohalla) | Tamilnadu: Chennai (Annanagar | Kotturpuram | Mogappair | T Nagar | Valasaravakkam | Velachery) | Maharashtra: Pune (Aundh | Nigdi Pradhikaran | Viman Nagar | Wanowrie) | Uttar Pradesh: Ghaziabad (Indrapuram) | Gujarat: Ahmedabad (Satellite) | Punjab: Amritsar (Court Road) | Haryana: Faridabad (Railway Station Road)

Patient Name : Mr.KISHORE KOLLI RAMA	Collected : 09/Nov/2024 10:23AM
Age/Gender : 35 Y 4 M 10 D/M	Received : 09/Nov/2024 12:42PM
UHID/MR No : CKOR.0000259388	Reported : 09/Nov/2024 03:18PM
Visit ID : CKOROPV431235	Status : Final Report
Ref Doctor : Self	Sponsor Name : ARCOFEMI HEALTHCARE LIMITED
Emp/Auth/TPA ID : 22E32503	

DEPARTMENT OF BIOCHEMISTRY


ARCOFEMI - MEDIWHEEL - FULL BODY ANNUAL PLUS MALE - 2D ECHO - PAN INDIA - FY2324


Test Name	Result	Unit	Bio. Ref. Interval	Method
LIPID PROFILE , SERUM				
TOTAL CHOLESTEROL	195	mg/dL	<200	CHO-POD
TRIGLYCERIDES	63	mg/dL	<150	GPO-POD
HDL CHOLESTEROL	38	mg/dL	40-60	Enzymatic Immunoinhibition
NON-HDL CHOLESTEROL	157	mg/dL	<130	Calculated
LDL CHOLESTEROL	144.8	mg/dL	<100	Calculated
VLDL CHOLESTEROL	12.6	mg/dL	<30	Calculated
CHOL / HDL RATIO	5.14		0-4.97	Calculated
ATHEROGENIC INDEX (AIP)	< 0.01		<0.11	Calculated

Comment:

Reference Interval as per National Cholesterol Education Program (NCEP) Adult Treatment Panel III Report.

	Desirable	Borderline High	High	Very High
TOTAL CHOLESTEROL	< 200	200 - 239	≥ 240	
TRIGLYCERIDES	<150	150 - 199	200 - 499	≥ 500
LDL	Optimal < 100 Near Optimal 100-129	130 - 159	160 - 189	≥ 190
HDL	≥ 60			
NON-HDL CHOLESTEROL	Optimal <130; Above Optimal 130-159	160-189	190-219	>220


Dr. Govinda Raju N L
 MSc, PhD (Biochemistry)
 Consultant Biochemistry


Dr Priya Murthy
 M.B.B.S, M.D (Pathology)
 Consultant Pathologist



THIS TEST HAS BEEN PERFORMED AT APOLLO HEALTH AND LIFESTYLE LIMITED- RRL BANGALORE
 SIN No: KOR241100554

Apollo Health and Lifestyle Limited (CIN - U06110TC2000PH6115819)
 Regd. Office: 1-10-60/62, Ashoka Raghupathi Chambers, 5th Floor, Begumpet, Hyderabad, Telangana - 500 016 |
 www.apollohl.com | Email ID: enquiry@apollohl.com, Ph No: 040-4904 7777, Fax No: 4904 7744

Address:
 32, 100/125, Doddabangla Village, Neeladri Main Road,
 Neeladri Nagar, Electronic city, Bengaluru,
 Karnataka - 560034


1860 500 7788
 www.apolloclinic.com

APOLLO CLINICS NETWORK
 Telangana: Hyderabad (AS Rao Nagar | Chanda Nagar | Kondapur | Nallakunta | Nizampet | Manikonda | Uppal) | Andhra Pradesh: Vizag (Seethamma Peta) | Karnataka: Bangalore (Basavanagudi | Bellandur | Electronics City | Fraser Town | HSR Layout | Indira Nagar | JP Nagar | Kundalahalli | Koramangala | Sarjapur Road) | Mysore (VV Mohalla) | Tamilnadu: Chennai (Annanagar | Kotturpuram | Mogappair | T Nagar | Valasaravakkam | Velachery) | Maharashtra: Pune (Aundh | Nigdi Pradhikaran | Viman Nagar | Wanowrie) | Uttar Pradesh: Ghaziabad (Indrapuram) | Gujarat: Ahmedabad (Satellite) | Punjab: Amritsar (Court Road) | Haryana: Faridabad (Railway Station Road)

Patient Name : Mr.KISHORE KOLLI RAMA	Collected : 09/Nov/2024 10:23AM
Age/Gender : 35 Y 4 M 10 D/M	Received : 09/Nov/2024 12:42PM
UHID/MR No : CKOR.0000259388	Reported : 09/Nov/2024 03:18PM
Visit ID : CKOROPV431235	Status : Final Report
Ref Doctor : Self	Sponsor Name : ARCOFEMI HEALTHCARE LIMITED
Emp/Auth/TPA ID : 22E32503	

DEPARTMENT OF BIOCHEMISTRY

ARCOFEMI - MEDIWHEEL - FULL BODY ANNUAL PLUS MALE - 2D ECHO - PAN INDIA - FY2324

Test Name	Result	Unit	Bio. Ref. Interval	Method
LIVER FUNCTION TEST (LFT) , SERUM				
BILIRUBIN, TOTAL	1.64	mg/dL	0.3-1.2	DPD
BILIRUBIN CONJUGATED (DIRECT)	0.25	mg/dL	<0.2	DPD
BILIRUBIN (INDIRECT)	1.39	mg/dL	0.0-1.1	Dual Wavelength
ALANINE AMINOTRANSFERASE (ALT/SGPT)	15	U/L	<50	IFCC
ASPARTATE AMINOTRANSFERASE (AST/SGOT)	16.0	U/L	<50	IFCC
AST (SGOT) / ALT (SGPT) RATIO (DE RITIS)	1.1		<1.15	Calculated
ALKALINE PHOSPHATASE	86.00	U/L	30-120	IFCC
PROTEIN, TOTAL	7.07	g/dL	6.6-8.3	Biuret
ALBUMIN	4.88	g/dL	3.5-5.2	BROMO CRESOL GREEN
GLOBULIN	2.19	g/dL	2.0-3.5	Calculated
A/G RATIO	2.23		0.9-2.0	Calculated

Comment:

LFT results reflect different aspects of the health of the liver, i.e., hepatocyte integrity (AST & ALT), synthesis and secretion of bile (Bilirubin, ALP), cholestasis (ALP, GGT), protein synthesis (Albumin) Common patterns seen:


1. Hepatocellular Injury:


*AST – Elevated levels can be seen. However, it is not specific to liver and can be raised in cardiac and skeletal injuries.*ALT – Elevated levels indicate hepatocellular damage. It is considered to be most specific lab test for hepatocellular injury. Values also correlate well with increasing BMI. Disproportionate increase in AST, ALT compared with ALP. AST: ALT (ratio) – In case of hepatocellular injury AST: ALT > 1 In Alcoholic Liver Disease AST: ALT usually >2. This ratio is also seen to be increased in NAFLD, Wilsons’s diseases, Cirrhosis, but the increase is usually not >2.

2. Cholestatic Patten:*ALP – Disproportionate increase in ALP compared with AST, ALT. ALP elevation also seen in pregnancy, impacted by age and sex.*Bilirubin elevated- predominantly direct , To establish the hepatic origin correlation with elevated GGT helps.

3. Synthetic function impairment:*Albumin- Liver disease reduces albumin levels, Correlation with PT (Prothrombin Time) helps.

4. Associated tests for assessment of liver fibrosis - Fibrosis-4 and APRI Index.


Dr.Govinda Raju N L
MSc,PhD(Biochemistry)
Consultant Biochemistry


Dr Priya Murthy
M.B.B.S,M.D(Pathology)
Consultant Pathologist



THIS TEST HAS BEEN PERFORMED AT APOLLO HEALTH AND LIFESTYLE LIMITED- RRL BANGALORE
SIN No:KOR241100554

Apollo Health and Lifestyle Limited (CIN - U06110TC2000PH6115839)
This test has been performed at Apollo Health & Lifestyle Ltd, RRL BANGALORE Laboratory
Regd. Office: 1-10-60/62, Ashoka Raghupathi Chambers, 5th Floor, Begumpet, Hyderabad, Telangana - 500 016 |
www.apollohl.com | Email ID: enquiry@apollohl.com, Ph No: 040-4904 7777, Fax No: 4904 7744


Address:
32/100/125, Doddabangla Village, Neeladri Main Road,
Neeladri Nagar, Electronic city, Bengaluru,
Karnataka- 560034


Patient Name : Mr.KISHORE KOLLI RAMA	Collected : 09/Nov/2024 10:23AM
Age/Gender : 35 Y 4 M 10 D/M	Received : 09/Nov/2024 12:42PM
UHID/MR No : CKOR.0000259388	Reported : 09/Nov/2024 03:18PM
Visit ID : CKOROPV431235	Status : Final Report
Ref Doctor : Self	Sponsor Name : ARCOFEMI HEALTHCARE LIMITED
Emp/Auth/TPA ID : 22E32503	

DEPARTMENT OF BIOCHEMISTRY

ARCOFEMI - MEDIWHEEL - FULL BODY ANNUAL PLUS MALE - 2D ECHO - PAN INDIA - FY2324

Test Name	Result	Unit	Bio. Ref. Interval	Method
RENAL PROFILE/KIDNEY FUNCTION TEST (RFT/KFT) , SERUM				
CREATININE	0.86	mg/dL	0.84 - 1.25	Modified Jaffe, Kinetic
UREA	17.70	mg/dL	17-43	GLDH, Kinetic Assay
BLOOD UREA NITROGEN	8.3	mg/dL	8.0 - 23.0	Calculated
URIC ACID	5.59	mg/dL	3.5-7.2	Uricase PAP
CALCIUM	9.70	mg/dL	8.8-10.6	Arsenazo III
PHOSPHORUS, INORGANIC	3.65	mg/dL	2.5-4.5	Phosphomolybdate Complex
SODIUM	139	mmol/L	136-146	ISE (Indirect)
POTASSIUM	3.9	mmol/L	3.5-5.1	ISE (Indirect)
CHLORIDE	106	mmol/L	101-109	ISE (Indirect)
PROTEIN, TOTAL	7.07	g/dL	6.6-8.3	Biuret
ALBUMIN	4.88	g/dL	3.5-5.2	BROMO CRESOL GREEN
GLOBULIN	2.19	g/dL	2.0-3.5	Calculated
A/G RATIO	2.23		0.9-2.0	Calculated


Dr. Govinda Raju N L
 MSc, PhD (Biochemistry)
 Consultant Biochemistry


Dr Priya Murthy
 M.B.B.S, M.D (Pathology)
 Consultant Pathologist



THIS TEST HAS BEEN PERFORMED AT APOLLO HEALTH AND LIFESTYLE LIMITED- RRL BANGALORE
 SIN No: KOR241100554

Apollo Health and Lifestyle Limited

(CIN - U06110TC2800PHG115819)
 Regd. Office: 1-10-60/62, Ashoka Raghupathi Chambers, 5th Floor, Begumpet, Hyderabad, Telangana - 500 016 |
 www.apollohl.com | Email ID: enquiry@apollohl.com, Ph No: 040-4904 7777, Fax No: 4904 7744

Address:
 32/100/125, Doddabangla Village, Neeladri Main Road,
 Neeladri Nagar, Electronic city, Bengaluru,
 Karnataka - 560034


1860 500 7788
 www.apolloclinic.com

Patient Name : Mr.KISHORE KOLLI RAMA	Collected : 09/Nov/2024 10:23AM
Age/Gender : 35 Y 4 M 10 D/M	Received : 09/Nov/2024 12:42PM
UHID/MR No : CKOR.0000259388	Reported : 09/Nov/2024 02:34PM
Visit ID : CKOROPV431235	Status : Final Report
Ref Doctor : Self	Sponsor Name : ARCOFEMI HEALTHCARE LIMITED
Emp/Auth/TPA ID : 22E32503	

DEPARTMENT OF BIOCHEMISTRY

ARCOFEMI - MEDIWHEEL - FULL BODY ANNUAL PLUS MALE - 2D ECHO - PAN INDIA - FY2324

Test Name	Result	Unit	Bio. Ref. Interval	Method
GAMMA GLUTAMYL TRANSPEPTIDASE (GGT) , SERUM	17.00	U/L	<55	IFCC

Priya Murthy

Dr Priya Murthy
M.B.B.S.,M.D(Pathology)
Consultant Pathologist



Patient Name : Mr.KISHORE KOLLI RAMA	Collected : 09/Nov/2024 10:23AM
Age/Gender : 35 Y 4 M 10 D/M	Received : 09/Nov/2024 12:42PM
UHID/MR No : CKOR.0000259388	Reported : 09/Nov/2024 01:37PM
Visit ID : CKOROPV431235	Status : Final Report
Ref Doctor : Self	Sponsor Name : ARCOFEMI HEALTHCARE LIMITED
Emp/Auth/TPA ID : 22E32503	

DEPARTMENT OF IMMUNOLOGY

ARCOFEMI - MEDIWHEEL - FULL BODY ANNUAL PLUS MALE - 2D ECHO - PAN INDIA - FY2324


Test Name	Result	Unit	Bio. Ref. Interval	Method
THYROID PROFILE TOTAL (T3, T4, TSH) , SERUM				
TRI-IODOTHYRONINE (T3, TOTAL)	1.96	ng/mL	0.7-2.04	CLIA
THYROXINE (T4, TOTAL)	9.46	µg/dL	5.48-14.28	CLIA
THYROID STIMULATING HORMONE (TSH)	3.421	µIU/mL	0.34-5.60	CLIA


Comment:

For pregnant females	Bio Ref Range for TSH in uIU/ml (As per American Thyroid Association)
First trimester	0.1 - 2.5
Second trimester	0.2 – 3.0
Third trimester	0.3 – 3.0

- TSH is a glycoprotein hormone secreted by the anterior pituitary. TSH activates production of T3 (Triiodothyronine) and its prohormone T4 (Thyroxine). Increased blood level of T3 and T4 inhibit production of TSH.
- TSH is elevated in primary hypothyroidism and will be low in primary hyperthyroidism. Elevated or low TSH in the context of normal free thyroxine is often referred to as sub-clinical hypo- or hyperthyroidism respectively.
- Both T4 & T3 provides limited clinical information as both are highly bound to proteins in circulation and reflects mostly inactive hormone. Only a very small fraction of circulating hormone is free and biologically active.
- Significant variations in TSH can occur with circadian rhythm, hormonal status, stress, sleep deprivation, medication & circulating antibodies.

TSH	T3	T4	FT4	Conditions
High	Low	Low	Low	Primary Hypothyroidism, Post Thyroidectomy, Chronic Autoimmune Thyroiditis
High	N	N	N	Subclinical Hypothyroidism, Autoimmune Thyroiditis, Insufficient Hormone Treatment.
N/Low	Low	Low	Low	Secondary and Tertiary Hypothyroidism
Low	High	High	High	Primary Hyperthyroidism, Goitre, Thyroiditis, Drug effects, Early Pregnancy
Low	N	N	N	Subclinical Hyperthyroidism
Low	Low	Low	Low	Central Hypothyroidism, Treatment with Hyperthyroidism
Low	N	High	High	Thyroiditis, Interfering Antibodies
N/Low	High	N	N	T3 Thyrotoxicosis, Non thyroidal causes


Dr. Govinda Raju N L
 MSc, PhD (Biochemistry)
 Consultant Biochemistry


Dr Priya Murthy
 M.B.B.S, M.D (Pathology)
 Consultant Pathologist



THIS TEST HAS BEEN PERFORMED AT APOLLO HEALTH AND LIFESTYLE LIMITED- RRL BANGALORE
 SIN No: KOR241100558

Apollo Health and Lifestyle Limited (CIN - U061107C2800PH6115819)
 This test has been performed at Apollo Health & Lifestyle Ltd, RRL BANGALORE Laboratory
 Regd. Office: 1-10-60/62, Ashoka Raghupathi Chambers, 5th Floor, Begumpet, Hyderabad, Telangana - 500 016 |
 www.apollohl.com | Email ID: enquiry@apollohl.com, Ph No: 040-4904 7777, Fax No: 4904 7744

Address:
 32/100/125, Doddabangal Village, Neeladri Main Road,
 Neeladri Nagar, Electronic city, Bengaluru,
 Karnataka - 560034


1860 500 7788
 www.apolloclinic.com

Patient Name : Mr.KISHORE KOLLI RAMA	Collected : 09/Nov/2024 10:23AM
Age/Gender : 35 Y 4 M 10 D/M	Received : 09/Nov/2024 12:42PM
UHID/MR No : CKOR.0000259388	Reported : 09/Nov/2024 01:37PM
Visit ID : CKOROPV431235	Status : Final Report
Ref Doctor : Self	Sponsor Name : ARCOFEMI HEALTHCARE LIMITED
Emp/Auth/TPA ID : 22E32503	

DEPARTMENT OF IMMUNOLOGY

ARCOFEMI - MEDIWHEEL - FULL BODY ANNUAL PLUS MALE - 2D ECHO - PAN INDIA - FY2324

High	High	High	High	Pituitary Adenoma; TSHoma/Thyrotropinoma
------	------	------	------	--

Govinda Raju
Dr.Govinda Raju N L
 MSc,PhD(Biochemistry)
 Consultant Biochemistry

Priya Murthy
Dr Priya Murthy
 M.B.B.S,M.D(Pathology)
 Consultant Pathologist



THIS TEST HAS BEEN PERFORMED AT APOLLO HEALTH AND LIFESTYLE LIMITED- RRL BANGALORE
 SIN No:KOR241100558

Apollo Health and Lifestyle Limited

(CIN - U06110TC2800PHG115819)
 Regd. Office: 1-10-60/62, Ashoka Raghupathi Chambers, 5th Floor, Begumpet, Hyderabad, Telangana - 500 016 |
 www.apollohl.com | Email ID: enquiry@apollohl.com, Ph No: 040-4904 7777, Fax No: 4904 7744

Address:
 32/100/125, Doddabangla Village, Neeladri Main Road,
 Neeladri Nagar, Electronic city, Bengaluru,
 Karnataka- 560034

 **1860 500 7788**
www.apolloclinic.com

Patient Name : Mr.KISHORE KOLLI RAMA	Collected : 09/Nov/2024 10:23AM
Age/Gender : 35 Y 4 M 10 D/M	Received : 09/Nov/2024 01:49PM
UHID/MR No : CKOR.0000259388	Reported : 09/Nov/2024 02:18PM
Visit ID : CKOROPV431235	Status : Final Report
Ref Doctor : Self	Sponsor Name : ARCOFEMI HEALTHCARE LIMITED
Emp/Auth/TPA ID : 22E32503	


DEPARTMENT OF CLINICAL PATHOLOGY

ARCOFEMI - MEDIWHEEL - FULL BODY ANNUAL PLUS MALE - 2D ECHO - PAN INDIA - FY2324

Test Name	Result	Unit	Bio. Ref. Interval	Method
COMPLETE URINE EXAMINATION (CUE) , URINE				
PHYSICAL EXAMINATION				
COLOUR	YELLOW		PALE YELLOW	Visual
TRANSPARENCY	CLEAR		CLEAR	Physical Measurement
pH	6.5		5-7.5	Double Indicator
SP. GRAVITY	1.005		1.002-1.030	Bromothymol Blue
BIOCHEMICAL EXAMINATION				
URINE PROTEIN	NEGATIVE		NEGATIVE	Protein Error Of Indicator
GLUCOSE	NEGATIVE		NEGATIVE	Glucose Oxidase
URINE BILIRUBIN	NEGATIVE		NEGATIVE	Azo Coupling Reaction
URINE KETONES (RANDOM)	NEGATIVE		NEGATIVE	Sodium Nitro Prusside
UROBILINOGEN	NORMAL		NORMAL	Modified Ehrlich Reaction
NITRITE	NEGATIVE		NEGATIVE	Diazotization
LEUCOCYTE ESTERASE	NEGATIVE		NEGATIVE	Leucocyte Esterase
CENTRIFUGED SEDIMENT WET MOUNT AND MICROSCOPY				
PUS CELLS	2-3	/hpf	0-5	Microscopy
EPITHELIAL CELLS	1-2	/hpf	<10	Microscopy
RBC	NIL	/hpf	0-2	Microscopy
CASTS	NIL		0-2 Hyaline Cast	Microscopy
CRYSTALS	ABSENT		ABSENT	Microscopy

Comment:

All urine samples are checked for adequacy and suitability before examination. All abnormal chemical examination are rechecked and verified by manual methods. Microscopy findings are reported as an average of 10 high power fields.


Dr. Rajalakshmi D
 M.B.B.S,M.D
 Consultant Pathologist


Dr. Vidya Aniket Gore
 M.B.B.S,M.D(Pathology)
 Consultant Pathologist



THIS TEST HAS BEEN PERFORMED AT APOLLO HEALTH

Apollo Health and Lifestyle Limited (CIN - 063110132000PLC115017)
 5th Floor, Begumpet, Hyderabad, Telangana - 500 016 |
 Bangalore - 560 034 | Chennai - 600 034 | Kolkata - 700 034
 www.apollohl.com | Email ID: enquiry@apollohl.com, Ph No: 040-4904 7777, Fax No: 4904 7744

Address:
 323/100/123, Doddathangur Village, Neeladri Main Road,
 Neeladri Nagar, Electronic city, Bengaluru,
 Karnataka - 560 034


1860 500 7788
 www.apolloclinic.com


APOLLO CLINICS NETWORK
 Telangana: Hyderabad (AS Rao Nagar | Chanda Nagar | Kondapur | Nallakunta | Nizampet | Manikonda | Uppal) | Andhra Pradesh: Vizag (Seethamma Peta) | Karnataka: Bangalore (Basavanagudi | Bellandur | Electronics City | Fraser Town | HSR Layout | Indira Nagar | JP Nagar | Kundalahalli | Koramangala | Sarjapur Road) | Mysore (VV Mohalla) | Tamilnadu: Chennai (Annanagar | Kotturpuram | Mogappair | T Nagar | Valasaravakkam | Velachery) | Maharashtra: Pune (Aundh | Nigdi Pradhikaran | Viman Nagar | Wanowrie) | Uttar Pradesh: Ghaziabad (Indrapuram) | Gujarat: Ahmedabad (Satellite) | Punjab: Amritsar (Court Road) | Haryana: Faridabad (Railway Station Road)

Patient Name : Mr.KISHORE KOLLI RAMA	Collected : 09/Nov/2024 01:28PM
Age/Gender : 35 Y 4 M 10 D/M	Received : 09/Nov/2024 04:44PM
UHID/MR No : CKOR.0000259388	Reported : 09/Nov/2024 06:10PM
Visit ID : CKOROPV431235	Status : Final Report
Ref Doctor : Self	Sponsor Name : ARCOFEMI HEALTHCARE LIMITED
Emp/Auth/TPA ID : 22E32503	

DEPARTMENT OF CLINICAL PATHOLOGY

ARCOFEMI - MEDIWHEEL - FULL BODY ANNUAL PLUS MALE - 2D ECHO - PAN INDIA - FY2324

Test Name	Result	Unit	Bio. Ref. Interval	Method
URINE GLUCOSE(POST PRANDIAL)	NEGATIVE		NEGATIVE	GOD-POD


Dr. Rajalakshmi D
 M.B.B.S,M.D
 Consultant Pathologist


Dr. Vidya Aniket Gore
 M.B.B.S,M.D(Pathology)
 Consultant Pathologist



THIS TEST HAS BEEN PERFORMED AT APOLLO HEALTH

Apollo Health and Lifestyle Limited (CIN - 063110132000FL115017)
 Registered Office: 16/02/14/006/14thi Chambers, 5th Floor, Begumpet, Hyderabad, Telangana - 500 016 |
 www.apollohl.com | Email ID: enquiry@apollohl.com, Ph No: 040-4904 7777, Fax No: 4904 7744
 APOLLO CLINICS NETWORK

Address:
 323/100/123, Doddathangur Village, Neeladri Main Road,
 Neeladri Nagar, Electronic city, Bengaluru,
 Karnataka - 560034


1860 500 7788
 www.apolloclinic.com

Telangana: Hyderabad (AS Rao Nagar | Chanda Nagar | Kondapur | Nallakunta | Nizampet | Manikonda | Uppal) | Andhra Pradesh: Vizag (Seethamma Peta) | Karnataka: Bangalore (Basavanagudi | Bellandur | Electronics City | Fraser Town | HSR Layout | Indira Nagar | JP Nagar | Kundalahalli | Koramangala | Sarjapur Road) | Mysore (VV Mohalla) | Tamilnadu: Chennai (Annanagar | Kotturpuram | Mogappair | T Nagar | Valasaravakkam | Velachery) | Maharashtra: Pune (Aundh | Nigdi Pradhikaran | Viman Nagar | Wanowrie) | Uttar Pradesh: Ghaziabad (Indrapuram) | Gujarat: Ahmedabad (Satellite) | Punjab: Amritsar (Court Road) | Haryana: Faridabad (Railway Station Road)

Patient Name : Mr.KISHORE KOLLI RAMA	Collected : 09/Nov/2024 10:23AM
Age/Gender : 35 Y 4 M 10 D/M	Received : 09/Nov/2024 01:49PM
UHID/MR No : CKOR.0000259388	Reported : 09/Nov/2024 03:20PM
Visit ID : CKOROPV431235	Status : Final Report
Ref Doctor : Self	Sponsor Name : ARCOFEMI HEALTHCARE LIMITED
Emp/Auth/TPA ID : 22E32503	

DEPARTMENT OF CLINICAL PATHOLOGY

ARCOFEMI - MEDIWHEEL - FULL BODY ANNUAL PLUS MALE - 2D ECHO - PAN INDIA - FY2324


Test Name	Result	Unit	Bio. Ref. Interval	Method
URINE GLUCOSE(FASTING)	NEGATIVE		NEGATIVE	GOD-POD

*** End Of Report ***

Result/s to Follow:
PERIPHERAL SMEAR



Dr. Vidya Aniket Gore
M.B.B.S,M.D(Pathology)
Consultant Pathologist



Dr Priya Murthy
M.B.B.S,M.D(Pathology)
Consultant Pathologist

AND LIFESTYLE LIMITED- RRL BANGALORE



Patient Name : Mr.KISHORE KOLLI RAMA
Age/Gender : 35 Y 4 M 10 D/M
UHID/MR No : CKOR.0000259388
Visit ID : CKOROPV431235
Ref Doctor : Self
Emp/Auth/TPA ID : 22E32503


Collected : 09/Nov/2024 10:23AM
Received : 09/Nov/2024 01:49PM
Reported : 09/Nov/2024 03:20PM
Status : Final Report
Sponsor Name : ARCOFEMI HEALTHCARE LIMITED

TERMS AND CONDITIONS GOVERNING THIS REPORT

1. Reported results are for information and interpretation of the referring doctor or such other medical professionals, who understand reporting units, reference ranges and limitation of technologies. Laboratories not be responsible for any interpretation whatsoever.
2. It is presumed that the tests performed are, on the specimen / sample being to the patient named or identified and the verifications of particulars have been confirmed by the patient or his / her representative at the point of generation of said specimen.
3. The reported results are restricted to the given specimen only. Results may vary from lab to lab and from time to time for the same parameter for the same patient (within subject biological variation).
4. The patient details along with their results in certain cases like notifiable diseases and as per local regulatory requirements will be communicated to the assigned regulatory bodies.
5. The patient samples can be used as part of internal quality control, test verification, data analysis purposes within the testing scope of the laboratory.
6. This report is not valid for medico legal purposes. It is performed to facilitate medical diagnosis only.



Dr. Vidya Aniket Gore
M.B.B.S,M.D(Pathology)
Consultant Pathologist



Dr Priya Murthy
M.B.B.S,M.D(Pathology)
Consultant Pathologist

AND LIFESTYLE LIMITED- RRL BANGALORE



Regd. Office: 104, CKOR 244 0055thi Chambers, 5th Floor, Begumpet, Hyderabad, Telangana - 500 016 |
www.apollohl.com | Email ID: enquiry@apollohl.com, Ph No: 040-4904 7777, Fax No: 4904 7744

This test has been performed at Apollo Health & Lifestyle Ltd, RRL BANGALORE Laboratory

APOLLO CLINICS NETWORK
Telangana: Hyderabad (AS Rao Nagar | Chanda Nagar | Kondapur | Nallakunta | Nizampet | Manikonda | Uppal) | Andhra Pradesh: Vizag (Seethamma Peta) | Karnataka: Bangalore (Basavanagudi | Bellandur | Electronics City | Fraser Town | HSR Layout | Indira Nagar | JP Nagar | Kundalahalli | Koramangala | Sarjapur Road) | Mysore (VV Mohalla) | Tamilnadu: Chennai (Annanagar | Kotturpuram | Mogappair | T Nagar) | Valasaravakkam | Velachery | Maharashtra: Pune (Aundh | Nigdi Pradhikaran | Viman Nagar | Wanowrie) | Uttar Pradesh: Ghazalabad (Indrapuram) | Gujarat: Ahmedabad (Satellite) | Punjab: Amritsar (Court Road) | Haryana: Faridabad (Railway Station Road)

Address:
323/100/123, Doddathangur Village, Neeladri Main Road,
Neeladri Nagar, Electronic city, Bengaluru,
Karnataka - 560034



Patient Name	: Mr. KISHORE KOLLI RAMA	Age	: 35Yrs 4Mths 11Days
UHID	: CKOR.0000259388	OP Visit No.	: CKOROPV431235
Printed On	: 09-11-2024 06:03 AM	Advised/Pres Doctor	: --
Department	: Radiology	Qualification	: --
Referred By	: Self	Registration No.	: --
Employer Id	: 22E32503		

DEPARTMENT OF RADIOLOGY

ULTRASOUND ABDOMEN AND PELVIS

FINDINGS:

Liver is normal in size and shows a normal echotexture. No biliary dilatation. No focal lesion

CBD is not dilated.

Portal vein is normal in size, course and calibre.

Gall bladder 3 mm sessile polyp seen.

Pancreas to the extent visualized, appears normal in size, contour and echogenicity

Spleen is normal in size, shape, contour and echopattern. No evidence of mass or focal lesions.

Right Kidney is normal in size, position, shape and echopattern. Corticomedullary differentiation is maintained. 5 mm calculus seen, no hydronephrosis.

Left Kidney is normal in size, position, shape and echopattern. Corticomedullary differentiation is maintained. No evidence of calculi or hydronephrosis.

Retroperitoneum – Obscured by bowel gas. No significant lymphadenopathy.

Urinary Bladder well distended. wall thickness is normal. No evidence of calculi, mass or mural lesion.

Prostate: normal in size and echotexture.

There is no ascites.

IMPRESSION:

**NON OBSTRUCTIVE RIGHT RENAL CALCULUS
GALL BLADDER POLYP**

---End Of The Report---



Dr.VINOD P JOSEPH
MBBS, DNB, DMRD
25487
Radiology

Patient Name	: Mr. KISHORE KOLLI RAMA	Age	: 35Yrs 4Mths 11Days
UHID	: CKOR.0000259388	OP Visit No.	: CKOROPV431235
Printed On	: 09-11-2024 08:01 AM	Advised/Pres Doctor	: --
Department	: Radiology	Qualification	: --
Referred By	: Self	Registration No.	: --
Employeer Id	: 22E32503		

DEPARTMENT OF RADIOLOGY

X RAY CHEST PA

Both lungs fields appear normal.

Both hilae are normal.

Both costophrenic and cardiophrenic angles are normal.

The cardiac and mediastinal shadows appear normal.

Bones and soft tissues appear normal.

IMPRESSION : NORMAL STUDY.

---End Of The Report---



Dr.VINOD P JOSEPH
MBBS, DNB, DMRD
25487
Radiology

Patient Name	: Mr. KISHORE KOLLI RAMA	Age	: 35Yrs 4Mths 14Days
UHID	: CKOR.0000259388	OP Visit No.	: CKOROPV431235
Printed On	: 12-11-2024 07:13 AM	Advised/Pres Doctor	: --
Department	: Cardiology	Qualification	: --
Referred By	: Self	Registration No.	: --
Employer Id	: 22E32503		

DEPARTMENT OF CARDIOLOGY

ECHO

---End Of The Report---



Dr.MOHAN MURALI
MBBS, DNB General Medicine, DrNB Cardiology
ANP2013000191IKTK
Cardiology

Patient Name	: Mr. KISHORE KOLLI RAMA	Age	: 35Yrs 4Mths 11Days
UHID	: CKOR.0000259388	OP Visit No.	: CKOROPV431235
Printed On	: 09-11-2024 06:16 AM	Advised/Pres Doctor	: --
Department	: Cardiology	Qualification	: --
Referred By	: Self	Registration No.	: --
Employer Id	: 22E32503		

DEPARTMENT OF CARDIOLOGY

Observation :-

1. Normal Sinus Rhythm.
2. Heart rate is 82 beats per minutes.
3. No pathological Q wave or ST-T changes seen.
4. Normal P,Q,R,S,T waves and axis.
5. No evidence of chamber, hypertrophy or enlargement seen.

Impression:

NORMAL RESTING ECG.

NOTE:KINDLY TAKE A PHOTOCOPY OF THE GRAPH FOR FUTURE REFERENCE IF NEEDED

---End Of The Report---



Dr.MOHAN MURALI
MBBS, DNB General Medicine, DrNB Cardiology
ANP20130001911KTK
Cardiology

Name : Mr. KISHORE KOLLI RAMA

Age : 35Y 4M 10D

UHID : CKOR.0000259388

Address : Koramangala Vi Bk Bangalore Karnataka INDIA 560095

sex : Male



CKOR.0000259388

Plan : ARCOFEMI MEDIWHEEL MALE AHC
CREDIT PAN INDIA OP AGREEMENT

OP No: CKOROPV431235

Bill No: CKOR-OCR-85226

Date: Nov 9th, 2024, 9:57 AM

Sno.	Service Type/Service Name	Department	
1	ARCOFEMI - MEDIWHEEL - FULL BODY ANNUAL PLUS MALE - 2D ECHO - PAN INDIA - FY2324		
1	DENTAL CONSULTATION	Consultation	<input type="checkbox"/>
2	ENT CONSULTATION → (23) Dr. Vijayalaxmi	Consultation	<input type="checkbox"/>
3	FITNESS BY GENERAL PHYSICIAN	Consultation	<input type="checkbox"/>
4	OPHTHAL BY GENERAL PHYSICIAN	Consultation	<input type="checkbox"/>
5	GAMMA GLUTAMYL TRANSFERASE (GGT)	Biochemistry	<input type="checkbox"/>
6	LIPID PROFILE	Biochemistry	<input type="checkbox"/>
7	HbA1c, GLYCATED HEMOGLOBIN	Biochemistry	<input type="checkbox"/>
8	GLUCOSE, POST PRANDIAL (PP), 2 HOURS (POST MEAL)	Biochemistry	<input type="checkbox"/>
9	GLUCOSE, FASTING	Biochemistry	<input type="checkbox"/>
10	PERIPHERAL SMEAR	Haematology	<input type="checkbox"/>
11	HEMOGRAM + PERIPHERAL SMEAR	Haematology	<input type="checkbox"/>
12	BLOOD GROUP ABO AND RH FACTOR	Blood Bank	<input type="checkbox"/>
13	COMPLETE URINE EXAMINATION	Clinical Pathology	<input type="checkbox"/>
14	RENAL PROFILE/RENAL FUNCTION TEST (RFT/KFT)	Biochemistry	<input type="checkbox"/>
15	THYROID PROFILE (TOTAL T3, TOTAL T4, TSH)	Biochemistry	<input type="checkbox"/>
16	ULTRASOUND - WHOLE ABDOMEN → (18)	Ultrasound Radiology	<input type="checkbox"/>
17	X-RAY CHEST PA ✓	X Ray Radiology	<input type="checkbox"/>
18	URINE GLUCOSE(POST PRANDIAL)	Clinical Pathology	<input type="checkbox"/>
19	URINE GLUCOSE(FASTING)	Clinical Pathology	<input type="checkbox"/>
20	LIVER FUNCTION TEST (LFT)	Biochemistry	<input type="checkbox"/>
21	2 D ECHO → (18)	Cardiology	<input type="checkbox"/>
22	ECG ✓	Cardiology	<input type="checkbox"/>
23	BODY MASS INDEX (BMI)	General	<input type="checkbox"/>
24	DIET CONSULTATION	General	<input type="checkbox"/>

Ht - 176 cm
wt - 66.6 kg



Apollo Clinic

Consent Form

Patient Name: K. RAMA KISHORE Age: 35y

UHID Number: Company Name:

I Mr/Mrs/Miss: K. Rama Kishore Employee of Bank of Baroda

(Company) want to inform you that I am ~~not~~ getting the Coagulation

Test which is a part of health check package.

Reason if any: I will be coming on wednesday

And I claim the above statement in my full consciousness.

Patient Signature: [Signature] Date: 09/11/2021



Patient Name : Mr Kishore K R

Patient ID :259388

Age : 35Year(s)

Sex: Male

Referring Doctor : H/C

Date:09.11.2024

ULTRASOUND ABDOMEN AND PELVIS

FINDINGS:

Liver is normal in size and shows a normal echotexture. No biliary dilatation. No focal lesion

CBD is not dilated.

Portal vein is normal in size, course and calibre.

Gall bladder 3 mm sessile polyp seen.

Pancreas to the extent visualized, appears normal in size, contour and echogenicity

Spleen is normal in size, shape, contour and echopattern. No evidence of mass or focal lesions.

Right Kidney is normal in size, position, shape and echopattern. Corticomedullary differentiation is maintained. 5 mm calculus seen, no hydronephrosis.

Left Kidney is normal in size, position, shape and echopattern. Corticomedullary differentiation is maintained. No evidence of calculi or hydronephrosis.

Retroperitoneum – Obscured by bowel gas. No significant lymphadenopathy.

Urinary Bladder well distended. wall thickness is normal. No evidence of calculi, mass or mural lesion.

Prostate: normal in size and exchotexture.

There is no ascites.

IMPRESSION:

NON OBSTRUCTIVE RIGHT RENAL CALCULUS

GALL BLADDER POLYP

DR VINOD JOSEPH DNB,DMRD
RADIOLOGIST



DR. SHURTI CHAND KEDIA
 MBBS, MS (ENT)
 KMC REG NO: J19251



Apollo Medical Centre
 Expertise. Closer to you.

HEALTH CHECK - ENT

9/11/24

NAME: *Kishore Kumar Rama*

AGE:

EAR:

RE:

LE:

EXTERNAL EAR

MIDDLE EAR

INNER EAR (FN)

Normal

HEARING ASSESSMENT:

RE:

LE:

RHINNE

WEBER

ABC

Normal

NOSE

AIRWAY

SEPTUM

TURBINATES

OTHERS

Normal

THROAT

ORAL CAVITY

OROPHARYNX

PHARYNX

LARYNX

Normal

NECK

NECK NODES

OTHER

Normal

AUDIOMETRY

IMPRESSION

Normal

[Signature]
SIGNATURE

Apollo Health and Lifestyle Limited

(CIN - U85110TG2000PLC046089) Regd. Office: #7-1-617/A, 615 & 616, Imperial Towers, 7th Floor; Ameerpet, Hyderabad, Telangana - 500 038 | Email ID: enquiry@apollohl.com

APOLLO CLINICS NETWORK KARNATAKA

Bangalore (Basavanagudi | Bellandur | Electronics City | HSR Layout | Indira Nagar | JP Nagar | Kundalahalli | Koramangala | Sarjapur Road) **Mysore** (Kallidasa Road)

Online appointments: www.apolloclinic.com

TO BOOK AN APPOINTMENT

1860 500 7788

OPHTHAL REPORT

NAME: Mr. Kishore Kolli Rama
AGE: 35... GENDER: MALE/FEMALE

RIGHT EYE

	SPH	CYL	AXIS	VA
DV	<u>0</u>			<u>6/6</u>
NV				<u>NS</u>

LEFT EYE

	SPH	CYL	AXIS	VA
DV	<u>0</u>			<u>6/6</u>
NV				<u>NS</u>

REMARK:

Colour Vn: Normal.

DATE: 09.11.2024

[Signature]
OPTOMETRIST

BRING THIS PRESCRIPTION IN YOUR NEXT VISIT

NAME: Mr. KISHORE KOLLI RAMA

AGE: 35Y

SEX: MALE

DATE: 09/11/2024

ECHOCARDIOGRAPHY REPORT

MEASUREMENT

AO - 25(20 - 35)mm	LIVD d 40(36-52)mm	IVS - 10(06 - 11)mm
LA - 28(19- 40)mm	LVID s 28(23- 39)mm	PWD - 10(06- 11)mm
EF - 60(>50%)	RVID-20	

VALVES

Mitral Valve : NORMAL
Aortic Valve : NORMAL
Tricuspid Valve : Normal,
Pulmonary Valve : Normal,

CHAMBERS

Left Atrium : Normal
Right Atrium : Normal
Left Ventricle : Normal
Right Ventricle : Normal

SEPTAE

IVS : Intact
IAS : Intact

GREAT ARTERIES

Aorta : Normal
Pulmonary Artery : Normal

DOPPLER DATA


Mitral : E > A , 0.8 / 0.5
Aortic : Normal , 1.0 m/s
Tricuspid : Normal , 0.4 / 0.6
Pulmonary : Normal, 1.10

WALL MOTION ABNORMALITIES : No RWMA

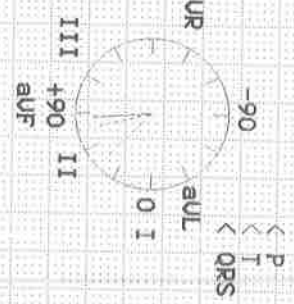
Pericardium : Normal

FINAL DIAGNOSIS

**NORMAL CHAMBERS AND DIMENSION
NO RWMA AT REST, NORMAL LV EF - 60%
NORMAL DIASTOLIC FUNCTION
NO OBVIOUS CLOTS/ EFFUSION/ VEGETATION**

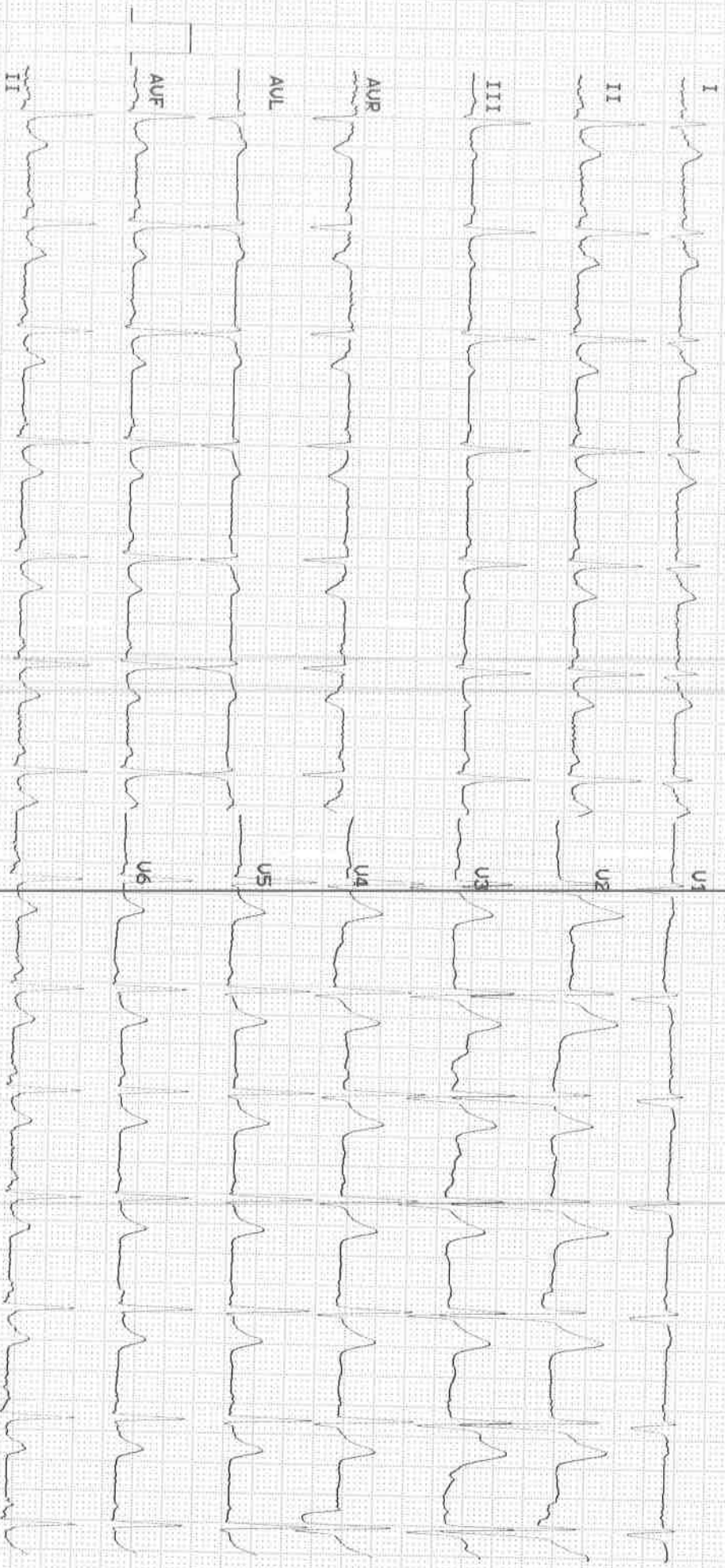
**DR. MOHAN MURALI
DNB(MED), DrNB(CARDIOLOGY)
CONSULTANT CARDIOLOGIST**

AGE: 35
 Measurement Results:
 QRS 106 ms
 QT/QTcB : 346 / 406 ms
 PR : 134 ms
 P : 104 ms
 RR/PP : 726 / 735 ms
 P/ORS/T : 75 / 85 / 45 degrees
 QTd/QTcBd : 38 / 45 ms
 Sokolow : 1.9 mV
 NK : 12



Interpretation:

Unconfirmed report.



Patient Name : Mr. KISHORE KOLLI RAMA Age : 35Yrs 4Mths 10Days
UHID : CKOR.0000259388 OP Visit No. : CKOROPV431235
Printed On : 09-11-2024 11:46 AM Advised/Pres Doctor : --
Department : Cardiology Qualification : --
Referred By : Self Registration No. : --
Employer Id : 22E32503

DEPARTMENT OF CARDIOLOGY

Observation :-

1. Normal Sinus Rhythm.
2. Heart rate is 82 beats per minutes.
3. No pathological Q wave or ST-T changes seen.
4. Normal P,Q,R,S,T waves and axis.
5. No evidence of chamber, hypertrophy or enlargement seen.

Impression:

NORMAL RESTING ECG.

NOTE:KINDLY TAKE A PHOTOCOPY OF THE GRAPH FOR FUTURE REFERENCE IF NEEDED

---End Of The Report---



Dr.MOHAN MURALI
MBBS, DNB General Medicine, DrNB Cardiology
ANP20130001911KTK
Cardiology



Apollo Medical
Centre

Patient Name : Mr. KISHORE KOLLI RAMA
UHID : CKOR.0000259388
Printed On : 09-11-2024 01:31 PM
Department : Radiology
Referred By : Self
Employer Id : 22E32503
Age : 35Yrs 4Mths 10Days
OP Visit No. : CKOROPV431235
Advised/Pres Doctor : --
Qualification : --
Registration No. : --

DEPARTMENT OF RADIOLOGY

X RAY CHEST PA

Both lungs fields appear normal.

Both hilae are normal.

Both costophrenic and cardiophrenic angles are normal.

The cardiac and mediastinal shadows appear normal.

Bones and soft tissues appear normal.

IMPRESSION : NORMAL STUDY.

---End Of The Report---

P.J. Vinod

Dr.VINOD P JOSEPH
MBBS, DNB, DMRD
25487
Radiology

Apollo Health and Lifestyle Limited

(CIN - U85110TG2000PLC046089) Regd. Office: #7-1-617/A, 615 & 616, Imperial Towers, 7th Floor, Ameerpet, Hyderabad, Telangana 500 038 | Email ID: enquiry@apollo.com

APOLLO CLINICS NETWORK KARNATAKA

Bangalore (Basavanagudi | Bellandur | Electronics City | HSR Layout | Indira Nagar | JP Nagar | Kundalahalli | Koramangala | Sarjapur Road) Mysore (Kallidasa Road)

Online appointments: www.apollohmc.com

TO BOOK AN APPOINTMENT

1860 500 7788

Outlook

Fw: Health Check up Booking Confirmed Request(22E32503),Package Code-PKG10000366, Beneficiary Code-300059

From KOLLI RAMA KISHORE <KOLLI.KISHORE@bankofbaroda.com>
Date Sat 09-11-2024 09:53

To Koramangala Apolloclinic <koramangala@apolloclinic.com>

Get Outlook for Android

From: Mediwheel <wellness@mediwheel.in>

Sent: Thursday, November 7, 2024 3:36:32 PM

To: KOLLI RAMA KISHORE <KOLLI.KISHORE@bankofbaroda.com>

Cc: customercare@mediwheel.in <customercare@mediwheel.in>

Subject: Health Check up Booking Confirmed Request(22E32503),Package Code-PKG10000366, Beneficiary Code-300059

Hi लिंक पर क्लिक ना करें या अटैचमेंट ना खोलें.

NOT CLICK ON LINKS OR OPEN ATTACHMENTS UNLESS YOU KNOW THE SENDER.

011-41195959

Dear K Rama Kishore ,

We are pleased to confirm your health checkup booking request with the following details.

Hospital Package Name : Mediwheel Full Body Annual Plus

Name of Diagnostic/Hospital : Apollo Medical Centre - Koramangala

Address of Diagnostic/Hospital : Apollo Medical centre, Plot 51, 5th Block, Opp. Jyothi Nivas College, Koramangala - 5600095

City : Bangalore

State : Karnataka

Pincode : 560095

Appointment Date : 09-11-2024

Confirmation Status : Booking Confirmed

Preferred Time : 08:00 AM - 08:30 AM

Booking Status : Booking Confirmed

Member Information

Booked Member Name	Age	Gender
MR. KISHORE KOLLI RAMA	35 year	Male

Note - Please note to not



बैंक ऑफ बरोडा
Bank of Baroda

नाम
Name के राम किशोर
Kishore Koli Rama

E.C. No. 167082




जारीकर्ता प्राधिकारी
Issuing Authority


धारक के हस्ताक्षर
Signature of Hold