



**LABORATORY REPORT : BIOCHEMISTRY**

<b>Name</b>	: Mr. PRATIK MAHESH YEOTIKAR	<b>Age /Sex</b>	: 35Y Y(s)/MALE
<b>Bill Date</b>	: 09-Nov-2024 09:58 AM	<b>UMR No.</b>	: 702411000717
<b>Rec. Dt</b>	: 09-Nov-2024 10:28 AM	<b>Bill No.</b>	: MCB70241102754
<b>Rept. Dt</b>	: 09-Nov-2024 11:34 AM	<b>Result No</b>	: RUR241109944
<b>Ref By</b>	: Dr. Anandeep Agarwal	<b>Sample ID</b>	: MCHAU4047297
<b>Sample Type</b>	: SERUM		

**BUN(BLOOD UREA NITROGEN)**

<b><u>Parameters</u></b>	<b><u>Result</u></b>	<b><u>Reference Range</u></b>	<b><u>Units</u></b>
<b>BLOOD UREA</b> <i>Urease kinetic</i>	21.6	16.6 - 48.5	mg/dL

\*\*\* End Of Report \*\*\*

*UAR*

DR. URMILA AJAY ROTTE  
CONSULTANT PATHOLOGIST, MBBS,  
DIPLOMA IN PATHOLOGY



**LABORATORY REPORT : BIOCHEMISTRY**

<b>Name</b>	: Mr. PRATIK MAHESH YEOTIKAR	<b>Age /Sex</b>	: 35Y Y(s)/MALE
<b>Bill Date</b>	: 09-Nov-2024 09:58 AM	<b>UMR No.</b>	: 702411000717
<b>Rec. Dt</b>	: 09-Nov-2024 10:28 AM	<b>Bill No.</b>	: MCB70241102754
<b>Rept. Dt</b>	: 09-Nov-2024 11:34 AM	<b>Result No</b>	: RUR241109945
<b>Ref By</b>	: Dr. Anandeeep Agarwal	<b>Sample ID</b>	: MCHAU4047297
<b>Sample Type</b>	: SERUM		

**LIPID PROFILE**

<u>Parameters</u>	<u>Result</u>	<u>Reference Range</u>	<u>Units</u>
<b>TOTAL CHOLESTEROL</b> <i>Enzymatic colorimetric</i>	120.6	Desirable :: < 200 mg/dL Borderline High :: 200 - 239 mg/dL High risk : > 240 mg/dL	mg/dL
<b>HDL CHOLESTEROL</b> <i>Homogeneous enzymatic colorimetric</i>	32.2	Low :: < 40 mg/dL High :: > 60 mg/dL	mg/dL
<b>LDL CHOLESTEROL</b> <i>Direct-Enzymatic colorimetric</i>	67	Very High : - > 190 mg/dL Optimal : - < 100 mg/dL Near Optimal : 100 - 129 mg/dL High : 160 - 189 mg/dL Borderline High:130-159 mg/dl	mg/dL
<b>VLDL</b> <i>Calculation</i>	21.42	2 - 30 mg/dL	mg/dL
<b>SERUM TRYGLYCERIDES</b> <i>Enzymatic colorimetric</i>	107.1	< 150 mg/dL Borderline High : 150 - 199 mg/dL High : 200 - 499 mg/dL	mg/dL
<b>CHO/HDL RATIO</b> <i>Calculation</i>	3.75 *	Normal : - < 3.5 High Risk : - > 5.0	
<b>LDL/HDL RATIO</b>	2.08		

\*\*\* End Of Report \*\*\*

*UAR*

**DR. URMILA AJAY ROTTE**  
CONSULTANT PATHOLOGIST, MBBS,  
DIPLOMA IN PATHOLOGY



**LABORATORY REPORT : BIOCHEMISTRY**

<b>Name</b>	: Mr. PRATIK MAHESH YEOTIKAR	<b>Age /Sex</b>	: 35Y Y(s)/MALE
<b>Bill Date</b>	: 09-Nov-2024 09:58 AM	<b>UMR No.</b>	: 702411000717
<b>Rec. Dt</b>	: 09-Nov-2024 10:28 AM	<b>Bill No.</b>	: MCB70241102754
<b>Rept. Dt</b>	: 09-Nov-2024 11:34 AM	<b>Result No</b>	: RUR241109946
<b>Ref By</b>	: Dr. Ananddeep Agarwal	<b>Sample ID</b>	: MCHAU4047298
<b>Sample Type</b>	: PLASMA		

**FBS (FASTING BLOOD GLUCOSE WITH URINE GLUCOSE)**

<u>Parameters</u>	<u>Result</u>	<u>Reference Range</u>	<u>Units</u>
<b>FASTING BLOOD GLUCOSE</b> <i>Hexokinase</i>	<b>104 *</b>	Normal Range : 70 - 99 Impaired Glucose tolerance : 100 -125 Diabetes Mellitus : >=126	mg/dL

\*\*\* End Of Report \*\*\*

*UAR*

**DR. URMILA AJAY ROTTE**  
CONSULTANT PATHOLOGIST, MBBS,  
DIPLOMA IN PATHOLOGY



**LABORATORY REPORT : BIOCHEMISTRY**

<b>Name</b>	: Mr. PRATIK MAHESH YEOTIKAR	<b>Age /Sex</b>	: 35Y Y(s)/MALE
<b>Bill Date</b>	: 09-Nov-2024 09:58 AM	<b>UMR No.</b>	: 702411000717
<b>Rec. Dt</b>	: 09-Nov-2024 10:28 AM	<b>Bill No.</b>	: MCB70241102754
<b>Rept. Dt</b>	: 09-Nov-2024 11:34 AM	<b>Result No</b>	: RUR241109947
<b>Ref By</b>	: Dr. Anandeep Agarwal	<b>Sample ID</b>	: MCHAU4047297
<b>Sample Type</b>	: SERUM		

**SERUM CREATININE**

<b><u>Parameters</u></b>	<b><u>Result</u></b>	<b><u>Reference Range</u></b>	<b><u>Units</u></b>
<b>CREATININE</b> <i>Jaffe</i>	0.94	0.7 - 1.2	mg/dL

\*\*\* End Of Report \*\*\*

*UAR*

DR. URMILA AJAY ROTTE  
CONSULTANT PATHOLOGIST, MBBS,  
DIPLOMA IN PATHOLOGY



**LABORATORY REPORT : BIOCHEMISTRY**

<b>Name</b>	: Mr. PRATIK MAHESH YEOTIKAR	<b>Age /Sex</b>	: 35Y Y(s)/MALE
<b>Bill Date</b>	: 09-Nov-2024 09:58 AM	<b>UMR No.</b>	: 702411000717
<b>Rec. Dt</b>	: 09-Nov-2024 10:28 AM	<b>Bill No.</b>	: MCB70241102754
<b>Rept. Dt</b>	: 09-Nov-2024 11:34 AM	<b>Result No</b>	: RUR241109950
<b>Ref By</b>	: Dr. Ananddeep Agarwal	<b>Sample ID</b>	: MCHAU4047297
<b>Sample Type</b>	: SERUM		

**SERUM URIC ACID**

<b><u>Parameters</u></b>	<b><u>Result</u></b>	<b><u>Reference Range</u></b>	<b><u>Units</u></b>
<b>SERUM URIC ACID</b> <i>uricase</i>	4.4	3.4-7.0	mg/dL

\*\*\* End Of Report \*\*\*

LAR

DR. URMILA AJAY ROTTE  
CONSULTANT PATHOLOGIST, MBBS,  
DIPLOMA IN PATHOLOGY





**LABORATORY REPORT : BIOCHEMISTRY**

<b>Name</b>	: Mr. PRATIK MAHESH YEOTIKAR	<b>Age /Sex</b>	: 35Y Y(s)/MALE
<b>Bill Date</b>	: 09-Nov-2024 09:58 AM	<b>UMR No.</b>	: 702411000717
<b>Rec. Dt</b>	: 09-Nov-2024 12:58 PM	<b>Bill No.</b>	: MCB70241102754
<b>Rept. Dt</b>	: 09-Nov-2024 02:40 PM	<b>Result No</b>	: RUR241110288
<b>Ref By</b>	: Dr. Ananddeep Agarwal	<b>Sample ID</b>	: MCHAU4047416
<b>Sample Type</b>	:		

**PLBS (POST LUNCH BLOOD SUGAR WITH URINE SUGAR)**

<b>Parameters</b>	<b>Result</b>	<b>Reference Range</b>	<b>Units</b>
<b>PLBS (POST LUNCH BLOOD GLUCOSE )</b> <i>Hexokinase</i>	82	Norma Range : < 140 mg/dL mpaired Glucose Tolerance : 140-199 mg/dL Diabetes Mellitus : > 200 mg/dL	mg/dL

\*\*\* End Of Report \*\*\*

LAR

DR. URMILA AJAY ROTTE  
CONSULTANT PATHOLOGIST, MBBS,  
DIPLOMA IN PATHOLOGY



**LABORATORY REPORT : BLOOD BANK**

<b>Name</b>	: Mr. PRATIK MAHESH YEOTIKAR	<b>Age /Sex</b>	: 35Y Y(s)/MALE
<b>Bill Date</b>	: 09-Nov-2024 09:58 AM	<b>UMR No.</b>	: 702411000717
<b>Rec. Dt</b>	: 09-Nov-2024 10:28 AM	<b>Bill No.</b>	: MCB70241102754
<b>Rept. Dt</b>	: 09-Nov-2024 12:48 PM	<b>Result No</b>	: RUR241109952
<b>Ref By</b>	: Dr. Ananddeep Agarwal	<b>Sample ID</b>	: MCHAU4047300
<b>Sample Type</b>	: WHOLE BLOOD		

**BLOOD GROUPING AND RH**

<u>Parameters</u>	<u>Result</u>	<u>Reference Range</u>	<u>Units</u>
<b>BLOOD GROUP</b> <i>Automated microcolumn gel method</i>	A		
<b>RH TYPE</b>	POSITIVE		

**INTERPRETATION**

1. If Rh is Du positive it is best considered as Rh negative as recipient and Rh positive as donor. Proper Cross matching is recommended before transfusion.
2. In case of forward and reverse grouping discrepancy, clinical correlation and repeat sample analysis is recommended.
3. For Infants below 6 months only forward grouping is performed.
4. A sub-grouping is recommended after the age of 6 months.

\*\*\* End Of Report \*\*\*



DR. Suwarna Rahul Jawale  
CONSULTANT PATHOLOGIST, MBBS,  
DNB



**LABORATORY REPORT : CLINICAL PATHOLOGY**

<b>Name</b>	: Mr. PRATIK MAHESH YEOTIKAR	<b>Age /Sex</b>	: 35Y Y(s)/MALE
<b>Bill Date</b>	: 09-Nov-2024 09:58 AM	<b>UMR No.</b>	: 702411000717
<b>Rec. Dt</b>	: 09-Nov-2024 10:28 AM	<b>Bill No.</b>	: MCB70241102754
<b>Rept. Dt</b>	: 09-Nov-2024 11:32 AM	<b>Result No</b>	: RUR241109951
<b>Ref By</b>	: Dr. Ananddeep Agarwal	<b>Sample ID</b>	: MCHAU4047299
<b>Sample Type</b>	: URINE		

**CUE(COMPLETE URINE EXAMINATION)**

<u>Parameters</u>	<u>Result</u>	<u>Reference Range</u>	<u>Units</u>
<b><u>PHYSICAL EXAMINATION</u></b>			
<b>QUANTITY</b>	20		ML
<b>COLOUR</b>	PALE YELLOW	PALE YELLOW	
<b>APPEARANCE</b>	CLEAR	CLEAR	
<b>PROTEIN</b> <i>Tetra-bromophenol blue/Heat coagulation test</i>	NIL	NIL	
<b>GLUCOSE</b> <i>Glucose oxidase Peroxidase/Benedict's test</i>	+	NIL	
<b><u>MICROSCOPIC EXAMINATION</u></b>			
<b>PUS CELLS</b>	2-3	0 - 5 /hpf	
<b>EPITHELIAL CELLS</b>	1-2	0 - 5	hpf
<b>RBC</b>	0-1	0 - 5 /hpf	
<b>CRYSTALS</b>	NIL	NIL	

*UAR*

DR. URMILA AJAY ROTTE  
CONSULTANT PATHOLOGIST, MBBS,  
DIPLOMA IN PATHOLOGY





**LABORATORY REPORT : CLINICAL PATHOLOGY**

<b>Name</b>	: Mr. PRATIK MAHESH YEOTIKAR	<b>Age /Sex</b>	: 35Y Y(s)/MALE
<b>Bill Date</b>	: 09-Nov-2024 09:58 AM	<b>UMR No.</b>	: 702411000717
<b>Rec. Dt</b>	: 09-Nov-2024 10:28 AM	<b>Bill No.</b>	: MCB70241102754
<b>Rept. Dt</b>	: 09-Nov-2024 11:32 AM	<b>Result No</b>	: RUR241109951
<b>Ref By</b>	: Dr. Ananddeep Agarwal	<b>Sample ID</b>	: MCHAU4047299
<b>Sample Type</b>	: URINE		

CASTS

NIL

NIL

\*\*\* End Of Report \*\*\*

*UAR*

DR. URMILA AJAY ROTTE  
CONSULTANT PATHOLOGIST, MBBS,  
DIPLOMA IN PATHOLOGY



**LABORATORY REPORT : HAEMATOLOGY**

<b>Name</b>	: Mr. PRATIK MAHESH YEOTIKAR	<b>Age /Sex</b>	: 35Y Y(s)/MALE
<b>Bill Date</b>	: 09-Nov-2024 09:58 AM	<b>UMR No.</b>	: 702411000717
<b>Rec. Dt</b>	: 09-Nov-2024 10:28 AM	<b>Bill No.</b>	: MCB70241102754
<b>Rept. Dt</b>	: 09-Nov-2024 11:54 AM	<b>Result No</b>	: RUR241109953
<b>Ref By</b>	: Dr. Ananddeep Agarwal	<b>Sample ID</b>	: MCHAU4047301
<b>Sample Type</b>	: WHOLE BLOOD		

**Parameters**

**ESR**

MODIFIED WESTERGREN'S  
METHOD

**Result**

08

**ESR**

**Reference Range**

0 - 10

**Units**

mm/1st hour

\*\*\* End Of Report \*\*\*



DR. Suwarna Rahul Jawale  
CONSULTANT PATHOLOGIST, MBBS,  
DNB



**LABORATORY REPORT : HAEMATOLOGY**

<b>Name</b>	: Mr. PRATIK MAHESH YEOTIKAR	<b>Age /Sex</b>	: 35Y Y(s)/MALE
<b>Bill Date</b>	: 09-Nov-2024 09:58 AM	<b>UMR No.</b>	: 702411000717
<b>Rec. Dt</b>	: 09-Nov-2024 10:28 AM	<b>Bill No.</b>	: MCB70241102754
<b>Rept. Dt</b>	: 09-Nov-2024 11:34 AM	<b>Result No</b>	: RUR241109954
<b>Ref By</b>	: Dr. Ananddeep Agarwal	<b>Sample ID</b>	: MCHAU4047302
<b>Sample Type</b>	: WHOLE BLOOD		

**CBP(COMPLETE BLOOD PICTURE)**

<b>Parameters</b>	<b>Result</b>	<b>Reference Range</b>	<b>Units</b>
<b>HEMOGLOBIN</b> <i>Photometric</i>	14.9	13.0 - 17.0	gms/dL
<b>R B C COUNT</b> <i>Electrical Impedance</i>	5.40	4.5 - 5.5 $10^{12}/L$	$10^{12}/L$
<b>PCV/HCT</b> <i>Calculated</i>	45.2	40 - 50	%
<b>MCV</b> <i>Calculated</i>	84	83 - 101	fL
<b>MCH</b> <i>Calculated</i>	27.6	27 - 32	pg
<b>MCHC</b> <i>Calculated</i>	33.0	31 - 37	g/dL
<b>TLC (TOTAL LEUCOCYTE COUNT)</b> <i>Impedance</i>	6.0	4.0 - 10.0	$10^3/\mu l$
<b>DIFFERENTIAL COUNT</b>			
<b>NEUTROPHILS</b> <i>DHSS/Microscopy</i>	45.0	40 - 80 %	
<b>LYMPHOCYTES</b> <i>DHSS/Microscopy</i>	40.9 *	20 - 40 %	
<b>MONOCYTES</b> <i>DHSS/Microscopy</i>	5.1	02 - 10 %	

*UAR*

DR. URMILA AJAY ROTTE  
CONSULTANT PATHOLOGIST, MBBS,  
DIPLOMA IN PATHOLOGY



**LABORATORY REPORT : HAEMATOLOGY**

<b>Name</b>	: Mr. PRATIK MAHESH YEOTIKAR	<b>Age /Sex</b>	: 35Y Y(s)/MALE
<b>Bill Date</b>	: 09-Nov-2024 09:58 AM	<b>UMR No.</b>	: 702411000717
<b>Rec. Dt</b>	: 09-Nov-2024 10:28 AM	<b>Bill No.</b>	: MCB70241102754
<b>Rept. Dt</b>	: 09-Nov-2024 11:34 AM	<b>Result No</b>	: RUR241109954
<b>Ref By</b>	: Dr. Ananddeep Agarwal	<b>Sample ID</b>	: MCHAU4047302
<b>Sample Type</b>	: WHOLE BLOOD		

<b>EOSINOPHILS</b> <i>DHSS/Microscopy</i>	<b>9.0 *</b>	00 - 06 %	
<b>BASOPHILS</b> <i>DHSS/Microscopy</i>	<b>0.0</b>	00 - 01 %	
<b>PLATELET COUNT</b> <i>Electrical Impedance</i>	<b>295</b>	150 - 400 $10^3/\mu\text{L}$	$10^3/\mu\text{L}$

\*\*\* End Of Report \*\*\*

UAR

DR. URMILA AJAY ROTTE  
CONSULTANT PATHOLOGIST, MBBS,  
DIPLOMA IN PATHOLOGY





**MEDICOVER**  
HOSPITALS

A Unit of Saharajaya Health Care Private Limited

June 16, 2022 - June 15, 2026

<b>NAME:</b>	PRATIK YEOTIKAR	<b>SEX:</b>	35YRS /M
<b>REF BY:</b>	DR. A. AGARWAL	<b>DATE:</b>	09/11/2024
<b>UMR NO :</b>	702411000717		

### USG ABDOMEN AND PELVIS

**Liver:** Size is normal. Shows bright echotexture s/o grade – I fatty changes. No focal lesion seen.

Intrahepatic portal and biliary radicals appear normal. Portal vein and CBD normal.

**Gall Bladder :** Physiologically distended. Wall thickness normal. No calculus seen.

**Pancreas:** Visualized head and body appears normal.

**Spleen :** Size is normal. Shape and Parenchymal echotexture normal. S.V. normal.

**RT. Kidney:** Size 8.1 x 3.6 cms, normal.

Parenchymal echotexture, corticomedullary differentiation normal.

Pelvicalyceal system appears normal. No calculus seen.

**LT. Kidney:** Size 8.6 x 3.9 cms, normal.

Parenchymal echotexture, corticomedullary differentiation normal.

Pelvicalyceal system appears normal.

**Few tiny calculi are noted in upper and lower group calyx of left kidney, largest measures 4.1 mm.**

**Urinary Bladder:** Distended, wall thickness normal. No calculus seen.

**Prostate :** Normal.

**Bowel loops:** Normal. Peristalsis normal. No e/o free fluid in abdomen / pelvis.

No e/o Pre/Para aortic lymphadenopathy. Aorta and IVC appear grossly normal.

### IMPRESSION :

- Grade – I fatty changes in liver.
- Left renal calculi.

*Abhishek Bujade*

**DR. ABHISHEK BUJADE**  
**MD RADIOLOGY**  
**(CONSULTANT RADIOLOGIST)**

*SI-999*

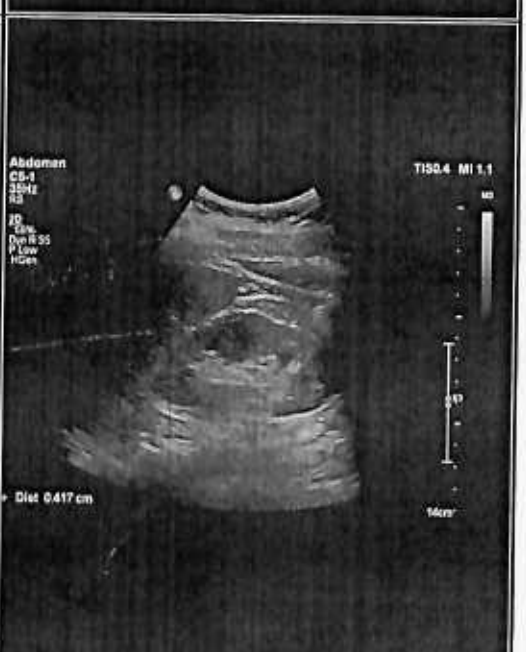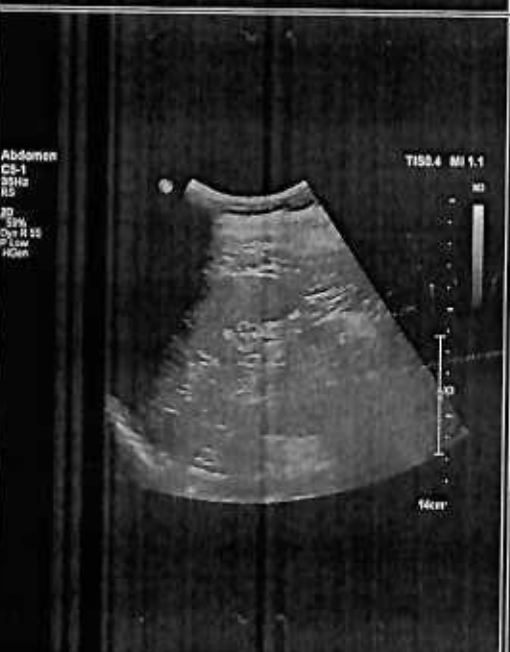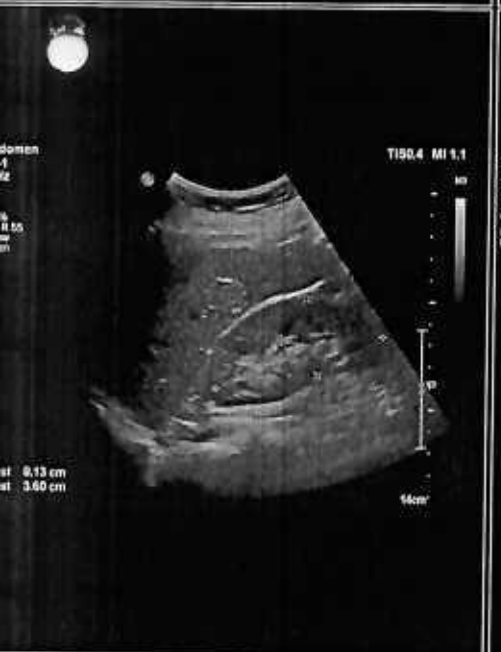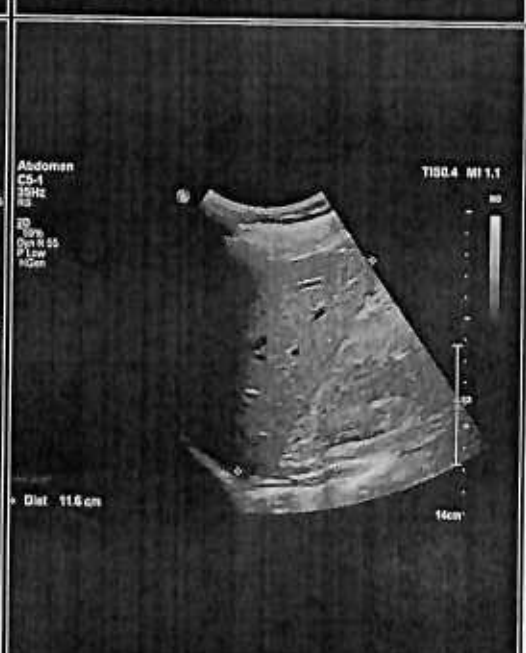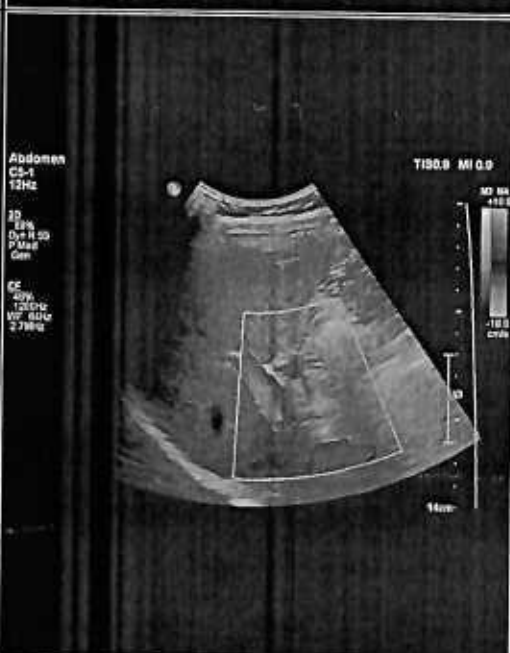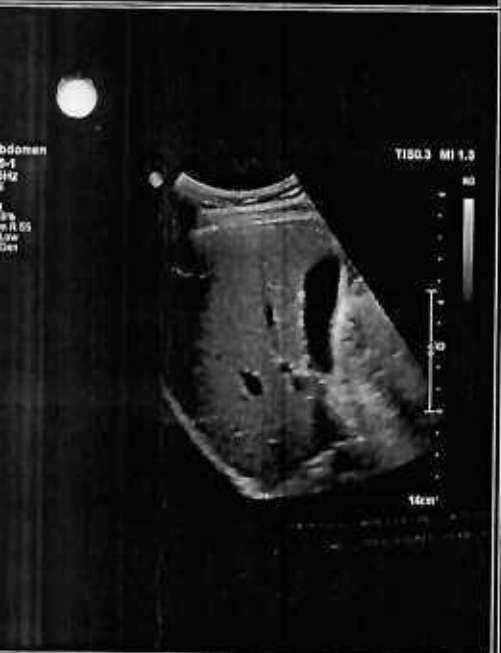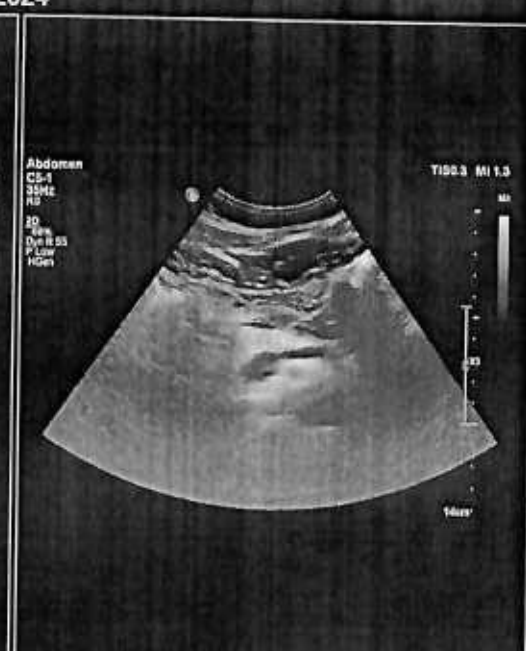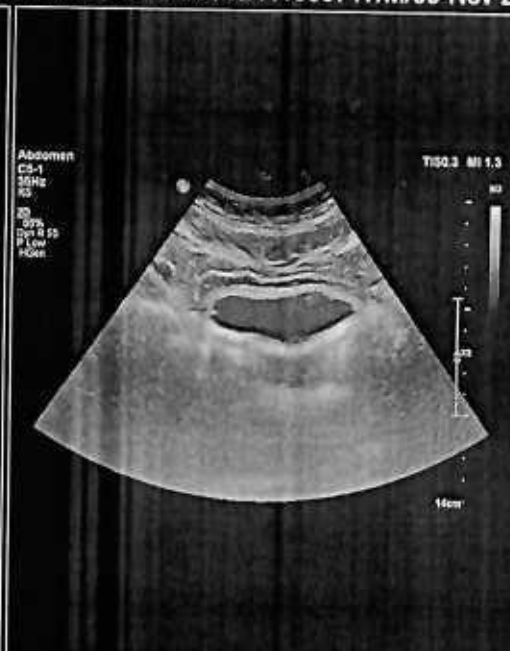
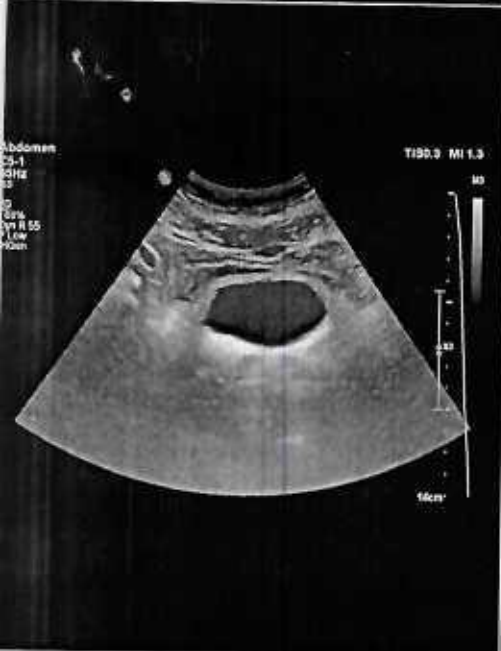For Appointment Please Contact - 040 - 6833 4455

📍 Near Chistiya Police Chowk, N-6, Cidco,  
Chhatrapati Sambhajinagar - 431003.

🌐 [www.medicoverhospital](http://www.medicoverhospital)

@ [Info@medicoverhospital.in](mailto:Info@medicoverhospital.in)

For Reports Only





# MEDICOVER HOSPITAL

Near Chistiya Colony , Police Chowki, N-6 Cidco ,  
Chhatrapati Sambhajinagar - 431001  
Email\_ID: info@medicoverhospitals.in

Name: Mr. PRATIK YEOTIKAR  
Age: 35 Y  
Sex: M  
Date: 09-Noy-2024

Ref By: Dr. ANANDEEP AGRAWAL  
Study: 2D ECHO  
Examined By: Dr. ANKUSH KOLHE  
Hospital ID: UMR0717

## ECHOCARDIOGRAPHY REPORT

### MEASUREMENTS

Aorta	30mm	LA	32mm
IVSed	10mm	PWed	10mm
LV ed	40mm	LVes	28mm
LVEF	60 %	IVC	12 mm, collapsing

IVS Motion - NORMAL

### CHAMBERS

LV            NORMAL CHAMBER DIMENSIONS  
                  RWMA- ABSENT  
                  DIASTOLIC DYSFUNCTION - ABSENT  
LA            NORMAL  
RA            NORMAL  
RV            NORMAL

### MITRAL VALVE

Morphology            NORMAL  
Mitral Stenosis -      ABSENT  
Mitral Regurgitation - ABSENT

### TRICUSPID VALVE

Morphology            NORMAL  
Doppler                TRIVIAL TR, RVSP- 30mm of Hg

### PULMONARY VALVE

Morphology            NORMAL  
Doppler                NORMAL

### AORTIC VALVE

Morphology            NORMAL  
Doppler                NORMAL

AORTA-Normal / No-CoA/ dissection

IAS/ IVS - Intact

NO CLOT/VEGETATION/PERICARDIAL EFFUSION

### FINAL IMPRESSION-

- NORMAL CHAMBER DIMENSIONS
- NO RESTING RWMA, LVEF - 60%
- NO LV DIASTOLIC DYSFUNCTION
- NO PULMONARY HYPERTENSION

DR ANKUSH KOLHE  
MBBS/FCPS/DIP. PRE.MED/DIP CARD(PGDCC)  
REG-2007-07-3028

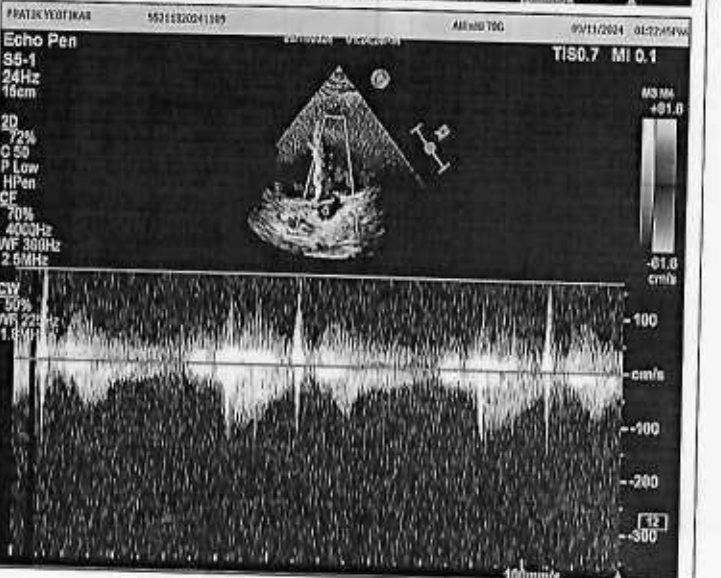
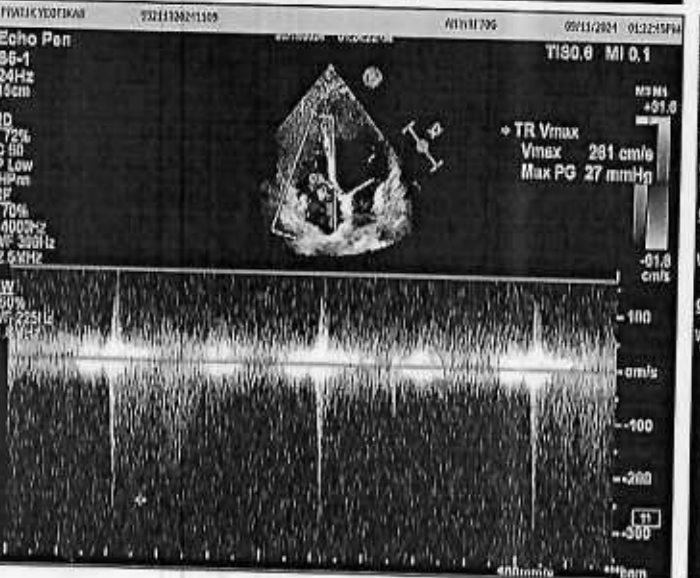
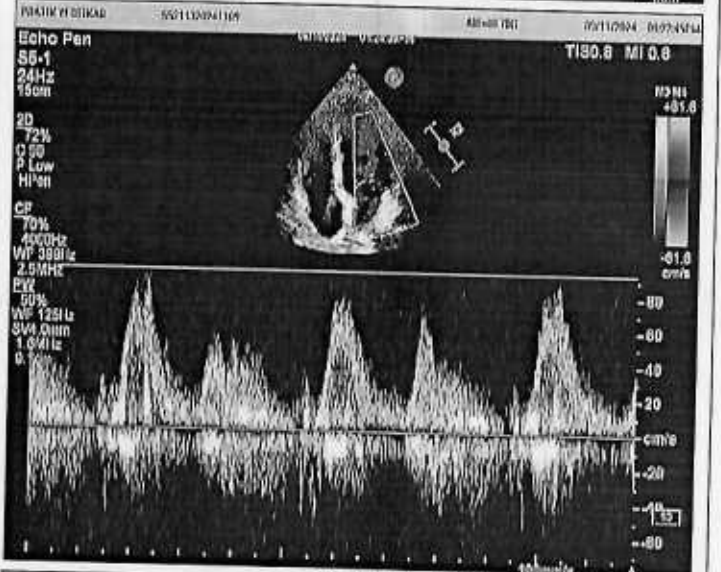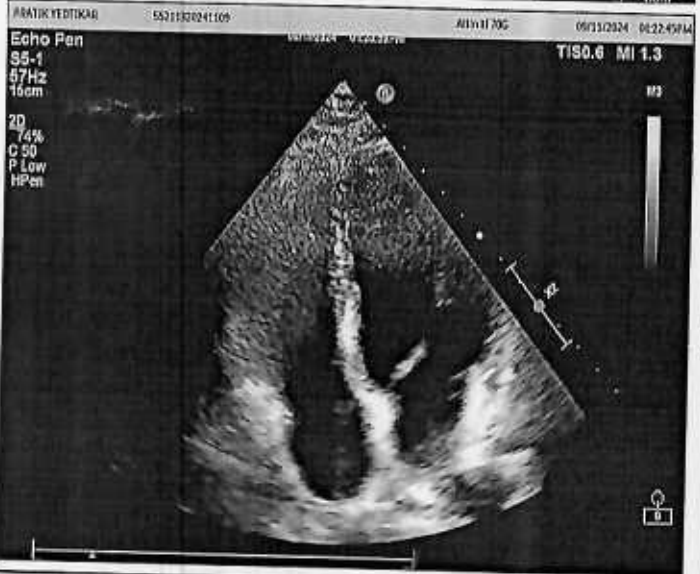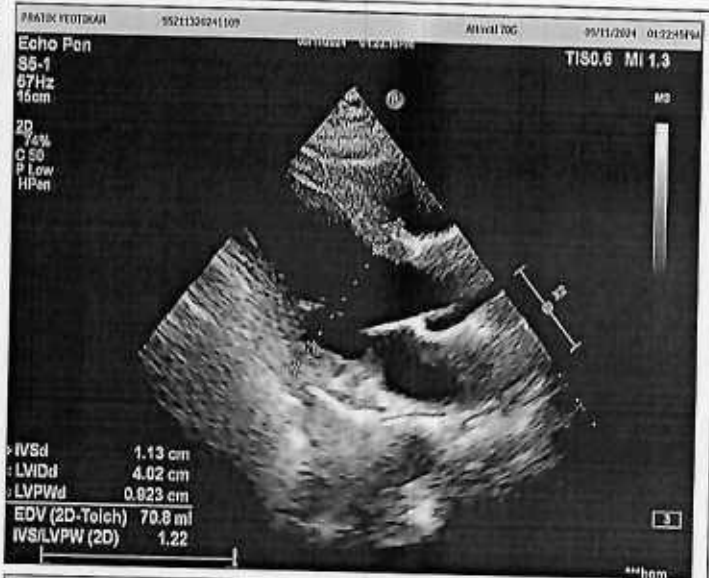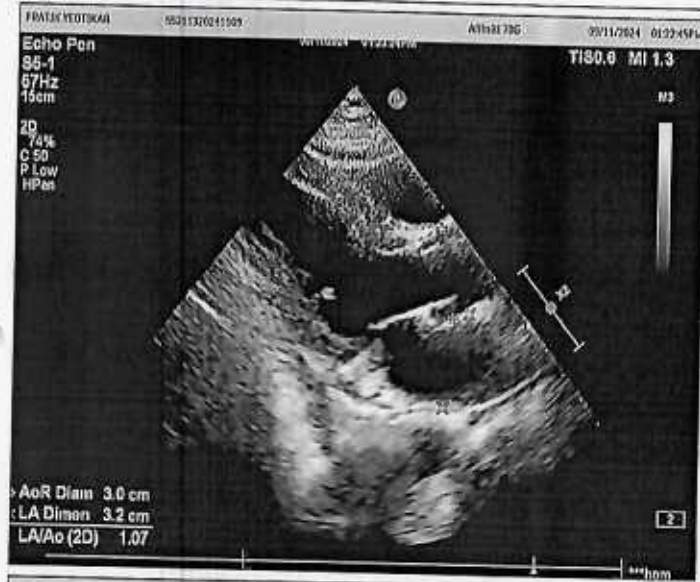DR. KULDEEP R TOTAWAR  
MD,DM CARDIOLOGIST  
REG. NO.-MMC 2014-06-2848

# MEDICOVER HOSPITAL

Near Chistiya Colony , Police Chowki, N-6 Cidco ,  
Chhatrapati Sambhajnagar - 431001  
Email\_ID: info@medicoverhospitals.in

Name: Mr. PRATIK YEOTIKAR  
Age: 35 Y  
Sex: M  
Date: 09-Nov-2024

Ref By: Dr. ANANDEEP AGRAWAL  
Study: 2D ECHO  
Examined By: Dr. ANKUSH KOLHE  
Hospital ID: UMR0717







H-2022-0977

June 16, 2022 - June 15, 2026



Patient ID:	UMR702411000717	Patient Name:	PRATIK YEOTIKAR
Age:	35 Years	Sex:	M
Referring Physician:	DR.A.AGARWAL	Modality:	CR
Study Date:	09-Nov-2024	Study:	Chest

### X-RAY CHEST PA VIEW

Both lung fields appears normal  
Both C.P.angles appears normal.  
Both hilar shadows normal.  
Mediastinal silhouette appears normal.  
Both domes of diaphragm, bony cage and soft tissue appears normal

**Imp : No significant abnormality detected.**

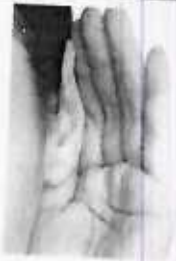**DR. ABHISHEK BUJADE**  
**MD RADIOLOGY**  
**(CONSULTANT RADIOLOGIST)**

For Appointment Please Contact - 040 - 6833 4455  
Near Chistiya Police Chowk, N-6, Cidco,  
Chhatrapati Sambhajnagar - 431003.

[www.medicoverhospital](http://www.medicoverhospital)  
[Info@medicoverhospital.in](mailto:Info@medicoverhospital.in)

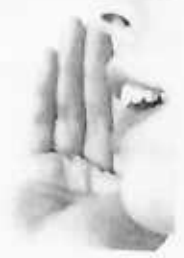For Reports Only

# AADHAR SPEECH THERAPY & HEARING CLINIC



All type of Hearing Aid  
Machine Available Hear.

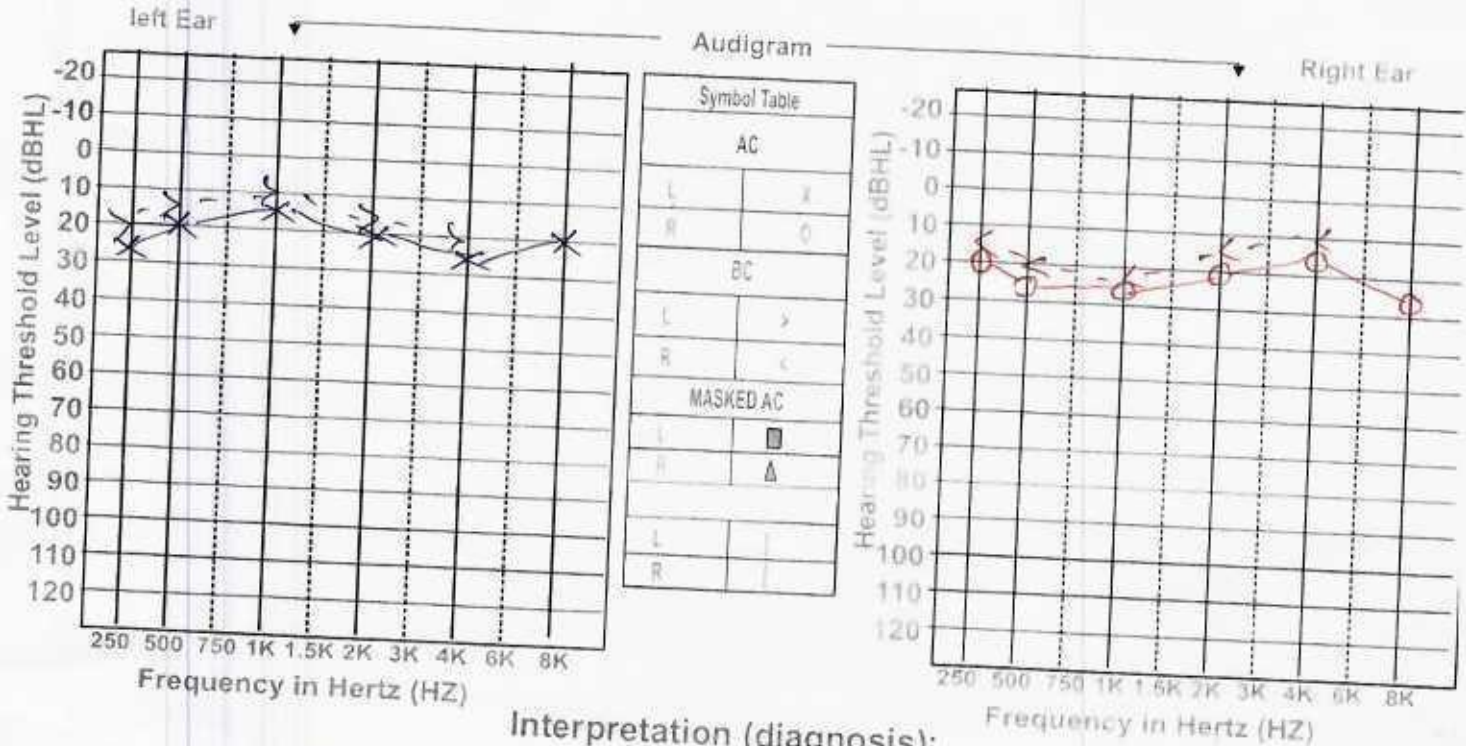
Mo : 8380840048 / 8380847568



## Audiological Evaluation Sheet

Name pratik yeetkar Age 35 Gender M  
Date : 09/11/24 Tested By PTA E Code -

Brief Case History / Complaint



Interpretation (diagnosis):

Right ear : bilateral - Normal hearing sensitivity.  
Left ear : \_\_\_\_\_

Otoscopy Findings : Right Ear  Left Ear   
Responses : Reliable  Fairly Reliable  Not Reliable   
Test Condition : Satisfactory  Not Satisfactory   
Procedure : Standard  Play

Audiometer: Aryan - 7000 A.

### Speech Audiometry

Test →	PTA	SAT	SRT	WRS	MCL	UCL
Ear ↓	dBHL	DBHL	dBHL	%	dBHL	dBHL
Right						
Left						

*[Signature]*  
Audiologist / Speech Therapist  
RCI-No B53593  
E-mail ID arunrathod0048@gmail.com

**Arun Rathod**

Add : Near Aamdar Amruttulya, Opp.SBI Bank Sevalal Chowk  
Hanuman Nagar, N-4 Cidco Aurangabad.



**MEDICOVER  
HOSPITALS**

A Unit of Sahridaya Health Care Private Limited

H-2022-0977

June 16, 2022 - June 15, 2026

Mr. Pratik Mahesh teotikan

Age. 35Y/M

Vn  $\left\{ \begin{array}{l} 6/6 \\ 6/6 \end{array} \right.$

Dist

RE

LE

Plano.

Plano

Near.

$\left\{ \begin{array}{l} N6 \\ N6. \end{array} \right.$

color: - Normal.

For Appointment Please Contact - 040 - 6833 4455  
Near Chistiya Police Chowk, N-6, Cidco,  
Chhatrapati Sambhajnagar - 431003.

www.medicoverhospital  
@ Info@medicoverhospital.in

For Reports Only



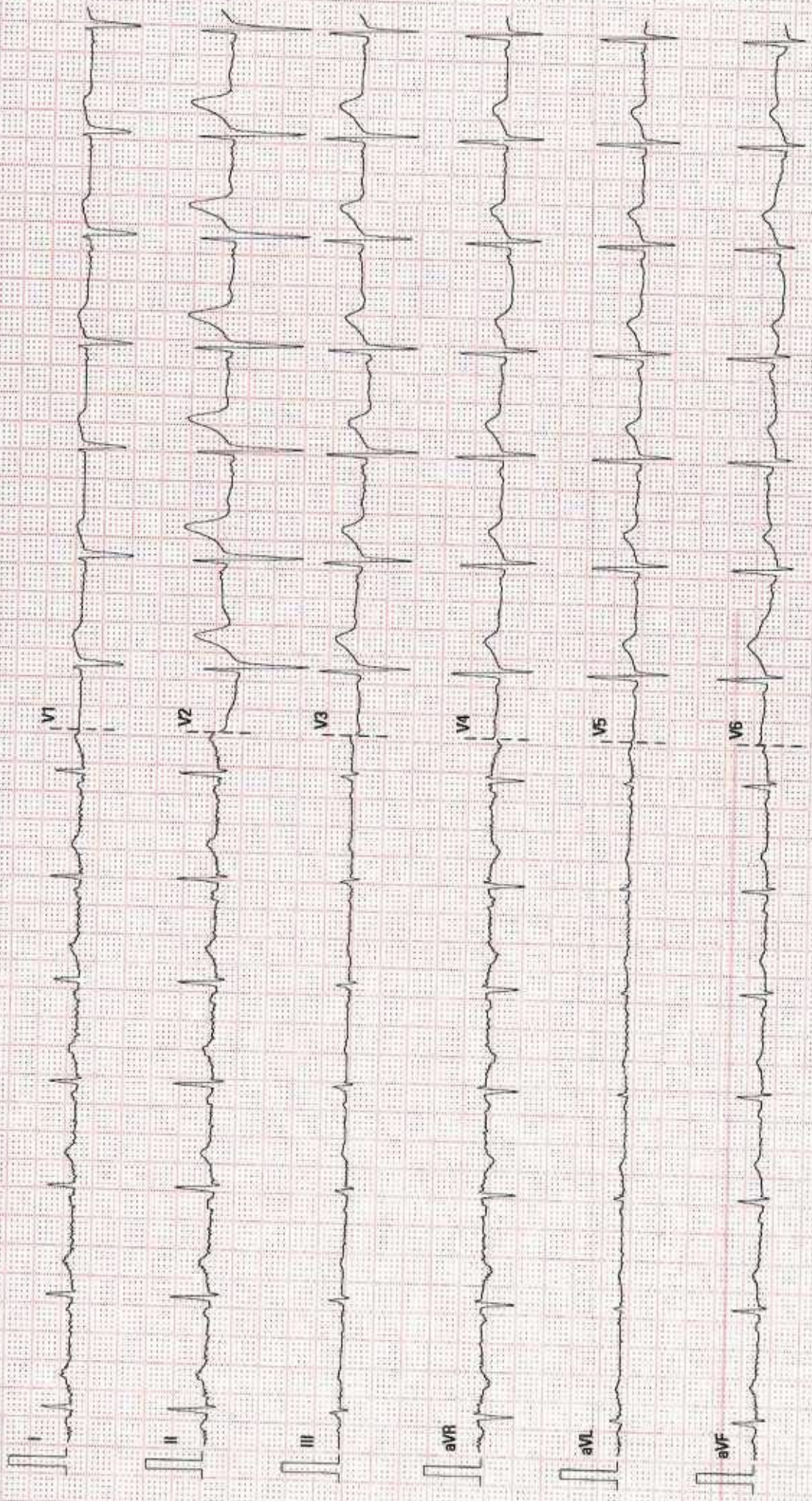
ID: 0717  
Name: PRATIK YEDTIKAR  
Age: Male  
Gender: Male

09-11-2024 10:45:55 AM

Rate: 81 bpm  
PR Interval: 120 ms  
QRS Duration: 76 ms  
QT/QTc Interval: 362/399 ms  
P/QRS/T Axes: 44/38/44 deg  
QTc: Hodges

Sinus rhythm  
--- Interpretation made without knowing patient's age ---  
Normal ECG

Unconfirmed Diagnosis.



25 mm/s 10 mm/mV 50 Hz BOR 35 Hz

MEDICOVER HOSPITALS

02.10.00128.4.1

SIN-FN-43046618