


Lata



MALIK RADIX HEALTH CARE PVT. LTD.
 C-217, C-218, Nirman Vihar,
 Delhi-110092
 Ph.: 011-49287456, 011-61381379
 Regd. No. 607

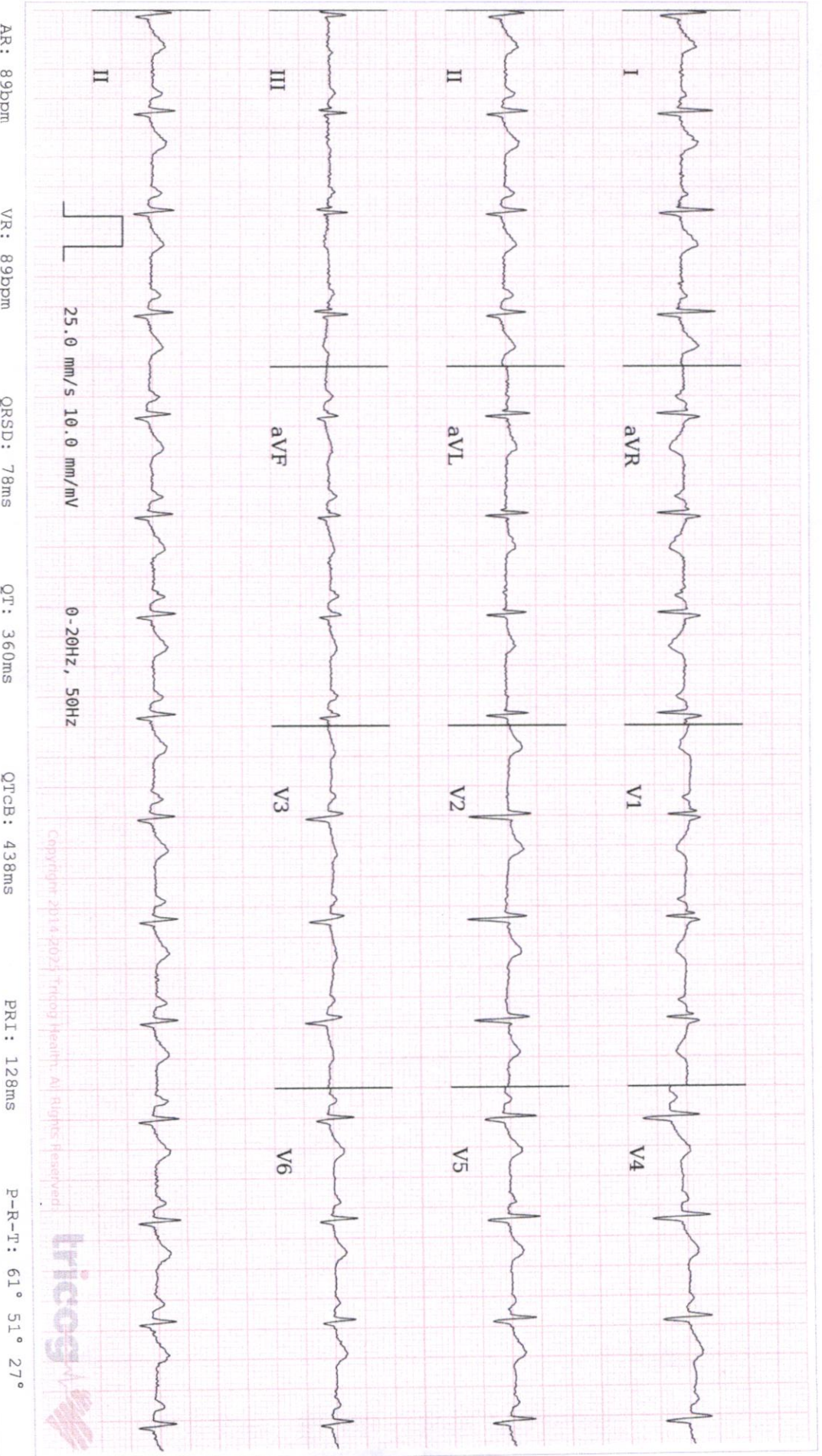


Age / Gender: 54/Female
 Patient ID: 9574120126

Malik Radix Health Care, Delhi

Date and Time: 8th Mar 25 10:17 AM

Dr. P. S. Shetty



ECG Within Normal Limits: Sinus Rhythm. rsr' Pattern in V1. Please correlate clinically.

REPORTED BY

Dr. Preema S Shetty



Disclaimer: Analysis in this report is based on ECG alone and should only be used as an adjunct to clinical history, symptoms and results of other invasive and non-invasive tests and must be interpreted by a qualified physician.

Malik Radix HealthCare.

ELECTROCARDIOGRAM

Name: MRS.LATA KUMARI SINGH

Age & Sex: 54YRS/FEMALE

Ref by: MEDIWHEEL

DATE: 08/03/2025

ECG FINDINGS:

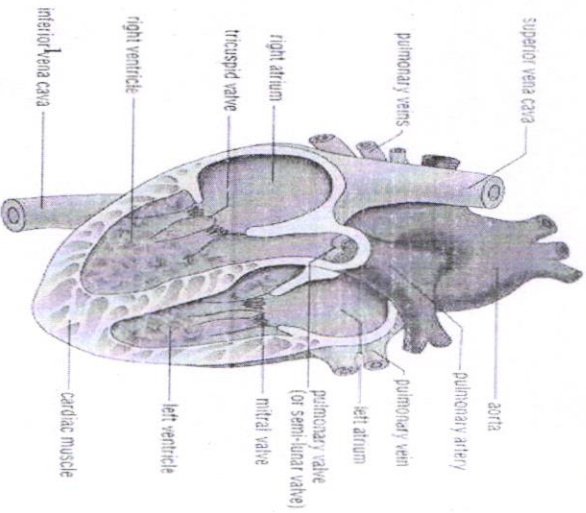
Rate 89 bpm Rhythm Sinus Mechanism Normal

Axis Normal Wave Normal PR Interval 0.12/Sec

QRS Complex Normal QT Interval Normal Q Wave Normal

ST Segment Normal T Wave Normal

Conclusion Sinus Rhythm (HR- 89 bpm), Normal Axis, To be correlate.



Doctors Signature
DR. SHEKHANAZIR AHMED
M.D. "Physician"
PGDCC
DMC-46499




Echocardiogram Report

Patient Name	MRS. LATA KUMARI SINGH
Date of Test	08/03/2025
Age	54YRS/FEMALE
Ref. by	MEDIWHEEL

Dimensions	Result	Normal Range
AO (ed)	2.9 cm	(2.1 -3.7cm)
LA (es)	3.0 cm	(2.1 -3.7cm)
RVID (ed)	1.9 cm	(1.1-3.0cm)
LVID (ed)	3.6 cm	(3.6 – 5.5 cm)
LVID (es)	2.5 cm	(2.3-3.9cm)
IVS (ed)	1.1 cm	(0.6 – 1-2 cm)
LVPW (ed)	1.1 cm	(0.6 – 1-2 cm)
EF	58 %	
FS	30 %	(28 % - 42 %)

Impression:

- NO REGIONAL WALL MOTION ABNORMALITY SEEN.
- LVEF= 58 %
- NORMAL CHAMBER DIMENSIONS.
- STAGE I LV DIASTOLIC DYSFUNCTION.
- NORMAL COLOR FLOW
- NO INTRA CARDIAC CLOT/MASS/ VEGETATION/PERICARDIAL EFFUSION SEEN.


 Dr. Sheikh Nazir Ahmed
 M.D. "Physician" PGDCC
 (Consultant Non – Invasive Cardiologist)

Facilities Available

- Multispeciality Hospital - 24 Hours Emergency - X-Ray/ ECG/ Ultrasound/ CT Scan - Dental- Fully Equipped Operation Theatre
 - Fully Functional Lab - 24/7 Casualty/ ICU-Nursery 24/7 Pharmacy - Labour Room - All Speciality OPD - Laproscopic Surgery -
 ECHO - Plastic Surgery



CONSULTANTS ON PANEL

PAEDIATRICS

Dr Ravi Malik (MBBS, MD)
Dr Harit Prasad (MBBS, MD, Pfd)
Dr Ritu Jain (MBBS, MD)

GYNAECOLOGY

Dr Renu Malik (MBBS, MD)
Dr Meena Malhotra (MBBS, MD)
Dr Rajni (MBBS, MD)
Dr Manju Gupta (MBBS, MS)
Dr Vaishali Saini (MBBS, DGO)
Dr Rupam Arora (MBBS, MD)

DENTAL

Dr Shruti Malik (BDS, MDS)
Dr Annu Saini (BDS, MDS)
Dr Rachit Thukral (BDS, MDS)
Dr Mohit Mangla (BDS, MDS)
Dr Tarun Mittal (BDS, MDS)
Dr Geetika Sharma (BDS)
Dr Shilpa Verma (BDS)

CHILD GASTROENTEROLOGY

Dr S. K Mittal (MBBS, MD)

MEDICINE

Dr A S Talwar (MBBS, MD)
Dr Sunny Uppal (MBBS, MD)
Dr Surendra Rajpal (MBBS, MD)

RESPIRATORY MEDICINE /PULMONOLOGY

Dr Abhinav Bhanot (MBBS, DNB)

LAPAROSCOPY SURGERY

Dr Ajay Jain (MBBS, MS)
Dr Deepak Saran (MBBS, MS)
Dr Pradeep Saini (MBBS, MS)
Dr G. S Garg (MBBS, MS)

ORTHOPAEDICS

Dr Vikas Bhardwaj (MBBS, MS ORTHO, DNB)
Dr Prabhhat Aggarwal (MBBS, MS ORTHO)
Dr KB Tiwari (MBBS, MS ORTHO)
Dr Deepak Kumar Arora (MBBS, MS ORTHO)

EYE/OPHTHALMOLOGY

Dr Nidhi Gupta (MBBS, MS, DNB, PGDM)
Dr Himanshu Singh Pundir (MBBS, MS)

ENT

Dr Sharad Kumar Singhi (MBBS, MS)
Dr Prateek Sharma (MBBS, MS)
Dr Ashok Singh (MBBS, MS)
Dr A K Lahiri (MBBS, MS)

RADIOLOGY(ULTRASOUND)

Dr K K Sinha (MBBS DNRB)
Dr T K Vohra (MBBS, MD)
Dr Rajesh Malhotra (MBBS, MD)
Dr Ashish Tomar (MBBS, MD)

PATHOLOGY

Dr Reema Dahiya (MBBS, MD PATH)
Dr Meenu Aggarwal (MBBS, MD PATH)

ANAESTHESIA

Dr Rajesh Dhali (MBBS, MD)
Dr Rakesh Atray (MBBS, MD)
Dr R K Arora (MBBS, MD)
Dr Swaraj Garg (MBBS, MD)

DERMATOLOGY

Dr Niharika Jha (MBBS, MD)

PLASTIC & COSMETIC SURGERY

Dr Ayush Jain (MBBS, MS, MCh)

PAEDIATRIC SURGERY

Dr Dharmendra Singh (MBBS, MS, M.Ch)
Dr Satish Aggarwal (MBBS, MS, M.Ch)

PAEDIATRIC NEPHROLOGY

Dr A S Vasudev (MD, Dip.in. Paed.)

NEPHROLOGY

Dr Javed (MBBS, MD, Nephro)

CARDIOLOGY

Dr Nishant Tyagi (MBBS, MD)

NEUROLOGY

Dr Amit Batra (MBBS, MD)

GASTROENTEROLOGY

Dr Deepak Lahoti (MBBS, MD)
Dr Naresh Aggarwal (MBBS, MD)
Dr Ashok Goyal (MBBS, MD)
Dr Ankur Singhal (MBBS, MD)

UROLOGY

Dr Nikhil Sharma (MBBS, Mch)

Dr Ankur Singhal (MBBS, MD)

PSYCHIATRY

Dr Mohit Sharma (MBBS, MD)

PHYSIOTHERAPY

Dr Kirti Dwivedi

Dr Ravi Kumar

NUTRITIONIST

Dr Deepika Kohli

Dr Sakshi Rana

CLINICAL PSYCHOLOGIST

Dr. Sarika Singh

Dr. Shruti Malik

BDS, MDS (Endodontics)
☎ +91-9899561092

Name : data kumari singh.
Age/Sex : 54 yrs / f
Date : 8/3/25

**Timings : 10:00 am. to 2:00 pm.
6:00 pm. to 8:30 pm.**

For Appointment

☎ 011-45152510
☎ +91-9999254639

CLINICAL EXAMINATION:-

1. TMJ:-

pt complain decay tooth ~~in~~
IM front tooth region
since 4-5 yrs.

2. DENTAL STATUS:

- a. Caries Teeth :
- b. Fracture Teeth :
- c. Root Stumps :
- d. Gingivitis :
- e. Periodontitis :
- f. Impacted Teeth :
- g. Malaligned Teeth :

M/H → ~~not~~ pt is on
myoain medication.
O/S → missing root
cariouls root
severe attrition

3. ORAL LESIONS:-

4. DIAGONISIS:-

ADU → OPG

5. TREATMENT PLANNING:

6. FOLLOW UP:-

Referral To Other Consultant: Yes/ No

If Yes, please mention the Name:

Doctor's Signature 8/3/25

ACT-5K
Crown-5K
7K

Facilities Available :

- ★ MULTI-SPECIALITY HOSPITAL ★ MODULAR FULLY EQUIPPED OT ★ NURSERY ★ LAPROSCOPIC SURGERY
- ★ 24X7 EMERGENCY ★ OPG ★ DENTAL ★ 24X7 DIAGNOSTICS ★ LABOUR ROOM ★ ECHO ★ EEG ★ DIGITAL X-RAY ★ CT SCAN
- ★ ECG ★ ULTRASOUND ★ RICU/ICU ★ ALL SPECIALITY OPD ★ PLASTIC & COSMETIC SURGERY ★ DIALYSIS ★ PHARMACY



EYE EXAMINATION (AHC)

Name: Mrs. Lata Kumari Singh	Age & Gender: 54 / F
Ref.by: Medic Wheel	Date: 08/03/25

Without Correction		With Correction	
Distance - Right	6/9	Distance - Right	6/6
Left	6/9	Left	6/6
Near - Right	N ₃₆	Near - Right	N ₃₆
Left	N ₃₆	Left	N ₃₆

Color Vision: Normal Abnormal

Diagnosis: Presbyopia

Treatment Recommended: use near glasses

Dr. Nidhi Gupta
 MBBS, MS, DNB
 Casualtant Ophthalmologist
 Malik Radix Healthcare Pvt. Ltd.
 DMC No. 121661

Facilities Available

- Multispeciality Hospital - 24 Hours Emergency - X-Ray/ ECG/ Ultrasound/ CT Scan - Dental- Fully Equipped Operation Theatre
- Fully Functional Lab - 24/7 Casualty/ ICU-Nursery 24/7 Pharmacy - Labour Room - All Speciality OPD - Laproscopic Surgery - ECHO - Plastic Surgery



LAB REPORT

Reg. Date	08/03/2025	Patient Id	2503080004	DOB.	30/12/1970
Name	MRS. LATA KUMARI SINGH	Gender	F	Perm. ID	
Age	54 Yrs. 2 Mn. 8 Day	Panel	MEDIWHEEL	Reported	08/03/2025 18:22:03
Ref. By	MEDIWHEEL				

Test Name	Result	Units	Ref. Range
PLUS CHECK ADVANCED F ANNUAL			

HAEMATOLOGY

COMPLETE HAEMOGRAM

HAEMOGLOBIN (HB%)	13.4	gm/dl	12 - 15
TOTAL LEUCOCYTE COUNT (TLC)	4,270	/cumm	4000 - 11000
DIFFERENTIAL LEUCOCYTE COUNT (DLC)			
NEUTROPHIL	48.6	%	40 - 80
LYMPHOCYTE	41.0	%	28 - 55
MONOCYTE	4.7	%	02 - 10
EOSINOPHIL	5.2	%	01 - 06
BASOPHIL	0.5	%	0 - 0
ESR (WESTEGREN'S METHOD)	15	mm/1st hr.	0 - 15
R B C COUNT	4.76	Millions/cmm	4.5 - 5.5
P.C.V / HAEMATOCRIT	43.2	%	35 - 45
M C V	90.8	fl.	80 - 100
M C H	28.2	Picogram	27.0 - 31.0
M C H C	31.0	gm/dl	33 - 37
PLATELET COUNT	2.14	Lakh/cu mm	1.50 - 4.50

Urine Routine Examination

PHYSICAL EXAMINATION

QUANTITY	40	ml.	
COLOUR	Pale Yellow		Pale Yellow
TRANSPARENCY	Clear		
SPECIFIC GRAVITY	1.015		
PH	6.5		

Checked by : _____
Page 1 Contd...2

If test results are alarming or unexpected, patient is advised to contact the laboratory immediately for possible remedial action.

Facilities Available

- Multispeciality Hospital - 24 Hours Emergency - X-Ray/ ECG/ Ultrasound/ CT Scan - Dental- Fully Equipped Operation Theatre
- Fully Functional Lab - 24/7 Casualty/ ICU-Nursery 24/7 Pharmacy - Labour Room - All Speciality OPD - Laproscopic Surgery -
ECHO - Plastic Surgery



LAB REPORT

Reg. Date	08/03/2025	Patient Id	2503080004	DOB.	30/12/1970
Name	MRS. LATA KUMARI SINGH	Gender	F	Perm. ID	
Age	54 Yrs. 2 Mn. 8 Day	Panel	MEDIWHEEL	Reported	08/03/2025 18:22:03
Ref. By	MEDIWHEEL				

Test Name	Result	Units	Ref. Range
CHEMICAL EXAMINATION			
ALBUMIN	Nil		
SUGAR	Nil		
MICROSCOPIC EXAMINATION			
PUS CELLS	2-3	/HPF	
RBC'S	Nil	/HPF	
CASTS	Nil		
CRYSTALS	NIL		
EPITHELIAL CELLS	2-3	/HPF	
BACTERIA	Nil		
OTHERS	Nil		
BLOOD GROUP ABO	" A "		
RH TYPING	Positive		
BLOOD SUGAR FASTING	94.48	mg/dl	70 - 100
BLOOD SUGAR PP	97.42	mg/dl	90 - 140
HB A1C	5.4	%	04 - 5.7

Interpretation

NON- DIABETIC	:<5.7 %
PRE DIABETES	: 5.7- 6.4%
DIABETES	: >6.5%
GOOD CONTROL DIABETES	: <7 %

Checked by : -----
 Page 2 Contd...3

If test results are alarming or unexpected, patient is advised to contact the laboratory immediately for possible remedial action.

Facilities Available

- Multispeciality Hospital - 24 Hours Emergency - X-Ray/ ECG/ Ultrasound/ CT Scan - Dental- Fully Equipped Operation Theatre
 - Fully Functional Lab - 24/7 Casualty/ ICU-Nursery 24/7 Pharmacy - Labour Room - All Speciality OPD - Laproscopic Surgery -
 ECHO - Plastic Surgery



LAB REPORT

Reg. Date	08/03/2025	Patient Id	2503080004	DOB.	30/12/1970
Name	MRS. LATA KUMARI SINGH	Gender	F	Perm. ID	
Age	54 Yrs. 2 Mn. 8 Day	Panel	MEDIWHEEL	Reported	08/03/2025 18:22:03
Ref. By	MEDIWHEEL				

Test Name	Result	Units	Ref. Range
-----------	--------	-------	------------

The Glycosylated haemoglobin assay has been validated as a reliable indicator Of mean blood glucose levels for a period of 8-12 week period. ADA recommended the testing twice a year in patients with stable blood glucose and quarterly. If treatment change, or if blood glucose levels are unstable.

TO BE CORRELATED CLINICALLY.

THYROID PROFILE

Free T3 ELFA	1.13	ng/ml	02 - 04
Free T4 ELFA	1.62	ug/dl	0.8 - 2.7
TSH Serum/ELFA	3.270	uIU/ml	0.25 - 5.50 uIU/ml

Interpretation

Clinical Use

- Diagnose Hypothyroidism and Hyperthyroidism
- Monitor T4 replacement or T4 suppressive Therapy
- Quantify TSH levels in the subnormal range

Increased Levels : Primary Hypothyroidism Subclinical Hypothyroidism, TSH dependent, Thyroid Hormone Resistance.

Decreased Levels : Grave's Disease, Autonomous Thyroid Hormone Secretion, TSH Deficiency

LIPID PROFILE

TOTAL CHOLESTEROL	210.63	mg/dL	130.0 - 200.0 (<200)
TRIGLYCERIDES	104.86	mg/dL	80.5 - 150.0 (<150)

Checked by : _____
Page 3 Contd...4

If test results are alarming or unexpected, patient is advised to contact the laboratory immediately for possible remedial action.

Facilities Available

- Multispeciality Hospital - 24 Hours Emergency - X-Ray/ ECG/ Ultrasound/ CT Scan - Dental- Fully Equipped Operation Theatre
- Fully Functional Lab - 24/7 Casualty/ ICU-Nursery 24/7 Pharmacy - Labour Room - All Speciality OPD - Laproscopic Surgery - ECHO - Plastic Surgery



LAB REPORT

Reg. Date 08/03/2025
Name MRS. LATA KUMARI SINGH
Age 54 Yrs. 2 Mn. 8 Day
Ref. By MEDIWHEEL

Patient Id2503080004
Gender F
Panel MEDIWHEEL

DOB. 30/12/1970
Perm. ID
Reported08/03/2025 18:22:03

Test Name	Result	Units	Ref. Range
H D L CHOLESTEROL DIRECT	44.86	mg/dL	42.0 - 60.0 (<40->59)
V L D L	21.0	mg/dL	4.0 - 30. (23-45)
L D L CHOLESTEROL	144.8	mg/dL	50.0 - 150.0 (50-150)
TOTAL CHOLESTEROL / HDL RATIO	4.7		3.3 - 5.1
LDL / HDL CHOLESTEROL RATIO	3.2		1.5 - 3.5
SERUM URIC ACID	3.89	mg/dl	2.4 - 6.0
BLOOD UREA NITROGEN (BUN)	25.00	mg/dl	6.0 - 21.0
SERUM CREATININE	0.61	mg/dl	0.6 - 1.2
BUN/CREAT RATIO	40.9	mg/dl	10 - 20
<u>LIVER FUNCTION TEST (LFT)</u>			
BILIRUBIN TOTAL	0.32	mg/dl	0.2 - 1.2
CONJUGATED (D. BILIRUBIN)	0.10	mg/dl	0.00 - 0.3
UNCONJUGATED (I.D.BILIRUBIN)	0.22	mg/dl	0.2 - 0.9
SGOT / AST	27.30	IU/L	0 - 35
SGPT / ALT	32.0	IU/L	0 - 35
ALKALINE PHOSPHATASE	109.40	U/L	64 - 306
TOTAL PROTEIN	7.60	gm/dl	6.0 - 8.3
ALBUMIN	4.56	gm/dl	3.2 - 5.0
GLOBULIN	3.04	gm/dl	2.5 - 5.6
A/G RATIO	1.50		0.9 - 2.0
GAMMA GT	32.60	IU/L	0.0 - 35.0

Meenu Aggarwal
DR. REEMA DAHIYA
DR. M.B.S. MD (Path)
Malik Radix Healthcare Pvt. Ltd.
Malik Radix Healthcare Pvt. Ltd.
Checked by :
Page 4 of 4

DR. MEENU AGGARWAL
M.B.B.S, MD (Path.)

If test results are alarming or unexpected, patient is advised to contact the laboratory immediately for possible remedial action.

Facilities Available

- Multispeciality Hospital - 24 Hours Emergency - X-Ray/ ECG/ Ultrasound/ CT Scan - Dental- Fully Equipped Operation Theatre
- Fully Functional Lab - 24/7 Casualty/ ICU-Nursery 24/7 Pharmacy - Labour Room - All Speciality OPD - Laproscopic Surgery - ECHO - Plastic Surgery

R

1000 KUMARI SINGH 54Y F PT236474 CHEST PA 08 03 2025 10 00 00
PAY BY THE PATIENT FOR CHEST PA 08 03 2025 10 00 00



UHID	PT236474	LAB No.	XRY2423379
Name	Mrs. LATA KUMARI SINGH	Regn. No.	GEN2445975
Age / Sex	54 Yrs / F	Receiving Dt/Time	08-Mar-2025 10:06
		Reporting Dt/Time	08-Mar-2025 05:12 PM



XRAY

CHEST (PA)

Both lung fields are normal.

Cp angles are clear.

Hila are normal...

Heart size appears within normal limits.

Soft tissue shadows and bony thorax are normal.

Advised....please correlate clinically.

***** END OF REPORT *****

Approved By :

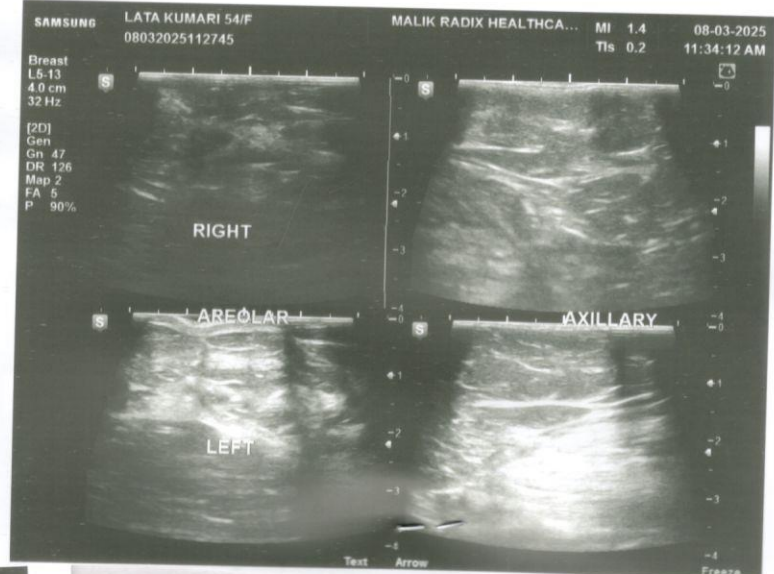
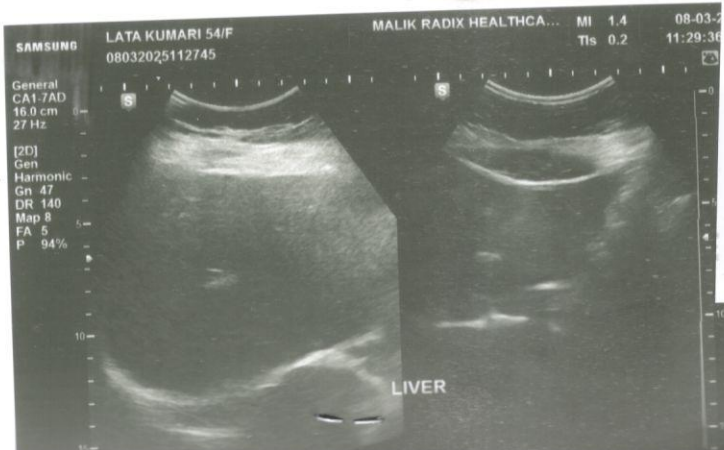
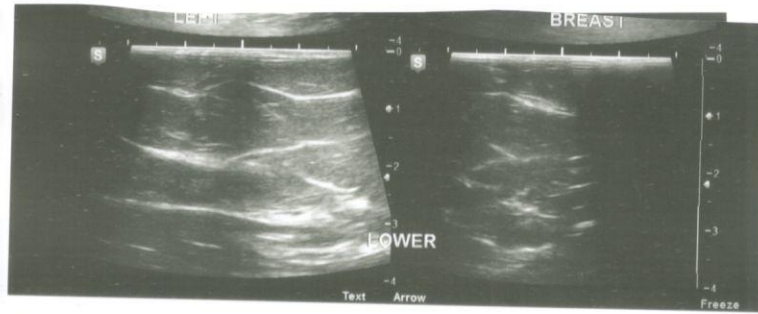
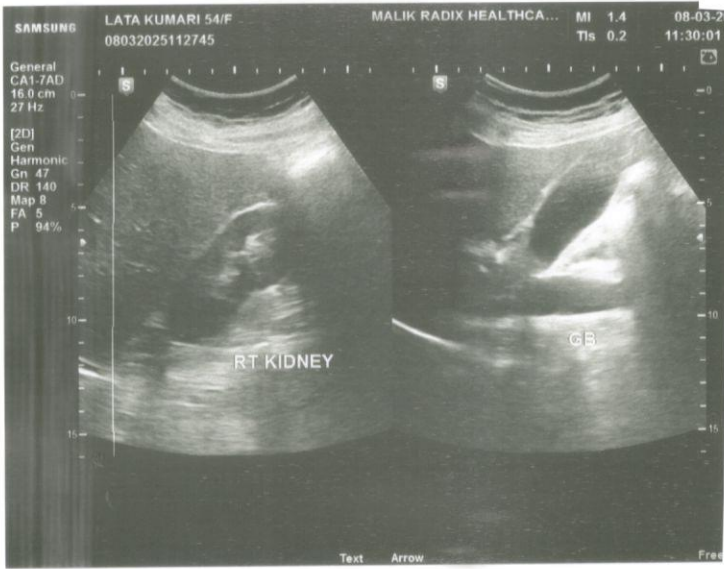
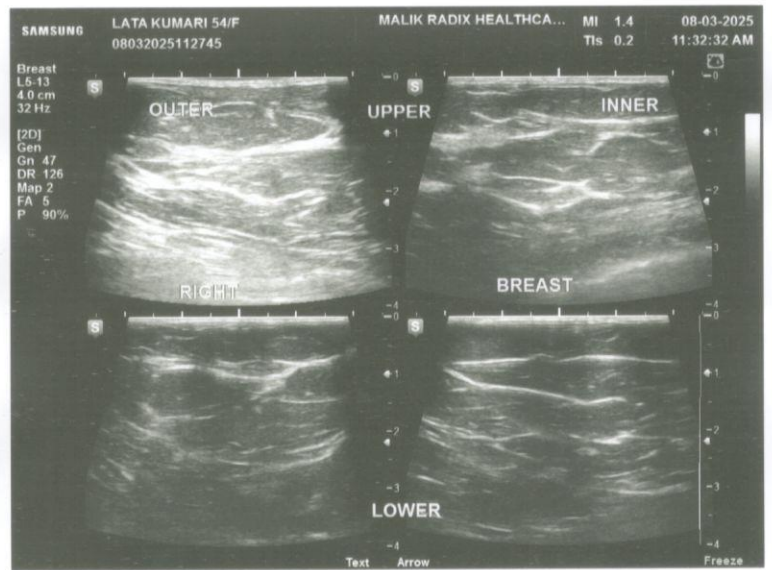
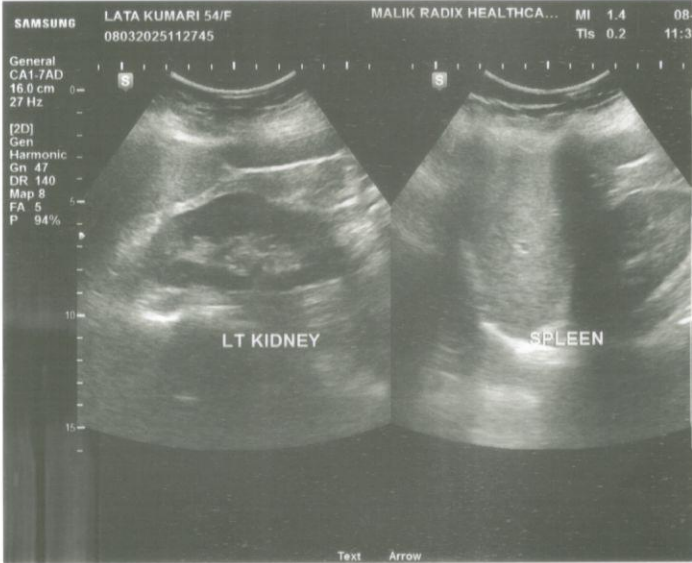
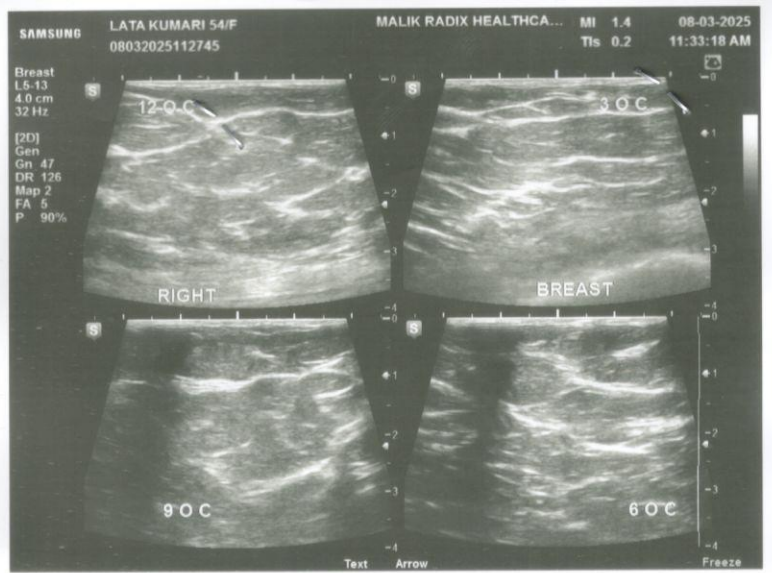
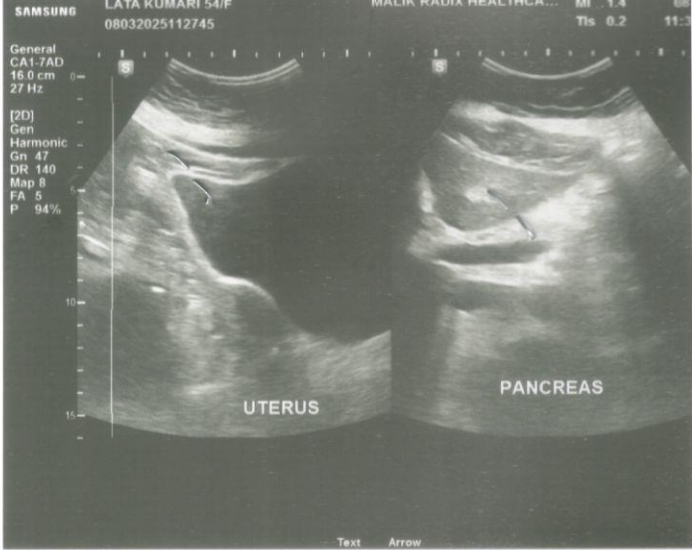
Approval Date : 00:00:00

DR. K.K. SINHA
M.B.B.S., D.M.R.D.
SENIOR CONSULTANT
Reg. No. 25437 (DMC)

DR. T. K VOHRA
MD (RADIOLOGIS)
SENIOR CONSULTANT
Reg. No. 3272 (DMC)

DR. MUKESH KOSHAL
MBBS, MD (RADIOLOGY)
CONSULTANT RADIOLOGY
Reg.No.DMC10407

Facilities Available



**RADIX
HEALTH
care**



Malik Radix Healthcare

C/217, C/218, Vikas Marg, Nirman Vihar, New Delhi-110092
A Unit of Malik Radix Healthcare
Toll Free - 1800-120-5457, Tel. : 011 49287456, 61381379
Whatsapp No. - 9811550650
E-mail: radixhealthcare@yahoo.co.in
Website: www.radixhealthcare.org



NAME	MRS LATA KUMARI SINGH	AGE	54 Y/F
REFD. BY.	HEALTH CHCEK UP	DATE	08.03.24

Ultrasound Examination of Breasts:

US examination of both breasts was performed using a high frequency probe.

On US both breasts show the normal appearances of post-menopausal adult breasts. Normal echogenic adipose tissue is seen. The glandular elements are sparse. The fibrous tissue stroma is well defined. No evidence of any SOL or abnormal calcification seen. No evidence of any abscess seen. Areolar and axillary regions are normal.

NORMAL STUDY.

Regards.

Dr Mukesh Koshal MD (Rad- diag)
Regn. No. DMC 10407

RADIOLOGIST :

Facilities Available

- Multispeciality Hospital - 24 Hours Emergency - X-Ray/ ECG/ Ultrasound/ CT Scan - Dental- Fully Equipped Operation Theatre
- Fully Functional Lab - 24/7 Casualty/ ICU-Nursery 24/7 Pharmacy - Labour Room - All Speciality OPD - Laproscopic Surgery -

RADIX
HEALTH
care



Radix Healthcare

Malik Radix Healthcare

C/217, C/218, Vikas Marg, Nirman Vihar, New Delhi-110092
A Unit of Malik Radix Healthcare
Toll Free - 1800-120-5457, Tel. : 011 49287456, 61381379
Whatsapp No. - 9811550650
E-mail: radixhealthcare@yahoo.co.in
Website: www.radixhealthcare.org



NAME	MRS LATA KUMARI SINGH	AGE	54 Y/F
REFD. BY.	HEALTH CHCEK UP	DATE	08.03.24

Ultrasound Examination of Whole Abdomen & Pelvis:

Liver: Liver shows normal parenchymal echotexture. No focal SOL is seen in liver. IHBR & portal radicles are normal.

Gallbladder: Gallbladder shows normal anechoic pattern. No evidence of cholecystitis or cholelithiasis seen. Common bile duct is normal in course & caliber.

Pancreas: Pancreas shows normal size & echotexture.

Spleen: Spleen shows normal size, outline & echotexture.

Kidneys: Kidneys show normal size, shape, position & echotexture. No calculus, hydronephrosis or SOL is seen in kidneys. Cortico- medullary differentiation and cortical thickness is normal on both sides.

No supra- renal mass seen.

Great abdominal vessels are normal.

Domes of diaphragm are seen to move normally & synchronously in respiration. No supra- or infra diaphragmatic collection is seen.

No ascites or pericardial effusion seen.

No para-aortic lymph nodes seen.

Urinary bladder: Urinary bladder shows normal anechoic pattern. No calculus, SOL or diverticulum seen.

Uterus: Uterus & adnexa normal for age.

Regards.


Dr Mukesh Koshal MD (Rad- diag)
Regn. No. DMC 10407

RADIOLOGIST :

Facilities Available

- Multispeciality Hospital - 24 Hours Emergency - X-Ray/ ECG/ Ultrasound/ CT Scan - Dental- Fully Equipped Operation Theatre
- Fully Functional Lab - 24/7 Casualty/ ICU-Nursery 24/7 Pharmacy - Labour Room - All Speciality OPD - Laproscopic Surgery -