



GEETANJALI HOSPITAL

270, Gurudwara Road, Near Post Office, Model Town, Hisar, Haryana
geetanjalihospitalhisar@gmail.com | www.geetanjalihospitalhisar.com

+91-99925-64300, +91-90680 23930



H-2020-0688
Jan 11, 2023 – Jan 10, 2027
Since Jan 11, 2020

Name: Mrs. Jyoti	AGE: 40 Y/F	Lab. No. 3735
Order From : OPD	Receipt No: 3035	DATE: 23.10.2024
Ref. by: Lotus Diagnostic	Echogenecity: Adequate	Time of Test: 01:21 PM

Referring diagnosis: Cardiac evaluation

TRANS THORACIC ECHOCARDIOGRAPHY/DOPPLER REPORT

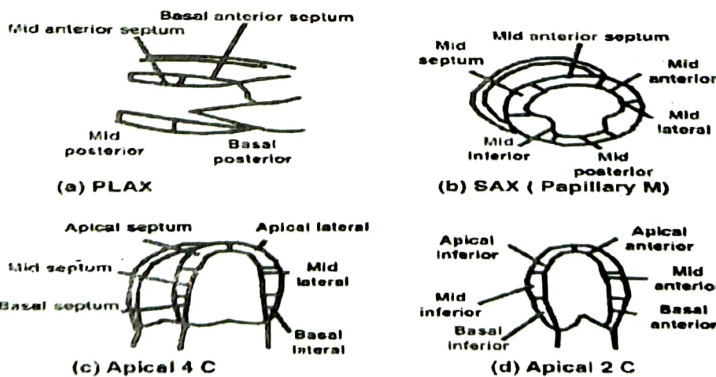
M Mode Parameters	Patient	Normal
Left Ventricular ED Dimension	4.61 cm	3.7-5.6 cm
Left Ventricular ES Dimension	3.20 cm	2.2-4.0 cm
IVS (D)	0.92 cm	0.6-1.2 cm
IVS (S)	1.17 cm	1.0-1.5 cm
LVPW (D)	0.92 cm	0.6-1.2 cm
LVPW (S)	0.92 cm	1.0-1.5 cm
Aortic Root Diameter	2.62 cm	2.0-3.7 cm
LA Diameter	3.83 cm	1.9-4.0 cm
RV Dimension	2.02 cm	0.7-2.6 cm

Indices of LV systolic Function	Patient	Normal
Ejection Fraction	58 %	55-80%
Fraction Shortening	30 %	28-42%

LV Diastolic Function

Mitral Inflow Pattern	Patient	Normal Value
E Wave	0.74 m/s	0.85±0.16
A Wave	0.52 m/s	0.56±0.12
E/A	1.41	1.06±0.5
DT	192.59 ms	160-200ms
MVA(PHT method)	4.10 cm ²	3.5-5.5cm ²

LV Regional Wall Motion Analysis: WNL



Patient's identity can not be ascertained at present, so this report can not be used for MLC Case.

Disclaimer: • Size & position of renal calculi may differ on different occasions. • Ureteric calculi may not be visible in absence of hydronephrosis. • Gall stones may not be visible in contracted state. • Genital anomalies may not be detectable on routine obstetric scan. • For some foetal anomalies, serial ultrasound examination are required. • For Gynecological disease, transvaginal ultrasound (TVS) shows better results. • Not valid for medico legal purposes. • If the result (s) is/are alarming or unexpected, the patient/consultant is advised to contact Centre immediately for a check. • This is only a professional opinion, it may kindly be correlated clinically. • No procedure/surgery is advised on the basis of this report only. • This Report is for the purpose of doctor only.



GEETANJALI HOSPITAL

270, Gurudwara Road, Near Post Office, Model Town, Hisar, Haryana

geetanjalihospitalhisar@gmail.com | www.geetanjalihospitalhisar.com

+91-99925-64300, +91-90680 23930



H-2020-0688
Jan 11, 2023 – Jan 10, 2027
Since Jan 11, 2020

Name: Mrs. Jyoti AGE: 40 Y/F Lab. No. 3735 DATE: 23.10.2024 ..2..

M-Mode/2-D Description: -

1. Left ventricle: - it is normal in size. The wall does not show any hypertrophy or thinning. No regional wall motion abnormality seen. LVEF= 58%. Mitral Valve inflow pattern reveals E>A suggestive of Normal LV Diastolic dysfunction.
2. Left atrium: it is normal sized.
3. Right atrium: it is normal sized.
4. Right ventricle: it is normal sized. RV systolic function is normal.
5. Aortic valve: - Aortic cusps are normal. No evidence of Aortic stenosis.
6. Mitral valve: - opens normally. Subvalvular apparatus appears normal. No evidence of Mitral stenosis.
7. Tricuspid valve: - it appears normal.
8. Pulmonic valve: - it appears normal.
9. Main pulmonary artery & its branches appear normal.
10. Pericardium: No pericardial effusion seen.
11. IVS/IAS: Intact
12. Pulse Rate- 82 beats per minute.
13. IVC is not dilated in size & Collapse >50% with Inspiration s/o RA pressure of 05 mmHg.

IVC COLLAPSIBILITY INDEX:

Max Diameter: 0.88 Cm, Min. Diameter: 0.12 Cm, Index: 86%

Doppler/CFM Findings:

Valve	Peak Velocity (m/sec)	Peak Gr (mmHg)	Mean Gr (mmHg)	Regurgitation
Mitral Valve	-	-	-	Nil
Aortic Valve	-	-	-	Nil
Tricuspid Valve	-	-	-	Nil
Pulmonary Valve	-	-	-	Nil

Final Interpretation:

No regional wall motion abnormality LVEF= 58%.

Normal LA, LV, RA and RV chamber dimensions.

Normal LV Diastolic Function. No intracardiac clot/mass/ pericardial pathology.

	Name	Signature	Date & Time
Echocardiographer	Dr. Anshul Jain		23.10.2024; 02:00 PM

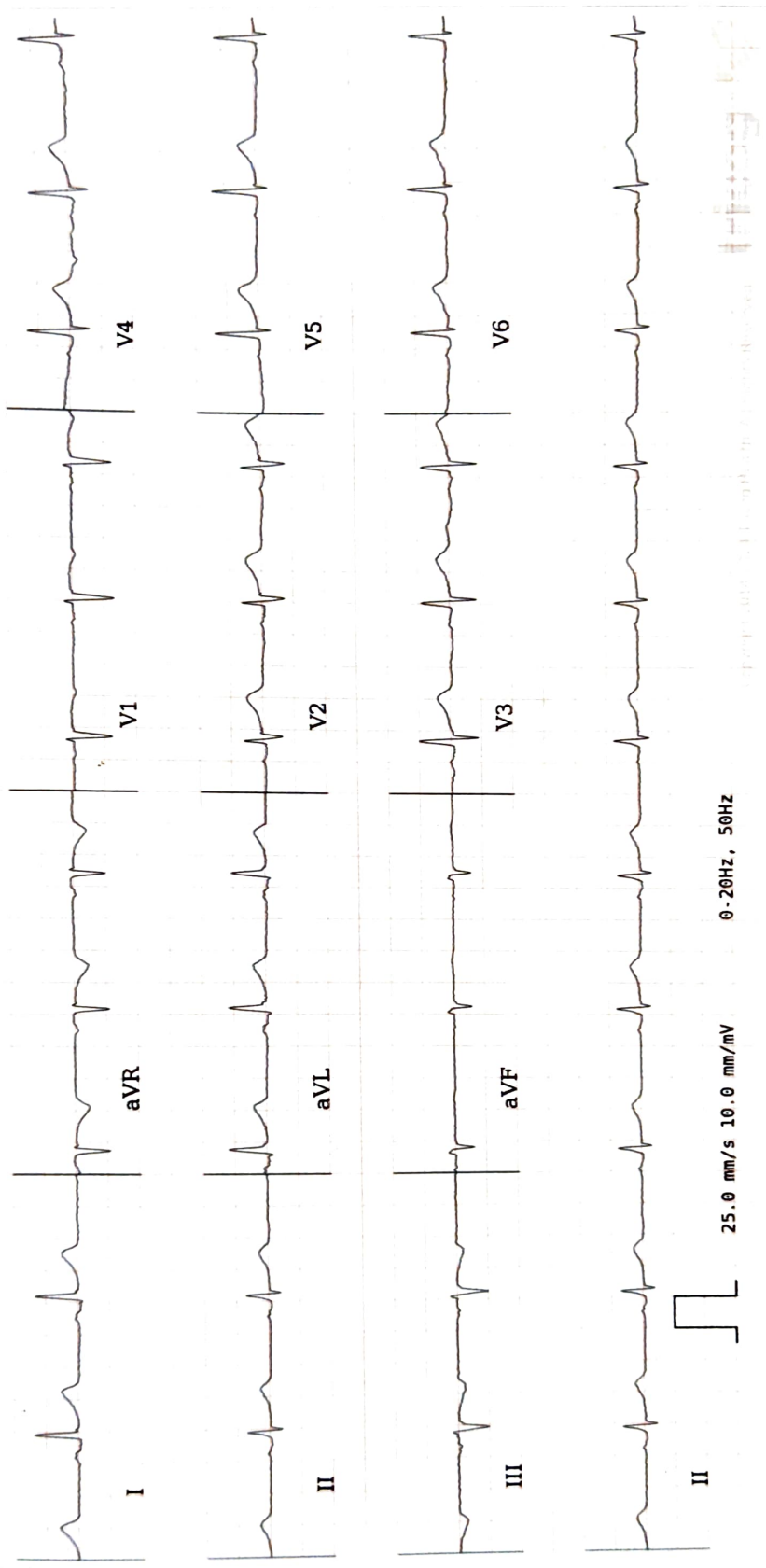
NOTE: This is just a professional opinion. The findings should be clinically co-related. These are the findings on the day of test. This report is not valid for any medico-legal purposes. No record of this report is kept in the hospital.

Report Typed By :- Mr. Abhishek (Emp. ID - 629).

Patient's identity can not be ascertained at present, so this report can not be used for MLC Case.

Size & position of renal calculi may differ on different occasions. Ureteric calculi may not be visible in absence of hydronephrosis. Gall stones may not be visible in contracted state. Genital anomalies may not be detectable on routine obstetric scan. For some foetal anomalies, serial ultrasound examination are required. For Gynecological disease, transvaginal (TVS) shows better results. Not valid for medico legal purposes. If the result (s) is/are alarming or unexpected, the patient/consultant is advised to contact Centre immediately for a This is only a professional opinion, it may kindly be correlated clinically. No procedure/surgery is advised on the basis of this report only. This Report is for the purpose of doctor only.

Age / Gender: 40/Female
 Patient ID: 0000231024
 Date and Time: 23rd Oct 24 10:52 AM



AR: 69bpm VR: 69bpm QRSd: 68ms QT: 384ms QTcB: 411ms PRI: 148ms P-R-T: -2° -14° NA

ECG Within Normal Limits: Sinus Rhythm. Please correlate clinically.

REPORTED BY



Dr. Nehra

Disclaimer: Analysis in this report is based on ECG alone and should only be used as an adjunct to clinical history, symptoms and results of other invasive and non-invasive tests and must be interpreted by a qualified physician.



PATIENT NAME: JYOTI SONI
REF BY: TPA

AGE/SEX: 40 YRS/F
DATE: OCTOBER 23, 2024

USG WHOLE ABDOMEN

Liver: normal in size. Parenchymal echotexture is normal and no focal area of altered echogenicity is seen. IHBR not dilated. CBD is normal in diameter.

GB: is normal, Wall thickness is normal.

Pancreas: head and body shows normal size and parenchymal attenuation.

Spleen: normal in size and normal echotexture.

Right Kidney: is normal in position, size and morphology. No evidence of any calculus detected. Pelvi calyceal system is normal. CMD is maintained.

Left Kidney: is normal in position, size and morphology. No evidence of any calculus detected. Pelvi calyceal system is normal. CMD is maintained.

Urinary Bladder: appears normal.

Uterus: is normal in size. E.T- 10.3 mm. No focal lesion seen.


B/L ovaries are normal in size. No adnexal mass lesion seen.

No obvious abnormal bowel dilatation or wall thickening is seen in present scan.

No free fluid seen.

IMPRESSION: - No significant abnormality seen sonologically

Clinical correlation and further evaluation is suggested.


Dr. Ram Baksh Sharma
Radiologist

Dr. Rambaksh Sharma
Consultant Radiologist

Dr. Guruprasad Mehetri
Consultant Radiologist

Dr. Rajesh Reddu
Consultant Radiologist

Dr. Sulekha Singh
Consultant Pathologist



Lotus Diagnostic & Imaging Centre

A Unit of Lotus Diagnostic & Imaging Solution Pvt. Ltd.

HB से लेकर MRI तक एक ही छत के नीचे

PATIENT NAME: JYOTI SONI
REF BY: TPA

AGE/SEX: 40 YRS/F
DATE: OCTOBER 23, 2024

ULTRASOUND BOTH BREAST

REPORT:

Small cyst of size 2.8 x 1.8 mm is seen at right breast supra-areolar region.


The breast parenchyma on both side shows normal echo-pattern with no definite focal lesion.

The nipple subareolar complex is normal on both side.

No definite enlarged node is seen in both axillae.

IMP: Small simple right benign breast cyst.

Clinical correlation & further evaluation is suggested.


Dr. Ram Baksh Sharma
Radiologist

Dr. Rambaksh Sharma
Consultant Radiologist

Dr. Guruprasad Mehetri
Consultant Radiologist

Dr. Rajesh Reddu
Consultant Radiologist

Dr. Sulekha Singh
Consultant Pathologist



Lotus Diagnostic & Imaging Centre

A Unit of Lotus Diagnostic & Imaging Solution Pvt. Ltd.

HB से लेकर MRI तक एक ही छत के नीचे

PATIENT NAME: JYOTI SONI
REF. BY: TPA

AGE/SEX: 40YRS/F
DATE: OCTOBER 23, 2024

X-RAY CHEST PA VIEW

- Bilateral lung parenchyma appears normal.
- Bilateral domes of diaphragm and costophrenic angles are normal.
- Cardiac and mediastinal shadow appear normal.
- Bilateral hila appear normal.
- Bony thorax and soft tissue appear normal.

Advised: Clinical correlation

Dr. Rambaksh Sharma
Consultant Radiologist

Dr. Guruprasad Mehetri
Consultant Radiologist

Dr. Rajesh Reddu
Consultant Radiologist

Dr. Sulekha Singh
Consultant Pathologist