

Saturday, March 08, 2025
DHANANJAY SINGH
45 YEARS/MALE

CHEST X RAY PA VIEW

Both the lung fields appear normal.

Both costophrenic angles appear clear.

Cardiac silhouette appear normal.

Both hila appears normal.

Bony thorax appears normal.

No evidence of free gas seen under dome of diaphragm.

COMMENTS:

- **NORMAL BOTH LUNG FIELDS.**
- **NORMAL CARDIAC SIZE.**



DR SARJAN VASAVA
M.B.B.S., D.M.R.D.
Reg. No. G-26527
SAMANVAY HOSPITALS

Digitally signed by
DR SARJAN VASAVA,
CONSULTANT RADIOLOGIST.



2017-03-22 00:25:56
WL: 128 WW: 256

R

5
L/F

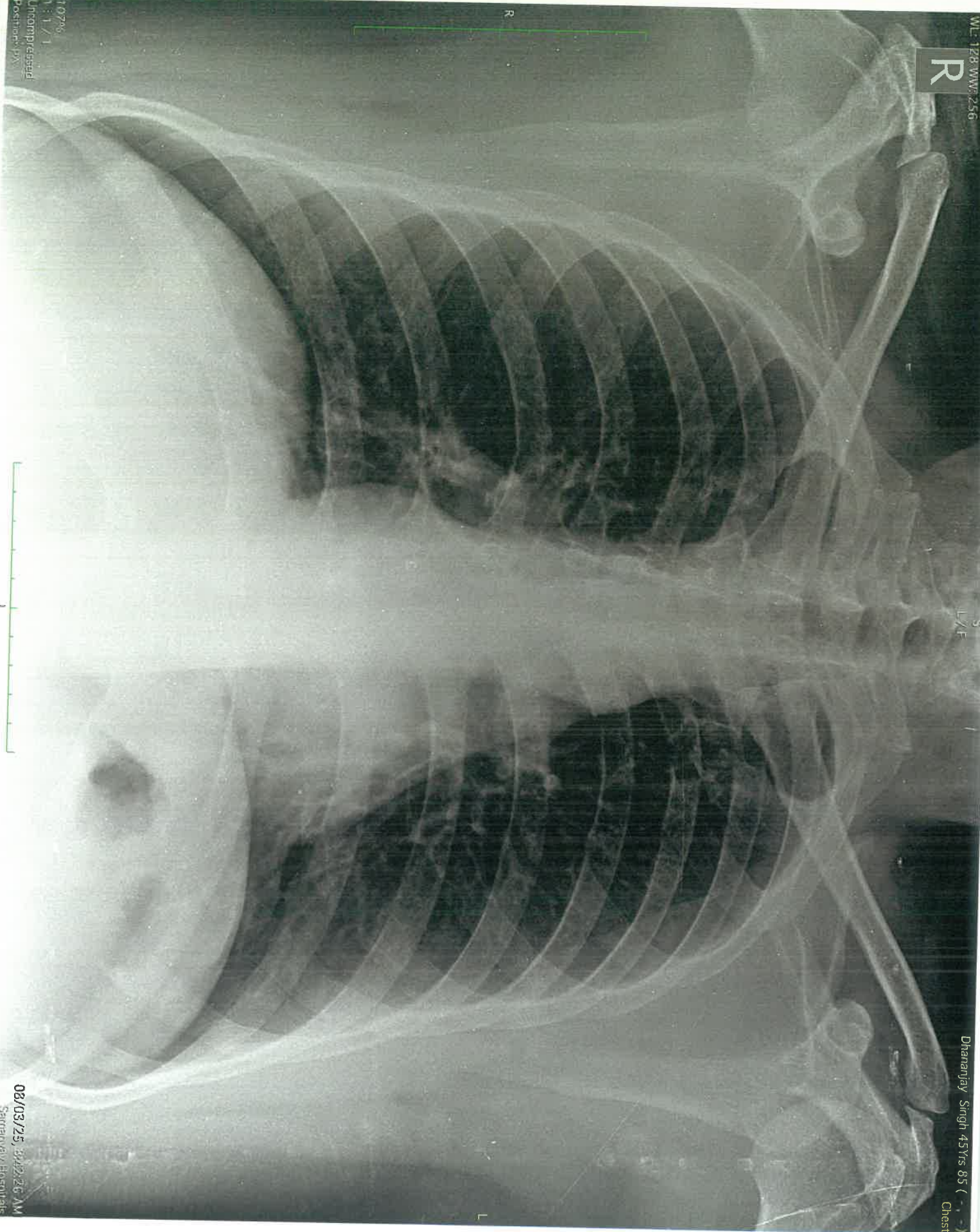
Dhananjay Singh 45Yrs 85 (- - -)
Chest

R

L

107296
1 : 1 / 1
Uncompressed
Position: PA

08/03/25, 04:22:26 AM
Sairam's Hospital
Medina, India



DHANANJAY SINGH

M / 45 YEARS

DATE: 08/03/2025

REAL TIME SONOGRAPHY OF THE ABDOMEN & PELVIS

LIVER - It is normal in size (14.6 cm). It shows bright echo pattern. No evidence of solid or cystic focal lesion is seen. The intrahepatic biliary system is normal and shows no dilatation of the radicles. The portal vein, CBD and hepatic veins appear normal.

GALL BLADDER - It is distended and appears normal. No evidence of sludge or cholecystitis is seen. The wall appears normal. Few calculi are noted in gall bladder, largest of size measures 9.3 mm.

PANCREAS - It is visualized and appears normal.

SPLEEN - It appears normal in size (10.6 cm), normal in shape and echotexture. No focal lesions.

KIDNEYS - . Both the kidneys appear normal in size, shape and show normal corticomedullary differentiation. Normal echogenicity of both kidneys.

Right kidney measures 10.3 x 5.1 cm. Left kidney measures 10.6 x 4.2 cm.

No calculus or hydronephrosis is seen on either side.

Urinary bladder is distended and appears normal. No cystitis or mass lesion noted.

Prostate appears normal in size vol - 17 cc . No focal lesion.

No evidence of any lymphadenopathy or ascites is noted.

No evidence of dilated bowel loops or bowel wall thickening noted.

IMPRESSION:

**✓ CHOLELITHIASIS.NO CHOLEVCYSTITIS.
FATTY LIVER GRADE-I.**



DR. SARJAN VASAVA,
CONSULTANT RADIOLOGIST.
DR SARJAN VASAVA
M.B.B.S., D.M.R.D.
Reg. No. G-26527
SAMANVAY HOSPITALS



Patient

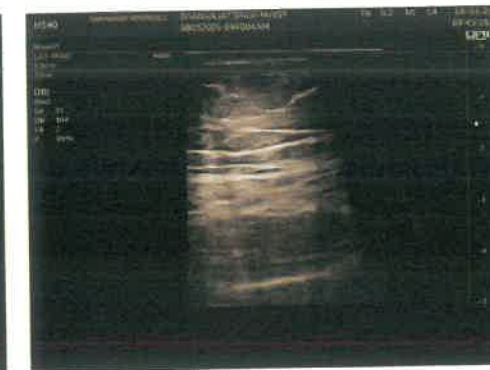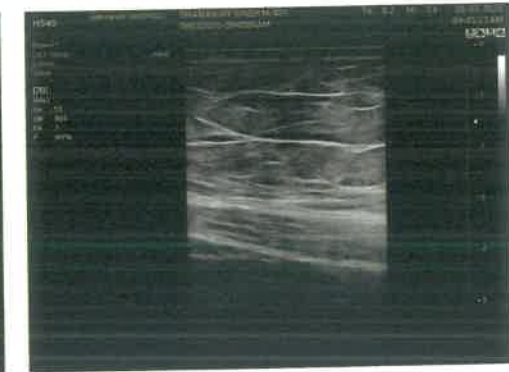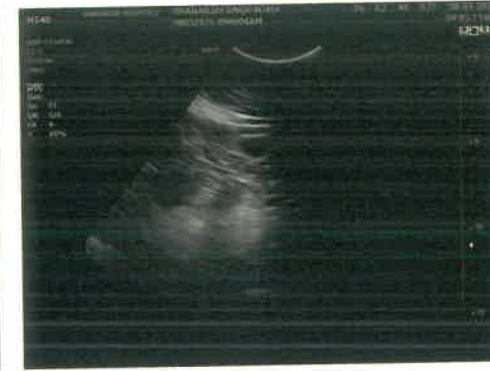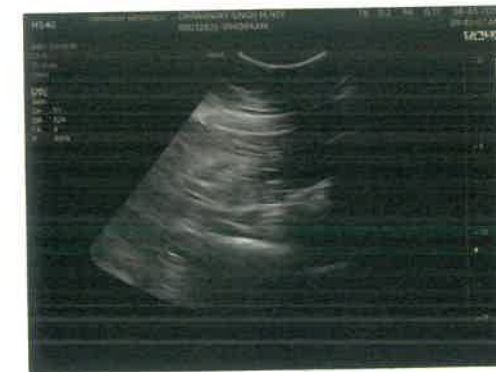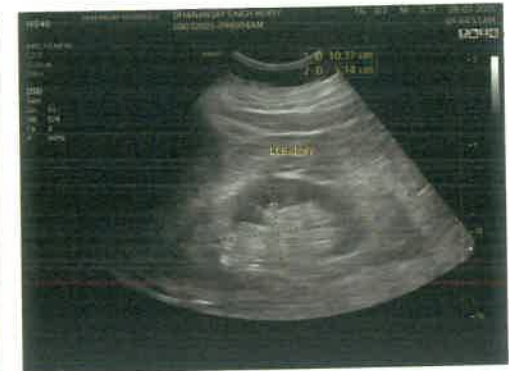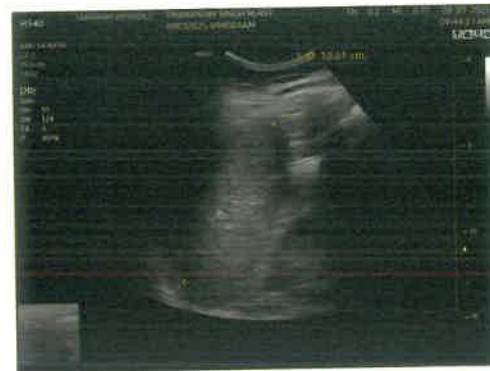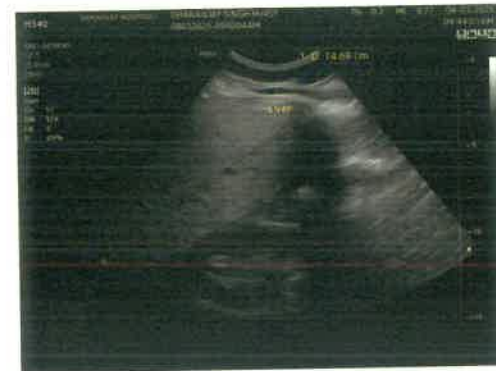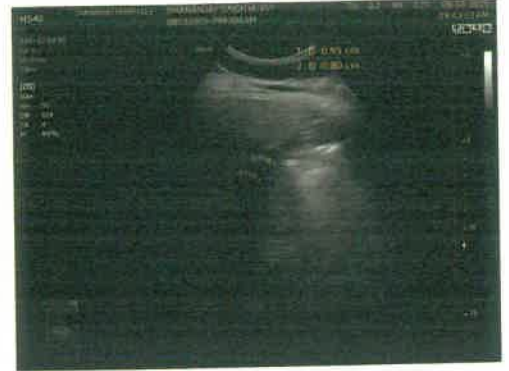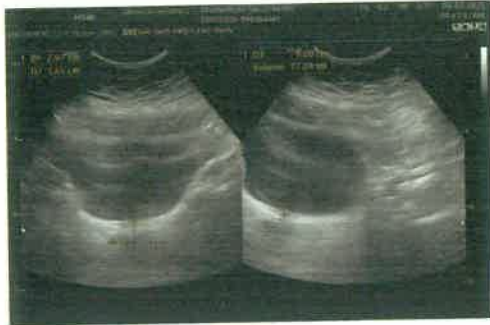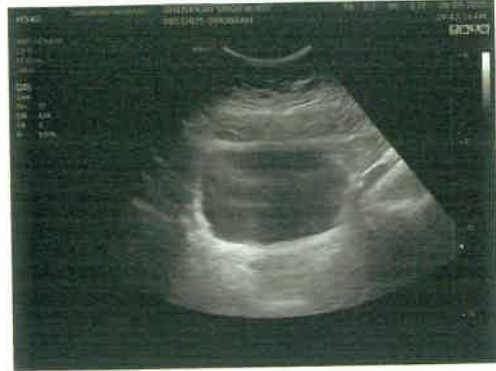ID
Name
Birth Date
Gender

08032025-094004AM
DHANANJAY SINGH M/45Y

Exam

Accession #
Exam Date
Description
Operator

08-03-2025



2D ECHOCARDIOGRAPHY AND COLOUR DOPPLER STUDY

NAME : MR.DHANANJAY SINGH

DATE :08-03-25

AGE/SEX :45 YRS / WARD :HCP REF BY :SAMANVAY HOSPITAL

OBSERVATION:


- NORMAL LV SIZE WITH NORMAL LV SYSTOLIC FUNCTION
- LVEF 56%, NO RWMA AT REST
- E/O NO LV DIASTOLIC DYSFUNCTION, NORMAL LA SIZE
- AORTIC VALVE, NO AR, NO AS
- MITRAL VALVE, MILD MR, NO MS
- TRIVIAL TR, MILD PAH, RVSP 32 MMHG
- NORMAL SIZED RA, RV WITH NORMAL RV FUNCTION
- PULMONARY VALVE- NO PR, NO PS, NORMAL SIZED PA & ITS BRANCHES
- IAS, IVS ARE INTACT
- NO INTRACARDIAC CLOT, VEGETATION
- PERICARDIUM NORMAL, NO PERICARDIAL EFFUSION
- IVC NORMAL

MEASUREMENTS:

M MODE: AORTA: 27 MM LA: 35 MM LV DD/DS: 48/27 MM IVS/PW: 11/11 MM
DOPPLER: MV RATIO E/A: 0.9/0.7 M/S AV VMAX: 1.3 M/S PV VMAX: 0.6 M/S

CONCLUSION:

NORMAL LV SIZE AND LV SYSTOLIC FUNCTION
LVEF 56%, NO RWMA AT REST
MILD MR, TRIVIAL TR, MILD PAH
E/O NO LV DIASTOLIC DYSFUNCTION



DR. PAVAN ROY
MD, DM (CARDIOLOGY)
CONSULTANT CARDIOLOGIST
REG. NO. G-23390
M No. 9305988155

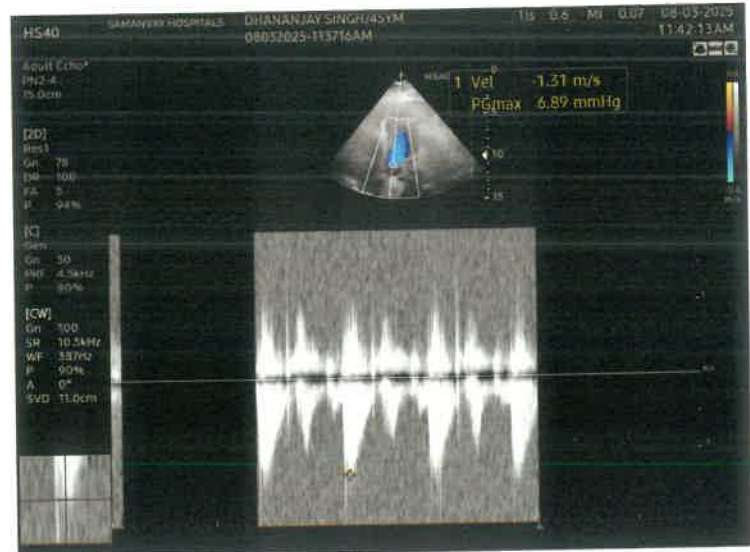
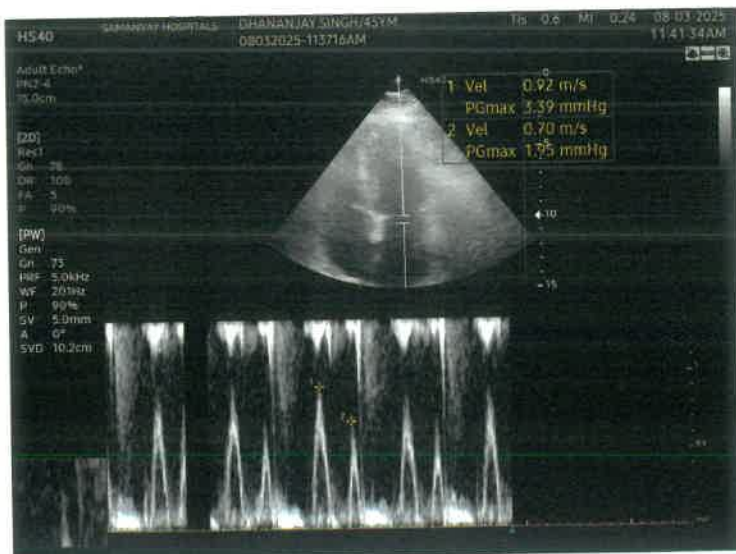
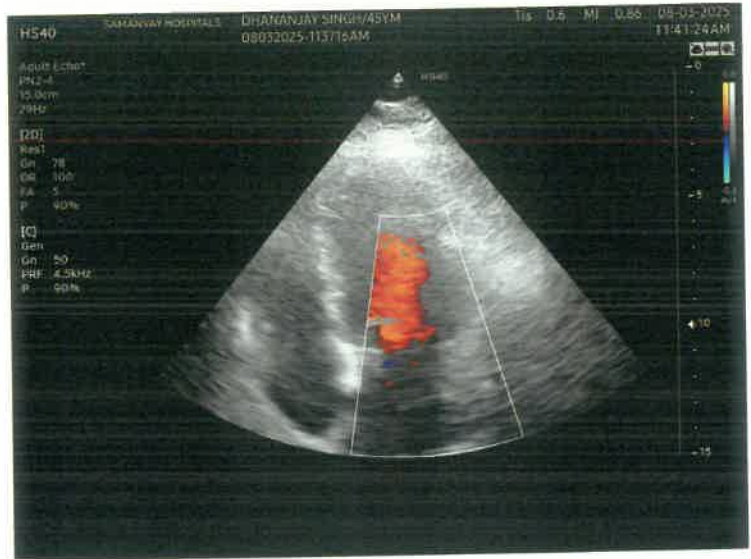
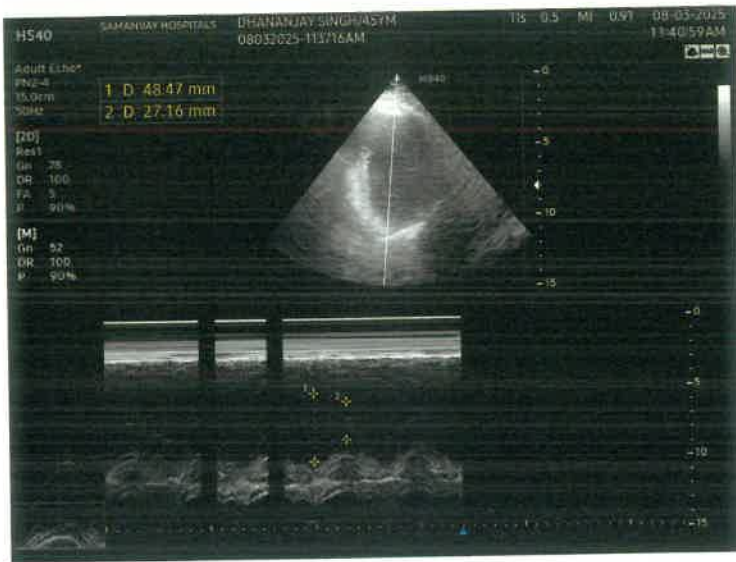
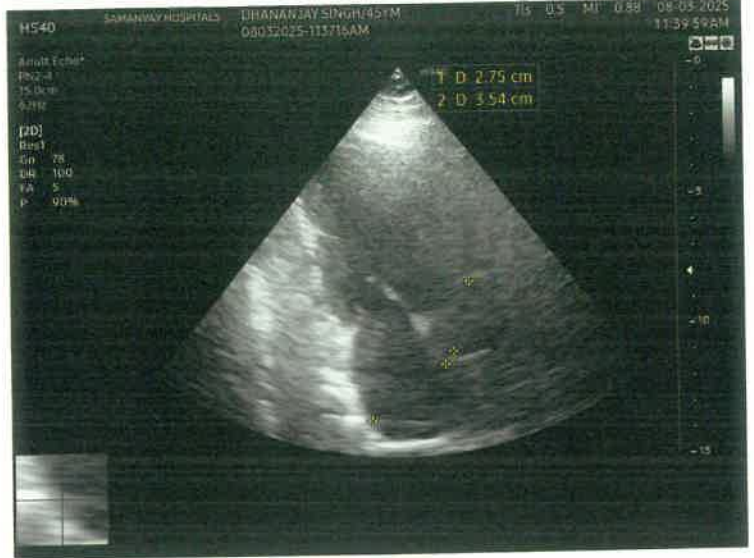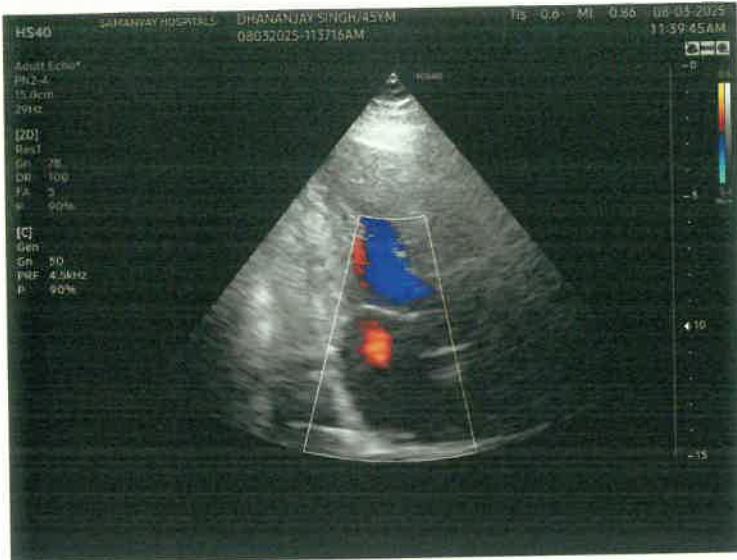
DR. PAVAN ROY
MD, DM (CARDIOLOGY), REG NO. G-23390
CONSULTANT INTERVENTIONAL CARDIOLOGIST

Patient

ID 08032025-113716AM
Name DHANANJAY SINGH/45YM
Birth Date
Gender

Exam

Accession #
Exam Date 08-03-2025
Description
Operator



COMPREHENSIVE HEALTH CHECK UP

Case No. : _____ Date : 8/3/25

Name : Mr. Dhanyaj Singh Age/Sex : 45/M

MEDICAL HISTORY : H/O low backache

PERSONAL HISTORY : _____

Appetite : _____ Smoking : —

Sleep : _____ H/O Alcohol : —

Bladder : _____ Lifestyle : Sedentary

Bowel : _____ Exercise : A walking

DRUG HISTORY : _____

PAST HISTORY : _____

FAMILY HISTORY : _____

GENERAL PHYSICAL EXAMINATION :

Built and Nourishment :

Height : 176 cm

57002 :- 98.4

B. P. 90/60 mm of Hg

Weight : 98.4 Kg

Character : _____ Pulse : 79 / Min

Nails : _____ Odema : _____

Tonsils : _____ Skin : _____

Tongue : _____ Sclera : _____

Eat. & Joints : _____ Glands : _____



Adv

(30) d.

Tb. Febug et 1000 (400)



EYE CHECK UP

Reg. No. : # Date : 8-3-25

Name : Dhunjey Singh Age / Sex : 45 / M

| | RIGHT EYE | LEFT EYE |
|--|-----------------------|----------|
| DISTANCE : (With / Without Glasses) | 0 16 | 0 16 |
| NEAR VISION : (With / Without Glasses) | N6 | N6 |
| ANTERIOR SEGMENT : | — uvr — | |
| I O P (MM of Hg) | — digitally uvr — | |
| FUNDUS : | — uvr — | |
| COLOR VISION : | — uvr — | |
| CLINICAL IMPRESSION : | — uvr — | |
| ADVICE : | (BE) Near add : +2.00 | |

Doctor's Signature :



Name: Dhanyaj Singh
Age Sex: 43/M

Date: 8/3/25

dx: RCTreated. $\frac{1}{21}$

- Buccal pit $\frac{1}{6}$
- Stain + Calculus².
- Gen. Attrition.

Adv: Scaling.

- Rest^m $\frac{1}{6}$
- Night Guard.