

❖ This medical fitness is only on the basis of clinical examination. No COVID -19 and other investigation has been done to reveal the fitness

MEDICAL EXAMINATION REPORT

Name Raman Sharma Age & Sex 54y/M Date of MER 09/11/24  
 Identification Mark Male near Rt. eye ID Proof VIN CARD  
 Ht 179 Wt 105 Chest Exp/Insp 120/125 Abd 116 PR 79/m BP 140/90

Any Operation

No

Any Medicine Taken

K/C/O HTN since 1 year on Rx Tab. Amlong 25mg

Any Accident

No

Alcohol/Tabacco/Drugs No

Consumption.....Duration.....

Qty.....

Whether the person is suffering from any of the following diseases, give details

DISEASE	Yes/NO	DETAIL
Diabetes	No	
Hypertension	YES	HTN since 1 year Rx Tab. Amlong 25mg
Renal Complications	No	
Heart Disease	No	
Cancer	No	
Any Other	No	

Examination of systems

SYSTEMS( any evidence of past/present disease)	YES	NO	DETAILS
Brain or nervous system		<input checked="" type="checkbox"/>	
Lungs or other parts of respiratory system		<input checked="" type="checkbox"/>	
GI Tract		<input checked="" type="checkbox"/>	
Ears, Eyes, Nose, Throat, Neck		<input checked="" type="checkbox"/>	
Cardiovascular System		<input checked="" type="checkbox"/>	

Signature of client.....

Signature of Doctor.....

Seal of Centre.....

**Dr. R.S. Maheshwari**  
 M.B.B.S. M.D. (Paed) P.C.M.S. (Ex.) M.I.A.P.  
 Consultant Physician & Child Specialist  
**LIFE LINE HOSPITAL**  
 GILL ROAD, LUDHIANA-141003  
 Registration No. 34970



सत्यमेव जयते  
ਆਰ ਥਾਕਾਰ



आधार

ਭਾਰਤੀ ਵਿਲੱਖਣ ਪਛਾਣ ਅਥਾਰਟੀ

**ਭਾਰਤ ਸਰਕਾਰ**  
Unique Identification Authority of India  
Government of India

ਦਾਖਿਲੇ ਦੀ ਪਛਾਣ / Enrollment No. : 1055/90677/02924

21/08/2013

To  
Raman Sharma  
ਰਮਨ ਸ਼ਰਮਾ  
S/O: Rajinder Kumar Sharma  
644-E  
B R S NAGAR  
Rajguru Nagar  
Rajguru Nagar, Ludhiana  
Punjab - 141012  
7355095673



KL358682102FT

35868210



ਤੁਹਾਡਾ ਆਧਾਰ ਨੰਬਰ / Your Aadhaar No. :

**9603 5512 8351**

ਆਧਾਰ - ਆਮ ਆਦਮੀ ਦਾ ਅਧਿਕਾਰ



ਭਾਰਤ ਸਰਕਾਰ

Government of India

ਰਮਨ ਸ਼ਰਮਾ

Raman Sharma

**Dr. R.S. Maheshwari**  
M.B.B.S. M.D. (Paed) D.C.M.S. (Ex.) M.I.A.P.  
Consultant Physician & Child Specialist  
LIFE LINE HOSPITAL  
GILL ROAD, LUDHIANA-141003  
Registration No. 34970



9603 5512 8351



ਆਧਾਰ - ਆਮ ਆਦਮੀ ਦਾ ਅਧਿਕਾਰ

*Rev*



# Lifeline Hospital

Multi Speciality & Super Speciality Hospital

NABH Accredited  
(HNB LEVEL)



NAME Raman sharma

EMP.CODE \_\_\_\_\_

AGE / SEX 51y/m

DATE 09/11/2024

REF. BY BOB

	RIGHT EYE				LEFT EYE				
	SPH	CYL	AXIS	VIA	SPH	CYL	AXIS	VIA	
DISTANCE	-0.25	—		6/6	-0.50	—		6/6	
FOR NEAR ADD			←						

COLOR VISION (ISHIHARA'S CHART)

COLOR VISION : Normal

OTHER OPINION: \_\_\_\_\_

EYE CARE DEPARTMENT  
LIFELINE HOSPITAL  
GILL ROAD, LUDHIANA-141003.

DOCTOR SIGNATURE

NAME: RAMAN SHARMA

AGE/SEX: 51Y/M

HEIGHT: 179 cms

WEIGHT: 105kgs

B.P: 140/90mmHg

PULSE: 60 BPM

- CVS - N.A.D.
- CNS - N.A.D.
- P/A - N.A.D.
- R/S - N.A.D.
- ENT - N.A.D.
- Skin Examination - N.A.D.
- Hearing Examination - N.A.D.
- Dental Examination - Good Oral Hygiene.

*Dr. R.S. Maheshwari*  
DR. R.S. Maheshwari  
M.B.B.S., M.D. (Paed) P.C.M.S. (Ex.) M.I.A.P.  
Consultant Physician & Child Specialist  
LIFE LINE HOSPITAL  
GILL ROAD, LUDHIANA-141003  
Registration No. 34970

QRS : 86 ms  
QT / QTcBaz : 366 / 411 ms  
PR : 172 ms  
P : 88 ms  
RR / PP : 792 / 789 ms  
P / QRS / T : 65 / -1 / 43 degrees

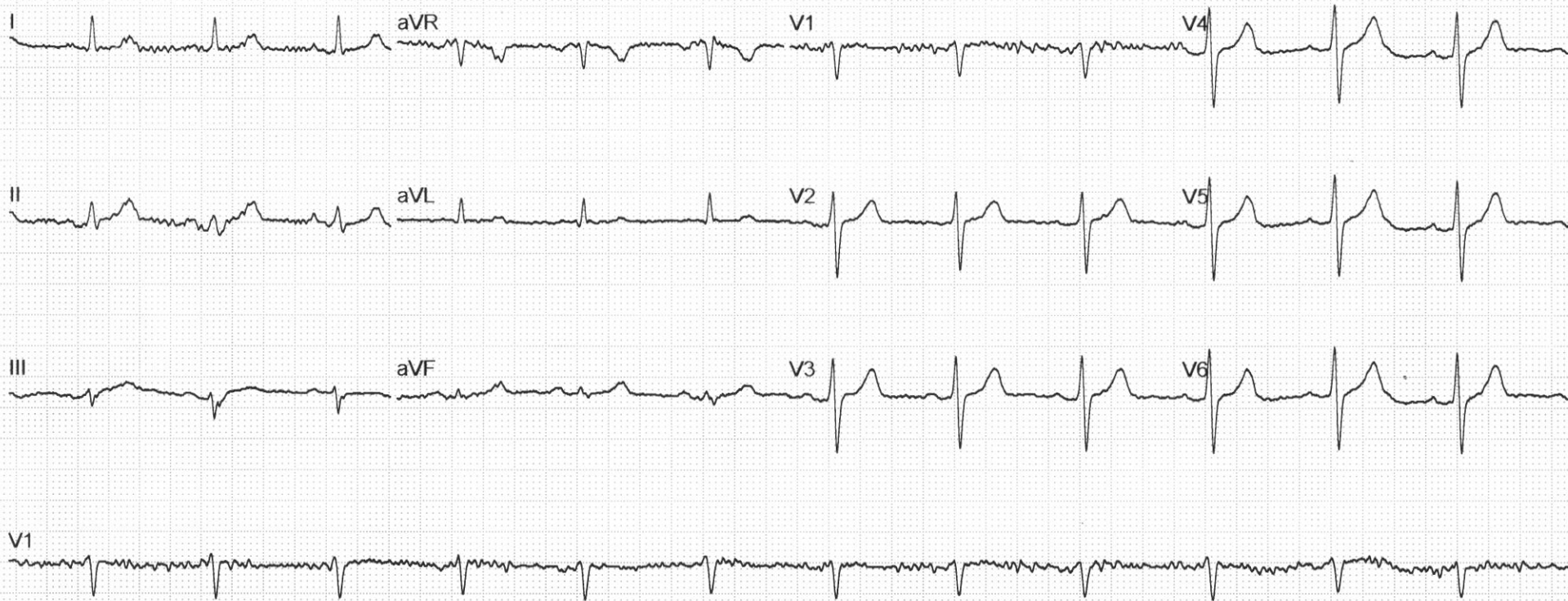
Normal sinus rhythm  
Normal ECG

*Handwritten signature*

Technician:  
Ordering Ph:  
Referring Ph:  
Attending Ph:

**Dr. R.S. Aneshwari**  
**M.B.B.S. MD**  
**Medical Director**  
**Reg. 34970**

*Handwritten signature*



# Lifeline Hospital

Multi Speciality & Super Speciality Hospital

NABH Accredited  
ENTRY LEVEL



To,  
Lifeline Hospital  
gill road,  
ldh

I referred to my stool sample.

**Dr. R.S. Maheshwari**  
M.B.B.S. MD (Paed) P.C.M.S. (Ex.) M.I.A.P.  
Consultant Physician & Child Specialist  
**LIFE LINE HOSPITAL**  
GILL ROAD, LUDHIANA-141003  
Registration-No. 34970

**Dr. Sanjeev Kumar Mittal**

MD, DNB, DM (Cardiology)  
 Fellowship American College of Cardiology (FACC)  
 Fellowship European Society of Cardiology (FESC)  
 Fellowship of Society of Cardiovascular  
 Angiography & Interventions, USA (FSCAI)  
**Senior Interventional Cardiologist**

**Dr. Reena Mittal**

Anaesthesiologist  
**Pain Management Specialist**



# Dr SANJEEV

## HEART CENTRE

*Let's go for healthy heart*

47-A (B-XX-894/2) Maya Nagar, Civil Lines, Ludhiana, Punjab (INDIA), Ph: 0161-2443344, E-mail: dr\_smittal@yahoo.com,

NAME	RAMAN SHARMA	AGE/SEX	51/MALE
REF .BY	LIFE LINE HOSPITAL	DATE	09/11/2024
DIAGNOSIS	CARDIAC EVALUATION		

### ECHOCARDIOGRAPHY REPORT

#### MEASUREMENTS:

#### NORMAL VALUES

Left Atrial dimension:	3.3	(1.9-4.0cm)
Aortic root dimension:	3.2	(2.0-3.7cm)
Aortic valve opening	1.9	
Left Ventricular end diastolic dimension	3.9	(3.8-5.6cm)
Left Ventricular end systolic dimension:	2.0	(2.0-4.0cm)
Interventricular septum thickness (end diastolic):	1.1	(0.6-1.2cm)
(end systolic):	1.7	
Left Ventricular posterior wall thickness (end diastolic)	1.0	(0.5-1.0cm)
(end systolic):	1.7	
Right ventricular dimension:	2.1	(0.7-2.6cm)
Right ventricular thickness:	Normal	(0.3-0.5cm)

#### INDICES OF LEFT VENTRICULAR FUNCTION

LV Ejection Fraction:	60	(55-70%)
-----------------------	----	----------

For all Investigations & in all emergencies,  
 Please Contact: 97797-12871

- Coronary Angiography
- ECG
- Stress ECHO
- PTCA / Stenting
- ECHO
- Advanced ECHO
- Renal and Peripheral Angiography
- TMT
- Strain rate Imaging
- Pacemaker Implantation
- Holter
- Carotid Doppler
- Natural Bypass Therapy (ECP Therapy)

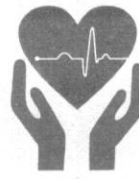

## Dr. Sanjeev Kumar Mittal

MD, DNB, DM (Cardiology)  
Fellowship American College of Cardiology (FACC)  
Fellowship European Society of Cardiology (FESC)  
Fellowship of Society of Cardiovascular  
Angiography & Interventions, USA (FSCAI)  
Senior Interventional Cardiologist

## Dr. Reena Mittal

Anaesthesiologist  
Pain Management Specialist



# Dr SANJEEV

## HEART CENTRE

*Let's go for healthy heart*

47-A (B-XX-894/2) Maya Nagar, Civil Lines, Ludhiana, Punjab (INDIA), Ph: 0161-2443344, E-mail: dr\_smittal@yahoo.com.


### IMAGING:

2-D imaging in PLAX, SAX and Apical views revealed normal LV size and normal LV contractility. RA/RV are normal in size. Mitral valve opening is normal. No evidence of Mitral valve prolapse is seen. Aortic valve has three cusps and its opening is not restricted. Pulmonary and tricuspid valves are structurally normal. Interatrial and interventricular septums are intact. No intracardiac mass or thrombus is seen. No pericardial pathology is observed. LV ejection fraction is approximately 60%.

### DOPPLER: PULSE WAVE, CONTINUOUS WAVE & COLOR FLOW MAPPING

MITRAL VALVE	:	E=0.53 m/sec	A= 0.63 m/s	A>E	Trace MR
AORTIC VALVE	:	1.13 m/sec			No AR
TRICUSPID VALVE	:	E= 0.59 m/sec	A=0.52 m/s		No TR
PULMONARY VALVE	:	0.95 m/sec			No PR
TISSUE DOPPLER IMAGING:		E' = 0.10 m/s		E/E' = 5.38	

**IMPRESSION:** Normal Cardiac Chamber dimensions  
Normal LV systolic function (LVEF 60%)  
Type 1 diastolic dysfunction.  
Trace MR. No TR. No PR. No AS/AR.  
No clot/ veg./Pericardial effusion.

  
Dr. Sanjeev Kumar Mittal  
DM Cardiology, FACC, FSCAI, FESC  
Cardiologist Mittal Clinic, Ludhiana  
Reg. No. 30318

For all Investigations & in all emergencies,  
Please Contact: 97797-12871

- Coronary Angiography
- PTCA / Stenting
- Renal and Peripheral Angiography
- Pacemaker Implantation
- Natural Bypass Therapy (ECP Therapy)
- ECG
- ECHO
- TMT
- Holter
- Stress ECHO
- Advanced ECHO
- Strain rate Imaging
- Carotid Doppler

# SANJEEV HEART CENTRE

Name raman sharma

Date 09/11/2024

Image 1

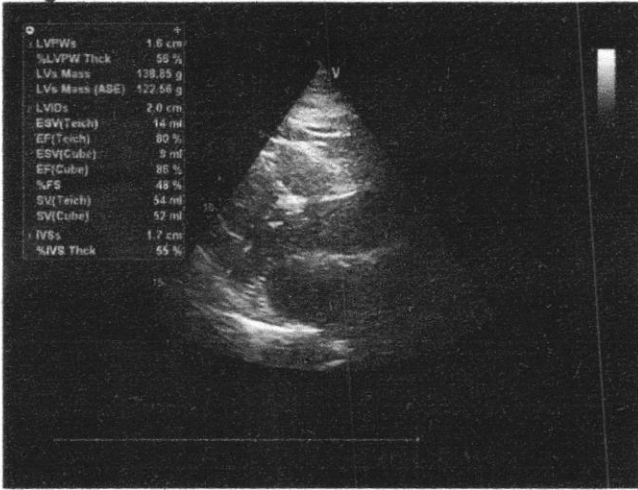


Image 2

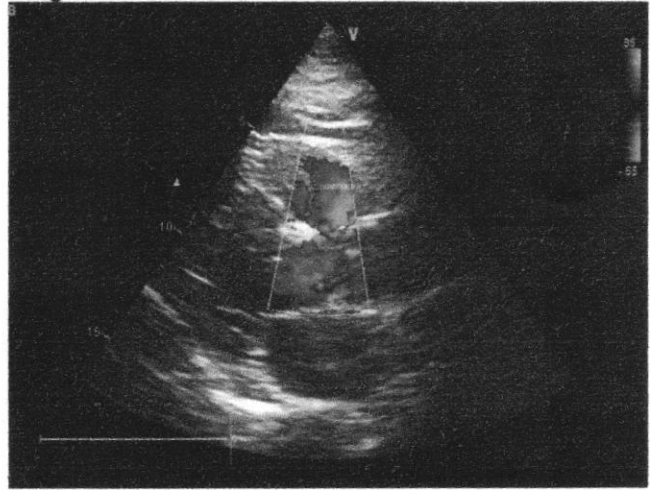


Image 3

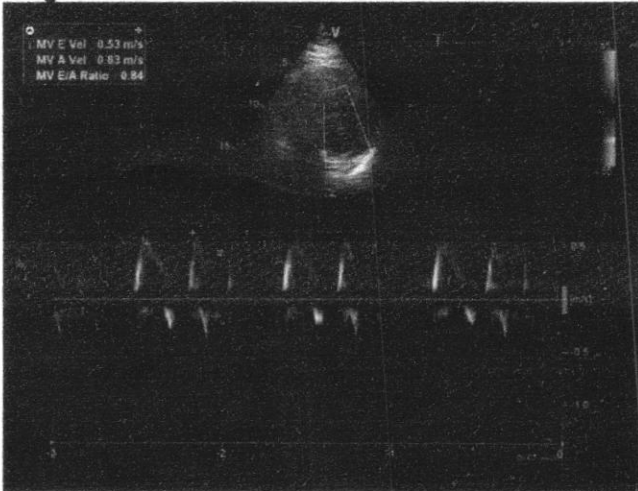


Image 4

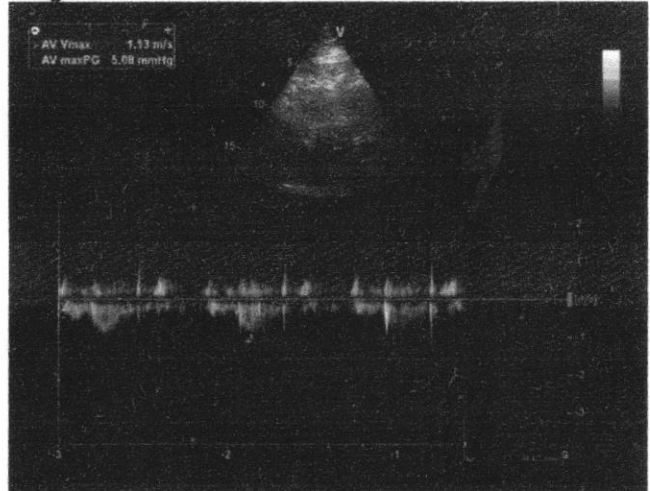


Image 5

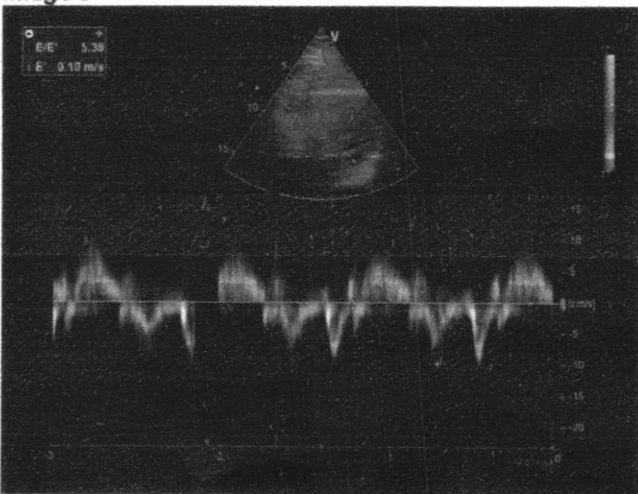
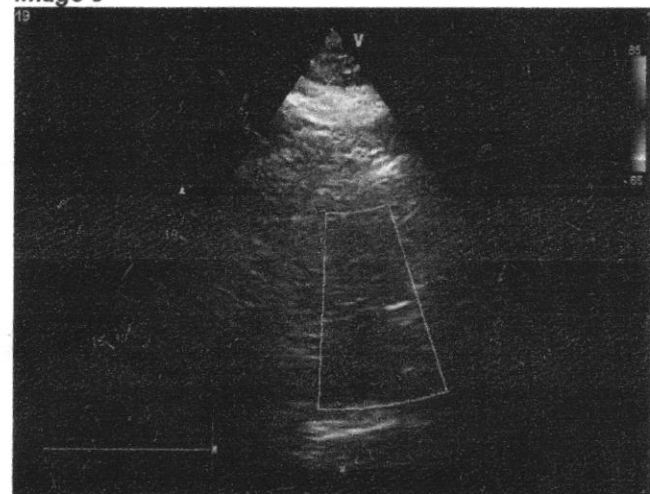


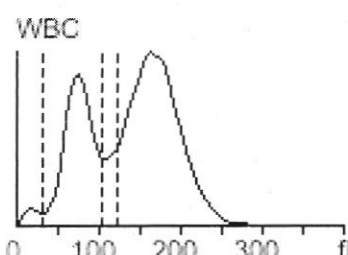
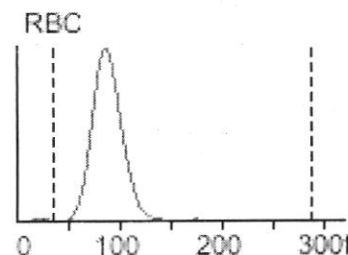
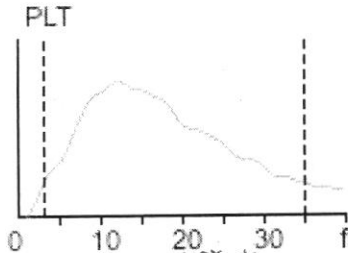
Image 6



Lab ID. :	10	Date :	09/11/2024
Name :	RAMAN SHARMA	Age/Sex :	51 Years/Male
Ref. By :	BANK OF BARODA	Mac. No. :	4692

## Complete Blood Count

Test Performed on ERBA H360 Fully Automated Analyser

Parameters	Result	Units	Reference Range	Graphs
<b>LEUKOCYTES</b>				
Total WBC Count	10.02	10 <sup>3</sup> /uL	4.0 - 11.0	 <p>WBC</p>
Lymphocytes%	30.4	%	20.0 - 50.0	
Mixed%	5.5	%	3.0 - 10.0	
Neutrophils%	64.1	%	50.0 - 70.0	
Lymphocytes#	3.05	10 <sup>3</sup> /uL	0.6 - 4.1	
Mixed#	0.55	10 <sup>3</sup> /uL	0.1 - 1.8	
Neutrophils#	6.42	10 <sup>3</sup> /uL	2.0 - 7.8	
<b>ERYTHROCYTES</b>				
Hemoglobin	14.0	g/dl	12.0 - 17.0	 <p>RBC</p>
R.B.C Count	4.81	10 <sup>6</sup> /uL	3.50 - 5.50	
Haematocrit(PCV)	42.9	%	36.0 - 47.0	
MCV	89.2	fl	80.0 - 99.0	
MCH	29.2	pg	27.0 - 32.0	
MCHC	32.7	g/dl	32.0 - 36.0	
RDW-SD	49.6	fl	35.0 - 56.0	
RDW-CV	14.4	%	11.5 - 14.5	
<b>THROMBOCYTES</b>				
Platelets Count	168	10 <sup>3</sup> /uL	150 - 450	 <p>PLT</p>
MPV	10.2	fl	7.4 - 10.4	
PDW	16.4	fl	10.0 - 17.0	
PDW-CV	16.2	%	10.0 - 17.0	
PCT	0.211	%	0.108 - 0.280	
P-LCR	40.5	%	13.0 - 43.0	
P-LCC	79.0	10 <sup>3</sup> /uL	30 - 90	
ESR	10	mm 1st hr	0 - 20	
Blood Group	"B" POSITIVE			

Dr. SURBHI GOYAL  
M.B.B.S. M.D. (PATHOLOGY)  
CONSULTANT PATHOLOGIST  
No 40135

*R. Kumar*  
9/11/24


NAME : RAMAN SHARMA  
AGE/SEX : 51Y/M  
REF BY : BANK OF BARODA  
DATE : 09.11.2024


## BLOOD EXAMINATION REPORT

DETERMINATION	NORMAL	RESULT
FBS	70-110mg/dl	89mg/dl
PPBS	70-140mg/dl	141mg/dl
BILLIRUBIN TOTAL	<1.2mg/dl.	0.74mg/dl
BILLIRUBIN DIRECT	<0.3mg/dl	0.18mg/dl
BILIRUBIN INDIRECT	<0.9mg/dl	0.56mg/dl
S.G.O.T.	5-50Units/L	35Units/L
S.G.P.T.	5-50 Units/L	40Units/L
GAMMA GT	9-52 Units/L	25Units/L
SGOT/SGPT RATIO		0.87 RATIO
TOTAL PROTEIN	6.0-8.0mg/dl	7.3mg/dl
ALBUMIN	3.5-5.3mg/dl	4.2mg/dl
S.GLOBULIN	2.0-4.0gm/dl	3.1gm/dl
A/G RATIO	1.25:1-1.75:1 mg/dl	1.35:1gm/dl
ALK. PHOSPHATASE	108-305 Units/L	189Units/L
UREA(BUN)	15-45mg/dl	23mg/dl
CREATININE	0.7-1.5mg/dl	0.78mg/dl
URIC ACID	3.0-7.2mg/dl	6.10mg/dl
BUN/SR.CREATININE RATIO	9:1-23:1 RATIO	29.4:0 RATIO
CHOLESTEROL	140-200mg/dl	253mg/dl
TRIGLYCRIDE	60-160mg/dl	154mg/dl
CHOLESTEROL HDL	35-60 mg/dl	49mg/dl
CHOLESTEROL LDL	60-150 mg/dl	174mg/dl
VLDL	20-40 mg/dl	30mg/dl
LDL/HDL Ratio	1.71-2.5mg/dl	3.5mg/dl
CHOLESTEROL/HDL Ratio	4.0:1-4.16:1 mg/dl	5.1:1mg/dl

### Recommendation:

1. This report is not valid for medico legal purposes.

  
REPORT CHECKED BY  
KULWINDER KAUR  
MSC (MLT)  
REG.NO-388-FIIPxpar(mg)2018

  
DR.SURBHI GOYAL  
M.B.B.S MD (Pathology)  
CONSULTANT PATHOLOGIST

**NAME : RAMAN SHARMA**  
**AGE/SEX : 51Y/M**  
**REF BY : BANK OF BARODA**  
**DATE : 09.11.2024**

## HbA1C

Test name	results	units
HbA1c{GLYCOSYLATED HEMOGLOBIN}BLOOD	5.50	%

### Interpretation

As per American Diabetes association {ADA}	
Reference Group	HbA1c in %
Non diabetic adults >=18 years	4.0 - 6.0
At risk	> = 6.0 to <= 6.5
Diagnosing diabetes	>6.5
Therapeutic goals for glycemic Control	Adults Goal of therapy : < 7.0 Action suggested : >8.0

**Note** : 1. Since HbA1c reflects long term fluctuations in the blood glucose concentration, a diabetic patient who is recently under good control may still have a high concentration of HbA1c. Converse is true for a diabetic previously under good control but now poorly controlled.

2. target goals of < 7.0 % may be beneficial in patients with short duration of diabetes , long life expectancy and no significant cardiovascular disease .In patient with significant complications of diabetes , limited life expectancy or extensive co-morbid conditions, targeting a goal of < 7.0 % may not be appropriate.

#### Comments

HbA1c provides an index of average blood glucose level over the past 8-12 weeks & is a much better indicator of long term glycemic as compared to blood & urinary glucose determinations.

#### ADA criteria for correlation between HbA1c & Mean plasma glucose levels

HbA1c %	Mean plasma glucose {mg/dl }	HbA1c %	Mean plasma glucose {mg/dl }
5	98	9	212
6	126	10	240
7	154	11	269
8	183	12	298

### Recommendation:-

1. This report is not valid for medico legal purposes.
2. The test can be repeated free of cost in case of any discrepancy.
3. Test to be clinically correlated.
4. All card tests require confirmation by serology
5. False negative or false positive results may occur in some cases

*Kaur*  
09/11/24

REPORT CHECKED BY  
KULWINDER KAUR  
MSC (MLT)  
REG.NO-388-FIIPxpar(mg)2018

*Surbhi*  
DR.SURBHI GOYAL  
M.B.B.S MD (Pathology)  
CONSULTANT PATHOLOGIST

Dr. SURBHI GOYAL  
M.B.B.S. M.D. (PATHOLOGY)  
CONSULTANT PATHOLOGIST  
No 40195

NAME : RAMAN SHARMA  
AGE/SEX : 51Y/M  
REF BY : BANK OF BARODA  
DATE : 09.11.2024

## BLOOD EXAMINATION REPORT

DETERMINATION	NORMAL	RESULT
CALCIUM	8.5-10.4mg/dl	9.2mg/dl

### Recommendation:-

1. This report is not valid for medico legal purposes.
2. The test can be repeated free of cost in case of any discrepancy.
3. Test to be clinically correlated.
4. All card tests require confirmation by serology
5. False negative or false positive results may occur in some cases

*K Kaur*  
9/11/24

REPORT CHECKED BY  
KULWINDER KAUR  
MSC (MLT)  
REG.NO-388-FIIPxpar(mg)2018

DR.SURBHI GOYAL  
M.B.B.S MD (Pathology)  
CONSULTANT PATHOLOGIST  
*Surbhi Goyal*  
Dr. SURBHI GOYAL  
M.B.B.S. M.D. (PATHOLOGIST)  
CONSULTANT PATHOLOGIST  
6

NAME : RAMAN SHARMA  
AGE/SEX : 51Y/M  
REF BY : BANK OF BARODA  
DATE : 09.11.2024

## TEST ASKED : -T3,T4,TSH

<u>TEST NAME</u>	<u>RESULT</u>	<u>NORMAL RANGE</u>
T3	1.00 ng/ml	0.70-2.04 ng/ml
T4	7.12µg/dl	4.6-10.5 µg/dl
TSH	1.226µIU/ml	0.40-4.20µIU/ml

### Recommendation:-

1. This report is not valid for medico legal purposes.
2. The test can be repeated free of cost in case of any discrepancy.
3. Test to be clinically correlated.
4. All card tests require confirmation by serology
5. False negative or false positive results may occur in some cases

*(K) Kaur*  
*9/11/24*

REPORT CHECKED BY  
KULWINDER KAUR  
MSC (MLT)  
REG.NO-388-FIIPxpar(mg)2018

*Dr. SURBHI GOYAL*  
*M.B.B.S. M.D. (PATHOLOGY)*  
*CONSULTANT PATHOLOGIST*

DR.SURBHI GOYAL  
M.B.B.S MD (Pathology)  
CONSULTANT PATHOLOGIST

NAME : RAMAN SHARMA  
AGE/SEX : 51Y/M  
REF BY : BANK OF BARODA  
DATE : 09.11.2024

<u>TEST NAME</u>	VALUE	UNITS
PROSTATE SPECIFIC ANTIGEN (PSA)	0.49	ng/ml

Technology : C.L.I.A

REFERENCE RANGE:  
NORMAL: 0 to 4 ng/ml  
Border Line: 4.01 to 10.00 ng/ml

Recommendation:-

1. This report is not valid for medico legal purposes.
2. The test can be repeated free of cost in case of any discrepancy.
3. Test to be clinically correlated.
4. All card tests require confirmation by serology
5. False negative or false positive results may occur in some cases.

*(K) Kaur*  
*9/11/24*

REPORT CHECKED BY  
KULWINDER KAUR  
MSC (MLT)  
REG.NO-388-FIIPxpar(mg)2018

DR.SURBHI KUMAR  
M.B.B.S (Pathology)  
CONSULTANT PATHOLOGIST  
CONSULTANT PATHOLOGIST  
No. 40




NAME : RAMAN SHARMA  
AGE/SEX : 51Y/M  
REF BY : BANK OF BARODA  
DATE : 09.11.2024


## URINE EXAMINATION REPORT

A. PHYSICAL EXAMINATION	
QUANTITY	30ml
COLOUR	P. YELLOW
DEPOSIT	ABSENT
REACTION	ACIDIC
SECIFIC GRAVITY	1.020
B. CHEMICAL EXAMINATION	
UROBILINOGEN	NIL
BLOOD	NIL
PROTEIN	NIL
SUGAR	NIL
KETONE BODIES	NIL
BILIRUBIN	NIL
NITRITE	NIL
LEUKOCYTES	NIL
C. MICROSCOPIC EXAMINATION	
EPITHELIAL CELLS	0-1/hpf
PUS CELLS	1-2/hpf
R.B.C.	NIL
CRYSTALS	NIL
CAST	NIL

### Recommendation:-

1. This report is not valid for medico legal purposes.
2. The test can be repeated free of cost in case of any discrepancy.
3. Test to be clinically correlated.
4. All card tests require confirmation by serology
5. False negative or false positive results may occur in some cases

  
REPORT CHECKED BY  
KULWINDER KAUR  
MSC (MLT)  
REG.NO-388-FIIPxpar(mg)2018

  
DR.SURBHI GOYAL  
M.B.B.S MD (Pathology)  
CONSULTANT PATHOLOGIST

DR. SURBHI GOYAL  
M.B.B.S MD (PATHOLOGY)  
CONSULTANT PATHOLOGIST  
Reg No 4011


NAME : RAMAN SHARMA  
AGE/SEX : 51Y/M  
REF BY : BANK OF BARODA  
DATE : 09.11.2024

## URINE EXAMINATION REPORT

DETERMINATION	NORMAL	RESULT
POST URINE SUGAR	NIL	NIL

### \*Recommendation:-

1. This report is not valid for medico legal purposes.
2. The test can be repeated free of cost in case of any discrepancy
3. Test to be clinically correlated.
4. All card tests require confirmation by serology
5. False negative or false positive results may occur in some cases

  
REPORT CHECKED BY  
KULWINDER KAUR  
MSC (MLT)  
REG.NO-388-FIIPxpar(mg)2018

  
DR.SURBHI GOYAL  
M.B.B.S MD (Pathology)  
CONSULTANT PATHOLOGIST

Name : RAMAN SHARMA  
Age/Sex : 51YRS/M  
Date : 9/11/2024

## X-ray Chest PA View

The cardiac size and shape is **enlarged**.

Both hilla are normal.

The lungs on either side show equal translucency

The peripheral vasculature is normal

The domes of the diaphragm is normal

The pleural spaces are normal.

## Cardiomegaly

*Dr. R.S. Maheshwari*

M.B.B.S. M.D. (Paed) P.C.M.S. (Ex.) M.I.A.P.  
Somatic Physician & Child Specialist

DR. R. S. MAHESHWARI

M.B.B.S. M.D. LUDHIANA-141003

Reg No. 34970

Patient's Name : RAMAN SHARMA

DATE : 09/11/2024

Age/Sex : 51 Yrs/M

## ULTRASONOGRAPHY OF ABDOMEN

**LIVER :** Liver is normal in size & shape and shows fatty infiltration. Hepatic bleary radicals are normally outlined. Portal vein is normal in caliber. No evidence of liver abscess. Movements of diaphragm are not restricted. No evidence of secondaries. CBD is of normal calibre.

**GALL BLADDER :** Gall Bladder is distended. Walls are normal. Lumen shows normal echo.

**PANCREAS :** Pancreas is normal in size, shape and echotexture. No evidence of any collection in lesser sac.

**SPLEEN :** Spleen is normal in size, shape and echotexture. Calibre splenic vein at hilum is WNL.

**RIGHT KIDNEY :** Right kidney is normal in size & shape. Cortical thickness is WNL. Pelvi-calyceal system is normal. There is no evidence of a calculus. No backpressure changes or S.O.L. Corticomedullary differentiation is well maintained.

**LEFT KIDNEY :** Left kidney is normal in size & shape. Cortical thickness is WNL. Pelvi-calyceal system is normal. There is no evidence of a calculus. No backpressure changes or S.O.L. Corticomedullary differentiation is well maintained.

**URETERS:** Both ureter are normal and not dilated

**URINARY BLADDER :** UB is seen filled stage. lumen is echo free walls are normal.

**PROSTATE :** Prostate medium lobe is enlarged in size. No focal lesion seen.

**IMPRESSION:-** GRADE - I FATTY LIVER // MILD PROSTATOMEGALY.

Adv... PSA.

*Dr. R. S. Maheshwari*  
M.B.B.S., M.D (Paed)

DR.R.S. MAHESHWARI

MBBS, MD [PAED]

Registration No. : - 34970

Reg. No. DAA/LDH/21/346

SONOLOGIST

LIFE LINE HOSPITAL

GILL ROAD, LUDHIANA-141003

Reg. No. DAA/LDH/21/346

**ULTRASONOLOGIST :-** This is only professional opinion and not diagnosis. It should be correlated clinically.



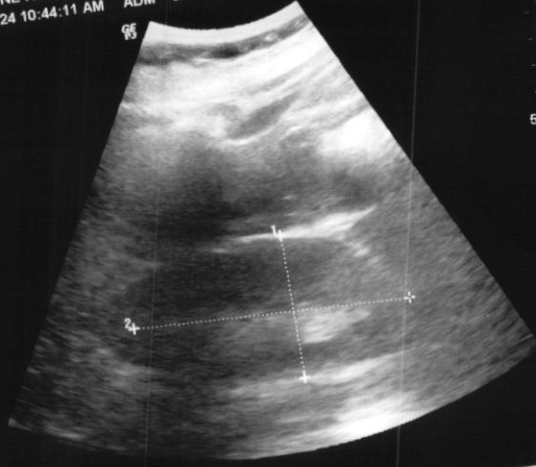LIFELINE HSP.LDH  
09/11/24 10:44:11 AM

95

RAMAN SHARMA 51,  
ADM 091124-104037-AM

MI 0.6 Tis 0.2 4C  
Abdomen

B  
0- Frq 4.0 MHz  
Gn 64  
E/A 1/1  
Map C/D/O  
D 16.0 cm  
DR 72  
FR 19 Hz  
AO 100 %  
XBeam On



5-  
I  
10 I  
15-

1 L 5.27 cm  
2 L 10.41 cm



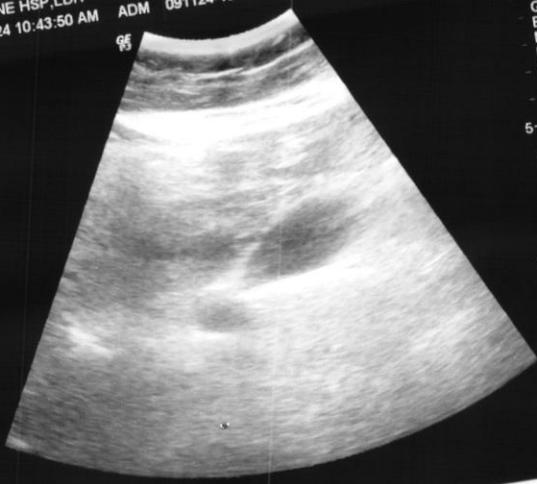LIFELINE HSP.LDH  
09/11/24 10:43:50 AM

95

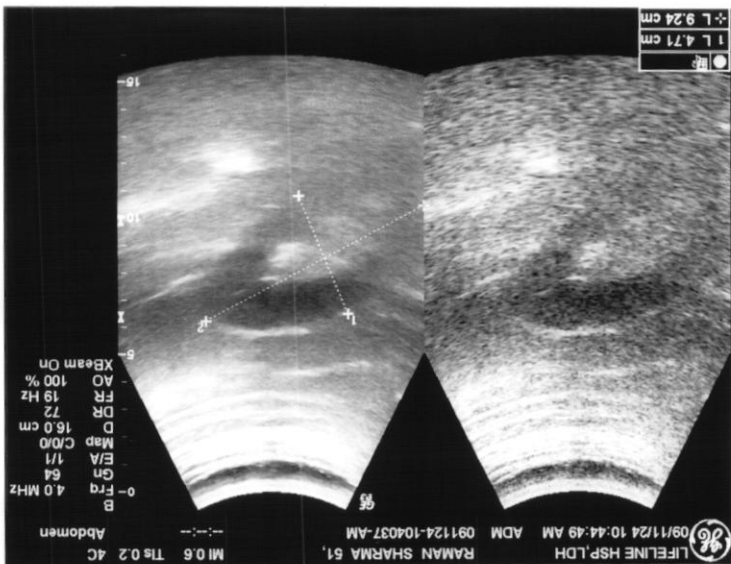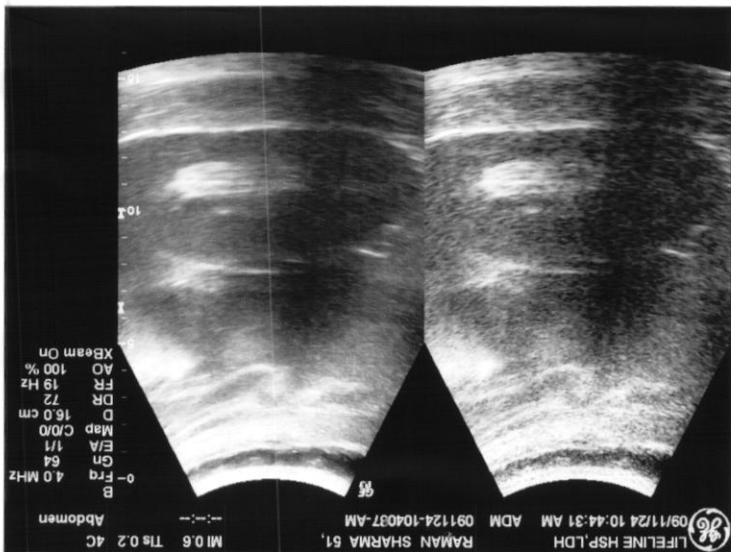
RAMAN SHARMA 51,  
ADM 091124-104037-AM

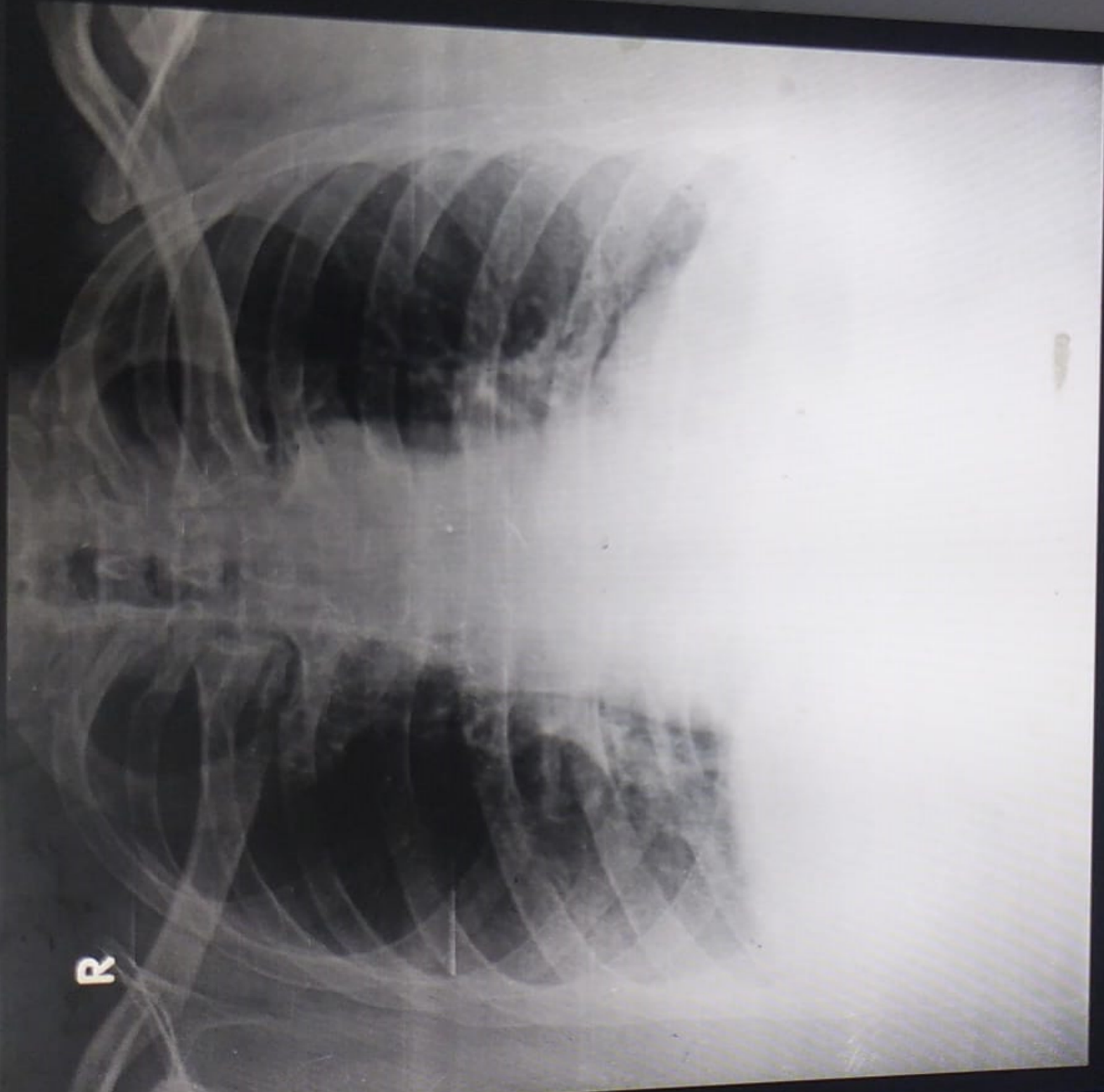
MI 0.6 Tis 0.2 4C  
Abdomen

B  
0- Frq 4.0 MHz  
Gn 64  
E/A 1/1  
Map C/D/O  
D 16.0 cm  
DR 72  
FR 19 Hz  
AO 100 %  
XBeam On



5-  
I  
10 I  
15-





RAMAN SHARMA 51 8002 M CHEST,FRN P->A 09-11-2024 11:42 AM  
LIFELINE HOSPITAL, GILL ROAD ,LUDHIANA