

**DAKSH HOSPITAL**

396 - 397, Gandhi Nagar, Scheme No. 8, ALWAR -301001

Ref. No.

Date.....

MEDICAL EXAMINATION REPORT

Mediwheel (BOB)

Name: Mrs. Pratibha Singh

Age: 33 yrs

Sex: Female

Date: 15/02/2025

General Physical Examination

Height : 165cm  
Pulse : 102/mt  
Respiration : 18/mt

Weight : 110 Kg  
BP : 130/90 mm/hg  
BMI : 40.4 kg/m<sup>2</sup>

Systemic Exam:- NORMALDental Check-up :- NORMALEye check-up:- NORMALSkin Check-up:- NORMALENT Check-up:- NORMAL

Gynae Check-up:- Mh-3y - d m - m - P<sub>1</sub> 8 Feb Plu man  
LMP 9 8 Feb LD-2y - Pap smear late

Impression:- - BMI - 40.4 kg/m<sup>2</sup>, Total Cholesterol 200, TG 180, TSH 5.95Recommendation:- Life style modification  
wt Reduction

Dr. Mukesh Kumar Gupta  
MD Gen. Medicine  
Reg. No 5423/16262

डॉ० मुकेश गुप्ता  
M.D.F.C.C.S.  
फिजिशियन एवं मधुमेह रोग विशेषज्ञ  
दक्ष हॉस्पिटल, अलवर  
रजि० नं०-5423/16262



Date :-15/02/2025

Name :- Mrs.PRATIBHA

Age & Sex 33 Yrs/female

Refd. :- Dr Mukesh Gupta M.D.

	TEST NAME	RESULT	REFERENCE RANGE
	ESR	15	00 -20 mm/hrs
	Blood Group & Rh Factor	A POSITIVE	
	HbA1C	4.7	4 - 5.6%
	Blood Sugar (F)	98.7	< 70 - 100 mg/dl
	Blood Sugar (PP)	-	< 140 mg/dl
	Urine Sugar (F)	NIL	-
	Urine Sugar (PP)	-	-
LIVER	S.Bilirubin Total	1.0	0.30 - 1.20 mg/dl
	S.Bilirubin Direct	0.3	0.10 - 0.30 mg/dl
	S.Bilirubin Indirect	0.7	0.30 - 0.90 mg/dl
	S.G.O.T.	34	>37 u/l
	S.G.P.T.	45	>40 u/l
	S.Alk. Phosp.	190	80-306 u/l
	G.G.T.	27	5-40 u/l
	Total Protein	6.8	6.5 - 8.5 gm/dl
	Albumin	3.6	3.8 - 5.4 gm/dl
	Globulin	3.0	2.3 - 3.5 gm/dl
	A/G Ratio	1.2	-
AST/ALT Ratio	0.75	-	
KIDNEY	Blood Urea	25.2	15 -45 mg/dl
	S.Creatinine	0.72	
	BUN	18	6-24 mg/dl
	S.Uric Acid	5.6	M 3.1 - 7.0, F 2.5 - 5.6 mg/dl
	BUN/Creatinine Ratio	25.1	-
LIPID PROFILE	Total Cholesterol	200.1	Up to 200 mg/dl
	S.HDL	45.1	30 - 70 mg/dl
	S.LDL	119.1	Up to 170 mg/dl
	S.VLDL	36.1	5.0 - 40 mg/dl
	S. Triglycerides	180.1	Up to 170 mg/dl
	LDL/HDL Ratio	2.6	-
	Total Cholesterol/ HDL Ratio	4.4	-
THYROID	T3	110.1	40-181 ng/dl
	T4	7.6	4.6-10.5 ug/dl
	TSH	5.95	0.30 - 5.0 mIU/L

**URINE EXAMINATION**

**Microscopic Examination :**

General/ Chemical Examination:	Colour	Pale Yellow	RBC	Absent
	Reaction	Acidic	WBC	2-3
	Specific Gravity	QNS	Epithelial Cells	0-1
	Appearance	Clear	Cast	Absent
	Albumin	Nil	Crystal	Absent
	Sugar	Nil	Spermatozoa	Absent
			Amorphous Sediments	Absent
			Other	Absent

X-RAY Chest NORMAL STUDY

**STOOL EXAMINATION**

**Microscopic Examination :**

General/ Chemical Examination:	Colour	-	RBC	-
	Consistency	-	WBC	-
	PH	-	Ova & Parasites	-
	Reducing Substances	-		

**Dr. B. S. GUPTA**  
MD (Pathology) (MAHE)  
RMC No. 1924/19778

डॉ. मुकेश गुप्ता  
M.D.F.C.C.S.  
विशेषज्ञ एवं प्रथम रोग विशेषज्ञ

TECHNOLOGIST

Investigations have their own limitations regarding the sensitivity & specificity of individual assay procedures, isolated laboratory investigations never confirm the final diagnosis of the disease. They only help in arriving at a diagnosis in conjunction with clinical presentation and other related investigations. Report is not valid for medico-legal purpose subject to ALWAR jurisdiction only.

Date :- 15/02/2025

Name :- Mrs. Pratibha Singh

Age &amp; Sex :- 33Yrs/ Female


Refd. :- Dr Mukesh Gupta MD

## CYTO-PATHOLOGY

### PAP SMEAR

1. Specimen type	Received two conventional smears.
2. Specimen adequacy	Smears are satisfactory for evaluation.
3. Microscopic finding	Smears are moderately cellular comprises of predominantly intermediate with mature superficial squamous epithelial cells arranged in clusters & scattered singly.
4. Inflammation	Not seen
5. Bacilli	Not seen
6. Endocervical cells	Not seen
7. Koilocytic changes	Not seen
8. Trichomonas	Not seen
9. Dysplasia	Nil
10. Neoplasia	Nil
11. Endometrial cells	Nil

**Impression:-** Negative for intraepithelial lesion or malignancy



Dr. R. S. GUPTA  
MD (Pathology) (MAHE)

RMC No. 7924/19778

TECHNOLOGIST

All investigations have their own limitations regarding the sensitivity & specificity of individual assay procedures, isolated laboratory investigations never confirm the final diagnosis of the disease. They only help in arriving at a diagnosis in conjunction with clinical presentation and other related investigations. Report is not valid for medico-legal purpose subject to ALWAR jurisdiction only.



# दक्ष हॉस्पिटल

396, गाँधी नगर स्कीम नं.8, अलवर (राज०) ☎ 0144-2703340

## Sonography / 2D Echo Cardiography / Doppler Report

NAME :- MRS PRATIBHA SINGH/F/33 YRS

15-Feb-25

BOB HEALTH CHECKUP

### U.S.G. OF ABDOMEN & PELVIS

#### LIVER

Liver is 14.9 cm with normal echo-texture. Intra hepatic biliary radicals Are not dilated. No evidence of focal or diffuse lesion.

#### GALL BLADDER

Gall bladder is contracted.

#### PANCREAS

Pancreas is normal in size, shape & echo-texture. No evidence of focal or diffuse lesion. MPD not dilated.

#### SPLEEN

10.9 cm normal in size with normal shape & echo- texture. Spleen vein is normal. No evidence of focal or diffuse lesion

#### KIDNEY

Both kidneys are normal size shape and echo- texture. CMD maintained.

#### URINARY BLADDER

UB is well distended, visualized lumen appear clear.

#### UTERUS:

Uterus is normal in size (8.2x2.9x5.1cm) with homogenous echo-texture. Endometrial 10 mm in thickness & echo genicity

#### OVARIES:

Both ovaries are normal size, shape & have few small follicles.

Advice- follow up/ hormonal study review at higher center for confirmation

Please correlate clinically. USG accuracy is 95 % due to technical limitations as well as inaccuracies inherent in the laboratory and statistical analysis biological process. This report is not valid for medico-legal cases

DR. MUKESH GUPTA  
SONOLOGIST

Dr. Mukesh Kumar Gupta

Physician & Sonologist

RM 5423/16262



"भ्रूण लिंग परीक्षण की शिकायत  
104 टोल फ्री सेवा पर भी की  
जा सकती है"

भ्रूण लिंग परीक्षण की शिकायत 104 टोल फ्री सेवा पर भी की जा सकती है।



# दक्ष हॉस्पिटल

396, गाँधी नगर स्कीम नं.8, अलवर ( राज० ) ☎ 0144-2703340

## Sonography / 2D Echo Cardiography / Doppler Report

### 2D/ ECHO REPORT

Name: - Mrs Pratibha Singh

Age: - 33 Yrs

Date: - 15-Feb-25

Reg. No.: - Alw/2009/04

BOB health checkup

PROCEDURES:

M-MODE/2D/DOPPLER/COLOR/CONTRAST B.A.S. M<sup>2</sup>


MEASUREMENT:			DOPPLER:					
AOD	23	NORMAL (20- 37mm)	MV	0.6	NORMAL (cm/sec.) (0.8- 1.3)	MR	No	
LA	22	(19- 40mm)	AV	1.4	(1.2- 1.8)	AR	No	
AVO	15	(12- 25mm)	TV	0.6	(0.3- 0.8)	TR	No	
RVDd.	11	(03- 09mm)	PV	0.8	(0.7- 1.1)	PR	No	
LVDd	39	(37- 56mm)	MITRAL VALVE-					
LVDs	23	(22- 40mm)	AML			Normal		
IVS d	11	(06- 12mm)	PML			Normal		
IVS s	13		AORTIC VALVE				Normal	
PWd	3	(05- 10mm)	TV & PV are normal.					
LV FUNCTION								
M- E- S Separation		<0.9cm						
Minor		24.42%						
LV Ejection Fraction	68%	65 +/- 12%						

LV WALL MOTION: NO RWMA  
ALL CARDIAC CHAMBERS ARE NORMAL  
ALL VALVES ARE NORMAL  
NO CLOT, VEGETATION, PERICARDIAL EFFUSION

FINAL DIAGNOSIS: NORMAL STUDY

Adv: - Follow up/ review at higher center for confirmation

Note:- Please Correlate clinically. Due to technical limitations as well as inaccuracies inherent in the laboratory and statistical analysis of biological process. Diagnostic accuracy of ECHO is up to 95% only.  
Report is not valid for medico-legal purpose.

  
DR. MUKESH GUPTA  
Dr. Mukesh Kumar Gupta  
Physician & Sonologist  
RM 5423/16262



भ्रूण लिंग परीक्षण की शिकायत  
104 टोल फ्री सेवा पर भी की जा सकती है।  
जांभूज-लिंग परीक्षण की शिकायत 104 टोल फ्री सेवा पर भी की जा सकती है।

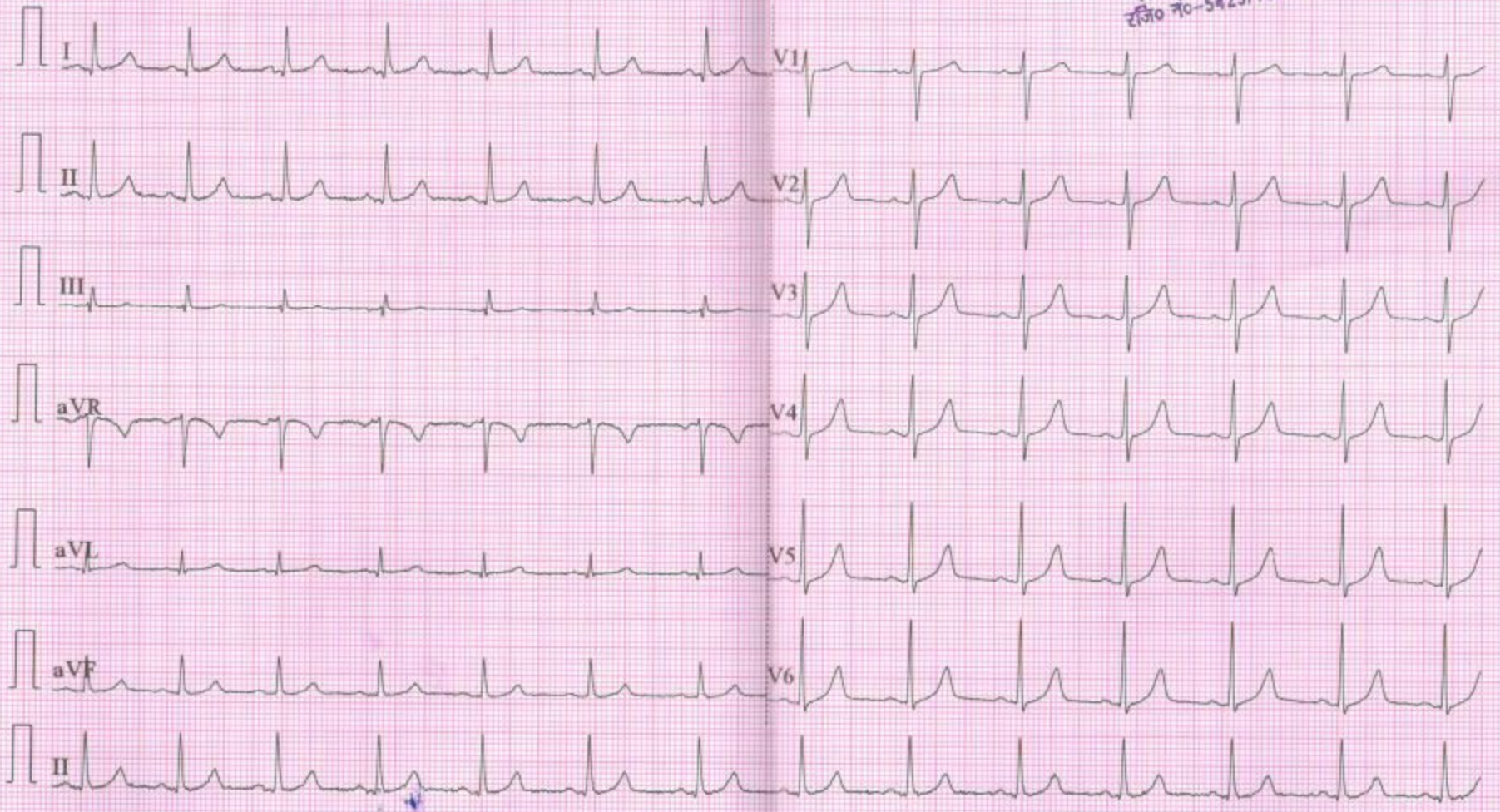
ID: 520  
Female Years

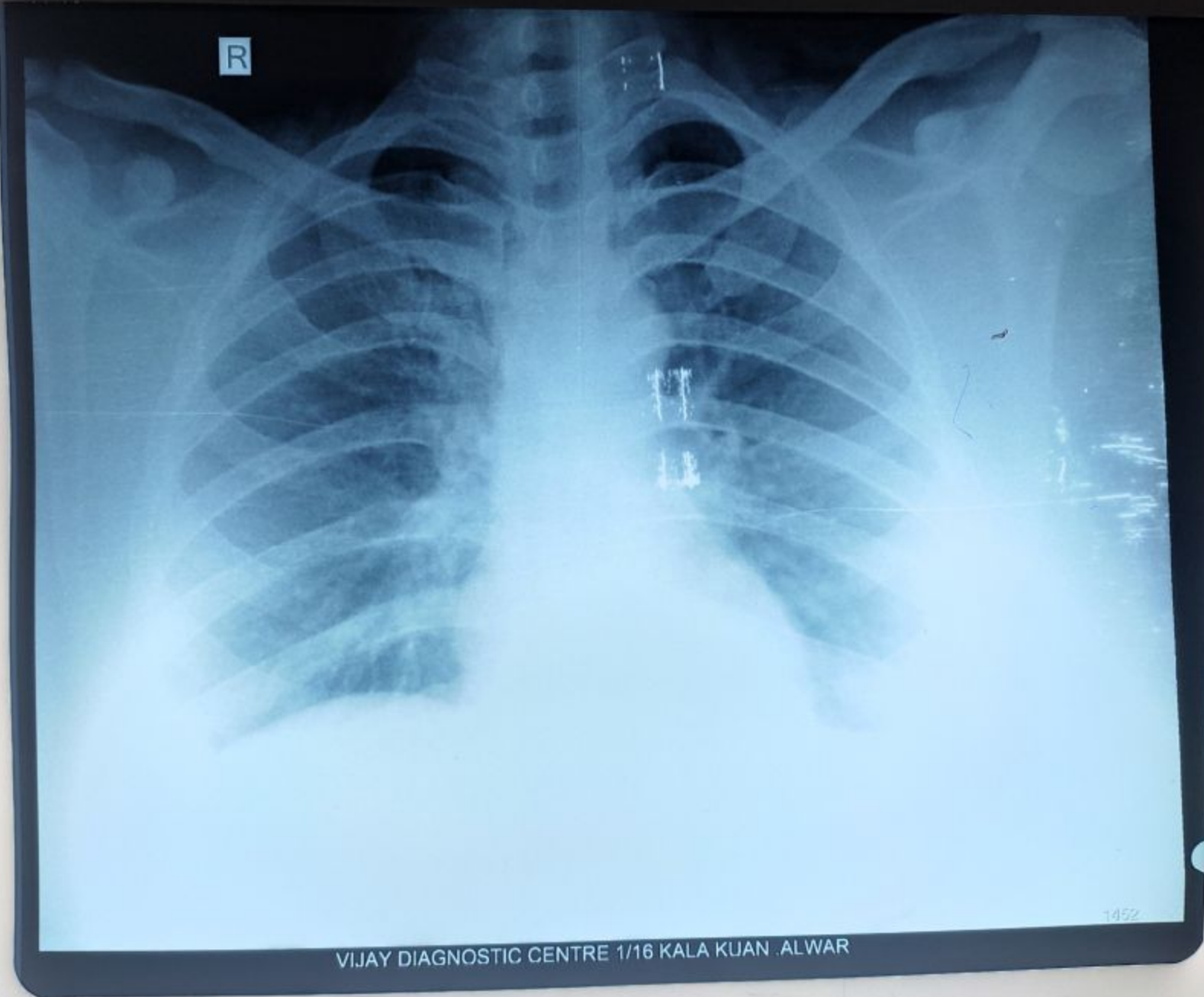
HR : 81 bpm  
P : 99 ms  
PR : 143 ms  
QRS : 80 ms  
QT/QTc : 357/417 ms  
P/ORS/T : 34/48/38 °  
RV5/SVI : 1.398/0.809 mV

Diagnosis Information:  
Sinus Rhythm  
\*\*\*Normal ECG\*\*\*

*Dr. Mukesh Gupta*  
M.D.F.C.C.S.  
फिजिशियन एवं मधुमेह रोग विशेषज्ञ  
दक्ष हॉस्पिटल, अलवर  
रजि० न०-5423/16262

Report Confirmed by:







# DAKSH HOSPITAL

396 - 397, Gandhi Nagar, Scheme No. 8, ALWAR -301001

---

Ref. No.

Date.....

## X-RAY REPORT

Name : Mrs Pratibha Singh  
Date of X-Ray : 15/02/2025  
Part of X-Ray : Digital X-Ray Chest

- Bony cage normal.
- Both Costo Phrenic Angle normal.
- B/L Lung filed normal.
- Cardiac shadow normal.

Note :- Kindly correlate clinically