

Patient Name : MRS. SONAL KUSHAWAHA
Age & Sex. : 35Y /F
Bill date : 08/03/2025 04:59 PM

Bill No. : OPB/1/24/17290
Reg No. : REG-16937
Sponsor : MEDIWHEEL

X-RAY CHEST PA

Both the lung fields appear normal.

Both costophrenic angles appear clear.

Cardiac silhouette appear normal.

Both hila appears normal.

Bony thorax appears normal.

No evidence of free gas seen under dome of diaphragm.

COMMENTS:

- **NORMAL BOTH LUNG FIELDS.**
- **NORMAL CARDIAC SIZE.**

Impression :
Conclusion :

DR SARJAN VASAVA
M.B.B.S D.M.R.D.
Reg. No. G-26527
SAMANVAY HOSPITALS

Dr. Sarjan Vasava

Radiology
(Reg No-G-26527)



WL: 128 WW: 256

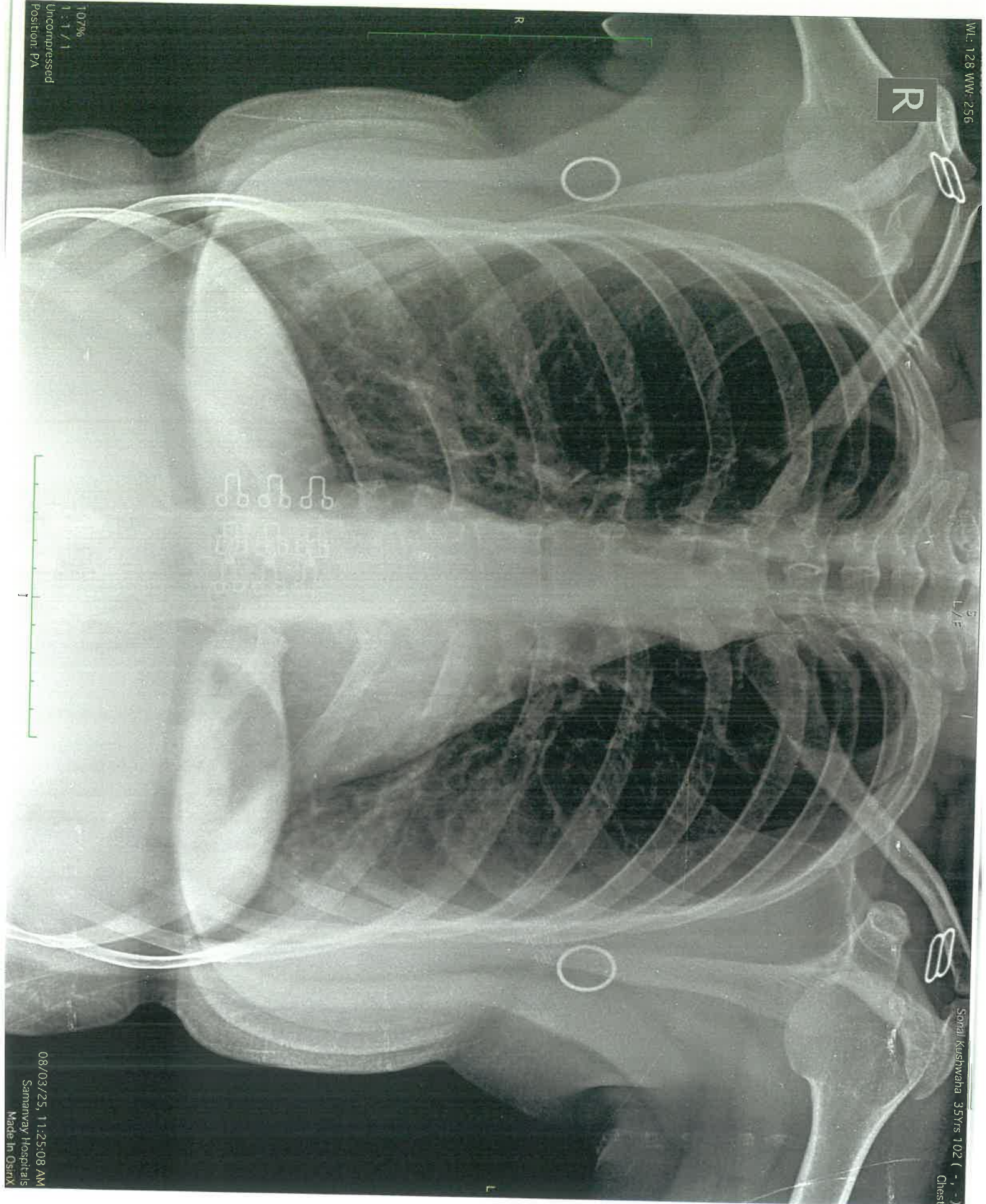
R

L/R

Sonal Kustiawaha 35Yrs 102 (-, -) Chest

107%
1:1/1
Uncompressed
Position: PA

08/03/25, 11:25:08 AM
Samaray Hospital
Made In OshX



sonali
Age: M / F
..... cm / kg

HR 79/min
Intervals:
RR 762 ms
P 114 ms
PR 218 ms
QRS 68 ms
QT 324 ms
QTc 372 ms

Axis:
P 50°
QRS 44°
T 53°
P (II) 0.14 mV
S (V1) -0.74 mV
R (V5) 1.41 mV
Sokol. 2.15 mV

SINUS RHYTHM
PROLONGED PR INTERVAL
5.79

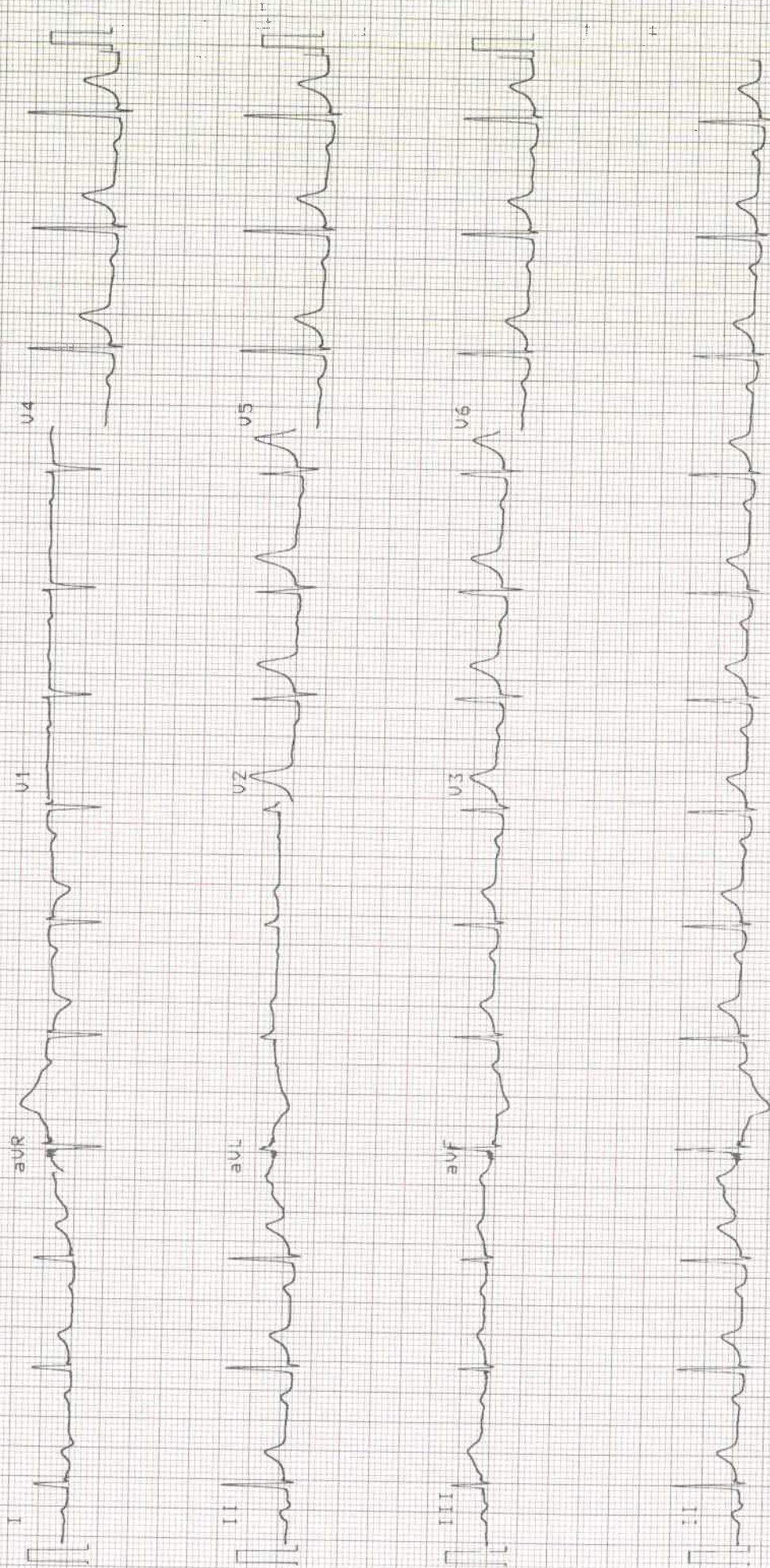


DR. PAVAN ROY
MD, DM (CARDIOLOGY)
CONSULTANT CARDIOLOGIST
REG NO. G-23390
M No 9305990158

UNCONFIRMED REPORT

10 mm/mV

10 mm/mV



10 mm/mV

2D ECHOCARDIOGRAPHY AND COLOUR DOPPLER STUDY

NAME : MRS.SONAL KUSHWAHA

DATE :08-03-25

AGE/SEX : 35YRS / F WARD :HCP REF BY :SAMANVAY HOSPITAL

OBSERVATION:

- NORMAL LV SIZE WITH NORMAL LV SYSTOLIC FUNCTION
- LVEF 60%, NO RWMA AT REST
- E/O NO LV DIASTOLIC DYSFUNCTION, NORMAL LA SIZE
- AORTIC VALVE, NO AR, NO AS
- MITRAL VALVE, MILD MR, NO MS
- TRIVIAL TR,NO PAH, RVSP 20 MMHG
- NORMAL SIZED RA, RV WITH NORMAL RV FUNCTION
- PULMONARY VALVE- NO PR, NO PS, NORMAL SIZED PA & ITS BRANCHES
- IAS, IVS ARE INTACT
- NO INTRACARDIAC CLOT, VEGETATION
- PERICARDIUM NORMAL, NO PERICARDIAL EFFUSION
- IVC NORMAL

MEASUREMENTS:

M MODE: AORTA: 21 MM LA: 30 MM LV DD/DS: 45/24 MM IVS/PW: 12/12 MM
DOPPLER: MV RATIO E/A: 0.8/0.6 M/S AV VMAX: 1.1 M/S PV VMAX: 0.7 M/S

CONCLUSION:

NORMAL LV SIZE AND LV SYSTOLIC FUNCTION
LVEF 60%, NO RWMA AT REST
MILD MR, TRIVIAL TR, NO PAH
E/O NO LV DIASTOLIC DYSFUNCTION



DR. PAVAN ROY
MD, DM (CARDIOLOGY)
CONSULTANT CARDIOLOGIST
REG. NO. G-23390
M No. 9305988155

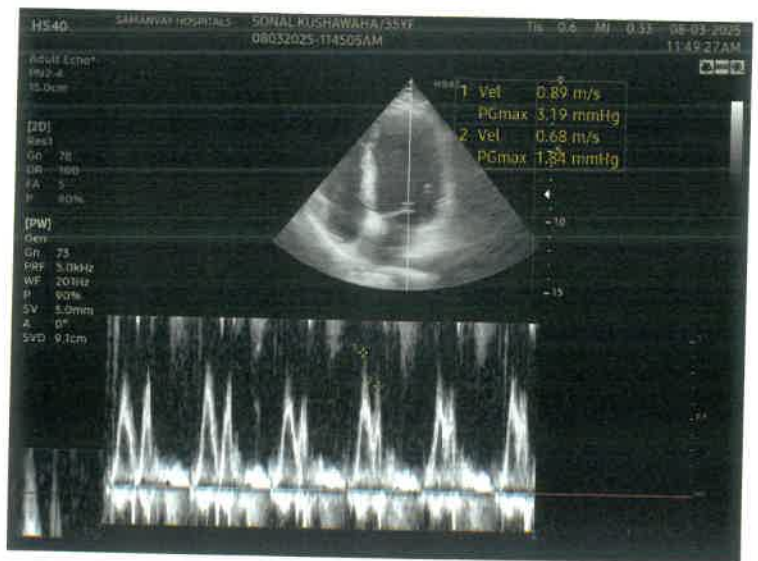
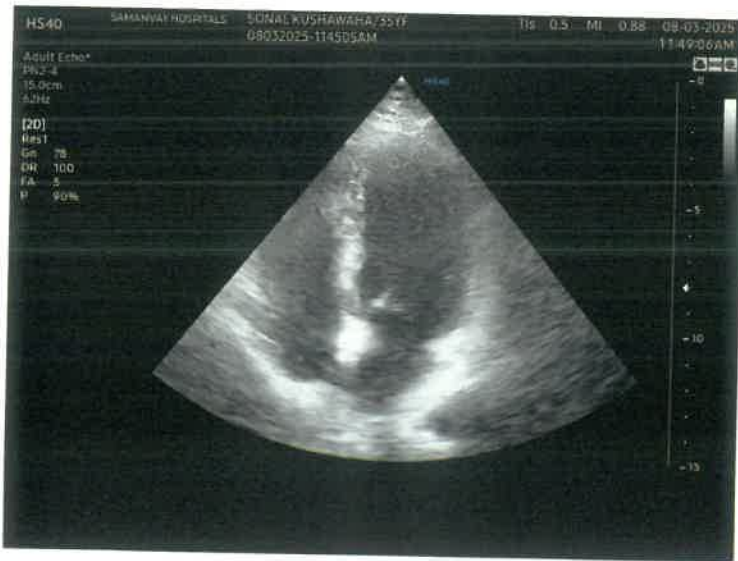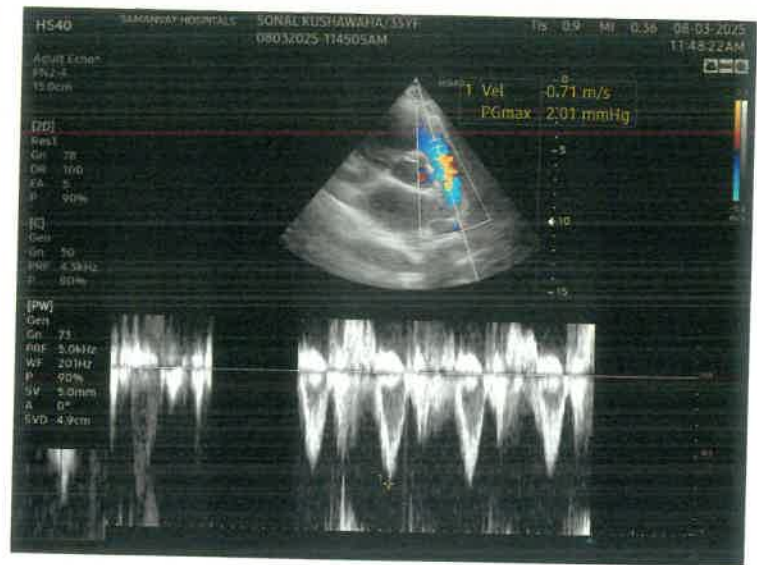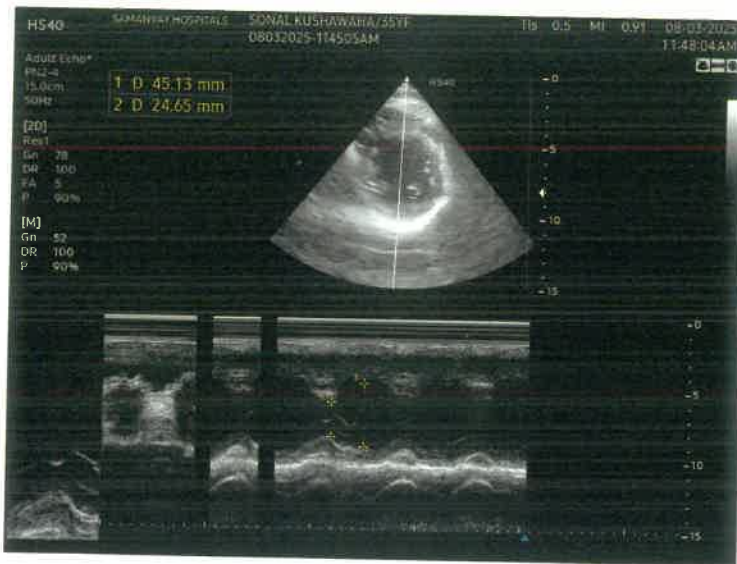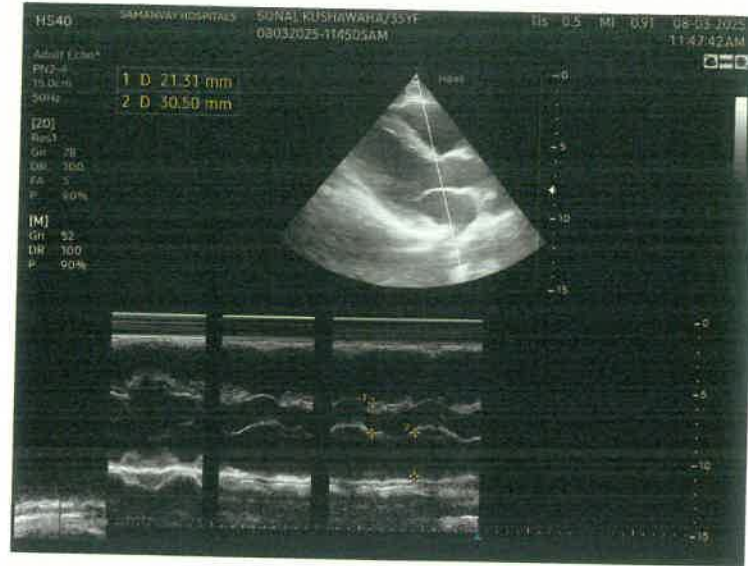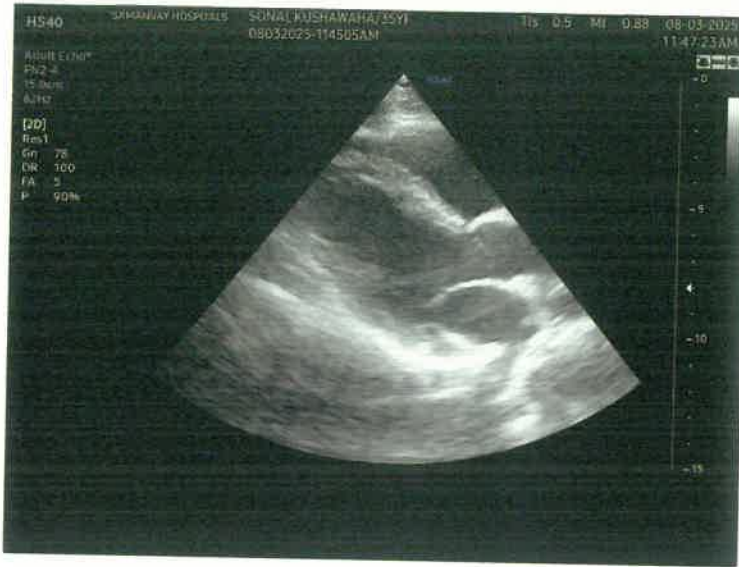DR. PAVAN ROY
MD, DM (CARDIOLOGY), REG NO. G-23390
CONSULTANT INTERVENTIONAL CARDIOLOGIST

Patient

ID 08032025-114505AM
 Name SONAL KUSHAWAHA/35YF
 Birth Date
 Gender

Exam

Accession #
 Exam Date 08-03-2025
 Description
 Operator



SONAL KUSHWAHA

35 YEARS/FEMALE

08/03/2025

REAL TIME SONOGRAPHY OF THE ABDOMEN & PELVIS

LIVER - It is normal in size (13.8 cm). It shows normal echo pattern. No evidence of solid or cystic focal lesion is seen. The intrahepatic biliary system is normal and shows no dilatation of the radicles. The portal vein, CBD and hepatic veins appear normal.

GALL BLADDER - It is distended and appears normal. No evidence of sludge or calculus is seen. The wall appears normal.

PANCREAS - It is visualized and appears normal.

SPLEEN - It appears normal in size (9.1 cm), normal in shape and echotexture. No focal lesions.

KIDNEYS - . Both the kidneys appear normal in size, shape and show normal corticomedullary differentiation. Normal echogenicity of both kidneys.

Right kidney measures 8.4 X 4.1 cm. Left kidney measures 9.3 X 3.7 cm.

No calculus or hydronephrosis is seen on either side.

Urinary bladder is distended and appears normal. No cystitis or mass lesion noted.

Uterus appears normal. ET measures 10.1 mm. No focal lesion.

No evidence of any lymphadenopathy or ascites is noted.

No evidence of dilated bowel loops or bowel wall thickening noted.

IMPRESSION:

NO SONOGRAPHIC ABNORMALITY IS DETECTED.


DR. SARJAN VASAVA,
CONSULTANT RADIOLOGIST.

DR SARJAN VASAVA
M.B.B.S. & M.R.D.
Reg. No. G-25527
SAMANVAY HOSPITALS

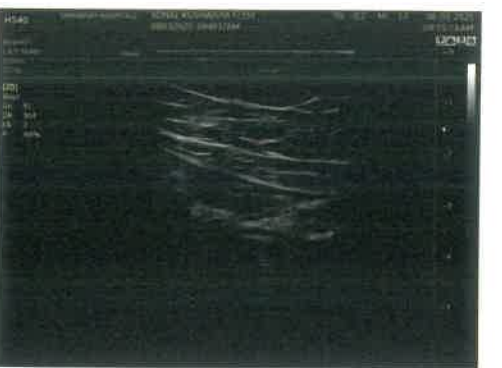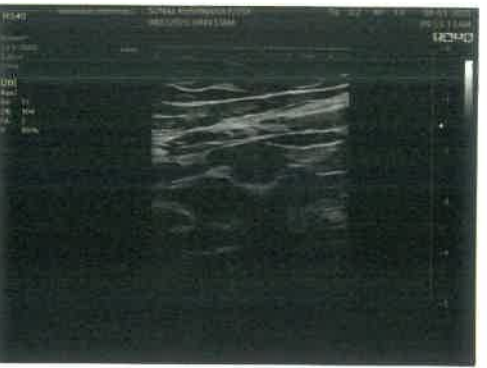
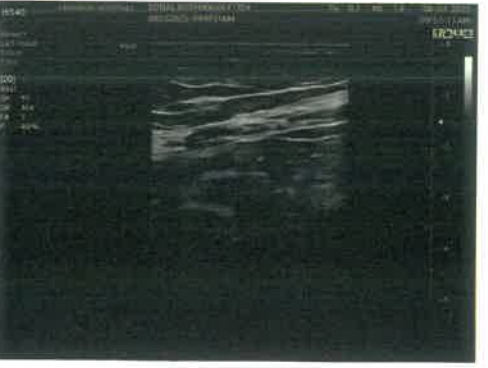

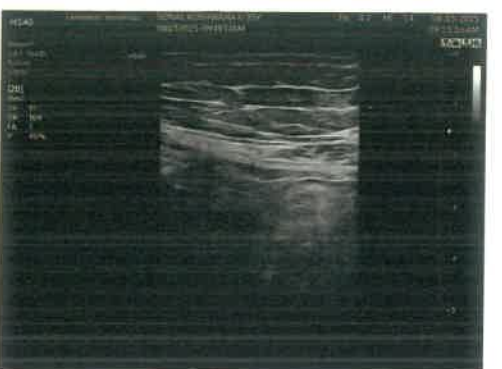
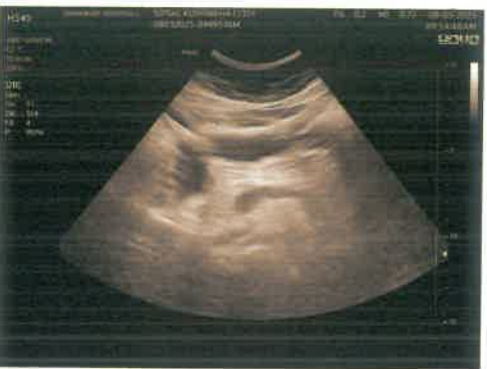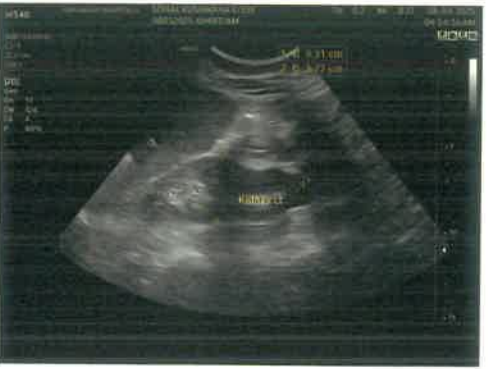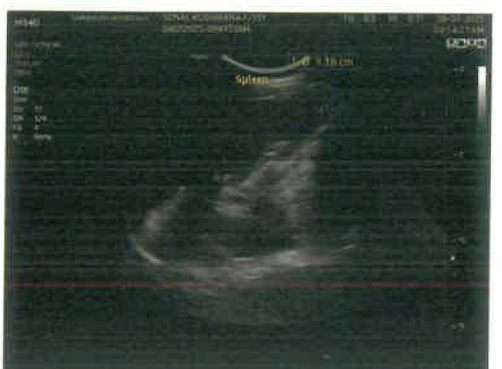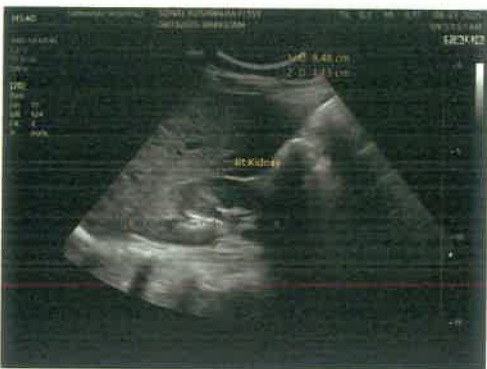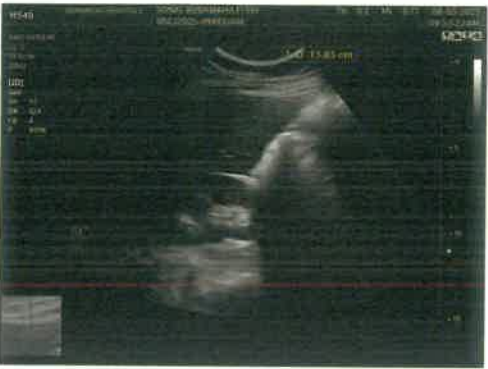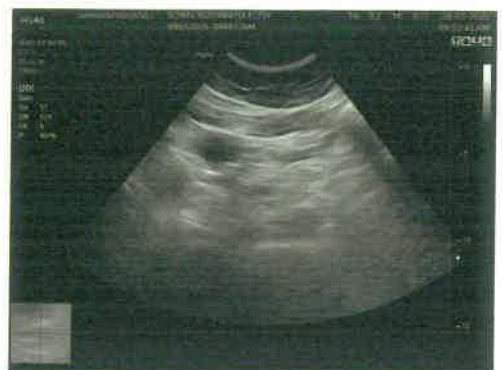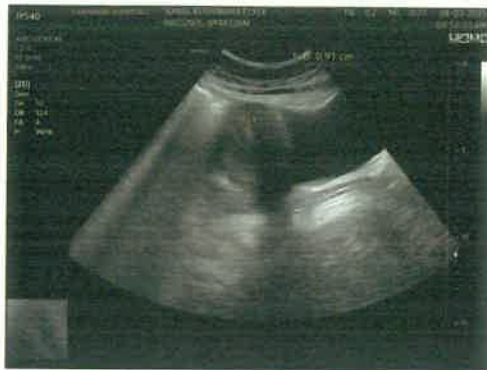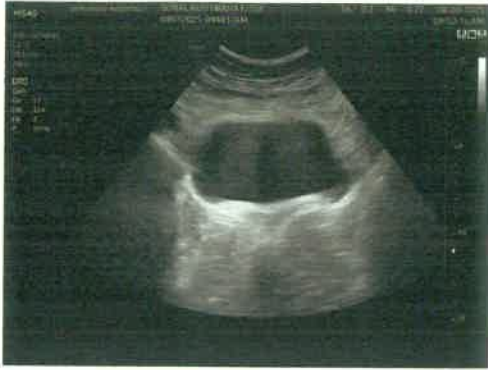Patient

Exam

ID 08032025-094937AM
Name SONAL KUSHWAHA F/35Y
Birth Date
Gender

Accession #
Exam Date 08-03-2025
Description
Operator



EYE CHECK UP

Reg. No. : # Date : 8-3-25

Name : Sonal Kushwaha Age / Sex : 35/F

	RIGHT EYE	LEFT EYE
DISTANCE : (With / Without Glasses)	6/6	6/6
NEAR VISION : (With / Without Glasses)	N6	N6
ANTERIOR SEGMENT :	— day eye —	
I O P (MM of Hg)	— digitally unv —	
FUNDUS :	— unv —	
COLOR VISION :	— unv —	
CLINICAL IMPRESSION :	— unv —	
ADVICE :	(BE) I-kul plus eye drop <u> </u> ①	

Doctor's Signature : *[Signature]*





COMPREHENSIVE HEALTH CHECK UP

Case No. : _____ Date : 8/3/25

Name : Mrs Sonal Kulkarni Age/Sex : 35 y/F

MEDICAL HISTORY : H/O Anemia - hb - 9.9 gm/dl
H/O menorrhagia

PERSONAL HISTORY : _____

Appetite : _____ Smoking : —

Sleep : _____ H/O Alcohol : —

Bladder : _____ Lifestyle : —

Sowel : _____ Exercise : —

DRUG HISTORY : _____

PAST HISTORY : _____

FAMILY HISTORY : _____

GENERAL PHYSICAL EXAMINATION :

Built and Nourishment :

SP02 - 99-1-

Height : 165cm

B. P. : 100/70 mm of Hg

Weight : 63.8 Kg

Character : _____ Pulse : 70 / Min

Nails : _____ Odema : _____

Tonsils : _____ Skin : _____

Tongue : _____ Sclera : _____

Eat. & Joints : _____ Glands : _____



Adv

30 ds { - TB. Negative on 2
Panel

Name:- Gomal kushwaha
Age 64

Date:- 8/3/25

o/e: Stain + Calculus +
- Cervical Abcession $\frac{64}{6}$

Adv: - Scaling
- Rest^m $\frac{64}{6}$



GYNECOLOGICAL CHECK UP

S/B Dr. : Swati Bhimani Date : 8/3/25

Name : Sonal Keshavnagar Age / Sex : _____

COMPLAINTS : NO COMPLAINTS
Abdominal pain / Leucorrhoea/ Dysmenorrhoea / Menorrhoea/
Polymenorrhoea / Discharge PV / Itching PV / Mass PV /
Post Coital Bleed / Dysparunja

MENSTRUAL HISTORY :
MENSTRUAL CYCLE : Reg /
DAYS / Irreg.,
FLOW : Mod / Heavy

LMP : 14/2.

OBS HISTORY :
Duration of Married Life

NO. OF CHILDREN :
G 2 L A 2F1M3

NO.	AGE	SEX	MODE OF DELIVERY	OTHERS


DESIRES CONTRACEPTION : YES / NO
MODE OF CONTRACEPTION : Safe Period / Barrier / IDU / OCP / Others

D/E : P / A h

P/S : 1 min cervical PAP smear

P/V : examination Adm

BREAST - NAD : Rt : _____ Lt : _____

ADVICE : _____


 CONSULTANT'S SIGNATURE : SBE
 ✓ Pap every 3 years
 ✓ Cervical Cancer vaccine