



# YASHFEEN CARDIAC HOSPITAL™

At. & Po. Viraval, Navsari. 396 445. Phone (H) (02637) 235725

Website : www.yashfeenhospital.in E-mail : info@yashfeenhospital.in  
(For Laboratory Reports Only)



Patient Name : NITESHBHAI THAGABHAI GAMIT Age : 47 Years Sex : M  
Ref By Dr. : - Area : Vyara Date : 08/03/2025  
Sample Time : 08/03/2025 08:45 No : 9 Time : 12:26PM

## HAEMOGRAM

Test	Findings	UOM	Normal Range
HAEMOGLOBIN	12.1	g/dl	M-13.5-17.0 gm/dl F-11.5-15.5 gm/dl
<b>HAEMOGRAM</b>			
RED BLOOD CELL	<b>6.61</b>	10 <sup>6</sup> /μL	3.76-5.70
TOTAL LEUCOCYTE COUNT	4900	10 <sup>3</sup> /μL	4,000-11,000cells/cumm
<b>Differential Count</b>			
Neutrophil	58	%	40-75 %
Lymphocytes	37	%	20-40 %
Eosinophil	2	%	01-06 %
Monocytes	3	%	02-10 %
Basophils	0	%	00-00 %
PLATELET COUNT	356000	10 <sup>3</sup> /μL	1.5-5.5 Lacs/cumm
<b>RBC INDICES</b>			
P.C.V.	<b>37.7</b>	%	Male-40-56%, Female-37-47%
M.C.V.	<b>57.0</b>	fL	76.0-94.0
M.C.H.	<b>18.3</b>	pg	27.0-30.0
M.C.H.C.	32.1	g/dl	30.0-35.0
BLOOD GROUP	"O"	-	-
RH FACTOR	POSITIVE	-	-
E.S.R.(1 hour)	<b>2</b>	mm/hr.	Male-5-10 mm/hr, Female-5-20 mm/hr



### Remarks

Designed By : Sarita Infotech Pvt. Ltd., Navsari

Yashfeen Cardiac Hospital

Dr. Piyush B. Chaudhari  
M.D. Medicine

Reg. No. G - 215  
Signature  
Technician

Thanks for Reference



# YASHFEEN CARDIAC HOSPITAL™

Af. & Po. Viraval, Navsari. 396 445. Phone (H) (02637) 235725

Website : www.yashfeenhospital.in E-mail : info@yashfeenhospital.in

(For Laboratory Reports Only)



Patient Name : NITESHBHAI THAGABHAI GAMIT  
Ref By Dr. : -  
Sample Time : 08/03/2025 08:45 No : 9

Age : 47 Years Sex : M  
Area : Vyara Date : 08/03/2025  
Time : 12:26PM

## HAEMOGLOBIN A1 C ESTIMATION

Test	Findings	UOM	Normal Range
Hb A1C	6.5	%	>8 :Action Suggested, 7-8 :Good Control, <7 :Goal, 6-7 :Near Normal Glycemia, <6 :Non-diabetic Level
<b>Technique</b> METHOD - HPLC			
Mean Blood Glucose	139.4	mg/dL	



Dr. P. B. CHAUDHARI  
M.D. Medicine  
Reg. No. G - 21518

### Remarks

Designed By : Sarita Infotech Pvt. Ltd., Navsari

Yashfeen Cardiac Hospital

*Thanks for Reference*

*[Signature]*  
signature  
Technician



# YASHFEEN CARDIAC HOSPITAL™

At. & Po. Viraval, Navsari. 396 445. Phone (H) (02637) 235725

Website : www.yashfeenhospital.in E-mail : info@yashfeenhospital.in  
(For Laboratory Reports Only)



Patient Name : NITESHBHAI THAGABHAI GAMIT Age : 47 Years Sex : M  
Ref By Dr. : - Area : Vyara Date : 08/03/2025  
Sample Time : 08/03/2025 08:45 No : 9 Time : 12:26PM

## LIPID PROFILE TEST REPORT

Test	Findings	UOM	Normal Range
S.CHOLESTEROL	183.0	mg/dL	<200:Desirable, 200-239:Borderline High, >=240:High
HDL CHOLESTEROL	<b>38.2</b>	mg/dL	<40:Low(High Risk), >=60:High(Low Risk)
LDL CHOLESTEROL	<b>139.0</b>	mg/dL	<100.0: Optimal, 100.0-129.0: Nearoptimal/ Aboveoptimal, 130.0-159.0:Borderline High, 160.0-189.0:High, >=190.0:Very High
VLDL CHOLESTEROL	32.5	mg/dL	Upto 40.0 mg/dL
S.TRIGLYCERIDES	<b>162.3</b>	mg/dL	<150.0:Normal, 150.0-199.0:Borderline high, 200.0-499.0:High, >=500.0:Very High
CHOL/ HDL RATIO	4.8	mg/dL	LESS THAN 5.0
LDL/ HDL RATIO	3.6	mg/dL	LESS THAN 5.0



Dr. P. CHAUDHARI  
M.D. Medicine  
Reg.No. G-21518

### Remarks

Designed By : Sarita Infotech Pvt. Ltd., Navsari

Yashfeen Cardiac Hospital

*[Signature]*  
SIGNATURE  
Technician

Thanks for Reference



# YASHFEEN CARDIAC HOSPITAL™

At. & Po. Viraval, Navsari. 396 445. Phone (H) (02637) 235725

Website : www.yashfeenhospital.in E-mail : info@yashfeenhospital.in  
(For Laboratory Reports Only)



Patient Name : NITESHBHAI THAGABHAI GAMIT  
Ref By Dr. : -  
Sample Time : 08/03/2025 08:45 No : 9

Age : 47 Years Sex : M  
Area : Vyara Date : 08/03/2025  
Time : 12:26PM

## LIVER FUNCTION TEST REPORT

Test	Findings	UOM	Normal Range
TOTAL BILIRUBIN	0.6	mg/dL	0-1.0 mg/dL
DIRECT BILIRUBIN	0.2	mg/dL	0-0.8 mg/dL
INDIRECT BILIRUBIN	<b>0.4</b>	mg/dL	0-0.2 mg/dL
SGPT	14.2	U/L	Below 40.0 U/L
S.ALKALINE PHOSPHATASE	81.9	U/L	Child-170.0-515.0 U/L, Adults-37.0-147.0 U/L
TOTAL PROTEIN	7.2	g/dl	6.0-8.0 g/dl
ALBUMIN	4.7	g/dl	3.0-5.0 g/dl
GLOBULIN	<b>2.5</b>	g/dl	3.0-3.5 g/dl
A/G	1.9	g/dl	
SGOT	17.1	U/L	Below 40.0 U/L



Dr. P. YUSH B. CHAUDHARI  
M.D. Medicine  
Reg. No. G-21518

### Remarks

Designed By : Sarita Infotech Pvt. Ltd., Navsari

Yashfeen Cardiac Hospital

*Thanks for Reference*

*[Signature]*  
Signature  
Technician



# YASHFEEN CARDIAC HOSPITAL™

At. & Po. Viraval, Navsari. 396 445. Phone (H) (02637) 235725

Website : [www.yashfeenhospital.in](http://www.yashfeenhospital.in) E-mail : [info@yashfeenhospital.in](mailto:info@yashfeenhospital.in)  
(For Laboratory Reports Only)



Patient Name : NITESHBHAI THAGABHAI GAMIT  
Ref By Dr. : -  
Sample Time : 08/03/2025 08:46 No : 9

Age : 47 Years Sex : M  
Area : Vyara Date : 08/03/2025  
Time : 12:26PM

## BIOCHEMICAL TEST REPORT

Test	Findings	UOM	Normal Range
S.CREATININE	0.9	mg/dL	Male-0.9-1.4 mg/dL, Female-0.8-1.2 mg/dL
BLOOD UREA NITROGEN	9.0	mg/dL	4.7-23.0 mg/dL
S.URIC ACID	5.9	mg/dL	Male:3.5-7.2 mg/dL, Female:2.6-6.0 mg/dL



Dr. P. *Chaudhari*  
USH B. CHAUDHARI  
M.D. Medicine  
Reg.No. G - 21518

### Remarks

Designed By : Sarita Infotech Pvt. Ltd., Navsari

Yashfeen Cardiac Hospital

*Thanks for Reference*

*Signature*  
signature  
Technician



# YASHFEEN CARDIAC HOSPITAL™

At. & Po. Viraval, Navsari. 396 445. Phone (H) (02637) 235725

Website : [www.yashfeenhospital.in](http://www.yashfeenhospital.in) E-mail : [info@yashfeenhospital.in](mailto:info@yashfeenhospital.in)  
(For Laboratory Reports Only)



Patient Name : NITESHBHAI THAGABHAI GAMIT  
Ref By Dr. : -  
Sample Time : 08/03/2025 08:46 No : 9

Age : 47 Years Sex : M  
Area : Vyara Date : 08/03/2025  
Time : 12:26PM

## BLOOD SUGAR TEST REPORT

Test	Findings	UOM	Normal Range
FASTING BLOOD SUGAR	<b>113.9</b>	mg/dL	70-110 mg/dL
FASTING URINE SUGAR	NIL	-	NIL
POSTPANDRIAL BLOOD SUGAR	<b>146.0</b>	mg/dL	70-140 mg/dL
POSTPANDRIAL URINE SUGAR	<b>±±</b>	-	NIL



*P. Chaudhari*  
Dr. PIVUSH B. CHAUDHARI  
M.D. Medicine  
Reg. No. G - 21518

### Remarks

Designed By : Sarita Infotech Pvt. Ltd., Navsari

Yashfeen Cardiac Hospital

*Reth*  
signature  
Technician

*Thanks for Reference*



# YASHFEEN CARDIAC HOSPITAL™

At. & Po. Viraval, Navsari. 396 445. Phone (H) (02637) 235725

Website : [www.yashfeenhospital.in](http://www.yashfeenhospital.in) E-mail : [info@yashfeenhospital.in](mailto:info@yashfeenhospital.in)  
(For Laboratory Reports Only)



Patient Name : NITESHBHAI THAGABHAI GAMIT  
Ref By Dr. : -  
Sample Time : 08/03/2025 08:46 No : 9

Age : 47 Years Sex : M  
Area : Vyara Date : 08/03/2025  
Time : 12:27PM

## THYROID FUNCTION TEST REPORT

Test	Findings	UOM	Normal Range
T3 (TRIODOTHYRONINE)	1.19	ng/ml	Newborns:0.73-2.88, 6 Days-3 Months:0.80-2.75, 4-12Months:0.86-2.65, 1-6 Years:0.92-2.48, 7-11 Years:0.93-2.31, 12-20Years:0.91-2.18, Adults:0.80-2.00
T4(THYROXINE)	8.86	µg/dl	Newborns:5.04-18.5, 6 Days-3 Months:5.41-17.0, 4-12 Months:5.67-16.0, 1-6 Years:5.95-14.7, 7-11 Years:5.99-13.8, 12-20 Years:5.91-13.2, Adults:5.10-14.1
TSH	2.23	µIU/ml	Newborns:0.70-15.2, 6 Days-3 Months:0.72-11.0, 4-12 Months:0.73-8.35, 1-6 Years:0.70-5.97, 7-11 Years:0.60-4.84, 12-20 Years:0.51-4.30, Adults:0.27-4.20

### TECHNIQUE

ELECTROCHEMILUMINESCEN  
CE



Dr. Piyush B. Chaudhari  
M.D. Medicine  
Reg. No. G - 21518

### Remarks

Designed By : Sarita Infotech Pvt. Ltd., Navsari

Yashfeen Cardiac Hospital

*[Signature]*  
Signature  
Technician

*Thanks for Reference*



# YASHFEEN CARDIAC HOSPITAL™

Af. & Po. Viraval, Navsari. 396 445. Phone (H) (02637) 235725

Website : [www.yashfeenhospital.in](http://www.yashfeenhospital.in) E-mail : [info@yashfeenhospital.in](mailto:info@yashfeenhospital.in)  
(For Laboratory Reports Only)



Patient Name : NITESHBHAI THAGABHAI GAMIT  
Ref By Dr. : -  
Sample Time : 08/03/2025 08:46 No : 9

Age : 47 Years Sex : M  
Area : Vyara Date : 08/03/2025  
Time : 12:27PM

## GGT TEST REPORT

Test	Findings	UOM	Normal Range
SERUM GGT	42.0	U/L	10.0-71.0 U/L



*P. Chaudhari*  
Dr. PIVUSH B. CHAUDHARI  
M.D. Medicine  
Reg.No. G - 21518

### Remarks

Designed By : Sarita Infotech Pvt. Ltd., Navsari

Yashfeen Cardiac Hospital

*[Signature]*  
Signature  
Technician

*Thanks for Reference*





# YASHFEEN CARDIAC HOSPITAL™

Af. & Po. Viraval, Navsari. 396 445. Phone (H) (02637) 235725

Website : www.yashfeenhospital.in E-mail : info@yashfeenhospital.in  
(For Laboratory Reports Only)



Patient Name : NITESHBHAI THAGABHAI GAMIT  
Ref By Dr. : -  
Sample Time : 08/03/2025 08:47 No : 9

Age : 47 Years Sex : M  
Area : Vyara Date : 08/03/2025  
Time : 12:29PM

## ROUTINE URINE ANALYSIS

Test	Findings	UOM	Normal Range
<b>PHYSICAL EXAMINATION</b>			
Quantity	-	-	
Colour	YELLOW	-	
Appearance	CLEAR	-	
Reaction	ACIDIC	-	
Sp. Gravity	1.006	-	
<b>CHEMICAL EXAMINATION</b>			
U.Albumin	NIL	-	
Sugar	NIL	-	
Acetone	NIL	-	
Bile Salt	NIL	-	
Bile Pigment	NIL	-	
Occult Blood	NIL	-	
<b>MICROSCOPIC EXAMINATION</b>			
Pus Cells	1-2	/hpf	
Epithelial cells	1-2	/hpf	
Red cells	ABSENT	/hpf	
Casts	-	/hpf	
Crystals	<b>AMORPHOUS SEEN</b>	/hpf	
Others	-	/hpf	



Dr. PIYUSH B. CHAUDHARI  
M.D. Medicine  
Reg. No. G - 21516

### Remarks

Designed By : Sarita Infotech Pvt. Ltd., Navsari

Yashfeen Cardiac Hospital

*Retu*  
signature  
Technician

*Thanks for Reference*



(Regd. No. E / 1390 / Navsari)

# YASHFEEN CARDIAC HOSPITAL™

MANAGED BY :- YASHFEEN FOUNDATION

VIRAVAL, NAVSARI. 396 445. PHONE : (H) (02637) 235725

Website : www.yashfeenhospital.in E-mail : info@yashfeenhospital.in

(Stationary For Report Only)

## 2D ECHO CARDIOGRAPHY COLOUR DOPPLER REPORT

Patient Name & No	: NITESHBHAI THAGABHAI GAMIT CH24045831	Age/Sex	UHID :	: 5972
Doctor	: Mohil Nagad	47/ M	No :	: 5853
Referred By	:		Date :	: 08/03/2025

### M-Mode findings

LVIDd : 40mm  
 LVIDs : 26mm  
 IVSd : 10mm  
 PWd : 09mm  
 EF : 60%  
 Aorta : 22mm  
 LA : 28mm

### 2D Imaging

Aortic Valve : Trileaflet, Normal  
 Mitral Valve : Thin, Pliable, Normal Mobility, Normal function  
 Tricuspid Valve : Normal  
 Pulmonary Valve : Normal

=> : All cardiac chambers are normal sized.  
 => : All cardiac valves are normal.  
 => : No regional wall motion abnormality.  
 => : Normal LV systolic function.  
 => : Normal LV diastolic function.  
 => : IAS/IVS intact.  
 => : No obvious clots/ vegetations/ or effusion.  
 => : IVC Normal size.

### Doppler Findings

=> : No MS/MR, No TS/TR, No AS/AR & No PS/PR  
 Mitral inflow Pattern : E > A  
 Tissue Doppler Findings : E' > A'

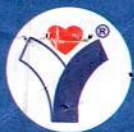Impression : Normal LVEF:60%, No RWMA.



Report Prepared By

**DR. MOHIL NAGAD**  
 M.D. (Medicine), D.M. (Cardiology)  
 Senior Consultant-Interventional Cardiology  
 Reg. No. 22893  
 YASHFEEN CARDIAC HOSPITAL, NAVSARI  
 Non-Invasive Cardiologist

Designed By : Sarita Infotech Pvt. Ltd., Navsari



# YASHFEEN CARDIAC HOSPITAL

## EYE DEPARTMENT

Chief Complaint :

*Routine Checkup*

Medical History : ~~DM / HT / Asthama / Allergy / Heart / Thyroid / TB / Anticoagulants~~

Family History : *—*

Past Ocular History : *—*

Ocular Trauma : *—*

Visual Acuity :

*6/9  
6/8*

IOP :

NAME

08\_MAR\_2025 AM 11:16

NO. 3540

SN: 4771998

REF. DATA

VD: 12.00 CYL: MIX

<R> S C A  
 - 0.00 - 0.25 26  
 - 0.00 - 0.25 27  
 - 0.00 - 0.25 29  
 - 0.00 - 0.25 27  
 S. E. - 0.25

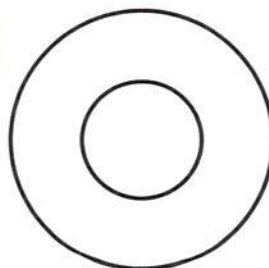
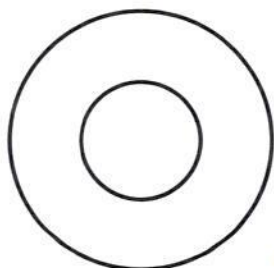
<L> S C A  
 + 0.25 - 0.25 125  
 + 0.25 - 0.25 125  
 + 0.25 - 0.25 124  
 + 0.25 - 0.25 125  
 S. E. + 0.25

PD: 66.0

	RIGHT EYE (PH.....)				LEFT EYE (L)			
	Sph.	Cyl.	Axis	V/A	Sph.	Cyl.	Axis	V/A
Distance	<i>Pl</i>			<i>6/9</i>	<i>M</i>			<i>6/8</i>
Near	<i>← N ADD +1.50 D M →</i>							<i>neb</i>

Constant/Distance/Reading/Bi-Focal/Progressive/Separate Glasses

SLE :



*Addr: Reg. Dept  
After 1 year*

*[Signature]*

# YASHFEEN IMAGING & RADIOLOGY DEPARTMENT

MANAGED BY :- YASHFEEN FOUNDATION

VIRAVAL, NAVSARI. 396 445. PHONE : (H) (02637) 235725

Website : [www.yashfeenhospital.in](http://www.yashfeenhospital.in) E-mail : [info@yashfeenhospital.in](mailto:info@yashfeenhospital.in)

Name	NITESHBHAI T. GAMIT	Age	47Y/M
Ref by Dr	SELF	Date	08/03/2025

## USG ABDOMEN (SCREENING)

**Liver** appears normal in size & shape with normal echopattern.

No e/o focal or diffuse lesion. IHBR appear normal.

PV and CBD appear normal.

**Gall bladder** appears distended & normal in shape & size. No e/o calculus or mass seen.

Walls appear normal.

**Pancreas** appears normal in size and echogenicity. No e/o focal or diffuse lesion.

**Spleen** appears normal in size and shows normal echopattern. No e/o focal lesion.

**Both Kidneys** appear normal in size and echopattern. CM Differentiation is preserved.

No e/o calculus or hydronephrosis on either side.

Perirenal spaces appear normal on either side.

Suprarenal regions appear normal on either side. No e/o mass lesion.

**Bladder** is physiologically distended. No e/o calculus or mass. Walls appear normal.

**Prostate** appears enlarged in size measuring 29 cc with normal echopattern.

No e/o calcification.

RIF region appears normal.

No e/o ascites.

### IMPRESSION:

Mild prostatomegaly. Adv: S. PSA correlation.



**Dr. DHARMESH DESAI**

(M.D. Radiology)

Reg. No. G-45284

YASHFEEN GROUP OF HOSPITAL

Dr. Dharmesh Desai  
MD

Please contact immediately for any typographical error.

This is only professional opinion, not a final diagnosis. Kindly correlate clinically. Not valid for medicolegal purpose.

NITESHBHAI T ,GAMIT

08-03-2025 10:06:59

SINUS RHYTHM  
MARKED LEFT AXIS DEVIATION  
ABNORMAL ECG

ID:  
DOB:  
47 Years , ,  
Male ,Unknown  
Med.:  
Location:  
Referring Physician:  
Notes:

Vent. Rate: 95 BPM  
PR int: 140 ms  
QRS dur: 109 ms  
QT/QTc: 339/392 ms  
P-R-T axes: 60 -37 74  
Avg. RR: 627 ms  
QTcB: 428 ms  
QTcF: 396 ms

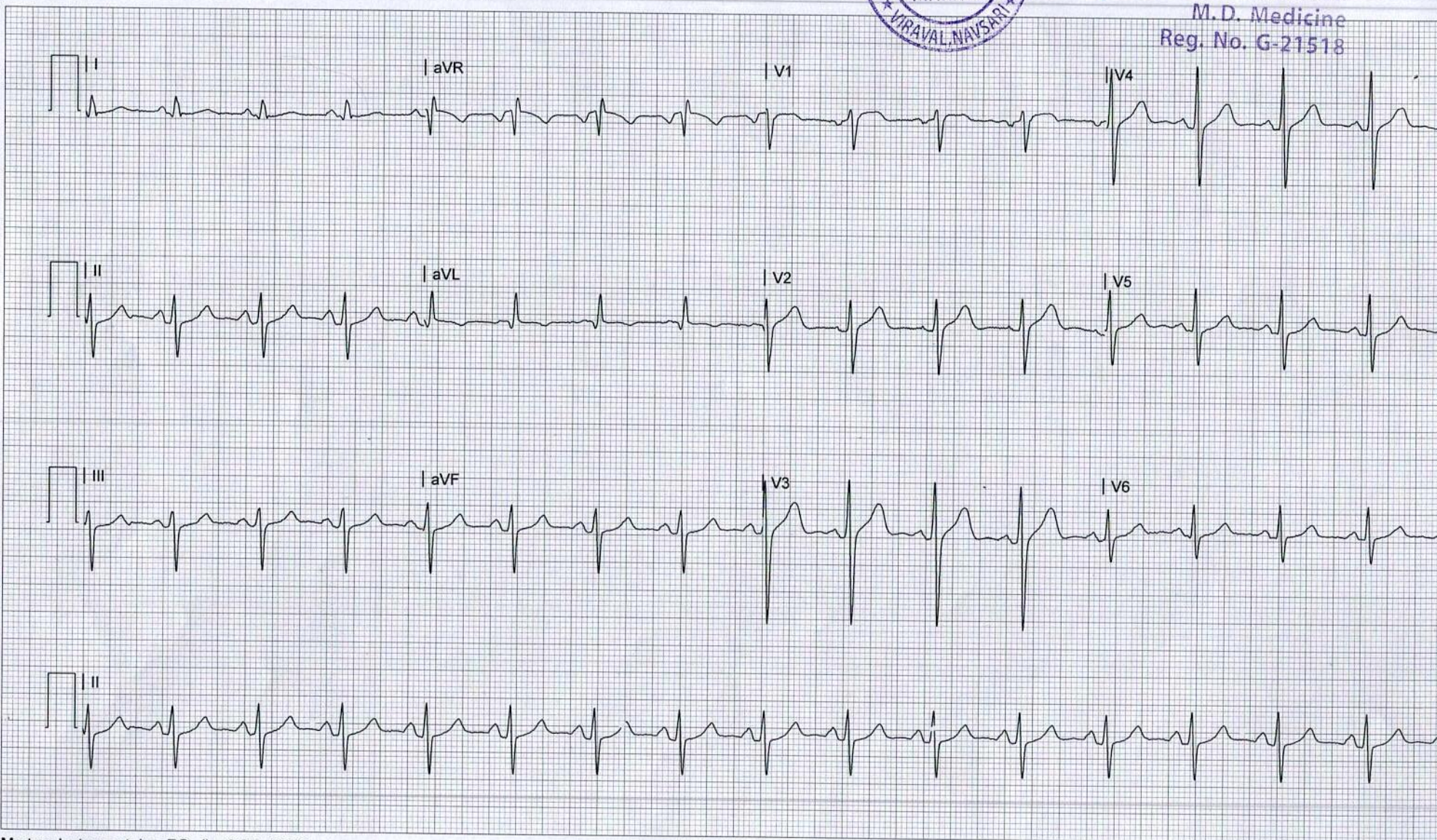
UNCONFIRMED REPORT  
Reviewed by:



Signed by:

Date:

Dr. Piyush B. Chaudhari  
M.D. Medicine  
Reg. No. G-21518



# YASHFEEN IMAGING & RADIOLOGY DEPARTMENT

MANAGED BY :- YASHFEEN FOUNDATION

VIRAVAL, NAVSARI. 396 445. PHONE : (H) (02637) 235725

Website : [www.yashfeenhospital.in](http://www.yashfeenhospital.in) E-mail : [info@yashfeenhospital.in](mailto:info@yashfeenhospital.in)

Patient's Name:	NITESHBHAI T. GAMIT	Age & Sex:	47Yrs/m
Ref. by Dr.	SELF	Date:	08-03-2025

## X RAY CHEST (PA VIEW)

Both lung fields appear normal.  
Both hila appear normal.  
Both CP angles appear clear.  
Cardiac size appears within normal limit.  
Both domes of diaphragm appear normal.  
Bony thoracic cage appears normal.

### IMPRESSION:

- Normal X-ray chest (PA view).



**Dr. DHARMESH DESAI**  
Dr. Dharmesh Desai (Radiology)  
Reg. No. G-45084  
YASHFEEN GROUP OF HOSPITAL

Please contact immediately for any typographical error.

This is only professional opinion, not a final diagnosis. Kindly correlate clinically. Not valid for medicolegal purpose.