



HEALTH CHECK-UP SUMMARY

Race Course Road, Vadodara

Name: ANITA GUPTA	
SH No: 300596	Date:09 11 2024
Age: 46	Gender:FEMALE

ASSESSMENT:

- K/C/O : THYROID, ARTHRITIS & CERVICAL SPONDYLYSIS, ON REGULAR TREATMENT
- C/O:-RIGHT HAND PAIN AND TINGLING SENSATION, FEELING LIKE COUGH STUCK IN CHEST , HAIRFALL , TAKING MEDICATIONS FOR SLEEP , OCCASIONAL HEADACHE, OCCASIONAL EYE PAIN & ITCHING , NECK STIFFNESS , ANXIETY UNDER STRESS, OCCASIONAL DIZZINESS , DYSNPOEA WITH ACTIVITY(Climbing ) , GENERALISED ARTHRALGIA , MILD VAGINAL DISCHARGE
- P/H/O OPERATION: KNEE SURGERY(1981)
- P/H/O HOSPITALIZATION : FOOD POISONING (2024)(15 DAYS)
- F/H/O : HYPERTENSION (FATHER), HEART DISEASE(FATHER) , DIABETES(MOTHER)
- ON AUSCULTATION OF LUNGS : MILD CONGESTION AT MID ZONE IN LEFT LUNG
- NEAR TO ABOVE OPTIMAL DIRECT LDL(120)
- ECG: T INVERSION IN L3 , RIGHT AXIS
- PAP SMEAR-MODERATE ACUTE INFLAMMATION.
- USG ABDOMEN AND PELVIS : MILD BULKY UTERUS WITH EARLY CHANGES OF ADENOMYOSIS. A WELL DEFINED ISO/HYPERECHOIC LESION IN ANTERIOR FUNDAL MYOMETRIUM LIKELY FOCAL ADENOMYOMA/UTERINE LIPOLEIOMYOMA .ADV:SOS TVS PELVIS

ADVISED:

- PLENTY OF LIQUIDS
- AVOID OUT SIDE FOOD AND WATER
- REGULAR EXERCISE.
- OPHTHALMOLOGIST ADVICE : FOLLOW ADVICE
- ORTHOPEDIC CONSULTATION
- GYNAC CONSULTATION
- PHYSICIAN CONSULTATION

**Sterling Addlife India Limited**  
Unit-Sterling Hospital Vadodara  
Race Course Circle, (West)  
VADODARA - 390 007:

**DR. JAY S PANDIT**

Prevention & Rehabilitation Dept

**Hospital Address:** Sterling Hospitals, Race Course Road, Opp. Inox Cinema Hari Nagar, Circle West, Vadodara – 390007, Gujarat, India | Call: 0265-6144111, 0265-2354455, 98 98 98 78 78  
www.sterlinghospitals.com | info@sterlinghospitals.com

**Registered Office:** Sterling Addlife India Private Limited | CIN U85110GJ2000PTC039121  
Sterling Hospital, Sterling Hospital Road, Memnagar, Ahmedabad-380052, Gujarat, India





**HEALTH CHECK UP  
MEDICAL EXAMINATION**

Name : Anita Gupta Employee ID : \_\_\_\_\_  
Company Name : \_\_\_\_\_ Age : 46 Sex : M/F  
Height : 160 cms. Weight : 60.2 Kgs BMI : 23.57 Blood Group : \_\_\_\_\_  
Name of HO / Registrar taking History : Dr - Jay S. Panch

Allergies : <input type="checkbox"/> None <input type="checkbox"/> Yes (If Yes, describe)	
Drugs/Food/Latex/Dyes/Contrast/Other .....	Reaction
1. <u>when increased temp</u>	<u>Body itching</u>
2. <u>of body or dry skin</u>	
3.	

Chief Complaints :  
1. K/clo - arthritis on regular Rx.  
K/clo - cervical spondylosis  
pt Head & pain / Night Hand tingling  
cough stuck in chest, Hairfall. Sesaki

Physical Examination :  
Vital Signs :  
Temp : Afebrile F SPO<sub>2</sub> : 99 Pulse : 77 /min R/R : 18 /min B.P. : 120/80 mm Hg

**Past History :**

If Hypertension, since On Medication 1) ..... 2) ..... 3) .....	If Diabetes, since On Medication 1) ..... 2) ..... 3) .....
If Ischaemic Heart Disease since On Medication 1) ..... 2) ..... 3) .....	Under Treatment Dr. ....
Under Treatment of Dr. ....	If Tuberculosis, When ..... Any Other P/H .....
Any Intervention done .....	Any Other Medication <u>thyroidic Rx.</u> <u>regular Rx.</u>
P/H of Operation Diagnosis : <u>Knee dx.</u> Name of Operation : <u>1981</u> Year of Operation : .....	P/H of Hospitalization Diagnosis : <u>fever/pain</u> Year : <u>2024</u> Duration : <u>(5 Days)</u> Blood Transfusion History : Yes <input checked="" type="checkbox"/> No Year : .....
Others .....	

**Family History :** (Specify : F-Father, M-Mother, B-Brother, S-Sister)

(Pl. Circle whichever is applicable e.g. If Father has h/o 10 yrs then, Yes / No F/10 yrs)

Hypertension	Yes/No <b>F</b>	Asthma	Yes/No <b>M</b>
Heart Disease	Yes/No <b>F</b>	Stroke	Yes/No <b>M</b>
Diabetes	Yes/No <b>M</b>	Arthritis/Gout	Yes/No
Tuberculosis	Yes/No	Cancer	Yes/No
Epilepsy	Yes/No	Other Chronic disease	Yes/No

**Personal History :**

Diet	<b>Veg.</b>	Smoking	Yes/No	since ..... / ..... per day
Appetite	<b>NAD</b>	Alcohol	Yes/No	since ..... / ..... (freq.)
Sleep	<b>on medz</b>	Drugs	Yes/No	since ..... / ..... (freq.)
Micturition	<b>NAD</b>	Tobacco	Yes/No	since ..... / ..... (freq.)
Bowel Habits		Any other habit		

**FOR FEMALES :**

 Obstetric History : L.D. **L.M.P - 26/10/2029**  
 Abortion : **2**  
 Others :

**General Examination :**
 Anemia   
  Cyanosis   
  Jaundice   
  Generalized Lymphadenopathy   
  Pedal oedema

**General Examination :**
**Head :**  NSF **occasional headache**

Injuries (Specify if any) :

**Eyes :**  NSF **glasses for distant vision, regular use for distant seeing**

- Vision :  Normal     Blurred     Double     Colour Blind
- Pupils :  Normal     Abnormal
- Other :  Inflammation     Pain     Itching     Discharge     No complaint

 Remarks (if any) : **(occ. occ.)**
**Ears :**  NSF

- Deaf     Yes     No    • Pain     Yes     No    • Discharge     Yes     No
- Dizziness     Yes     No

**Nose :**  NSF

- Nosebleed     Yes     No    • Congestion     Yes     No    • Sinus problem     Yes     No

**Mouth :**  NSF

- Lesion     Yes     No
- Dental Hygiene     Good     Poor    Bleeding gums     Yes     No
- Sense of taste     Yes     No

**Throat/Neck :**  NSF

- Swollen glands  Yes  No
- Stiffness  Yes  No
- Dysphagia  Yes  No

**SYSTEMIC EXAMINATION**

**Neurological :**  NSF

- Headache  Yes  No
- Memory changes  Yes  No
- Dizziness  Yes  No
- Syncope  Yes  No
- Seizures  Yes  No
- Paralysis  Yes  No if yes  R  L
- Cooperative  Yes  No
- Anxiety  Yes  No
- Depression  Yes  No
- Suicidal attempt  Yes  No
- Any psychiatric illness NO
- Oriented  Yes  No if disoriented, to  Person  Place  Time
- Reaction:  Brisk  Sluggish  No response
- LOC:  Alert  Confused  Sedated
- Speech:  Clear  Slurred

**Respiratory :**  NSF

- Lung sounds: mild congestion at mid zone right
- Dyspnoea:  None  With activity  At rest  Lying down  Retractions
- Cough:  None  Non-productive  Productive - colour
- Hemoptysis:  Yes  No
- Night Sweats:  Yes  No
- Cyanosis:  Yes  No Where .....

**Cardiovascular :**  NSF

- Chest discomfort  Yes  No
- Oedema  Yes  No Location: .....  Pitting  Non-pitting

**Extremities-Musculoskeletal :**  NSF

- Skin:  Warm  Cool  Dry  Firm  Flaccid  Colour
- Extremities: Tingling  Yes  No • Weakness  Yes  No Deformity  Yes  No
- Joints: Pain  Yes  No • Stiffness  Yes  No
- Uses:  Walker  Wheelchair  None arthralgia generalized

**Gastrointestinal :**  NSF

- Appetite  Good  Poor
- Nausea  Yes  No
- Vomiting  Yes  No
- Distension  Yes  No
- Heartburn  Yes  No
- Flatus  Yes  No
- Pain  Yes  No
- Rectal Bleeding  Yes  No
- Colostomy  Yes  No
- Ileostomy  Yes  No

**Bowel**

- Diarrhoea  Constipation  Incontinence  Blood in stool  None
- Pain  Yes  No Place ..... Hemorrhoids  Yes  No
- Frequency of stool ..... 1 time/day
- Interventions:  None • Laxatives  Yes  No Type stunweck Frequency 1 time/day

**Genitorurinary :**  NSF

Colour of Urine white Frequency 1 time / 9-5-2 hrs.

Pain  Yes  No Burning  Yes  No Itching  Yes  No

Urgency  Yes  No Incontinence  Yes  No

Nocturia  Yes  No Urostomy  Yes  No

History of calculi  Yes  No History of UTI  Yes  No

Foleys Catheter  Yes  No Date of Insertion \_\_\_\_\_

**Reproductive :**  NA  NSF

LMP \_\_\_\_\_ Regular / Irregular \_\_\_\_\_

Dysmenorrhea  Yes  No Amenorrhea  Yes  No if yes, Duration \_\_\_\_\_

Menopausal  Yes  No if yes, Duration \_\_\_\_\_

Vaginal discharge  Yes  No Itching  Yes  No

Little

**Breasts**  NA  NSF

Breast Feeding  Yes  No Lumps  Yes  No

**Positive Finding & Advice**

.....

.....

.....

.....

**Sterling Addlife India Limited**  
Unit-Sterling Hospital Vadodara  
Race Course Circle, (West)  
VADODARA - 390 007.

Sign and Stamp of Medical Officer

**Sterling Hospital**  
Racecourse Road

**EMERGENCY HELPLINE**

992 444 9972  
0265 - 61 44 111

**Sterling Hospital**  
Bhayli

**EMERGENCY HELPLINE**

908 1000 557  
0265 - 61 23 333



**Sterling**  
HOSPITALS

**HOPE**  
**HEALTH**  
**HAPPINESS**



OPHTHALMIC CHECK-UP

SIGNIFICANT HISTORY:

PAST HISTORY:

Refractive Error:

Any Surgery:

Color Blind:

Diabetes:

Hypertension:

Any Treatment:

EXAMINATION OF EYES:

Right Eye:

Left Eye:

Distant Vision without Glasses:

Distant Vision with Glasses:

Near Vision without Glasses:

Near Vision with Glasses:

Intraocular Pressure:

Anterior Segment:

Fundus:

PRESCRIPTION OF GLASSES:

	RIGHT			LEFT		
	Sphere	Cylinder	Axis	Sphere	Cylinder	Axis
Distant	-1.5	-0.5	90°	-0.75	-0.75	75°
Near		--			--	--

Type of glass:

ADVICE:

**Sterling Addlife India Limited**  
Unit-Sterling Hospital Vadodara  
Race Course Circle, (West)  
VADODARA - 390 007.

**DR MAYA PATEL**  
(OPHTHALMOLOGIST)

**Hospital Address:** Sterling Hospitals, Race Course Road, Opp. Inox Cinema Hari Nagar, Circle West, Vadodara - 390007, Gujarat, India | Call: 0265-6144111, 0265-2354455, 98 98 98 78 78  
www.sterlinghospitals.com | info@sterlinghospitals.com

**Registered Office:** Sterling Addlife India Private Limited | CIN U85110GJ2000PTC039121  
Sterling Hospital, Sterling Hospital Road, Memnagar, Ahmedabad-380052, Gujarat, India





GYNAECOLOGIST CHECK UP

NAME: Anita Cuplai

AGE: 46 yrs

COMPLAINTS: C/o Thyroid

O/H PARA: G<sub>4</sub> P<sub>2</sub> A<sub>2</sub> L<sub>2</sub>

MENSTRUAL H/O: 26/10/24

P/A: Soft

P/S: NAD

P/V: NAD

ADVICE: Pap smear test taken

DATE: 9/11/24

1 male  
~~1 male~~ - 22 yrs

1 Female - 19 yrs

Both of LSCS

TL not done

Patient not come  
took her records.

MC - 1-2 days.  
26-30

Sterling Addlife India Limited  
Unit-Sterling Hospital Vadodara

Race Course Circle, (West)

VADODARA - 390 007.

*Dr. Archana Dwivedi*  
DR. ARCHANA DWIVEDI  
(GYNAECOLOGIST)





Passport No :

**LABORATORY TEST REPORT**


Patient Information	Sample Information	Location Information
Name : Mrs. Anita . Gupta	Lab Id : 112407500792	Pt. Type : Sterling Hospital Vadodara Health Checkup
Sex/Age : Female / 46 Y 29-Dec-1977	Registration on : 09-Nov-2024 09:08	Location : Main BNo./
Ref. Id : 300596 / 2817538	Collected at : SAWPL	Approved on : 09-Nov-2024 14:09 Status : Final
Ref. By : Dr. RMO . STERLING...	Collected on : 09-Nov-2024 09:04	Printed On : 09-Nov-2024 16:14
	Sample Type : EDTA blood	Process At : 75 – Sterling Hospital, Race course (Vadodara)

**MEDIWHEEL FULL BODY ANNUAL PLUS CHECK/ ADVANCE**
**Complete Blood Count**

Test	Result	Unit	Biological Ref. Interval
Hemoglobin <small>Colorimetric</small>	12.8	g/dL	12.0 - 16.0
RBC Count <small>Electrical impedance</small>	4.34	million/cmm	3.8 - 4.8
Hematocrit <small>Calculated</small>	39.1	%	36 - 48
MCV <small>Derived</small>	90.2	fL	83 - 101
MCH <small>Calculated</small>	29.6	pg	26.4 - 33.2
MCHC <small>Calculated</small>	32.8	g/dL	31.8 - 35.9
RDW CV <small>Calculated</small>	13.30	%	11.6 - 14

**Total WBC and Differential Count**

WBC count	SF Cube cell analysis	7280	/cmm	4000 - 10000
-----------	-----------------------	------	------	--------------

**Differential Count**

Differential Count	Result	Unit	Absolute Count
Neutrophils <small>Microscopic</small>	60	% 40 - 80	4368 /cmm 2000 - 6700
Lymphocytes <small>Microscopic</small>	29	% 20 - 40	2111 /cmm 1000 - 3000
Eosinophils <small>Microscopic</small>	04	% 1 - 6	291 /cmm 20 - 500
Monocytes <small>Microscopic</small>	07	% 2 - 10	510 /cmm 200 - 1000
Basophils <small>Microscopic</small>	00	% 0 - 2	0 /cmm 0 - 100

**Platelet Count**

Platelet Count	Electrical impedance	399000	/cmm	150000 - 410000
----------------	----------------------	--------	------	-----------------

MPV	Calculated	10.40	fL	7.5 - 10.3
-----	------------	-------	----	------------

Platelets Morphology Platelets are adequate on Smear


 Dr. C. Shrinivasan..

 M.D ( Pathology ) [G-18341]  
Consultant Pathologist

Page 1 of 14

This is an Electronically Authenticated Report

**Sterling Accuris Pathology Laboratory**

Sterling Hospital, Opp. Inox Cinema, Race Course Circle (West), Vadodara - 390 007, tests marked with # are referred tests

Ph: 0265-6144210

pathlab@sterlinghospitals.com | Website: www.sterlinghospitals.com / www.sterlingaccuris.com



Download Accuris App







Passport No :

**LABORATORY TEST REPORT**



Patient Information		Sample Information		Location Information	
Name	: Mrs. Anita . Gupta	Lab Id	: 112407500792	Pt. Type	: Sterling Hospital Vadodara Health Checkup
Sex/Age	: Female / 46 Y 29-Dec-1977	Registration on	: 09-Nov-2024 09:08	Location	: Main BNo./
Ref. Id	: 300596 / 2817538	Collected at	: SAWPL	Approved on	: 09-Nov-2024 14:09 Status : Final
Ref. By	: Dr. RMO . STERLING...	Collected on	: 09-Nov-2024 09:04	Printed On	: 09-Nov-2024 16:14
		Sample Type	: EDTA blood	Process At	: 75 – Sterling Hospital, Race course (Vadodar

**MEDIWHEEL FULL BODY ANNUAL PLUS CHECK/ ADVANCE**

**Complete Blood Count**

Test	Result	Unit	Biological Ref. Interval
<b>Erythrocytes Sedimentation Rate</b>			
ESR	7	mm/1hr	0 - 21
<small>Capillary photometry</small>			

**Differential Count**

**Absolute Count**

**Dr. C. Shrinivasan..**

M.D ( Pathology ) [G-18341]  
Consultant Pathologist

This is an Electronically Authenticated Report.

**Sterling Accuris Pathology Laboratory**

Sterling Hospital, Opp. Inox Cinema, Race Course Circle (West), Vadodara - 390 007 tests marked with # are referred tests

Ph: 0265-6144210

pathlab@sterlinghospitals.com | Website: www.sterlinghospitals.com / www.sterlingaccuris.com





Passport No :

**LABORATORY TEST REPORT**


Patient Information	Sample Information	Location Information
Name : <b>Mrs. Anita . Gupta</b> Sex/Age : <b>Female / 46 Y</b> 29-Dec-1977 Ref. Id : 300596 / 2817538 Ref. By : Dr. RMO . STERLING...	Lab Id : <b>112407500792</b> Registration on : 09-Nov-2024 09:08 Collected at : <b>SAWPL</b> Collected on : 09-Nov-2024 09:04 Sample Type : EDTA blood	Pt. Type : Sterling Hospital Vadodara Health Checkup Location : Main : BNo./ Approved on : 09-Nov-2024 12:28 Status : Final Printed On : 09-Nov-2024 16:14 Process At : 75 – Sterling Hospital, Race course (Vadodar

**MEDIWHEEL FULL BODY ANNUAL PLUS CHECK/ ADVANCE**
**Blood Group**

Test	Result	Unit	Biological Ref. Interval
<b>ABO Type</b> <i>Tube Agglutination</i>	"O"		
<b>Rh (D) Type</b>	Positive		


 Dr. C. Shrinivasan..

 M.D ( Pathology ) [G-18341]  
 Consultant Pathologist

Page 3 of 14

This is an Electronically Authenticated Report.

**Sterling Accuris Pathology Laboratory**

Sterling Hospital, Opp. Inox Cinema, Race Course Circle (West), Vadodara - 390 007, tests marked with # are referred tests

Ph: 0265-6144210

pathlab@sterlinghospitals.com | Website: www.sterlinghospitals.com / www.sterlingaccuris.com



Download Accuris App





Passport No :

**LABORATORY TEST REPORT**


Patient Information	Sample Information	Location Information
Name : Mrs. Anita . Gupta	Lab Id : 112407500792	Pt. Type : Sterling Hospital Vadodara Health Checkup
Sex/Age : Female / 46 Y 29-Dec-1977	Registration on : 09-Nov-2024 09:08	Location : Main BNo./
Ref. Id : 300596 / 2817538	Collected at : SAWPL	Approved on : 09-Nov-2024 10:36 Status : Final
Ref. By : Dr. RMO . STERLING...	Collected on : 09-Nov-2024 09:04	Printed On : 09-Nov-2024 16:14
	Sample Type : Serum, Urine	Process At : 75 – Sterling Hospital, Race course (Vadodar

**MEDIWHEEL FULL BODY ANNUAL PLUS CHECK/ ADVANCE**

Test	Result	Unit	Biological Ref. Interval
<b>Fasting Blood Glucose</b> <i>GOD-POD</i>	95.0	mg/dL	74 - 100
<b>Fasting Urine Glucose</b> <i>GOD-POD</i>	Absent		Absent
<b>Fasting Urine Ketone</b> <i>Nitroprusside</i>	Absent		Absent

	Fasting Blood Glucose*	Postprandial Blood Glucose #	Random Blood Glucose
Normal	< 100 mg/dL	< 140 mg/dL	< 140 mg/dL
Prediabetic	100 – 125 mg/dL	140 – 199 mg/dL	140 – 199 mg/dL
Diabetic	>/=126 mg/dL	>/= 200 mg/dl	>/= 200 mg/dl

\* Fasting is defined as no caloric intake for more than 8 hours

# The test should be performed as described by the WHO, using a glucose load containing the equivalent of 75 g anhydrous glucose dissolved in water.

**Criteria for Diagnosis of Diabetes:**

1. Fasting blood glucose (FPG)  $\geq$  126 mg/dL
2. Two-hour blood glucose (2-h OGTT) = 200 mg/dL
3. HbA1c values (A1c)  $\geq$  6.5%
4. Random plasma glucose  $\geq$  200 mg/dL

(With symptoms of hyperglycemia or hyperglycemic crisis)

In the absence of unequivocal hyperglycemia, diagnosis of DM using A1C, FPG or 2-h OGTT requires two abnormal test results from the same sample or in two separate samples.

**References:**

1. American diabetes association. Standards of medical care in diabetes 2024
2. National Library of Medicine – National Institute of Health (USA) – Diabetes Mellitus
3. World Health Organization – Factsheet on Diabetes – Prevention and treatment


  
Dr. C. Shrinivasan..

 M.D ( Pathology ) [G-18341]  
Consultant Pathologist

Page 4 of 14

This is an Electronically Authenticated Report

**Sterling Accuris Pathology Laboratory**

 Sterling Hospital, Opp. Inox Cinema, Race Course Circle (West), Vadodara - 390 007. Tests marked with # are referred tests  
Ph: 0265-6144210

 pathlab@sterlinghospitals.com |  Website: www.sterlinghospitals.com / www.sterlingaccuris.com


Download Accuris App





Passport No :

**LABORATORY TEST REPORT**


Patient Information		Sample Information		Location Information	
Name	: Mrs. Anita . Gupta	Lab Id	: 112407500792	Pt. Type	: Sterling Hospital Vadodara Health Checkup
Sex/Age	: Female / 46 Y 29-Dec-1977	Registration on	: 09-Nov-2024 09:08	Location	: Main BNo./
Ref. Id	: 300596 / 2817538	Collected at	: SAWPL	Approved on	: 09-Nov-2024 12:55 Status : Final
Ref. By	: Dr. RMO . STERLING...	Collected on	: 09-Nov-2024 11:40	Printed On	: 09-Nov-2024 16:14
		Sample Type	: Fluoride	Process At	: 75 – Sterling Hospital, Race course (Vadodar

**MEDIWHEEL FULL BODY ANNUAL PLUS CHECK/ ADVANCE**

Test	Result	Unit	Biological Ref. Interval
Post-breakfast Blood Glucose <i>GOD-POD</i>	92	mg/dL	70 - 140
Post-breakfast Urine Glucose <i>GOD-POD</i>	Absent		Absent
Post Breakfast Urine Ketone <i>Nitroprusside</i>	Absent		Absent


**Dr. C. Shrinivasan..**

 M.D ( Pathology ) [G-18341]  
 Consultant Pathologist

Page 5 of 14

This is an Electronically Authenticated Report.

**Sterling Accuris Pathology Laboratory**

 Sterling Hospital, Opp. Inox Cinema, Race Course Circle (West), Vadodara - 390 007 tests marked with # are referred tests  
 Ph: 0265-6144210

 pathlab@sterlinghospitals.com |  Website: www.sterlinghospitals.com / www.sterlingaccuris.com


Download Accuris App





Passport No :

**LABORATORY TEST REPORT**


Patient Information	Sample Information	Location Information
Name : Mrs. Anita . Gupta	Lab Id : 112407500792	Pt. Type : Sterling Hospital Vadodara Health Checkup
Sex/Age : Female / 46 Y 29-Dec-1977	Registration on : 09-Nov-2024 09:08	Location : Main
Ref. Id : 300596 / 2817538	Collected at : SAWPL	Location : BNo./
Ref. By : Dr. RMO . STERLING...	Collected on : 09-Nov-2024 09:04	Approved on : 09-Nov-2024 11:45 Status : Final
	Sample Type : EDTA blood	Printed On : 09-Nov-2024 16:14
		Process At : 75 – Sterling Hospital, Race course (Vadodara)

**MEDIWHEEL FULL BODY ANNUAL PLUS CHECK/ ADVANCE**
**HbA1c (Glycosylated Hemoglobin) by HPLC**

Test	Result	Unit	Biological Ref. Interval
HbA1c	4.90	%	For Screening: Diabetes: $\geq 6.5\%$ ; Pre-Diabetes: 5.7 - 6.4%; Non-Diabetes: $< 5.7\%$
Mean Blood Glucose	93.93	mg/dL	For Diabetic Patient: Poor Control : $> 7.0\%$ ; Good Control : 6.0-7.0%

**Description:**

- Total haemoglobin A1 c is continuously synthesized in the red blood cell through its 120 days life span. The concentration of HBA1c in the cell reflects the average blood glucose concentration it encounters.
- The level of HBA1c increases proportionately in patients with uncontrolled diabetes. It reflects the average blood glucose concentration over an extended time period and remains unaffected by short-term fluctuations in blood glucose levels.
- The measurement of HbA1c can serve as a convenient test for evaluating the adequacy of diabetic control and in preventing various diabetic complications. Because the average half life of a red blood cell is sixty days, HbA1c has been accepted as a measurement which reflects the mean daily blood glucose concentration, better than fasting blood glucose determination, and the degree of carbohydrate imbalance over the preceding two months.
- It may also provide a better index of control of the diabetic patient without resorting to glucose loading procedures.

**HbA1c assay Interferences:**

Erroneous values might be obtained from samples with abnormally elevated quantities of other Haemoglobins as a result of either their simultaneous elution with HbA1c (HbF) or differences in their glycation from that of HbA (HbS).

**Reference:** American diabetes association. Standards of medical care in diabetes 2024


**Dr. C. Shrinivasan..**

M.D ( Pathology )(G-18341]

Consultant Pathologist

Page 6 of 14

This is an Electronically Authenticated Report.

**Sterling Accuris Pathology Laboratory**

 Sterling Hospital, Opp. Inox Cinema, Race Course Circle (West), Vadodara - 390 007, tests marked with # are referred tests  
 Ph: 0265-6144210

pathlab@sterlinghospitals.com | Website: www.sterlinghospitals.com / www.sterlingaccuris.com



Download Accuris App



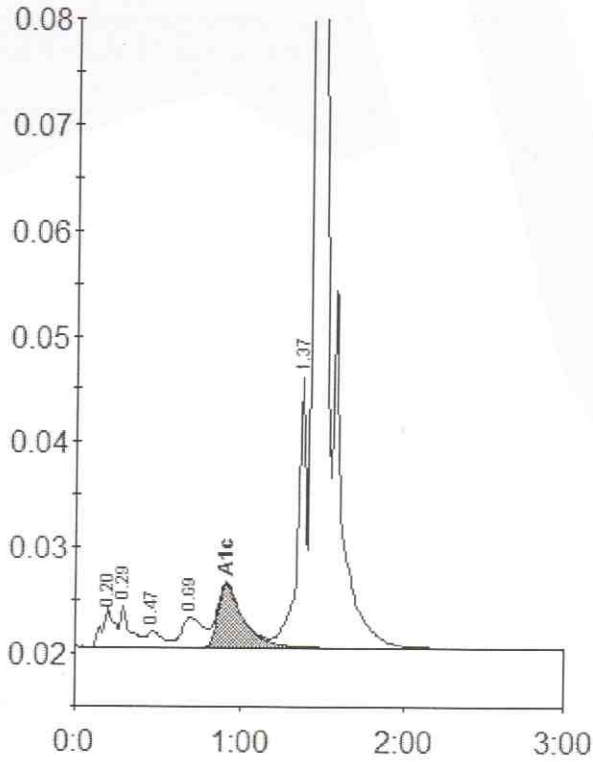


# Patient report

# Sterling HOSPITALS

Bio-Rad DATE: 09/11/2024  
 D-10 TIME: 11:25 AM  
 S/N: #DJ8G550303 Software version: 4.30-2  
 Sample ID: 112407500792  
 Injection date: 09/11/2024 11:25 AM  
 Injection #: 10 Method: HbA1c  
 Rack #: --- Rack position: 10

**sterling**  
**ACCURIS**  
 Pathology lab that cares



Peak table - ID: 112407500792

Peak	R.time	Height	Area	Area %
A1a	0.20	3821	18652	1.1
A1b	0.29	4092	17046	1.0
F	0.47	1529	10449	0.6
LA1c/CHb-1	0.69	2833	25993	1.5
A1c	0.92	5979	63506	4.9
P3	1.37	25779	96741	5.7
A0	1.44	498308	1463355	86.3
Total Area:			1695742	

Concentration:	%
A1c	4.9





Passport No :

**LABORATORY TEST REPORT**


Patient Information	Sample Information	Location Information
Name : Mrs. Anita . Gupta	Lab Id : 112407500792	Pt. Type : Sterling Hospital Vadodara Health Checkup
Sex/Age : Female / 46 Y 29-Dec-1977	Registration on : 09-Nov-2024 09:08	Location : Main
Ref. Id : 300596 / 2817538	Collected at : SAWPL	Location : BNo./
Ref. By : Dr. RMO . STERLING...	Collected on : 09-Nov-2024 09:04	Approved on : 09-Nov-2024 10:36 Status : Final
	Sample Type : Serum	Printed On : 09-Nov-2024 16:14
		Process At : 75 – Sterling Hospital, Race course (Vadodar

**MEDIWHEEL FULL BODY ANNUAL PLUS CHECK/ ADVANCE**
**Lipid Profile**

Test	Result	Unit	Biological Ref. Interval
<b>Cholesterol</b> <i>Cholesterol oxidase – Peroxidase</i>	184.0	mg/dL	Desirable : <200 Borderline High : 200-239 High : >240
<b>Triglyceride</b> <i>Ezymatic (Lipase/GK/GPa/POD)</i>	85.0	mg/dL	Normal : <150 Borderline : 150-199 High : 200-499 Very High : >500
<b>HDL Cholesterol</b> <i>PTA/MgCl2</i>	47.0	mg/dL	Low: <40.0 High: >60.0
<b>Direct LDL</b> <i>Direct measured</i>	H 120.00	mg/dL	Optimal: <100 Near to above Optimal: 100–129 Borderline High: 130-159 High: 160–189 Very High: =190
<b>VLDL</b> <i>Calculated</i>	17.00	mg/dL	15 - 35
<b>CHOL/HDL Ratio</b> <i>Calculated</i>	3.9		Up to 5.0
<b>dLDL/HDL Ratio</b> <i>Calculated</i>	2.6		Up to 3.5


**Dr. C. Shrinivasan..**

 M.D ( Pathology ) [G-18341]  
Consultant Pathologist

Page 8 of 14

**Sterling Accuris Pathology Laboratory**

 Sterling Hospital, Opp. Inox Cinema, Race Course Circle (West), Vadodara - 390 007 tests marked with # are referred tests  
Ph: 0265-6144210

pathlab@sterlinghospitals.com | Website: www.sterlinghospitals.com / www.sterlingaccuris.com

This is an Electronically Authenticated Report.



Download Accuris App





Passport No :

**LABORATORY TEST REPORT**


Patient Information	Sample Information	Location Information
Name : Mrs. Anita . Gupta	Lab Id : 112407500792	Pt. Type : Sterling Hospital Vadodara Health Checkup
Sex/Age : Female / 46 Y 29-Dec-1977	Registration on : 09-Nov-2024 09:08	Location : Main
Ref. Id : 300596 / 2817538	Collected at : SAWPL	Location : BNo./
Ref. By : Dr. RMO . STERLING...	Collected on : 09-Nov-2024 09:04	Approved on : 09-Nov-2024 10:37 Status : Final
	Sample Type : Serum	Printed On : 09-Nov-2024 16:14
		Process At : 75 – Sterling Hospital, Race course (Vadodar

**MEDIWHEEL FULL BODY ANNUAL PLUS CHECK/ ADVANCE**

Test	Result	Unit	Biological Ref. Interval
<b>Uric Acid</b> <i>Uricase</i>	4.70	mg/dL	2.5 - 6.2
<b>Blood Urea Nitrogen</b> <i>Calculated</i>	11.21	mg/dL	7.0 - 17.0
<b>Urea</b> <i>Urease, Colorimetric</i>	24.0	mg/dL	15.0 - 36.4
<b>Creatinine, serum</b> <i>Creatinine Amidohydrolase</i>	0.70	mg/dL	0.52 - 1.04
<b>BUN Creatinine Ratio</b> <i>Calculated</i>	16.01		
<b>Urea Creatinine Ratio</b> <i>Calculated</i>	34.29		


**Dr. C. Shrinivasan..**

 M.D ( Pathology )[G-18341]  
 Consultant Pathologist

Page 9 of 14

**Sterling Accuris Pathology Laboratory**

Sterling Hospital, Opp. Inox Cinema, Race Course Circle (West), Vadodara - 390 007 tests marked with # are referred tests

Ph: 0265-6144210

pathlab@sterlinghospitals.com | Website: www.sterlinghospitals.com / www.sterlingaccuris.com

This is an Electronically Authenticated Report.



Download Accuris App





Passport No :

**LABORATORY TEST REPORT**


Patient Information		Sample Information		Location Information	
Name	: Mrs. Anita . Gupta	Lab Id	: 112407500792	Pt. Type	: Sterling Hospital Vadodara Health Checkup Main
Sex/Age	: Female / 46 Y 29-Dec-1977	Registration on	: 09-Nov-2024 09:08	Location	: BNo./
Ref. Id	: 300596 / 2817538	Collected at	: SAWPL	Approved on	: 09-Nov-2024 10:39 Status : Final
Ref. By	: Dr. RMO . STERLING...	Collected on	: 09-Nov-2024 09:04	Printed On	: 09-Nov-2024 16:14
		Sample Type	: Serum	Process At	: 75 - Sterling Hospital, Race course (Vadodar

**MEDIWHEEL FULL BODY ANNUAL PLUS CHECK/ ADVANCE**
**Liver Function Test**

Test	Result	Unit	Biological Ref. Interval
<b>ALT (SGPT)</b> <i>UV with P5P, IFCC</i>	17.0	U/L	0 - 35
<b>AST (SGOT)</b> <i>UV with P5P</i>	34.0	U/L	14 - 36
<b>GGT (Gamma Glutamyl Transferase)</b> <i>L-y-Glytamyl-p-nitroanilide</i>	13.0	U/L	12 - 43
<b>Alkaline Phosphatase</b> <i>PNPP, AMP Buffer, IFCC</i>	94.0	U/L	38 - 126
<b>Total Bilirubin</b> <i>Azobilirubin chromophores</i>	0.40	mg/dL	0.2 - 1.3
<b>Conjugated Bilirubin</b> <i>Cationic Mordant Binding</i>	0.10	mg/dL	0.0 - 0.3
<b>Unconjugated Bilirubin</b> <i>Cationic Mordant Binding</i>	0.10	mg/dL	0.0 - 1.1
<b>Delta Bilirubin</b> <i>Calculated</i>	0.20	mg/dL	0.0 - 0.2
<b>Total Protein</b> <i>Copper tartrate to colour complex</i>	6.30	g/dL	6.3 - 8.2
<b>Albumin</b> <i>Bromocresol Green Method</i>	3.80	g/dL	3.5 - 5.0
<b>Globulin</b> <i>Calculated</i>	2.50	g/dL	2.3 - 3.5
<b>A/G Ratio</b> <i>Calculated</i>	1.52		1.3 - 1.7


**Dr. C. Shrinivasan..**

 M.D ( Pathology )(G-18341]  
Consultant Pathologist

Page 10 of 14

This is an Electronically Authenticated Report.

**Sterling Accuris Pathology Laboratory**

Sterling Hospital, Opp. Inox Cinema, Race Course Circle (West), Vadodara - 390 007 tests marked with # are referred tests

Ph: 0265-6144210

pathlab@sterlinghospitals.com | Website: www.sterlinghospitals.com / www.sterlingaccuris.com



Download Accuris App





Passport No :

**LABORATORY TEST REPORT**


Patient Information		Sample Information		Location Information	
Name	: Mrs. Anita . Gupta	Lab Id	: 112407500792	Pt. Type	: Sterling Hospital Vadodara Health Checkup
Sex/Age	: Female / 46 Y 29-Dec-1977	Registration on	: 09-Nov-2024 09:08	Location	: Main BNo./
Ref. Id	: 300596 / 2817538	Collected at	: SAWPL	Approved on	: 09-Nov-2024 11:20 Status : Final
Ref. By	: Dr. RMO . STERLING...	Collected on	: 09-Nov-2024 09:04	Printed On	: 09-Nov-2024 16:14
		Sample Type	: Serum	Process At	: 75 – Sterling Hospital, Race course (Vadodar

**MEDIWHEEL FULL BODY ANNUAL PLUS CHECK/ ADVANCE**
**Thyroid Function Tests**

Test	Result	Unit	Biological Ref. Interval
T3, total (Triiodothyronine) <i>CLIA</i>	1.23	ng/mL	0.58 - 1.59
T4, total (Thyroxine) <i>CLIA</i>	6.35	µg/dl	4.87 - 11.72
TSH (3rd Gen.) <i>Chemiluminescence</i>	3.0290	µIU/mL	Non-Pregnant Woman: 0.4001-4.049; Pregnant Woman: 1st Trimester: 0.1298-3.120; 2nd Trimester: 0.2749-2.652; 3rd Trimester : 0.3127-2.947

Remarks: \* On Rx.


**Dr. C. Shrinivasan..**

 M.D ( Pathology )[G-18341]  
Consultant Pathologist

Page 11 of 14

This is an Electronically Authenticated Report.

**Sterling Accuris Pathology Laboratory**

Sterling Hospital, Opp. Inox Cinema, Race Course Circle (West), Vadodara - 390 007 tests marked with # are referred tests

Ph: 0265-6144210

 pathlab@sterlinghospitals.com |  Website: www.sterlinghospitals.com / www.sterlingaccuris.com


Download Accuris App



Passport No :

**LABORATORY TEST REPORT**


Patient Information		Sample Information		Location Information	
Name	: Mrs. Anita . Gupta	Lab Id	: 112407500792	Pt. Type	: Sterling Hospital Vadodara Health Checkup
Sex/Age	: Female / 46 Y 29-Dec-1977	Registration on	: 09-Nov-2024 09:08	Location	: Main BNo./
Ref. Id	: 300596 / 2817538	Collected at	: SAWPL	Approved on	: 09-Nov-2024 11:20 Status : Final
Ref. By	: Dr. RMO . STERLING...	Collected on	: 09-Nov-2024 09:04	Printed On	: 09-Nov-2024 16:14
		Sample Type	: Serum	Process At	: 75 – Sterling Hospital, Race course (Vadodar

**MEDIWHEEL FULL BODY ANNUAL PLUS CHECK/ ADVANCE**

Levels of TSH in pregnancy ( $\mu\text{IU/mL}$ ): First Trimester 0.1 - 2.5; Second Trimester 0.2 – 3.0; Third Trimester 0.3 – 3.0.

**NOTE:** TSH concentrations in apparently normal euthyroid subjects are known to be highly skewed, with a strong tailed distribution towards higher TSH values. This is well documented in the pediatric population including the infant age group.

TSH	T3/FT3	T4/FT4	Suggested interpretation of Thyroid function tests pattern
Within range	Decreased	Within range	Isolated low T3 often seen in elderly & associated Non-Thyroid illness. In elderly the drop in T3 level can be up to 25%.
Raised	Within Range	Within Range	Isolated High TSH Especially in the range of 4.7 to 15 mIU/ml is commonly associated with physiological & Biological TSH Variability; Subclinical Autoimmune Hypothyroidism; Intermediate T4 therapy for hypothyroidism; Recovery phase after Non-Thyroidal illness.
Raised	Decreased	Decreased	Chronic Autoimmune Thyroiditis; Post thyroidectomy, post radioiodine; Hypothyroid phase of transient thyroiditis.
Raised or within range	Raised	Raised or within range	Interfering antibodies to thyroid hormones (anti-TPO antibodies); Intermediate T4 therapy of T4 overdose; Drug Interference-Amiodarone, Heparin, Beta blocker, steroids, anti-epileptics.
Decreased	Raised or within range	Raised or within range	Isolated Low TSH – Especially in the range of 0.1 to 0.4 often seen in elderly & associated with Non-Thyroidal illness; Subclinical Hyperthyroidism; Thyroxine ingestion.
Decreased	Decreased	Decreased	Central Hypothyroidism; Non-Thyroidal illness; Recent treatment for Hypothyroidism (TSH remains suppressed).
Decreased	Raised	Raised	Primary Hyperthyroidism (Graves' disease), Multinodular goitre Toxic nodule; Transient thyroiditis: postpartum, Silent (lymphocytic), Post viral (granulomatous, subacute, DeQuervain'a) Gestational thyrotoxicosis hyperemesis gravidarum.
Decreased or within range	Raised	Within range	T3 toxicosis; Non-Thyroidal illness.

Reference: Wallach's Interpretation of Diagnostic by Mary Williamson, 10th edition, 2015.


  
Dr. C. Shrinivasan..

 M.D ( Pathology )(G-18341)  
Consultant Pathologist

Page 12 of 14

This is an Electronically Authenticated Report.

**Sterling Accuris Pathology Laboratory**

 Sterling Hospital, Opp. Inox Cinema, Race Course Circle (West), Vadodara - 390 007; tests marked with # are referred tests  
Ph: 0265-6144210

pathlab@sterlinghospitals.com | Website: www.sterlinghospitals.com / www.sterlingaccuris.com



Download Accuris App





Passport No :

**LABORATORY TEST REPORT**


Patient Information		Sample Information		Location Information	
Name	: Mrs. Anita . Gupta	Lab Id	: 112407500792	Pt. Type	: Sterling Hospital Vadodara Health Checkup
Sex/Age	: Female / 46 Y 29-Dec-1977	Registration on	: 09-Nov-2024 09:08	Location	: Main BNo./
Ref. Id	: 300596 / 2817538	Collected at	: SAWPL	Approved on	: 09-Nov-2024 10:57 Status: Final
Ref. By	: Dr. RMO . STERLING...	Collected on	: 09-Nov-2024 09:04	Printed On	: 09-Nov-2024 16:14
		Sample Type	: Urine	Process At	: 75 - Sterling Hospital, Race course (Vadodar

**MEDIWHEEL FULL BODY ANNUAL PLUS CHECK/ ADVANCE**
**URINE ROUTINE EXAMINATION**

Test	Result	Unit	Biological Ref. Interval
<b>Physical &amp; Chemical (Dip strip) examination</b>			
Colour	Pale Yellow		Pale Yellow
pH <i>Double indicator</i>	5.5		5.5 - 7.0
Specific Gravity <i>Polyelectrolyte based reaction</i>	1.020		1.015 - 1.025
Protein <i>Protein error of indicators</i>	Absent		Absent
Glucose <i>GOD-POD</i>	Absent		Absent
Ketone <i>Nitroprusside</i>	Absent		Absent
Blood <i>Peroxidase like reaction</i>	Absent		Absent
Bilirubin <i>Diazo reaction</i>	Absent		Absent
Leucocytes <i>Esterase reaction</i>	Absent		Absent
Nitrite <i>p-arsanilic acid to diazonium compound</i>	Absent		Absent
<b>Microscopic Examination</b>			
Erythrocytes (RBCs)	Absent	/hpf	0 - 2
Pus Cells	1-2	/hpf	0 - 5
Epithelial Cells	Scanty	/hpf	
Crystals	Absent		Absent
Casts	Absent		Absent
Bacteria	Absent		Absent
Amorphous Material	Absent		Absent
Yeast	Absent		Absent


**Dr. C. Shrinivasan..**

 M.D ( Pathology ) [G-18341]  
Consultant Pathologist

Page 13 of 14

This is an Electronically Authenticated Report.

**Sterling Accuris Pathology Laboratory**

 Sterling Hospital, Opp. Inox Cinema, Race Course Circle (West), Vadodara - 390 007 tests marked with # are referred tests  
Ph: 0265-6144210

pathlab@sterlinghospitals.com | Website: www.sterlinghospitals.com / www.sterlingaccuris.com



Download Accuris App





Scan to check report authenticity

Histo / Cyto No : **C4000810**

### LABORATORY REPORT



Patient Information		Sample Information		Client / Location Information	
Name	: Mrs. Anita . Gupta	Lab ID	: 112407500792	Client Name	: Sterling Hospital Vadodara Health Checkup Main
Sex/Age	: Female /46 Years	Registered on	: 09-Nov-2024 09:08	Location	:
Ref. Id	:	Collected at	: non SAWPL	Approved on	: 09-Nov-2024 14:46
Ref. By	: Dr. RMO . STERLING...	Collected on	: 09-Nov-2024 13:00	Printed on	: 09-Nov-2024 16:14
		Sample Type	: PAP Material	Processed at	: 17 – Sterling Hospital, Bhayli (Vadodara)
Branch	: 75 – Sterling Hospital, Race course (Vadodara)				

### CYTOPATHOLOGY

\* **PAP Smear No. :**

P - 590/24

\* **Obstetric History :**

G4 P2 A2 L2

\* **Menstrual History :**

LMP : 26/10/24

\* **Per-Speculum Examination :**

NAD

\* **Per-Vaginal Examination :**

NAD

\* **Specimen Adequacy :**

Satisfactory for evaluation : Endocervical and Transformation Zone Absent.


\* :

NEGATIVE FOR INTRAEPITHELIAL LESION OR MALIGNANCY.

\* :

Moderate Acute Inflammation.

----- End Of Report -----



**Dr. Swati Gupta**

MD (Path) DipRCPath

This is an electronically authenticated report.

tests marked with # are referred tests

Page 14 of 14



**Sterling Accuris Pathology Laboratory**

Sterling Hospital, Opp. Inox Cinema, Race Course Circle (West), Vadodara - 390 007,

Ph: 0265-6144210

pathlab@sterlinghospitals.com | Website: www.sterlinghospitals.com / www.sterlingaccuris.com



Download Accuris App



Patient Id	: RCR-300596	Patient Name	: GUPTA ANITA .
Age	: 46Y 10M 11D	Sex	: Female
Ref. Doctor	: DR. RMO . STERLING	Study Date	: 09 Nov 2024 - 09:55 AM

**X-RAY CHEST PA VIEW**

Poor inspiratory efforts.  
Both lung fields show prominent broncho-vascular markings.  
Cardiac size appears within upper normal limit.  
Trachea and mediastinal soft tissue shadow appear unremarkable.  
Lateral C.P. angles and both domes of diaphragm appear normal.  
Bony thorax under vision appears normal.

**CONCLUSION:**

**No significant chest abnormality detected.**

**Dr. Shilpi Gupta MD**  
**Sr. Consultant Radiologist**

**Hospital Address:** Sterling Hospitals, Race Course Road, Opp. Inox Cinema Hari Nagar, Circle West, Vadodara – 390007, Gujarat, India | Call: 0265-6144111, 0265-2354455, 98 98 98 78 78  
www.sterlinghospitals.com | info@sterlinghospitals.com

**Registered Office:** Sterling Addlife India Private Limited | CIN U85110GJ2000PTC039121  
Sterling Hospital, Sterling Hospital Road, Memnagar, Ahmedabad-380052, Gujarat, India



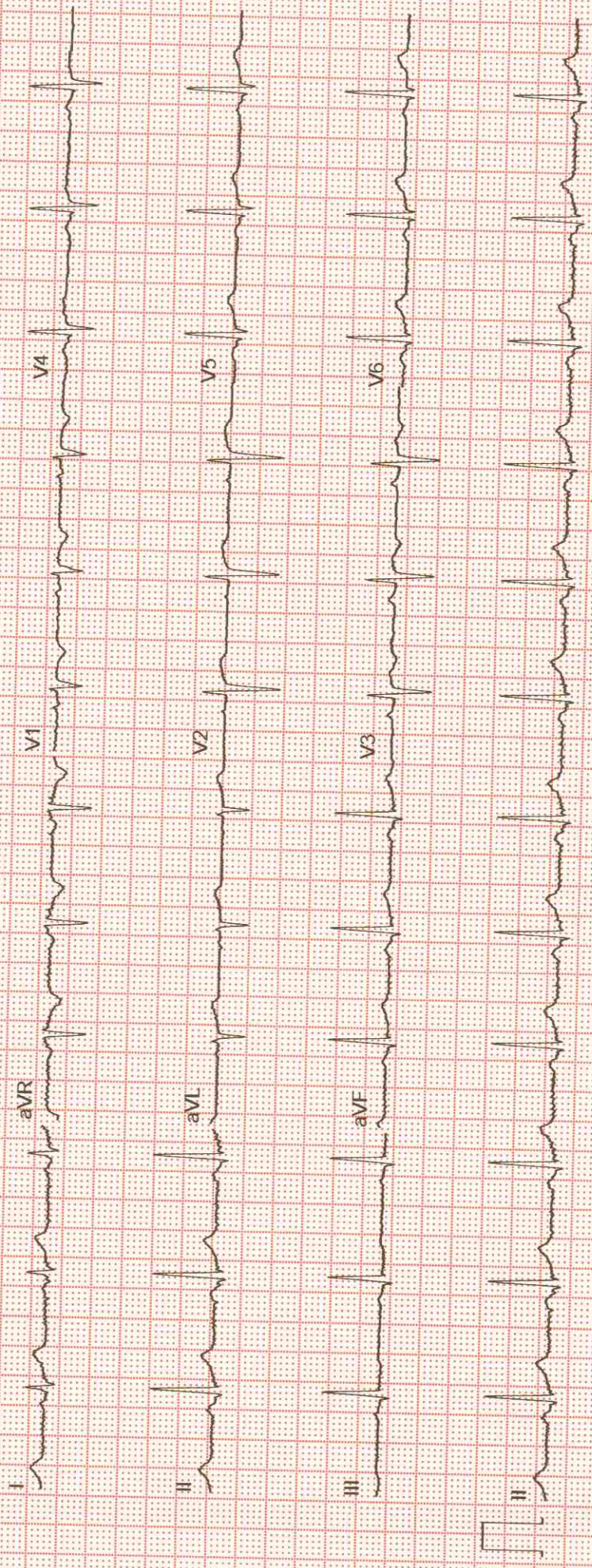
09.11.2024 9:51:43  
STERLING HR VITAL  
HCP  
VADODARA

75 bpm  
- / - mmHg

TT V3  
ST axis

46 Years  
Female

QRS	78 ms
QT / QTcBaz	360 / 402 ms
PR	138 ms
P	100 ms
RR / PP	798 / 800 ms
P / QRS / T	54 / 79 / 41 degrees





# 2D ECHOCARDIOGRAPHY REPORT



Race Course Road, Vadodara

Name: Mrs. ANITA GUPTA  
Age: 46 Years  
Sex: F  
Date: 09-Nov-2024

Ref By: HCP  
Study: 2D Echo

### M-MODE:

IVS	10mm	LVDD	46mm
PW	11mm	LVDS	24mm
LA	37mm	LV EF	55-60 %

### DOPPLER STUDY:

MITRAL	E 0.94 A 0.64
AORTIC	1.20
TRICUSPID	N
PULMONARY	N

### CONCLUSION :

- NORMAL SIZED CHAMBERS
- NORMAL LV SYSTOLIC FUNCTION LVEF 55-60 %
- NO RWMA AT REST
- NORMAL RV SIZE AND FUNCTION
- NO DIASTOLIC DYSFUNCTION
- ALL VALVES ARE NORMAL
- NO CLOT OR VEGETATION
- NO PERICARDIAL EFFUSION
- NORMAL IVC

**Dr. KAUSHIK TRIVEDI MD**  
Consultant interventional Cardiologist

Hospital Address: Sterling Hospitals, Race Course Road, Opp. Inox Cinema Hari Nagar, Circle West, Vadodara – 390007, Gujarat, India | Call: 0265-6144111, 0265-2354455, 98 98 98 78 78  
www.sterlinghospitals.com | info@sterlinghospitals.com

Registered Office: Sterling Addlife India Private Limited | CIN U85110GJ2000PTC039121  
Sterling Hospital, Sterling Hospital Road, Memnagar, Ahmedabad-380052, Gujarat, India

SonoDoc 91-20-25443913







Report Date: 09 Nov 2024 - 02:09 PM

Patient Id	: RCR-300596	Patient Name	: GUPTA ANITA .
Age	: 46Y 10M 11D	Sex	: Female
Ref. Doctor	: DR. RMO . STERLING	Study Date	: 09 Nov 2024 - 12:38 PM

**BILATERAL MAMMOGRAM: -**

Technique: Dedicated low dose film screen mammography with cranio-caudal and medio-lateral view was performed.  
Clinical profile: **Routine check-up,**

**REPORT**

The mammary parenchyma is inhomogeneously dense in at retro-periareolar and lateral aspect of both the breasts because of prominent fibro-glandular tissues. This somewhat lowers the sensitivity of mammography.

No suspicious focal mass or clustered micro calcifications are seen, although the dense surrounding tissue could obscure a lesion. No evidence of skin thickening or nipple retraction noted on either side.

No evidence of enlarged pathological lymph nodes seen on either side.

**COMMENTS:**

- **Mammographically dense mammary parenchyma in at retro-periareolar and lateral aspect of both the breasts - because of prominent fibro-glandular tissues (BIRADS 0).**
- **No secondary mammographic signs of malignancy.**
- Adv: Clinical & SOS sonomammography correlation.

The false negative mammography is approximately 10%. Management of a palpable abnormality must be based upon clinical grounds. **Sensitivity of mammography limited without sonography. Sonography is recommended if strong clinical suspicion is there.**

**Dr. Shilpi Gupta MD**  
**Sr. Consultant Radiologist**

**Hospital Address:** Sterling Hospitals, Race Course Road, Opp. Inox Cinema Hari Nagar, Circle West, Vadodara – 390007, Gujarat, India | Call: 0265-6144111, 0265-2354455, 98 98 98 78 78  
www.sterlinghospitals.com | info@sterlinghospitals.com

**Registered Office:** Sterling Addlife India Private Limited | CIN U85110GJ2000PTC039121  
Sterling Hospital, Sterling Hospital Road, Memnagar, Ahmedabad-380052, Gujarat, India





Patient Id	: RCR-300596	Patient Name	: GUPTA ANITA .
Age	: 46Y 10M 11D	Sex	: Female
Ref. Doctor	: DR.RMO.STERLING	Study Date	: 09 Nov 2024 - 11:36 AM

**SONOGRAPHY OF WHOLE ABDOMEN: -**

**LIVER:** Liver appears normal in size and shows normal parenchymal echoes. No evidence of focal or diffuse lesion is seen. No evidence of dilated IHBR is seen. Intrahepatic portal radicals appear normal. Portal vein is normal in caliber at porta & shows hepatopetal blood flow.

**GALL BLADDER:** Gall bladder is distended and appears normal. No evidence of calculus or changes of cholecystitis are seen. CBD appears normal (4.1 mm).

**PANCREAS:** Pancreas is partially visualized and visualized portion is normal in size & shows normal parenchymal echoes.

**SPLEEN:** Spleen is normal in size & shows normal parenchymal echoes. No evidence of focal or diffuse lesion is seen.

**BOTH KIDNEYS:** Both kidneys are normal in size, shape, position and contour. Cortical thickness & echo appear normal. No evidence of renal calculus, hydronephrosis or mass lesion is seen on either side.

Right kidney measures 10.0 x 4.0 cm

Left kidney measures 10.0 x 4.9 cm

No evidence of suprarenal mass lesion is seen on either side.

**URINARY BLADDER:** Bladder is adequately distended and appears unremarkable.

**UTERUS:** Uterus is anteverted & appears mild bulky in size (10.4 x 5.6 x 5.1 cm). Uterine myometrium is mild coarse in echotexture. A well defined iso/hyperechoic lesion is seen in anterior fundal myometrium measuring approx. 3.3 x 2.5 cm in size likely focal adenomyoma/ uterine lipoleiomyoma. Endometrial and rest of myometrial echoes appear normal. Endometrial thickness measures about 8.9 mm. No evidence of intrauterine pregnancy is seen.

**OVARIES:** Both ovaries appear normal in size, shape and position. No evidence of solid or cystic ovarian mass lesion is seen on either side.

No evidence of ascites, lymphadenopathy is seen.

Mild gaseous distention of bowel loops is seen.

**CONCLUSION:**

- Mild bulky uterus with early changes of adenomyosis.
- A well defined iso/hyperechoic lesion in anterior fundal myometrium likely focal adenomyoma/ uterine lipoleiomyoma. Adv: SOS TVS pelvis.
- No other significant abnormality detected.

**Hospital Address:** Sterling Hospitals, Race Course Road, Opp. Inox Cinema Hari Nagar, Circle West, Vadodara - 390007, Gujarat, India | Call: 0265-6144111, 0265-2354455, 98 98 98 78 78  
www.sterlinghospitals.com | info@sterlinghospitals.com

**Registered Office:** Sterling Addlife India Private Limited | CIN U85110GJ2000PTC039121  
Sterling Hospital, Sterling Hospital Road, Memnagar, Ahmedabad-380052, Gujarat, India





Report Date: 09 Nov 2024 - 12:11 PM

Patient Id	: RCR-300596	Patient Name	: GUPTA ANITA .
Age	: 46Y 10M 11D	Sex	: Female
Ref. Doctor	: DR.RMO.STERLING	Study Date	: 09 Nov 2024 - 11:36 AM

**Dr. Shilpi Gupta MD**  
Consultant Radiologist

**Hospital Address:** Sterling Hospitals, Race Course Road, Opp. Inox Cinema Hari Nagar, Circle West, Vadodara – 390007, Gujarat, India | Call: 0265-6144111, 0265-2354455, 98 98 98 78 78  
www.sterlinghospitals.com | info@sterlinghospitals.com

**Registered Office:** Sterling Addlife India Private Limited | CIN U85110GJ2000PTC039121  
Sterling Hospital, Sterling Hospital Road, Memnagar, Ahmedabad-380052, Gujarat, India

