




YASHFEEN CARDIAC HOSPITAL™

At. & Po. Viraval, Navsari. 396 445. Phone (H) (02637) 235725

Website : www.yashfeenhospital.in E-mail : info@yashfeenhospital.in
(For Laboratory Reports Only)



Patient Name : ROHANKUMAR NAVNITLAL PATEL Age : 37 Years Sex : M
Ref By Dr. : - Area : Talodh Date : 08/03/2025
Sample Time : 08/03/2025 08:38 No : 8 Time : 12:03PM

HAEMOGRAM

Test	Findings	UOM	Normal Range
HAEMOGLOBIN	13.8	g/dl	M-13.5-17.0 gm/dl F-11.5-15.5 gm/dl
HAEMOGRAM			
RED BLOOD CELL	6.01	10 ⁶ /μL	3.76-5.70
TOTAL LEUCOCYTE COUNT	6400	10 ³ /μL	4,000-11,000cells/cumm
Differential Count			
Neutrophil	59	%	40-75 %
Lymphocytes	34	%	20-40 %
Eosinophil	1	%	01-06 %
Monocytes	6	%	02-10 %
Basophils	0	%	00-00 %
PLATELET COUNT	351000	10 ³ /μL	1.5-5.5 Lacs/cumm
RBC INDICES			
P.C.V.	43.7	%	Male-40-56%, Female-37-47%
M.C.V.	72.7	fL	76.0-94.0
M.C.H.	23.0	pg	27.0-30.0
M.C.H.C.	31.6	g/dl	30.0-35.0
BLOOD GROUP	"O"	-	-
RH FACTOR	POSITIVE	-	-
E.S.R.(1 hour)		mm/hr.	Male-5-10 mm/hr, Female-5-20 mm/hr

Remarks

Designed By : Sarita Infotech Pvt. Ltd., Navsari

Yashfeen Cardiac Hospital

Reg. No. G-21518

Thanks for Reference

Dr. P. V. CHAUDHARI
M.D. Medicine
Signature
Technician





YASHFEEN CARDIAC HOSPITAL™

At. & Po. Viraval, Navsari. 396 445. Phone (H) (02637) 235725

Website : www.yashfeenhospital.in E-mail : info@yashfeenhospital.in
(For Laboratory Reports Only)



Patient Name : ROHANKUMAR NAVNITLAL PATEL
Ref By Dr. : -
Sample Time : 08/03/2025 08:39 No : 8

Age : 37 Years Sex : M
Area : Talodh Date : 08/03/2025
Time : 12:05PM

BLOOD SUGAR TEST REPORT

Test	Findings	UOM	Normal Range
FASTING BLOOD SUGAR	108.4	mg/dL	70-110 mg/dL
FASTING URINE SUGAR	NIL	-	NIL
POSTPANDRIAL BLOOD SUGAR	114.0	mg/dL	70-140 mg/dL
POSTPANDRIAL URINE SUGAR	NIL	-	NIL



Dr. Piyush B. Chaudhari
M.D. Medicine
Reg. No. G - 21518

Remarks

Designed By : Sarita Infotech Pvt. Ltd., Navsari

Yashfeen Cardiac Hospital

Reta
Signature
Technician

Thanks for Reference



YASHFEEN CARDIAC HOSPITAL™

At. & Po. Viraval, Navsari. 396 445. Phone (H) (02637) 235725

Website : www.yashfeenhospital.in E-mail : info@yashfeenhospital.in
(For Laboratory Reports Only)



Patient Name : ROHANKUMAR NAVNITLAL PATEL
Ref By Dr. : -
Sample Time : 08/03/2025 08:39 No : 8

Age : 37 Years Sex : M
Area : Talodh Date : 08/03/2025
Time : 12:05PM

LIPID PROFILE TEST REPORT

Test	Findings	UOM	Normal Range
S.CHOLESTEROL	161.7	mg/dL	<200:Desirable, 200-239:Borderline High, >=240:High
HDL CHOLESTEROL	38.4	mg/dL	<40:Low(High Risk), >=60:High(Low Risk)
LDL CHOLESTEROL	126.6	mg/dL	<100.0: Optimal, 100.0-129.0: Nearoptimal/ Aboveoptimal, 130.0-159.0:Borderline High, 160.0-189.0:High, >=190.0:Very High
VLDL CHOLESTEROL	16.3	mg/dL	Upto 40.0 mg/dL
S.TRIGLYCERIDES	81.5	mg/dL	<150.0:Normal, 150.0-199.0:Borderline high, 200.0-499.0:High, >=500.0:Very High
CHOL/ HDL RATIO	4.2	mg/dL	LESS THAN 5.0
LDL/ HDL RATIO	3.3	mg/dL	LESS THAN 5.0



Dr. PIYUSH B. CHAUDHARI
M.D. Medicine
Reg. No. G - 21516

Remarks

Designed By : Sarita Infotech Pvt. Ltd., Navsari

Yashfeen Cardiac Hospital

Thanks for Reference

[Signature]
Signature
Technician



YASHFEEN CARDIAC HOSPITAL™

At. & Po. Viraval, Navsari. 396 445. Phone (H) (02637) 235725

Website : www.yashfeenhospital.in E-mail : info@yashfeenhospital.in
(For Laboratory Reports Only)



Patient Name : ROHANKUMAR NAVNITLAL PATEL Age : 37 Years Sex : M
Ref By Dr. : - Area : Talodh Date : 08/03/2025
Sample Time : 08/03/2025 08:39 No : 8 Time : 12:05PM

LIVER FUNCTION TEST REPORT

Test	Findings	UOM	Normal Range
TOTAL BILIRUBIN	0.5	mg/dL	0-1.0 mg/dL
DIRECT BILIRUBIN	0.2	mg/dL	0-0.8 mg/dL
INDIRECT BILIRUBIN	0.3	mg/dL	0-0.2 mg/dL
SGPT	19.9	U/L	Below 40.0 U/L
S.ALKALINE PHOSPHATASE	83.5	U/L	Child-170.0-515.0 U/L, Adults-37.0-147.0 U/L
TOTAL PROTEIN	7.1	g/dl	6.0-8.0 g/dl
ALBUMIN	4.4	g/dl	3.0-5.0 g/dl
GLOBULIN	2.7	g/dl	3.0-3.5 g/dl
A/G	1.6	g/dl	
SGOT	14.7	U/L	Below 40.0 U/L



P. Chaudhari
Dr. PIYUSH B. CHAUDHARI
M.D. Medicine
Reg. No. G - 21518

Remarks

Designed By : Sarita Infotech Pvt. Ltd., Navsari

Yashfeen Cardiac Hospital

Thanks for Reference

Sarita
Signature
Technician



YASHFEEN CARDIAC HOSPITAL™

At. & Po. Viraval, Navsari. 396 445. Phone (H) (02637) 235725

Website : www.yashfeenhospital.in E-mail : info@yashfeenhospital.in
(For Laboratory Reports Only)



Patient Name : ROHANKUMAR NAVNITLAL PATEL Age : 37 Years Sex : M
Ref By Dr. : - Area : Talodh Date : 08/03/2025
Sample Time : 08/03/2025 08:39 No : 8 Time : 12:06PM

GGT TEST REPORT

Test	Findings	UOM	Normal Range
SERUM GGT	42.0	U/L	10.0-71.0 U/L



P. Chaudhari
Dr. PIYUSH B. CHAUDHARI
M.D. Medicine
Reg.No. G-21518

Remarks

Designed By : Sarita Infotech Pvt. Ltd., Navsari

Yashfeen Cardiac Hospital

Thanks for Reference


[Signature]
Signature
Technician



YASHFEEN CARDIAC HOSPITAL™

At. & Po. Viraval, Navsari. 396 445. Phone (H) (02637) 235725

Website : www.yashfeenhospital.in E-mail : info@yashfeenhospital.in
(For Laboratory Reports Only)



Patient Name : ROHANKUMAR NAVNITLAL PATEL
Ref By Dr. : -
Sample Time : 08/03/2025 08:39 No : 8

Age : 37 Years Sex : M
Area : Talodh Date : 08/03/2025
Time : 12:06PM

BIOCHEMICAL TEST REPORT

Test	Findings	UOM	Normal Range
S.CREATININE	0.9	mg/dL	Male-0.9-1.4 mg/dL, Female-0.8-1.2 mg/dL
S.URIC ACID	4.7	mg/dL	Male:3.5-7.2 mg/dL, Female:2.6-6.0 mg/dL
BLOOD UREA NITROGEN	11.8	mg/dL	4.7-23.0 mg/dL



P. Chaudhari
Dr. Piyush B. CHAUDHARI
M.D. Medicine
Reg.No. G - 21518

Remarks

Designed By : Sarita Infotech Pvt. Ltd., Navsari

Yashfeen Cardiac Hospital

Thanks for Reference

Sarita
Signature
Technician



YASHFEEN CARDIAC HOSPITAL™

At. & Po. Viraval, Navsari. 396 445. Phone (H) (02637) 235725

Website : www.yashfeenhospital.in E-mail : info@yashfeenhospital.in
(For Laboratory Reports Only)



Patient Name : ROHANKUMAR NAVNITLAL PATEL
Ref By Dr. : -
Sample Time : 08/03/2025 08:40 No : 8

Age : 37 Years Sex : M
Area : Talodh Date : 08/03/2025
Time : 12:06PM

THYROID FUNCTION TEST REPORT

Test	Findings	UOM	Normal Range
T3 (TRIODOXYTHYRONINE)	1.21	ng/ml	Newborns:0.73-2.88, 6 Days-3 Months:0.80-2.75, 4-12Months:0.86-2.65, 1-6 Years:0.92-2.48, 7-11 Years:0.93-2.31, 12-20Years:0.91-2.18, Adults:0.80-2.00
T4 (THYROXINE)	7.71	µg/dl	Newborns:5.04-18.5, 6 Days-3 Months:5.41-17.0, 4-12 Months:5.67-16.0, 1-6 Years:5.95-14.7, 7-11 Years:5.99-13.8, 12-20 Years:5.91-13.2, Adults:5.10-14.1
TSH	6.01	µIU/ml	Newborns:0.70-15.2, 6 Days-3 Months:0.72-11.0, 4-12 Months:0.73-8.35, 1-6 Years:0.70-5.97, 7-11 Years:0.60-4.84, 12-20 Years:0.51-4.30, Adults:0.27-4.20

TECHNIQUE

ELECTROCHEMILUMINESCEN
CE



Dr. Piyush B. Chaudhari
M.D. Medicine
Reg. No. G - 21513

Remarks

Designed By : Sarita Infotech Pvt. Ltd., Navsari

Yashfeen Cardiac Hospital

Thanks for Reference

[Signature]
Signature
Technician



YASHFEEN CARDIAC HOSPITAL™

At. & Po. Viraval, Navsari. 396 445. Phone (H) (02637) 235725

Website : www.yashfeenhospital.in E-mail : info@yashfeenhospital.in
(For Laboratory Reports Only)



Patient Name : ROHANKUMAR NAVNITLAL PATEL
Ref By Dr. : -
Sample Time : 08/03/2025 08:41 No : 8

Age : 37 Years Sex : M
Area : Talodh Date : 08/03/2025
Time : 12:06PM

HAEMOGLOBIN A1 C ESTIMATION

Test	Findings	UOM	Normal Range
Hb A1C	5.0	%	>8 :Action Suggested, 7-8 :Good Control, <7 :Goal, 6-7 :Near Normal Glycemia, <6 :Non-diabetic Level
Technique METHOD - HPLC		-	
Mean Blood Glucose	96.2	mg/dL	



P. Chaudhari
Dr. RIYUSH B. CHAUDHARI
M.D. Medicine
Reg.No. G - 21578

Remarks

Designed By : Sarita Infotech Pvt. Ltd., Navsari

Yashfeen Cardiac Hospital

Thanks for Reference

[Signature]
Signature
Technician



YASHFEEN CARDIAC HOSPITAL™

At. & Po. Viraval, Navsari. 396 445. Phone (H) (02637) 235725

Website : www.yashfeenhospital.in E-mail : info@yashfeenhospital.in
(For Laboratory Reports Only)



Patient Name : ROHANKUMAR NAVNITLAL PATEL
Ref By Dr. : -
Sample Time : 08/03/2025 08:41 No : 8

Age : 37 Years Sex : M
Area : Talodh Date : 08/03/2025
Time : 12:29PM

ROUTINE URINE ANALYSIS

Test	Findings	UOM	Normal Range
PHYSICAL EXAMINATION			
Quantity	-	-	-
Colour	YELLOW	-	-
Appearance	CLEAR	-	-
Reaction	ACIDIC	-	-
Sp. Gravity	1.023	-	-
CHEMICAL EXAMINATION			
U.Albumin	NIL	-	-
Sugar	NIL	-	-
Acetone	NIL	-	-
Bile Salt	NIL	-	-
Bile Pigment	NIL	-	-
Occult Blood	NIL	-	-
MICROSCOPIC EXAMINATION			
Pus Cells	2-3	/hpf	-
Epithelial cells	1-2	/hpf	-
Red cells	ABSENT	/hpf	-
Casts	-	/hpf	-
Crystals	AMORPHOUS SEEN	/hpf	-
Others	-	/hpf	-



Dr. *Piyush B. Chaudhari*
Dr. PIYUSH B. CHAUDHARI
M.D. Medicine
Reg.No. G-21518

Remarks

Designed By : Sarita Infotech Pvt. Ltd., Navsari

Yashfeen Cardiac Hospital

Thanks for Reference

Reta
signature
Technician



(Regd. No. E / 1390 / Navsari)

YASHFEEN CARDIAC HOSPITAL™

MANAGED BY :- YASHFEEN FOUNDATION

VIRAVAL, NAVSARI. 396 445. PHONE : (H) (02637) 235725

Website : www.yashfeenhospital.in E-mail : info@yashfeenhospital.in

(Stationary For Report Only)

2D ECHO CARDIOGRAPHY COLOUR DOPPLER REPORT

Patient Name & No	: ROHANKUMAR NAVNITLAL PATEL CH2404583I	Age/Sex	UHID :	: 5971
Doctor	: Mohil Nagad	37/ M	No :	: 5854
Referred By	:		Date :	: 08/03/2025

M-Mode findings

LVIDd : 48mm
 LVIDs : 32mm
 IVSd : 10mm
 PWd : 10mm
 EF : 60%
 Aorta : 20mm
 LA : 30mm

2D Imaging

Aortic Valve : Trileaflet, Normal
 Mitral Valve : Thin, Pliable, Normal Mobility, Normal function
 Tricuspid Valve : Normal
 Pulmonary Valve : Normal

=> : All cardiac chambers are normal sized.
 => : All cardiac valves are normal.
 => : No regional wall motion abnormality.
 => : Normal LV systolic function.
 => : Normal LV diastolic function.
 => : IAS/IVS intact.
 => : No obvious clots/ vegetations/ or effusion.
 => : IVC Normal size.

Doppler Findings

=> : No MS/MR, No TS/TR, No AS/AR & No PS/PR
 Mitral inflow Pattern : E > A
 Tissue Doppler Findings : E' > A'

Impression : Normal LVEF: 60%, No RWMA.



Report Prepared By

DR. MOHIL NAGAD
 M.D. Medicine, Dip. Cardiology
 Senior Consultant, Interventional Cardiology
 Reg. No. G-28035
 YASHFEEN HOSPITAL, NAVSARI
 M.D. (Phy.) Dip. Cardiology
 Non-Invasive Cardiologist

Report Checked By

Mobin Sheikh

Designed By : Sarita Infotech Pvt. Ltd., Navsari



YASHFEEN CARDIAC HOSPITAL EYE DEPARTMENT

Chief Complaint : *Ronti Chebey*

Medical History : ~~DM / HT / Asthama / Allergy / Heart / Thyroid / TB / Anticoagulants~~

Family History :

Past Ocular History :

Ocular Trauma :

Visual Acuity : *Ny < 6/12
G/20'*

IOP :

NAME |

08_MAR_2025 AM 11:28
NO. 3541
SN: 4771998

REF. DATA

VD: 12.00 CYL: MIX

<R> S C A
- 0.00 - 1.25 14
- 0.25 - 1.25 13
- 0.25 - 1.25 13
- 0.25 - 1.25 13
S. E. - 1.00

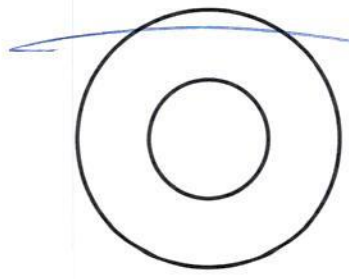
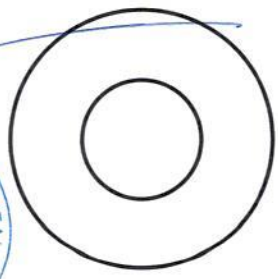
<L> S C A
- 0.00 - 2.75 167
- 0.00 - 2.75 166
- 0.00 - 2.75 166
- 0.00 - 2.75 166
S. E. - 1.50

PD: 68.5

	RIGHT EYE (PH.....)				LEFT EYE			
	Sph.	Cyl.	Axis	V/A	Sph.	Cyl.	Axis	V/A
Distance	/	<i>1.00</i>	<i>10</i>	<i>6/8</i>	/	<i>2.50</i>	<i>170</i>	<i>6/8</i>
Near	<i>all</i>				<i>all</i>			

Constant/Distance/Reading/Bi-Focal/Progressive/Separate Glasses *Adhos
Classes*

SLE :



Handwritten signature

Handwritten signature

YASHFEEN IMAGING & RADIOLOGY DEPARTMENT

MANAGED BY :- YASHFEEN FOUNDATION

VIRAVAL, NAVSARI. 396 445. PHONE : (H) (02637) 235725

Website : www.yashfeenhospital.in E-mail : info@yashfeenhospital.in

Name	ROHANKUMAR N. PATEL	Age	37Y/M
Ref by Dr	SELF	Date	08/03/2025

USG ABDOMEN (SCREENING)

Liver appears normal in size & shape with normal echopattern.
No e/o focal or diffuse lesion. IHBR appear normal.
PV and CBD appear normal.

Gall bladder appears distended & normal in shape & size. No e/o calculus or mass seen.
Walls appear normal.

Pancreas appears normal in size and echogenicity. No e/o focal or diffuse lesion.

Spleen appears normal in size and shows normal echopattern. No e/o focal lesion.

Both Kidneys appear normal in size and echopattern. CM Differentiation is preserved.
No e/o calculus or hydronephrosis on either side.
Perirenal spaces appear normal on either side.
Suprarenal regions appear normal on either side. No e/o mass lesion.

Bladder is empty (due to non-compliance of patient). Adv: Follow up USG with normally distended bladder.

Prostate appears enlarged in size measuring 36 cc with normal echopattern.
No e/o calcification.

RIF region appears normal.

No e/o ascites.

IMPRESSION:

Moderate prostatomegaly. Adv: S. PSA correlation.



Dr. DHARMESH DESAI
(M.D. Radiology)
Reg. No. 045284
YASHFEEN GROUP OF HOSPITAL

Please contact immediately for any typographical error.

This is only professional opinion, not a final diagnosis. Kindly correlate clinically. Not valid for medicolegal purpose.

ROHANKUMAR N, PATEL
 ID:
 DOB:
 37 Years
 Male, Unknown
 Med.:
 Location:
 Referring Physician:
 Notes:

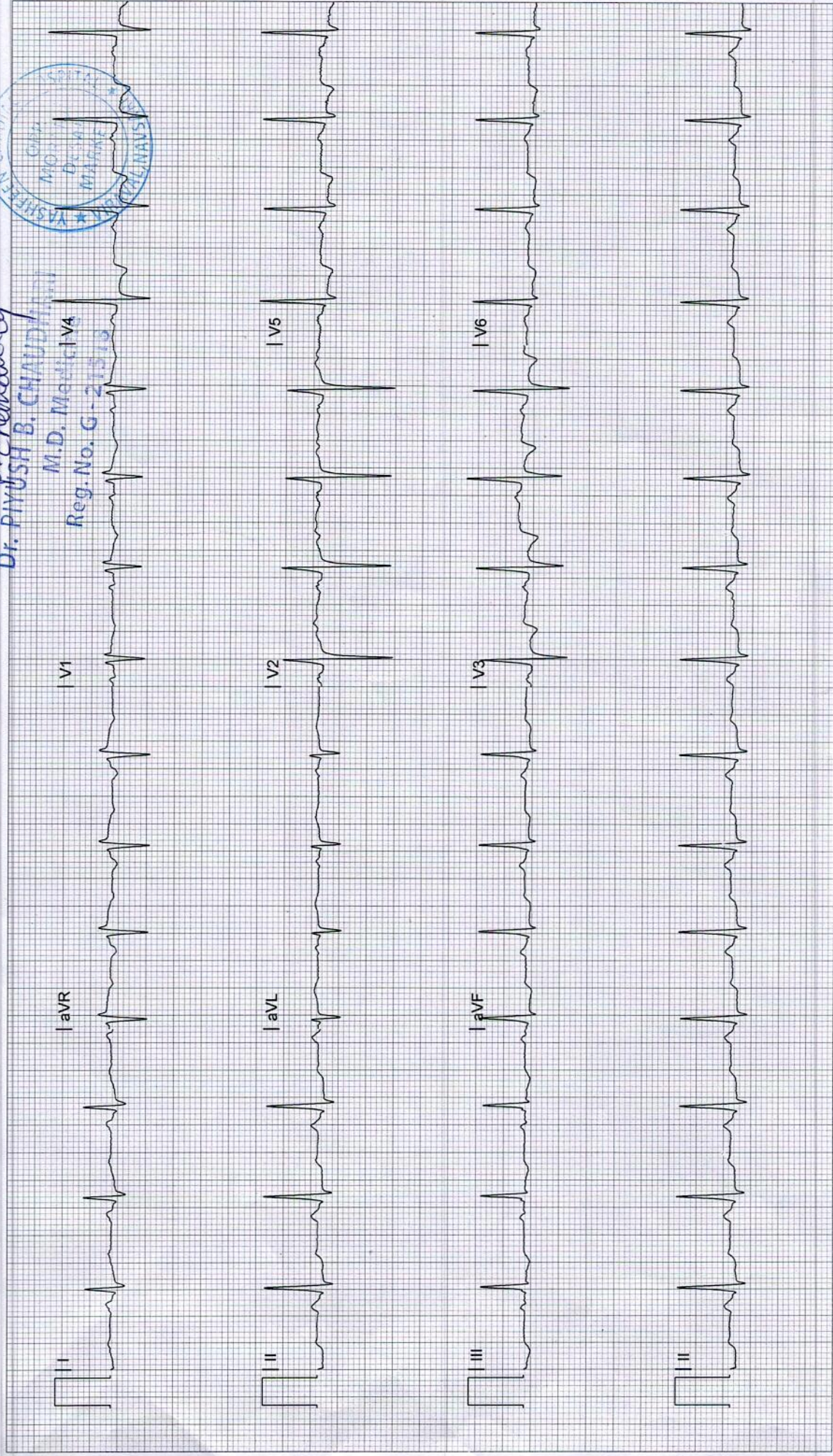

08-03-2025 10:02:02
 Vent. Rate: 93 BPM
 PR int: 140 ms
 QRS dur: 102 ms
 QT/QTc: 323/374 ms
 P-R-T axes: 53 78 -3
 Avg. RR: 641 ms
 QTcB: 403 ms
 QTcF: 374 ms

SINUS RHYTHM
 INCOMPLETE RIGHT BUNDLE BRANCH BLOCK
 ST DEVIATION AND MODERATE T-WAVE ABNORMALITY, CONSIDER ANTEROLATERAL ISCHEMIA
 ABNORMAL ECG

UNCONFIRMED REPORT
 Reviewed by:

Signed by:
 Date:

Dr. PIYUSH B. CHAUDHARI
 M.D. Medicine
 Reg. No. G-21519



YASHFEEN IMAGING & RADIOLOGY DEPARTMENT

MANAGED BY :- YASHFEEN FOUNDATION

VIRAVAL, NAVSARI. 396 445. PHONE : (H) (02637) 235725

Website : www.yashfeenhospital.in E-mail : info@yashfeenhospital.in

Patient's Name:	ROHANKUMAR N. PATEL	Age & Sex:	37Yrs/m
Ref. by Dr.	SELF	Date:	08-03-2025

X RAY CHEST (PA VIEW)

Both lung fields appear normal.
Both hila appear normal.
Both CP angles appear clear.
Cardiac size appears within normal limit.
Both domes of diaphragm appear normal.
Bony thoracic cage appears normal.

IMPRESSION:

- Normal X-ray chest (PA view).



Dr. Dharmesh Desai

Dr. Dharmesh Desai (Radiology)

Reg. No. GMD5284

YASHFEEN GROUP OF HOSPITAL

Please contact immediately for any typographical error.

This is only professional opinion, not a final diagnosis. Kindly correlate clinically. Not valid for medicolegal purpose.