



SINCE 1994

# NADKARNI

## PATHOLOGY LABORATORY

**Dr. Mrs. Sangeeta V. Nadkarni**

Consulting Pathologist (MMC Reg. No. 53839)

Add Reg. No. : 1872/2000

E-mail : healthcare.nadkarni@gmail.com

Website : www.nadkarnipathlab.com

Consultant Pathologist • SHASHWAT HOSPITAL



MAIN LABORATORY : 1, Indraprastha Chambers, Ground Floor, Near Amber Hall, Karve Road, Pune 411 038. Ph. : 97635 93646, 8983 7777 93 • Timings : Monday to Saturday 7 am to 8 pm

Reg No : N25409787 / OPD  
Name : Mr. AMIT PURANDARE  
Referred Dr : MEDI WHEEL

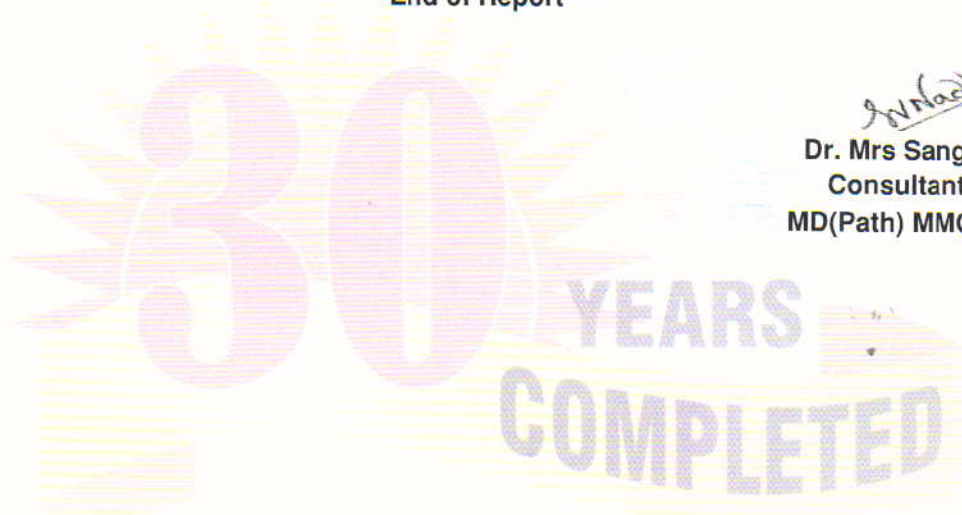
Sex / Age : Male / 37Y  
Reg Date : 08/03/2025 11:12 AM  
Report Date : 08/03/2025 05:26 PM

### BIOCHEMISTRY

Test Name	Result	Unit	Reference Range
<b>Blood Glucose Fasting and Post Prandial</b>			
Blood Glucose (Fasting)	109	mg/dl	Normal : < 99 Prediabetic : 100.0 - 125.0 Diabetic : > 125.0
Post Prandial Glucose Instrument Used	119	mg/dl	90 - 140 mg/dL Fully Automated EM200 (TRANSASIA BIOMEDICALS).

### End of Report

**Dr. Mrs Sangeeta Nadkarni**  
Consultant Pathologist  
MD(Path) MMC Reg No-53839



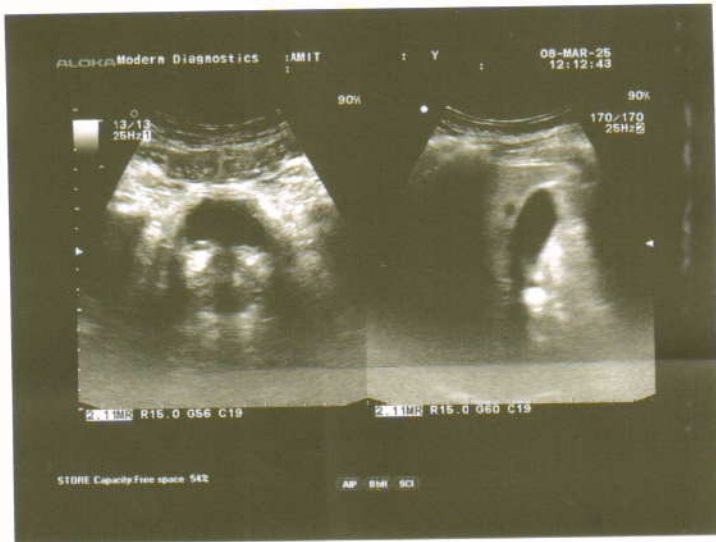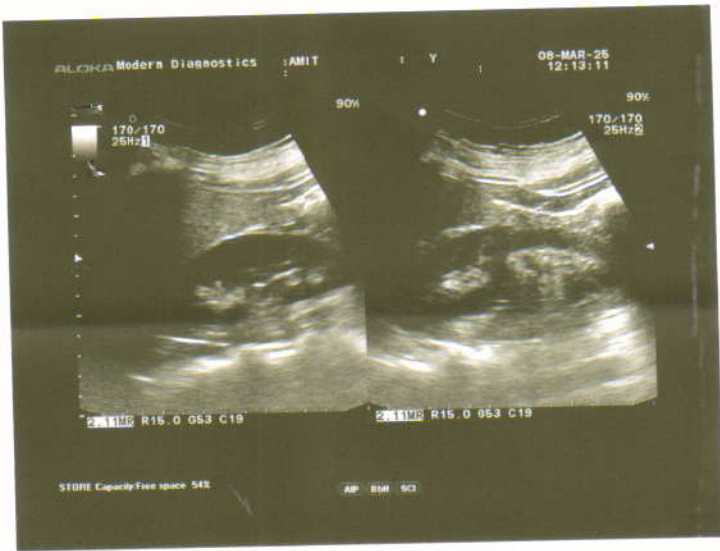
#### Verified & Checked


- Transasia EM 200 Fully Automated Random Access Clinical Chemistry Analyser • TMT • E.C.G. • Semi Automated Biochemistry Analyser Erba Chem 5 V2 Plus
- Automated Haematology Analyser H 360 • Clinical Pathology • Microbiology • Cytology • Histopathology • Minividas Blue • Tosoh MAXIA • Turbosmart

**ALL CREDIT AND DEBIT CARDS ACCEPTED & GPAY, PAYMT****HOME VISIT AVAILABLE BY APPOINTMENT**

**COLLECTION CENTRE 1** : 1, Varun Complex, Opp. Nimbalkar Horse Riding School,  
Off. Karve Road, Kothrud, Pune - 38. Ph. : **8983 7777 92**  
Timing : MONDAY TO SATURDAY : Morning : 8 am to 1 pm, Evening : 4 pm to 7 pm

**COLLECTION CENTRE 2** : Bldg. No. 7, Health Care Clinic, Anandnagar,  
Paud Road, Kothrud, Pune - 38. Ph. : **8983 7777 95**  
Timing : MONDAY TO SATURDAY : Morning : 8 am to 1 pm, Evening : 5 pm to 8 pm





**Dr. Prashant Naik**

M.D. (Radiology)

Reg. No. 58314

Time : 6.00 pm to 8.00 pm

• DIGITAL X-RAY • SONOGRAPHY • COLOUR DOPPLER

Patient's Name Mr Amit Purandare  
Ref By Dr Dr V.M.Nadkarni  
Date March 08, 2025

### USG ABDOMEN & PELVIS

Liver normal in size, shape & outline & reveals normal echo-texture.  
No focal lesion seen. Intra hepatic biliary and portal vein radicles normal.  
Gall bladder physiologically distended & shows clear contents. No calculi. No e/o cholecystitis.  
Portal vein & CBD normal. No calculus in CBD.  
Spleen & visualized pancreas show normal size & echoanatomy. Tail of pancreas not visualized due to unavoidable bowel gas.  
Both kidneys normal in size, shape, outline & position.  
Right kidney :- 98mm x 42mm.  
Left kidney :- 108mm x 47 mm.  
No hydronephrosis, hydroureter on either side. No calculus seen in both kidneys or in visualized ureters.  
Cortico-medullary differentiation normal.  
Urinary bladder is well filled. No mural or luminal pathology seen.  
Prostate normal in size, echotexture; measures 30mmx25mmx24mm.  
Aorta & IVC normal. No lymphadenopathy. No loculated or free fluid collection seen in abdomen or pelvis. No abnormally dilated bowel loops seen.

### IMPRESSION

No abnormality appreciated in this USG study of Abdomen & Pelvis

**Dr. Kedar Athawale**  
DMRD, DNB  
Thanks for referral

**KEDAR ATHAWALE**  
DNB (Radiology)  
98224 07720