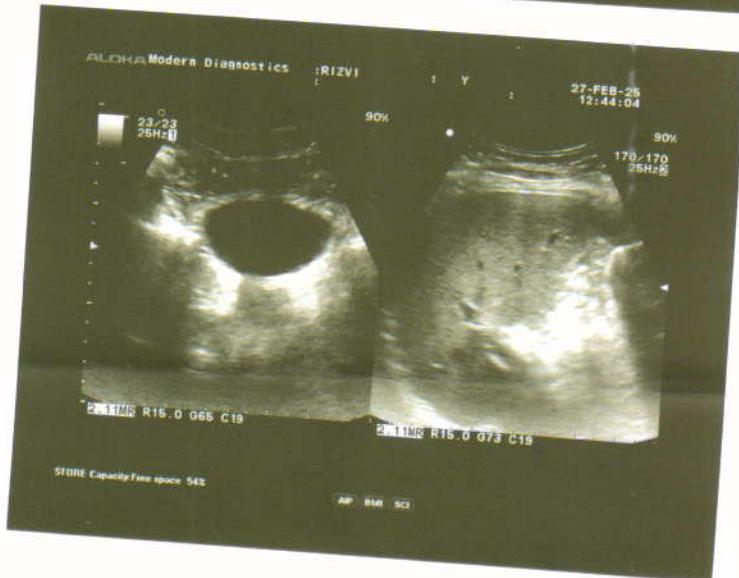
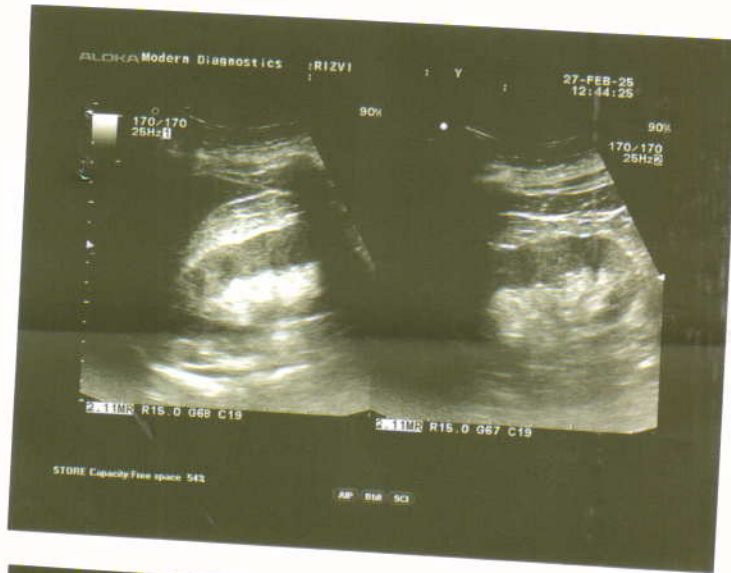
Patient's Name Mr Mahammad Rizvi
Ref By Dr Dr V.M.Nadkarni
Date Feb 27, 2025

USG ABDOMEN & PELVIS

Liver normal in size, shape & outline & reveals normal echo-texture.
No focal lesion seen. Intra hepatic biliary and portal vein radicles normal.
Cholecystectomy.
Portal vein & CBD normal. No calculus in CBD.
Spleen & visualized pancreas show normal size & echoanatomy. Tail of pancreas not visualized due to unavoidable bowel gas.
Both kidneys normal in size, shape, outline & position.
Right kidney :- 102mm x 47mm.
Left kidney :- 103mm x 56 mm.
No hydronephrosis, hydroureter on either side. No calculus seen in both kidneys or in visualized ureters.
Cortico-medullary differentiation normal.
Urinary bladder is well filled. No mural or luminal pathology seen.
Prostate normal in size, echotexture; measures 30mmx25mmx24mm.
Aorta & IVC normal. No lymphadenopathy. No loculated or free fluid collection seen in abdomen or pelvis. No abnormally dilated bowel loops seen.

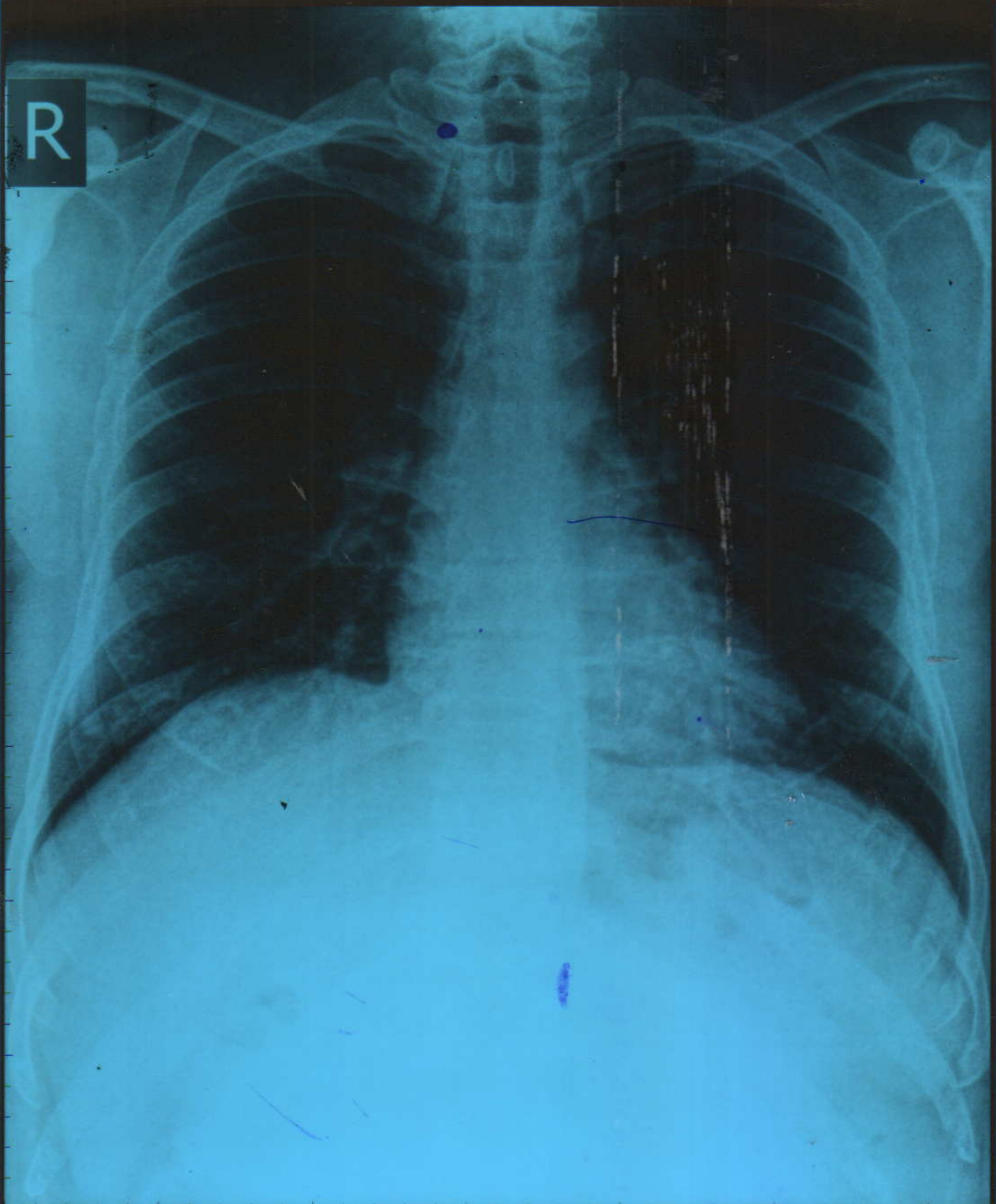
IMPRESSION

No abnormality appreciated in this USG study of Abdomen & Pelvis

Dr. Kedar Athawale
DMRD, DNB
Thanks for referral

DR. KEDAR ATHAWALE
DMRD DNB (Radiology)
Reg. No. 81098

R



MOHAMMAD RIZVI Male / 38 YRS

Chest PA

27/02/2025 01:11:36 PM

SHRI DASHABHUJA X-RAY CLINIC. PUNE. 020-25468187.



**SHRI DASHABHUJA
X-RAY CLINIC**

Digital X-Ray (CR System) Available
CBCT & OPG Facility Available

GANGAVATARANA, Ground Floor, Plot
No. 7, S. No. 42 A/1A/2F, Dashbhujia
Ganesh Colony, Near Dashbhujia
Ganesh Temple, Karve Road,
Pune. 411038.
Clinic : 2546 8187, 8308839383
Res : 2422 1359, 9822041859

Dr. LALIT P. PATHAK

M. D. Radiologist
Reg. No. 52382

Timing : 9.00 a.m. To 1.30 p.m.
4.30 p.m. To 8.30 p.m.
SUNDAY CLOSED

NAME:MR MOHAMMAD RIZVI.

DATE:27 02 2025.

REF BY:DR VIVEK NADKARNI.

X RAY CHEST PA VIEW.

Both the domes of the diaphragm are clear & at normal position.
The heart, the aorta, the mediastinum & the pulmonary vasculature
reveal no abnormality.
Lungs show no acute or active parenchymal pathology.
Pleural sinuses are clear on both sides.
There is no evidence of any hilar or mediastinal lymphadenopathy.
No pathology is evident in the thoracic bony cage &
the soft tissues.

CONCLUSION:NORMAL X RAY CHEST PA VIEW.

Dr. Lalit P. Pathak
Reg. No. 52382 M.D. (Radiology)
Shri Dashbhujia X-Ray Clinic
Near Dashbhujia Ganesh Temple,
Karve Road, Pune - 411 008.

CBCT, OPG & PORTABLE X-RAY FACILITY AVAILABLE

(P.T.O)