

IPSITA RANI BEHERA

35 YEARS/FEMALE

09/11/2024

REAL TIME SONOGRAPHY OF THE ABDOMEN & PELVIS

LIVER - It is normal in size (14.3 cm). It shows normal echo pattern. No evidence of solid or cystic focal lesion is seen. The intrahepatic biliary system is normal and shows no dilatation of the radicals. The portal vein, CBD and hepatic veins appear normal.

GALL BLADDER - It is distended and appears normal. No evidence of sludge or calculus is seen. The wall appears normal.

PANCREAS - It is visualized and appears normal.

SPLEEN - It appears normal in size (10.7 cm), shape and in echo texture. No focal lesions.

KIDNEYS - . Both the kidneys appear normal in size, shape and show normal corticomedullary differentiation. Normal echogenicity of both kidneys.

Right kidney measures 10.7 X 3.2 cm. Left kidney measures 10.6 X 4.4 cm.

Calculus of size 4.4 mm is noted in upper calyx of right kidney.

No hydronephrosis is seen on either side.

Urinary bladder is distended and appears normal. No evidence of calculus / mass lesion is seen. The walls appear normal.

Uterus appears normal. ET measures 10.0 mm. No focal lesion.

Both adnexa appears normal.

No evidence of any lymphadenopathy or ascites is noted.

IMPRESSION:

RIGHT RENAL CALCULUS.NO HYDRONEPHROSIS.



DR. SARJAN VASAVA,
CONSULTANT RADIOLOGIST.

DR SARJAN VASAVA
M.B.B.S., D.M.R.D.
Reg. No. G-26527
SAMANVAY HOSPITALS

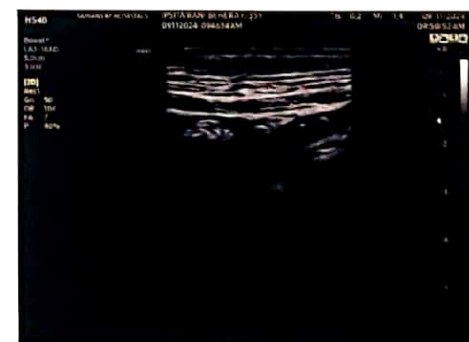
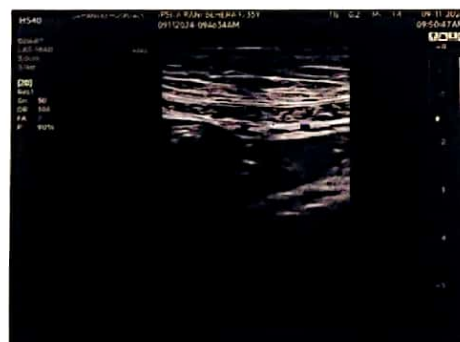
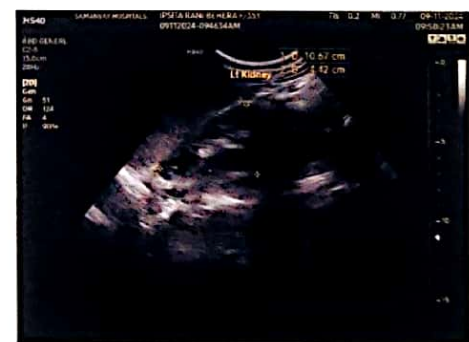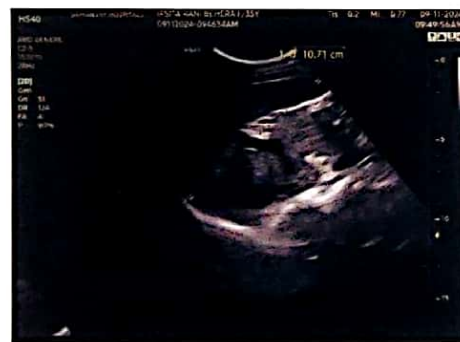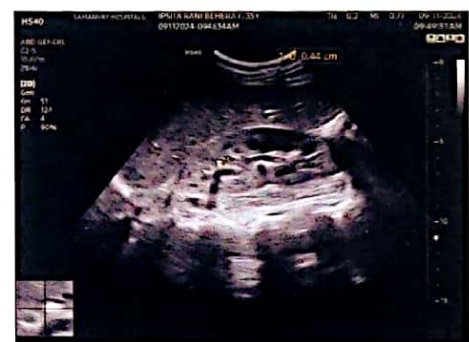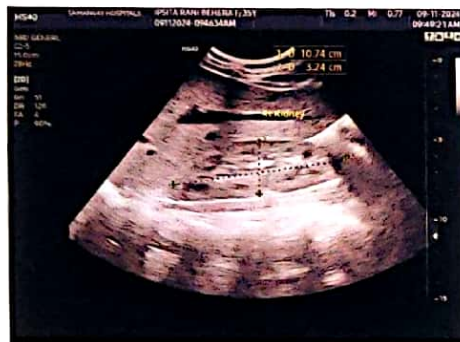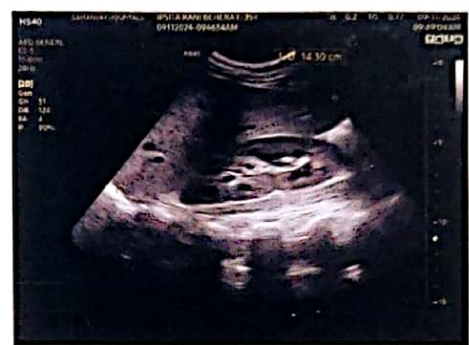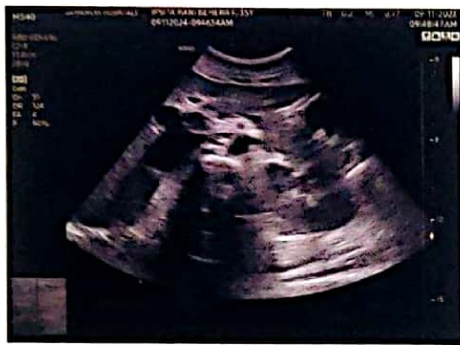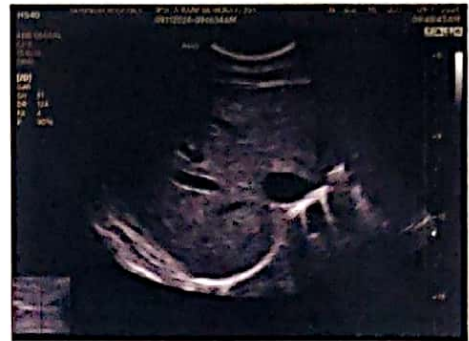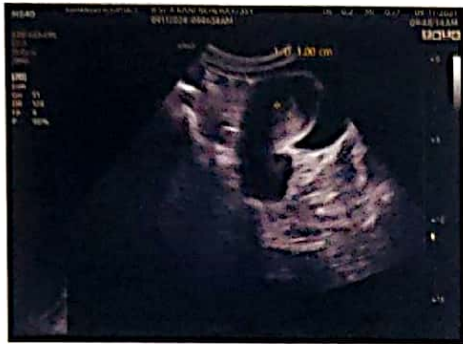Patient

ID 09112024-094634AM
Name IPSITA RANI BEHERA F/35Y
Birth Date
Gender

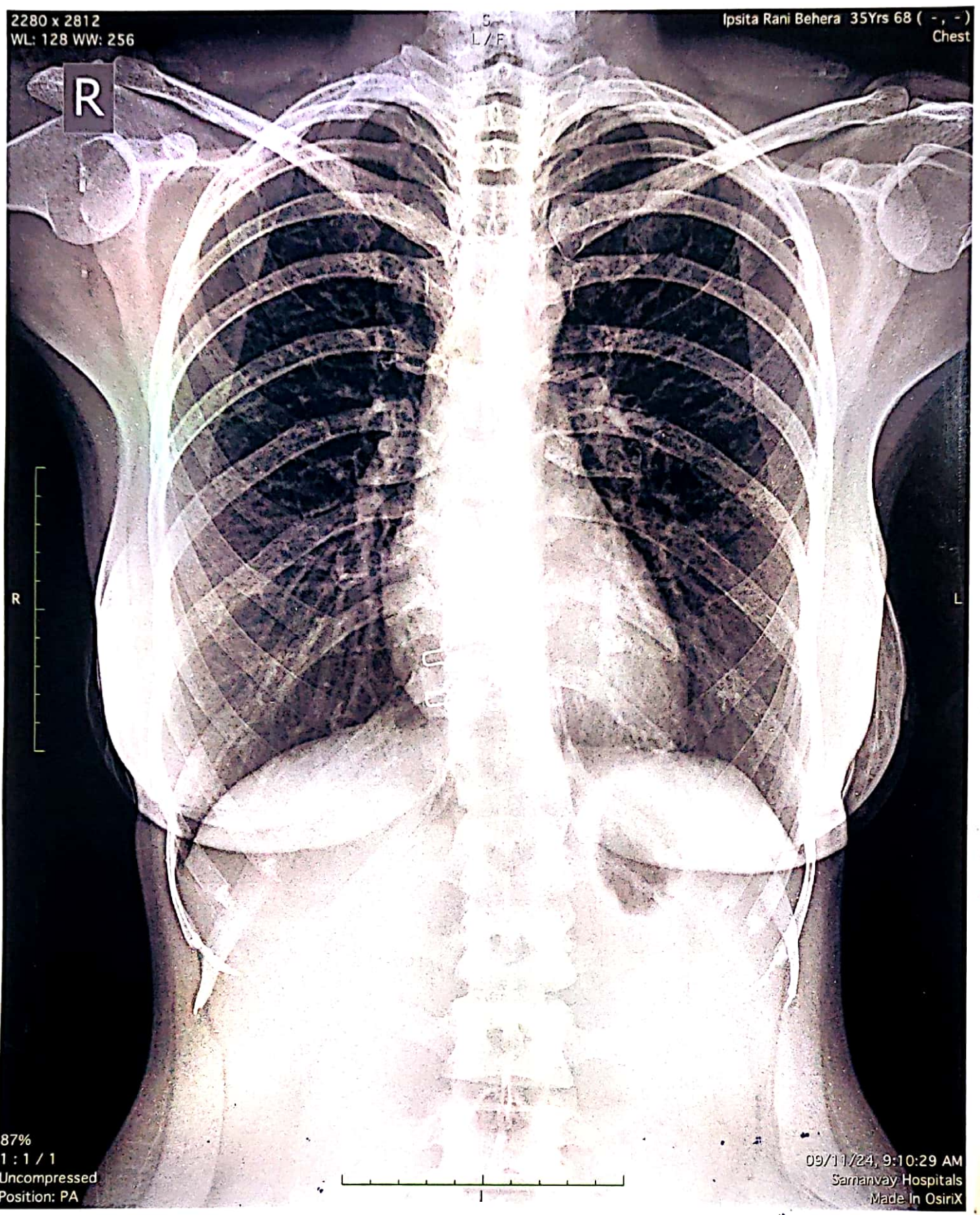
Exam


Accession #
Exam Date 09-11-2024
Description
Operator



Ipsita Rani Behera F/35y

09-11-24





Ipsita
Behara

Female

Age:
..... cm / kg

HR 63/min

Intervals:
RR 949 ms
P 86 ms
PR 128 ms
QRS 78 ms
QT 414 ms
QTc 427 ms

10 mm/mV

SINUS RHYTHM

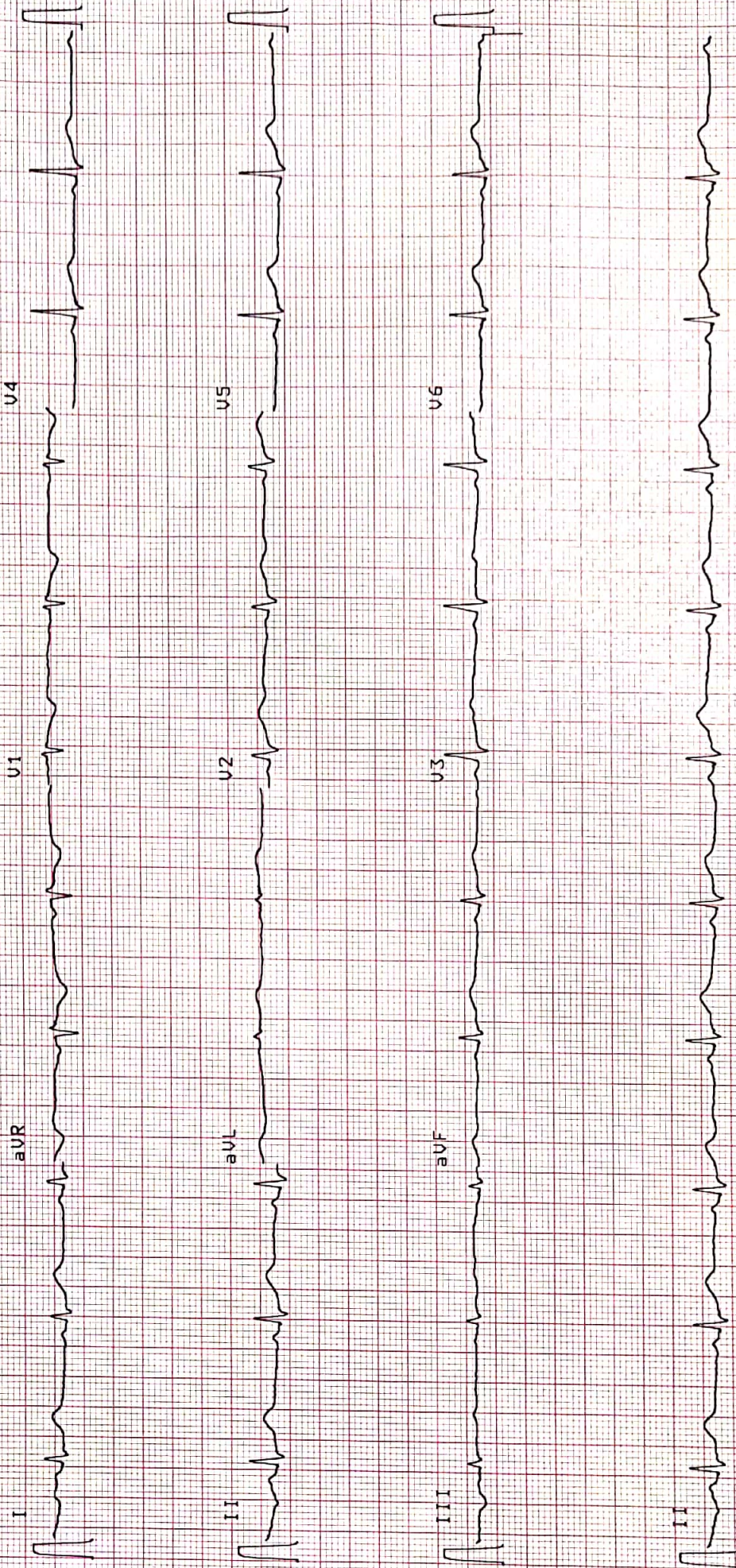
LOW LIMB LEAD VOLTAGE
NON SPECIFIC T ABNORMALITY

5.79

UNCONFIRMED REPORT

DR. PAVAN ROY
MD, DM (CARDIOLOGY)
CONSULTANT CARDIOLOGIST
REG. NO. 930599163
M. No. 153620163

10 mm/mV



10 mm/mV

25 mm/s

samarvaya hospital, baroda

53 29-NOV-24 09:22:21

F50 S5F S8S

0.05-25Hz

SCHILLER

Part No.2.157017M

CE 0123

M.B.F

DR. PAVAN ROY
MD, DM (CARDIOLOGY)
CONSULTANT CARDIOLOGIST
REG. NO. G-23300
M. No. 930599163
M. No. 153620163



GYNECOLOGICAL CHECK UP

S/B Dr. : Swati Bhimani Date : 9/11/24

Name : Mrs. Ipshta Rami Age / Sex : 35/F

COMPLAINTS : NO COMPLAINTS
Abdominal pain / Leucorrhoea / Dysmenorrhoea / Menorrhoea /
Polymenorrhoea / Discharge PV / Itching PV / Mass PV /
Post Coital Bleed / Dysparunja

MENSTRUAL HISTORY :
MENSTRUAL CYCLE : Reg
DAYS / Irreg.,
FLOW : Mod / Heavy

LMP : 25/10

OBS HISTORY :
Duration of Married Life

NO. OF CHILDREN : G¹ P¹ L¹ A¹ 1st MD / 9 / 3 1/2 yrs / e.

NO.	AGE	SEX	MODE OF DELIVERY	OTHERS

DESIRES CONTRACEPTION : YES / NO
MODE OF CONTRACEPTION : Safe Period / Barrier / IDU / OCP / Others

D / E : P / A : ln

P / S : Artificial Contraception

P / V : _____

BREAST NA : Rt : _____ Lt : _____

ADVICE : _____

CONSULTANT'S SIGNATURE



2D ECHOCARDIOGRAPHY AND COLOUR DOPPLER STUDY

NAME : MRS.IPSITA RANI

DATE :09-11-24

AGE/SEX :35 YRS / F WARD: HCP

REF BY : SAMANVAY HOSPITAL

OBSERVATION:

- NORMAL LV SIZE WITH NORMAL LV SYSTOLIC FUNCTION
- LVEF 60%, NO RWMA AT REST
- E/O NORMAL LV DIASTOLIC DYSFUNCTION, NORMAL LA SIZE
- AORTIC VALVE, NO AR, NO AS
- MITRAL VALVE, TRIVIAL MR, NO MS
- TRIVIAL TR, NO PAH, RVSP 26 MMHG
- NORMAL SIZED RA, RV WITH NORMAL RV FUNCTION
- PULMONARY VALVE- NO PR, NO PS, NORMAL SIZED PA & ITS BRANCHES
- IAS, IVS ARE INTACT
- NO INTRACARDIAC CLOT, VEGETATION
- PERICARDIUM NORMAL, NO PERICARDIAL EFFUSION
- IVC NORMAL IN SIZE

MEASUREMENTS:

M MODE: AORTA: 22 MM LA: 24 MM LV DD/DS: 48/29 MM IVS/PW: 10/09 MM
DOPPLER: MV RATIO E/A: 0.9/0.4 M/S AV VMAX: 1.1 M/S PV VMAX: 0.5 M/S

CONCLUSION:

**NORMAL LV SIZE AND LV SYSTOLIC FUNCTION
LVEF 60%, NO RWMA AT REST
TRIVIAL MR, TRIVIAL TR, NO PAH
E/O NORMAL LV DIASTOLIC DYSFUNCTION**



DR. PAVAN ROY
MD, DM (CARDIOLOGY) REG. NO. 16-23390
CONSULTANT INTERVENTIONAL CARDIOLOGIST

Patient Name : MRS. IPSITA RANI BEHERA
Age & Sex. : 35Y 3M 26D /F
Bill date : 09/11/2024 12:38 PM

Bill No. : OPB/1/24/10973
Reg No. : REG-14260
Sponsor : MEDIWHEEL

X-RAY CHEST PA

Both the lung fields appear normal.

Both costophrenic angles appear clear.

Cardiac silhouette appear normal.

Both hila appears normal.

Mediastinum and aorta appear normal.

Bony thorax appears normal.

No evidence of free gas seen under dome of diaphragm.

COMMENTS:

- **NORMAL BOTH LUNG FIELDS.**
- **NORMAL CARDIAC SIZE.**

Impression :
Conclusion :



Dr. Sarjan Vasava
Radiology

(Reg No-G-26527)

DR SARJAN VASAVA
M.B.B.S., D.M.R.D.
Reg. No. G-26527
SAMANVAY HOSPITALS



COMPREHENSIVE HEALTH CHECK UP

Case No. : _____ Date : _____

Name : Ipsita Rani Age/Sex : _____

MEDICAL HISTORY : Renal Calculi + Hypothyroidism
- on Ayurvedic Medication

PERSONAL HISTORY : _____

Appetite : _____ Smoking : _____

Sleep : _____ H/O Alcohol : _____

Bladder : _____ Lifestyle : _____

Bowel : _____ Exercise : _____

DRUG HISTORY : _____

PAST HISTORY : _____

FAMILY HISTORY : _____

GENERAL PHYSICAL EXAMINATION :

Built and Nourishment :

Height : 156 cm SpO₂ :- 97+

B. P. : 100/70 mm of Hg Weight : 45.2 Kg

Character : _____ Pulse : 64 / Min

Nails : _____ Odema : _____

Tonsils : _____ Skin : _____

Tongue : _____ Sclera : _____

Eat. & Joints : _____ Glands : _____



thyrotoxicosis

- on Ayurvedic
medication

Adu

- Renal studies / S. UOH /
S. VITB12/24


2023 { Tb, NCCFR 070
Tb, SUB type plus CD 070
उपरोक्त के साथ

EYE CHECK UP

Reg. No.: _____ Date: 9-11-2024
 Name: Ipsita Rami Age / Sex: 35 / F

	RIGHT EYE	LEFT EYE
DISTANCE : (With / Without Glasses)	6/60 -2.0 X -0.75 X 85	6/60 2.0 / -0.75 x 60
NEAR VISION : (With / Without Glasses)	N.6	N.6
ANTERIOR SEGMENT :	WNL	WNL
I O P (MM of Hg)	140	140
FUNDUS :	WNL	WNL
COLOR VISION :	WNL	WNL
CLINICAL IMPRESSION :	MYOPIC Astigmatism	
ADVICE :	gl	

Doctor's Signature :



Dental



MRS. Ipsita Rumi - 35/F


9-11-2024

Co : No complains .

Adv : follow-up every 6 months .


Vasna Main Road,
Opp Raneshwar Temple, Vadodara.

info@samanvayhospital.com



Ph: +91 88820 82082

Patient Name : MRS. IPSITA RANI BEHERA
 Age / Sex : 35Y 3M 26D/Female
 IP/Reg.No/UHID : Reg-14260 /UHID14260
 Lab No : LA24010349
 Referred By : Dr.SAMANVAY HOSPITAL
 Bedcategory/Bed :
 Mobile No : 9178130971
 UHID : UHID14260
 Consultant : Mr. Samanvay Hospital
 Sponsor : **MEDIWHEEL**
 ABHA Address :
 Barcode No. : **38035,38036,38037,38038**

Bill No : OPB/1/24/10973
 Sample Collected : Nov 9 2024 9:39AM
 Sample Received : Nov 9 2024 9:48AM
 Report On : Nov 9 2024 9:48AM
 Bill Creation Date : Nov 9 2024 9:04AM
 Bar Code : 
 Reg No : Reg-14260
 IPNo :
 Passport No. :
 Verified On : **Nov 9 2024 12:01PM**
 ABHA Num :

Test Name

Results

Units

Biological Reference

MICRO

URINE ANALYSIS

PHYSICAL EXAMINATION

VOLUME : 30 ML
 COLOUR : PALE YELLOW
 APPEARANCE : CLEAR

CHEMICAL EXAMINATION

PH : 6.0 4.5 - 8.0
 SPECIFIC GRAVITY : 1.025 1.000 - 1.030
 PROTEIN : Negative
 GLUCOSE : Negative
 KETONE : Negative
 BLOOD : Negative
 UROBILINOGEN : Negative
 BILE PIGMENTS : Negative
 BILE SALT : Negative
 NITRITE : Negative
 LEUKOCYTE ESTERASE : Negative


MICROSCOPIC EXAMINATION

PUS CELLS : 1--2 CELLS/HPF 0 - 5
 RBC : NIL RBC'S/HPF 0 - 2
 EPITHELIAL CELLS : 2--3 OCC/HPF 0 - 5
 CASTS : NIL
 CRYSTALS : NIL

HPLC

HBA1C/ GLYOCO HB

GLYCOCYLATED HAEMOGLOBIN(HBA1C)(HPLC) : 4.2 % 4.0 - 6.0




Mrs. Neena Ravi Patel

Dr. Sweta Patel
MD (Pathology)


Prepared by

Verified By

Patient Name : MRS. IPSITA RANI BEHERA
Age / Sex : 35Y 3M 26D/Female
IP/Reg.No/UHID : Reg-14260 /UHID14260
Lab No : LA24010349
Referred By : Dr.SAMANVAY HOSPITAL
Bedcategory/Bed :
Mobile No : 9178130971
UHID : UHID14260
Consultant : Mr. Samanvay Hospital
Sponsor : **MEDIWHEEL**
ABHA Address :
Barcode No. : **38035,38036,38037,38038**

Bill No : OPB/1/24/10973
Sample Collected : Nov 9 2024 9:39AM
Sample Received : Nov 9 2024 9:48AM
Report On : Nov 9 2024 9:48AM
Bill Creation Date : Nov 9 2024 9:04AM
Bar Code : 
Reg No : Reg-14260
IPNo :
Passport No. :
Verified On : **Nov 9 2024 12:01PM**
ABHA Num :

Test Name	Results	Units	Biological Reference
AVERAGE BLOOD SUGAR	73.84	mg/dl	0 - 140.0
BIOCHEMISTRY			
LIPID PROFILE			
CHOLESTROL (TOTAL)(CHOD-PAP)	139.0	mg/dl	0.0 - 200.0 Desirable blood cholesterol : <200 mg/dl Borderline high blood cholesterol : 200-239 mg/dl High blood cholesterol : >239 mg/dl
TRIGLYCERIDE(GPO-METHOD)	56.8	mg/dl	0 - 161.0 NORMAL : <161 MG/DL HIGH : 161-199 MG/DL HYPERTRIGLYCERIDEMIC : 200-499 MG/DL
HDL CHOLESTEROL(DIRECT METHOD)	59.2	mg/dl	42.0 - 88.0
CHOLESTROL (TOTAL)/HDL RATIO(CALCULATED)	↓ 2.35		3.30 - 4.40
VLDL	11.36		0 - 30.0
LDL CHOLESTEROL(CALCULATED)	79.8		0 - 130.0
LDL/HDL RATIO	1.35		
CREATININE (BLOOD)(ENZYMATIC)	0.62	mg/dl	0.6 - 1.1
UREA(UREASE-GLDH)	22.1	mg/dl	21.0 - 43.0
BUN(UREASE-GLDH)	10.32	mg/dl	5.0 - 21.0
URIC ACID	3.2	mg/dl	2.6 - 6.0
BUN CREATININE RATIO(CALCULATED)	16.6	mg/dl	10.0 - 20
LIVER FUNCTION TEST			
BILIRUBIN-TOTAL(DIAZO)	0.48	mg/dl	0.00 - 2.0
BILIRUBIN-DIRECT(DIAZO)	0.28	mg/dl	0.00 - 0.4
BILIRUBIN-INDIRECT(DIAZO)	0.20	mg/dl	0.00 - 1.10



Mrs. Neena Ravi Patel


Dr. Sweta Patel
MD (Pathology)

Prepared by

Verified By

Nr. St. Kabir School, Opp. Raneshwar Temple, Vasna Road, Vadodara-15

Patient Name : MRS. IPSITA RANI BEHERA
Age / Sex : 35Y 3M 26D/Female
IP/Reg.No/UHID : Reg-14260 /UHID14260
Lab No : LA24010349
Referred By : Dr.SAMANVAY HOSPITAL
Bedcategory/Bed :
Mobile No : 9178130971
UHID : UHID14260
Consultant : Mr. Samanvay Hospital
Sponsor : **MEDIWHEEL**
ABHA Address :
Barcode No. : **38035,38036,38037,38038**

Bill No : OPB/1/24/10973
Sample Collected : Nov 9 2024 9:39AM
Sample Received : Nov 9 2024 9:48AM
Report On : Nov 9 2024 9:48AM
Bill Creation Date : Nov 9 2024 9:04AM
Bar Code : 
Reg No : Reg-14260
IPNo :
Passport No. :
Verified On : **Nov 9 2024 12:01PM**
ABHA Num :

Test Name	Results	Units	Biological Reference
-----------	---------	-------	----------------------

SGOT(IFCC WITHOUT PYRIDOXAL PHOSPHATE)	22.8	U/L	0 - 31
SGPT(IFCC WITHOUT PYRIDOXAL PHOSPHATE)	12.7	U/mL	0 - 34
ALKALINE PHOSPHATASE(ALKP04)* (AMP-METHOD)	47.0	U/L	42 - 141
PROTEIN (SERUM)(BIURET)	7.36	g/dl	6.4 - 8.3
ALBUMIN(BCG)	4.18	g/dl	3.5 - 5.2
GLOBULIN(CALCULATED)	3.18	g/dl	2.3 - 3.7
A/G RATIO(CALCULATED)	1.31	Ratio	1.0 - 2.0
GAMMA GT(GLUPA C METHOD)	35.0	U/L	0.0 - 58.0

IMMUNOLOGY

T3 T4 TSH

TOTAL T3(CHEMILUMINESCENCE / CLIA)	0.82	ng/ml	0.19 - 6.51
TOTAL T4(CHEMILUMINESCENCE / CLIA)	6.43	ug/dl	4.5 - 12.7
TSH(CHEMILUMINESCENCE / CLIA)	↑ 6.68	μIU/mL	0.35 - 4.78

Interpretation :

1. TSH results between 4.5 to 15.0 show considerable physiologic and seasonal variation, suggest clinical correlation or repeat testing with fresh sample.
- 2.TSH results between 0.1 to 0.45 requires correlation with patient age and clinical symptoms. As with increasing age, there are marked changes in thyroid hormone production, metabolism and its action resulting in an increase prevalence of sub-clinical thyroid disease.
3. TSH values may be transiently altered because of non- thyroidal illness like severe infections, liver diseases, renal and heart failure, severe burns, trauma and surgery etc.
- 4.Drugs that decreased TSH values e.g. L-dopa, glucocorticoid. Drugs that increase TSH values e.g .Iodine, Lithium and amiodarone.

BIOCHEMISTRY


FASTING BLOOD GLUCOSE*

FASTING BLOOD GLUCOSE(FBS)(GOD-POD)	88.6	mg/dl	74.0 - 100.0
FASTING URINE GLUCOSE	NIL		

HEMATOLOGY

BLOOD GROUP RH "B" POSITIVE

CBC WITH ESR




Dr. Sweta Patel
MD (Pathology)
Verified By

Mrs. Neena Ravi Patel

Prepared by

Nr. St. Kabir School, Opp. Raneshwar Temple, Vasna Road, Vadodara-15

Patient Name : MRS. IPSITA RANI BEHERA
Age / Sex : 35Y 3M 26D/Female
IP/Reg.No/UHID : Reg-14260 /UHID14260
Lab No : LA24010349
Referred By : Dr.SAMANVAY HOSPITAL
Bedcategory/Bed :
Mobile No : 9178130971
UHID : UHID14260
Consultant : Mr. Samanvay Hospital
Sponsor : **MEDIWHEEL**
ABHA Address :
Barcode No. : **38035,38036,38037,38038**


Bill No : OPB/1/24/10973
Sample Collected : Nov 9 2024 9:39AM
Sample Received : Nov 9 2024 9:48AM
Report On : Nov 9 2024 9:48AM
Bill Creation Date : Nov 9 2024 9:04AM
Bar Code : 
Reg No : Reg-14260
IPNo :
Passport No. :
Verified On : **Nov 9 2024 12:01PM**
ABHA Num :

Test Name	Results	Units	Biological Reference
RBCS PARAMETER			
HAEMOGLOBIN(SLS METHOD)	↓ 8.3	g/dl	13.0 - 17.0
RBC COUNT(IMPEDENCE)	↓ 4.32	10 ⁶ /uL	4.50 - 5.50
PCV (HEAMATOCRIT)(IMPEDENCE)	↓ 29.1	%	40.0 - 50.0
MCV(CALCULATED)	↓ 67.4	fl	80.0 - 100.0
MCH(CALCULATED)	↓ 19.2	pg	27.0 - 33.0
MCHC(CALCULATED)	↓ 28.5	g/dl	32.0 - 36.0
RDW-CV(PARTICLE COUNTER(CALCULATED))	↑ 16.8	%	11.6 - 14.0
RDW-SD(PARTICLE COUNTER(CALCULATED))	41.0	fl	39 - 46
WBCS PARAMETER			
TOTAL COUNT(FLOW CYTOMETRY)	↓ 3070	/uL	4000 - 10000
DLC			
NEUTROPHILS(FLOW CYTOMETRY)	47	%	40 - 70
LYMPHOCYTES(FLOW CYTOMETRY)	↑ 43	%	20 - 40
MONOCYTES(FLOW CYTOMETRY)	07	%	2 - 8
EOSINOPHILS(FLOW CYTOMETRY)	03	%	1 - 4
BASOPHILS(FLOW CYTOMETRY)	00	%	0.0 - 1.0
ABSOLUTE NEUTROPHIL COUNT(CALCULATED)	↓ 1440.0	10 ³ /uL	2000.0 - 7000.0
ABSOLUTE LYMPHOCYTE COUNT(CALCULATED)	1320.0	10 ³ /uL	1000.0 - 3000.0
ABSOLUTE MONOCYTE COUNT(CALCULATED)	210.0	10 ³ /uL	200.0 - 1000.0
ABSOLUTE EOSINOPHIL COUNT(CALCULATED)	80.0	10 ³ /uL	20.0 - 500.0
PLATELETS PARAMETER			
PLATELET COUNT(IMPEDENCE)	↓ 97000	/uL	150000 - 450000
ESR	10	mm/hr	0 - 20

-----End of the Report-----

Mrs. Neena Ravi Patel

Prepared by



Dr. Sweta Patel
MD (Pathology)

Verified By

Nr. St. Kabir School, Opp. Raneshwar Temple, Vasna Road, Vadodara-15