



# MEDICOVER HOSPITALS

## MEDICAL HEALTH CHECK- UP ASSESMENT FORM

NAME : Mr /  Mrs K. Neha Sharma      DATE: 2/3/25

AGE : 35 y

SEX: Male /  Female

UMR NO : 542503000286

DOCTOR'S NAME:  
Health checkup

TEMP :	<u>96.3</u>	° f	BP :	<u>100/60</u>	mmHg
PULSE :	<u>75</u>	b/m	HEIGHT :	<u>154</u>	cm
RR :	<u>20</u>	b/m	WEIGHT :	<u>69.5</u>	kg
SPO2 :	<u>98</u>	%	HGT:	<u>-</u>	

REMARK:



hc 480  
39 Years

neha sharma  
Female

3/7/2025 12:08:36 PM

Rate 83 . Sinus rhythm.....normal P axis, V-rate 50- 99  
. Borderline intraventricular conduction delay.....QRSD >112ms  
PR 159 . Baseline wander in lead(s) V1,V4  
QRSD 114  
QT 372  
QTc 437

*WNL*  
↑

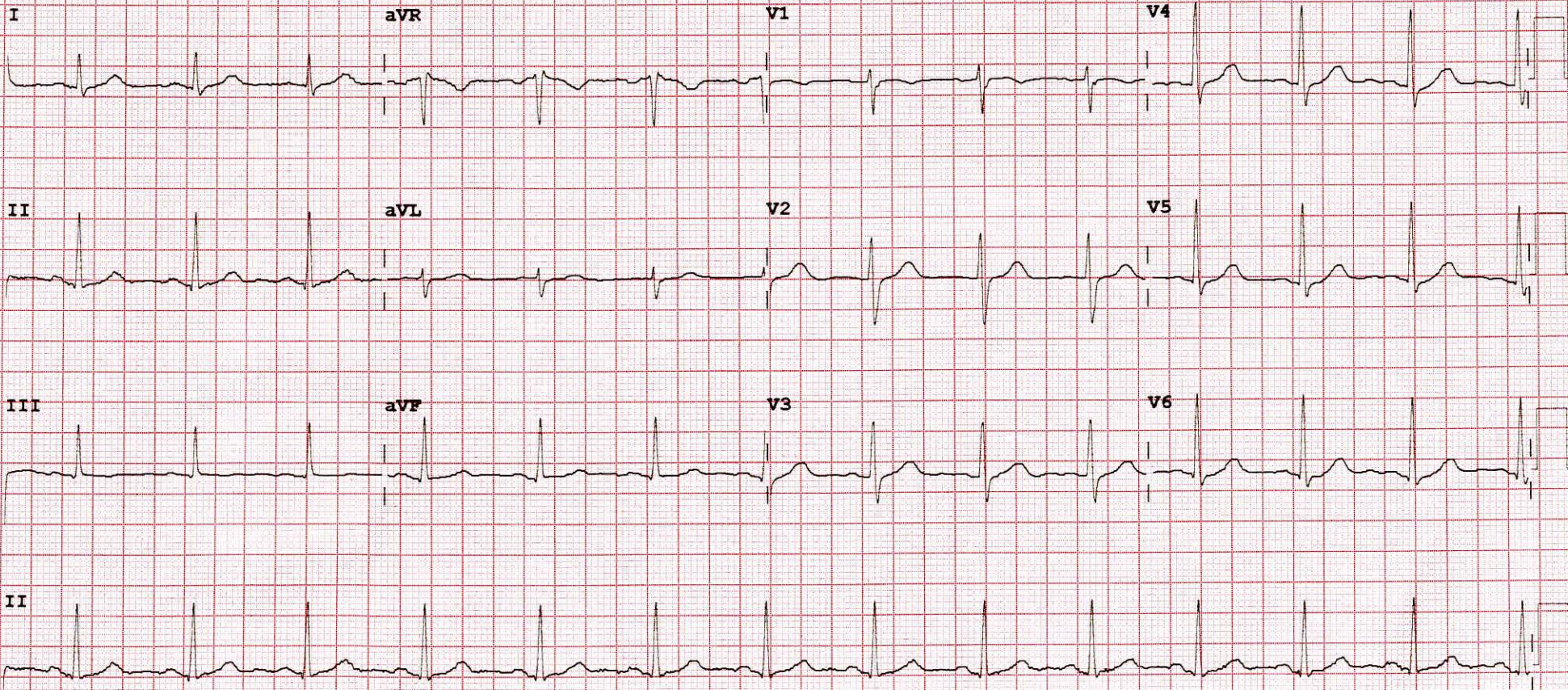
--AXIS--

P 56  
QRS 74  
T 30

- OTHERWISE NORMAL ECG -

12 Lead; Standard Placement

Unconfirmed Diagnosis





**OUT PATIENT DEPARTMENT**

<b>Patient Name</b> : Mrs. NEHA SHARMA	<b>UMR No</b> : 542503000486
<b>Age/Gender</b> : 39Years, 3Months/FEMALE	<b>Bill No</b> : HC542503000269_14 <b>Bill Dt</b> : 07-Mar-2025
<b>Mobile</b> : 9867254652	<b>Visit Dt.</b> : 07-Mar-2025 <b>Visit Type</b> : Single
<b>Organisation</b> : AROCFEMI HEALTHCARE PVT LTD (MEDIWHEEL)	

**Vitals :**

BP Sit	BP Stand	Weight	Height	HR	TEMP	Resp	SP02	BMI
100/60	0/	69.5	154	85	96.2	28	98	29.3

**Consultant :**

**DR.Anushree Sameer Vankar**

CONSULTANT

**Ophthalmology History :**

HEALTH CHECKUP

**Assessment And Plan :**

VN (PGP)(RE) : 6/6(B)N6 (LE): 6/6(B) N6  
 COLOUR VISION : (BE) NORMAL  
 REF : (RE) : -0.25DS --6/6 (LE) : -0.50DS--:6/6  
 ANT SEG (BE) - WNL DISC (BE) - 0.3

**Remarks :**

DILATED REFRACTION

**Rx :**

**TOTAL NO.OF MEDICINES: 1**

Medicine	Frequency	Route - Timing - Duration
1 REFRESH TEARS EYE DROP Dose/ Volume / Tablet : 1 DROP	1-1-1-1 Timing : --	LOCAL APPLICATION - Not Applicable - 1 Months

**DR.Anushree Sameer Vankar**

CONSULTANT



**OUT PATIENT DEPARTMENT**

<b>Patient Name</b> : Mrs. NEHA SHARMA	<b>UMR No</b> : 542503000486
<b>Age/Gender</b> : 39Years, 3Months/FEMALE	<b>Bill No</b> : HC542503000269_15 <b>Bill Dt</b> : 07-Mar-2025
<b>Mobile</b> : 9867254652	<b>Visit Dt.</b> : 07-Mar-2025 <b>Visit Type</b> : Single
<b>Organisation</b> : AROCFEMI HEALTHCARE PVT LTD (MEDIWHEEL)	

**Vitals :**

BP Sit	BP Stand	Weight	Height	HR	TEMP	Resp	SP02	BMI
100/60	0/	69.5	154	85	96.2	20	98	29.3

**Consultant :**  
**Dr. Binota Singh**  
BDS, eMBA  
CONSULTANT

**Final Diagnosis :**

gen gingivitis

**Chief Complaint :**

routine check up

**Assessment And Plan :**

stains and calculus

caries 38

**Advice :**

scaling and polishing

extraction 38

**Rx :**

**Dr. Binota Singh**  
BDS, eMBA  
CONSULTANT



<b>Patient ID:</b>	54250000486	<b>Patient Name:</b>	NEHA SHARMA 39YRS/F
<b>Age:</b>		<b>Sex:</b>	F
<b>Accession Number:</b>		<b>Modality:</b>	US
<b>Referring Physician:</b>	EHC	<b>Study:</b>	USG ABDOMEN
<b>Study Date:</b>	07-Mar-2025		

**USG WHOLE ABDOMEN (TAS)**

LIVER is normal in size, normal in shape and echotexture. No evidence of any focal lesion. The portal vein appears normal & shows normal hepato-petal flow. No evidence of intra-hepatic biliary duct dilatation.

GALL BLADDER appears distended with normal wall thickness. There is no obvious calculus or pericholecystic collection. CBD appears normal.

Visualised parts of head & body of PANCREAS appear normal.

SPLEEN is normal in size and echotexture. No focal lesion seen. Splenic vein is normal.

Both kidneys are normal in size, shape and echotexture with normal parenchymal reflectivity and maintained cortico-medullary differentiation. No hydronephrosis or calculi or mass seen.

URINARY BLADDER is adequately distended; no e/o wall thickening or mass or calculi seen.

UTERUS is retroverted and is normal in size, shape and echotexture; No focal lesion seen; ET measures – 7.8 mm.

Both ovaries are normal in size, shape and position.


Visualised bowel loops appear normal. There is no free fluid seen.

*NB:- This scan does not rule out all pathologies related to bowel and appendix.*

**IMPRESSION –**

- **No significant abnormality detected.**

THIS REPORT IS NOT TO BE USED FOR MEDICOLEGAL PURPOSE. THE CONTENTS OF THIS REPORT REQUIRE CLINICAL CO-RELATION BEFORE ANY APPLICATION.



**Dr. Ashwin Y.**  
M.D. (Radio-Diagnosis)



<b>Patient ID:</b>	542503000486	<b>Patient Name:</b>	NEHA SHARMA
<b>Age:</b>	39 Years	<b>Sex:</b>	F
<b>Accession Number:</b>	HC	<b>Modality:</b>	DX
<b>Referring Physician:</b>		<b>Study:</b>	CHEST
<b>Study Date:</b>	07-Mar-2025		

**X RAY CHEST PA VIEW**

Both lungs are clear.

The frontal cardiac dimensions are normal.

• pleural spaces are clear.

Both hilar shadows are normal in position and density.

No diaphragmatic abnormality is seen.

The soft tissues and bony thorax are normal.

**Impression:**

- **No significant abnormality is seen.**



**Dr. Ashwin Y.**  
M.D. (Radio-Diagnosis)





**MEDICOVER**  
HOSPITALS

NAVI MUMBAI

## 2D ECHO CARDIOGRAPHY WITH COLOR DOPPLER

Name : Mrs. Neha Sharma

Date:-07/03/2025

Age / Sex : 39 Yrs / Female

UMR No. 542503000480

Referred By : Health check up

### **FINDINGS:**

- No left ventricle regional wall motion abnormality.
- Normal left ventricle systolic function. LVEF = 60%.
- No left ventricle diastolic dysfunction. No e/o raised LVEDP.
- Trivial mitral regurgitation.
- No aortic regurgitation. No aortic stenosis.
- Mild tricuspid regurgitation. No pulmonary hypertension.  
PASP = 30 mmHg  
No left ventricle clot / vegetation / pericardial effusion.
- Intact IAS and IVS.
- Normal left atrium and left ventricle dimensions.
- Normal right atrium and right ventricle dimensions.
- Normal right ventricle systolic function. No hepatic congestion.

### **IMP:**

- No RWMA.
- Trivial MR . Mild TR. No PH.
- Normal LV and RV systolic function.

**DR RISHI BHARGAVA**  
**MD DM CARDIOLOGY**





**MEDICOVER**  
HOSPITALS

NAVI MUMBAI

**M-MODE MEASUREMENTS:**

LA	34	mm
AO root	29	mm
AO CUSP SEP	18	mm
LVID( s)	33	mm
LVID(d)	42	mm
IVS(d)	11	mm
LVPW(d)	10	mm
RVID(d)	29	mm
RA	31	mm
LVEF	60	%

	PEAK	MEAN	Vmax	Gradient of Regurgitation
MITRAL	N			Trivial
AORTIC	7			Nil
TRICUSPID	30			Mild
PULMONERY	4.1			Nil

