

MER- MEDICAL EXAMINATION REPORT

Date of Examination	09-11-2024		
NAME	MITHUN JAT		
AGE	34	Gender	Male
HEIGHT(cm)	180 CM	WEIGHT (kg)	72 kg
B.P.	120/70		
EKG	Normal		
X Ray	Normal		
Vision Checkup	Normal		
Present Ailments	-		
Details of Past ailments (If Any)	-		
Comments / Advice : She /He is Physically Fit	fit		
$BMI = 22.2 \text{ kg/m}^2 \text{ (Normal)}$			

Signature with Stamp of Medical Examiner

Dr. Mukesh Dubey  
(MBBS DCP)  
Registration No.-10632

Panel Medical Examiner  
Triveni Diagnostic & Research Centre  
Agrawal Plaza, B-7, H.I.G Main Road,  
INDORE



भारतीय विशिष्ट ओळख प्राधिकरण  
 भारत सरकार  
 Unique Identification Authority of India  
 Government of India

नोंदविण्याचा क्रमांक / Enrollment No 1169/21066/13913

To,  
 मिथुन जाट  
 Mithun Jat  
 Gaon- Magraniya, Taluka- Shujalpur, Post- Unchod  
 Shujalpur  
 Shujalpur Mandir Shujalpur Shajapur  
 Madhya Pradesh 465333

05/05/2013

Ref: 5229 / 231 / 293936 / 293936 / P



SH327949485F1



आपला आधार क्रमांक / Your Aadhaar No. :

**9922 6371 9329**

आधार - सामान्य माणसाचा अधिकार



भारत सरकार  
 Government of India



मिथुन जाट  
 Mithun Jat  
 जन्म वर्ष / Year of Birth : 1990  
 पुरुष / Male



9922 6371 9329

आधार - सामान्य माणसाचा अधिकार

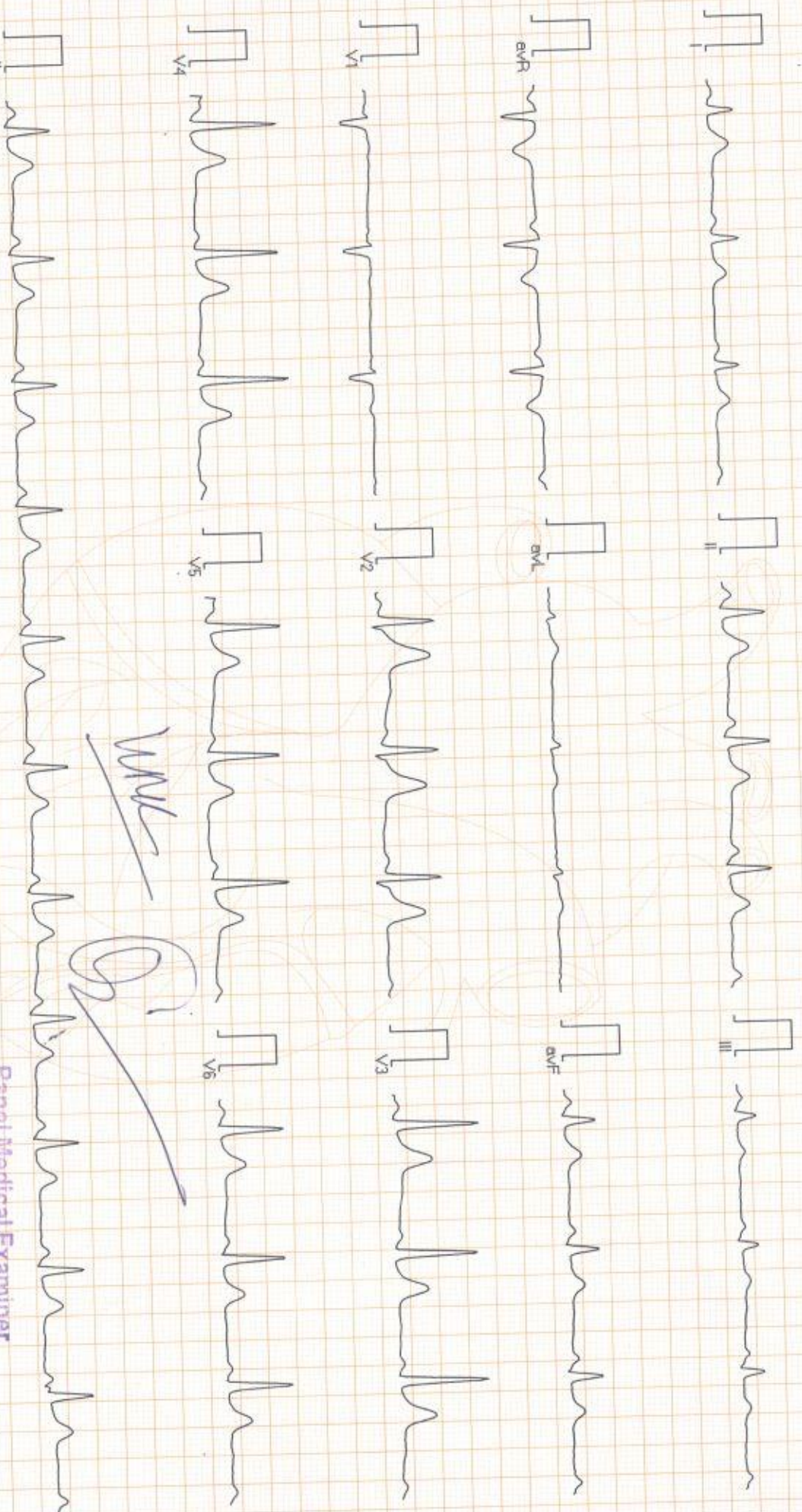Panej Medical Examiner  
 Panjoni Diagnostic & Research Centre  
 Rawal Plaza, B-7, H.I.G. Main Road,  
 INDORE

ECG



TRIVENI DIAGNOSTIC AND RESEARCH CENTER INDORE

1340 / MR. MITHUN JAT / 34 Yrs / M/ Non Smoker  
Heart Rate : 68 bpm / Tested On : 09-Nov-24 11:11:51 / HF 0.05 Hz - LF 20 Hz / Notch 50 Hz / Sn 1.00 Cm/mV / Sw 25 mm/s



*MM*  
*Gi*

Vent Rate : 68 bpm  
PR Interval : 130 ms  
QRS Duration: 84 ms  
QT/QTc Int : 380/394 ms  
P-QRS-T axis: 66.00 • 56.00 • 52.00 •

Panel Medical Examiner

Triveni Diagnostic & Research Centre  
Kajwala Plaza, B-7, HLG Main Road,  
INDORE

Reported By:

# डॉ. मनोज भटनागर

एम.एस.

नेत्र रोग विशेषज्ञ एवं सर्जन



CGI wear

Reg. No. 5453

Rx Mithun Jai  
34 yrs

## विशेषज्ञ

- इन्ट्राऑक्यूलर लेंस इम्प्लांट
- फेको विधि द्वारा बगैर टांके का मोतियाबिंद ऑपरेशन
- कॉन्टेक्ट लेंस विशेषज्ञ
- लेसिक लेजर (चश्मा उतारने की विधि)

दिनांक 9-11-24

Vis on  $\left\{ \begin{array}{l} 6/6 \\ 6/6 \end{array} \right.$

Near Vis on  $N/6$

Colour Vis on Normal

Ext Exam: NAD

Findings  Physiological changes +

# Dr. Bhatnagar's Multispeciality Dental Clinic

**Dr. Nikita Bhatnagar**

B.D.S., M.D.S. (Gold Medalist)

Reg. No. A-3503

Mob. : 96699-37000

Clinic: E-4, HIG Colony, HIG Main Road  
Indore-452011 (M.P.)

**डॉ. निकिता भटनागर**

बी.डी.एस., एम.डी.एस., (गोल्ड मेडलिस्ट)

रजि. नं. ए-3503

मो. : 96699-37000

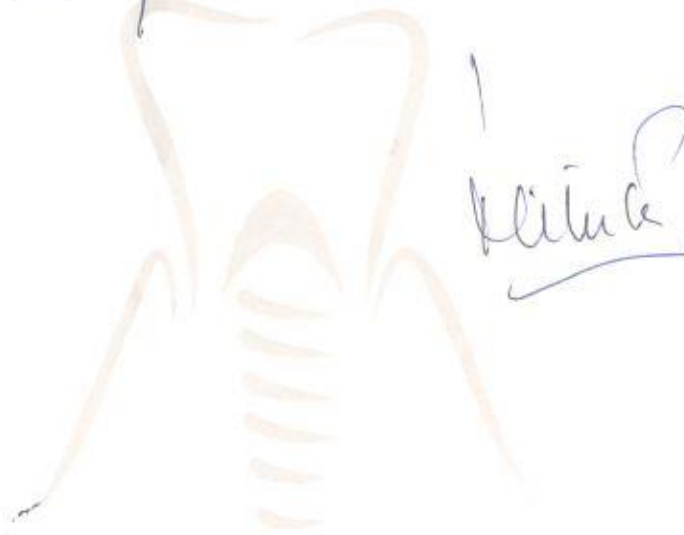क्लिनिक: ई-4, एच.आई.जी. कॉलोनी, एच.आई.जी. मेन रोड  
इन्दौर-452011 (म.प्र.)

Mr. Mithun Jat

Date..... 09/11/2022

Rs. Colgate toothpaste

— brushes for mlu.



## COSMETIC DENTISTRY

- Smile designing
- Teeth whitening & bleaching
- Tooth jewellery
- Composite & ceramic veneers
- Invisalign / Orthodontic braces
- Tooth colored fillings

## GENERAL DENTISTRY

- Instant Dental X-rays
- Root Canal Treatment
- Gum treatment
- Atraumatic Extractions
- Wisdom tooth treatment
- Crown and bridges

## PREVENTIVE DENTISTRY

- Teeth cleaning & polishing
- Fluoride application
- Treatment for Precancerous
- Conditions & lesions
- Tobacco chewing habit cessation

## GERIATRIC DENTISTRY

- Dental Implants
- Dentures
- Oro-facial pain
- TMJ Disorders
- Snoring while sleeping

Adv: Complete oral prophylaxis.

Tituli



# Triveni Diagnostic Centre

Reg No. : 98589 VISITID : 0000103217  
PATIENT NAME : Mr. MITHUN JAT SPEC. NO : 1905432891  
AGE/SEX : 34 YEARS/MALE SAMP. DATE : 09/11/2024 12:31:00  
REF. BY : Dr. ARCOFEMI HEALTHCARE LIMITED RESULT DATE : 09/11/2024 19:06:35

## HEMATOLOGY

### CBC (COMPLETE BLOOD COUNT)

NAME OF TEST	RESULT VALUE	REFERENCE RANGE	UNIT
HAEMOGLOBIN	13.8	13.5 - 18	gm/dl
TOTAL RBC COUNT	4.29	4 - 5.5	mill/cummm
HAEMATOCRIT (PCV)	40.8	41.5 - 50.4	%
MEAN CORPUS VOL(MCV)	95.1	80 - 96	f l
MEAN CORPUS HB (MCH)	32.17	27.5 - 33.2	picograms
MEAN CORPUS HB CONC (MCHC)	33.82	33.4 - 35.5	%
RDW	12.3	11.5 - 15.5	%
PDW	14.9	-	f l
MPV	7.7	-	f l
PCT	0.19	-	%
P-LCR	19.0	-	%
TOTAL WBC	5700	4000 - 11000	/cumm
PLATELET COUNT	2.57	1.5 - 4.0	Lacs/cumm
<b>DIFFERENTIAL COUNT</b>			
NEUTROPHILS	62	40 - 70	%
LYMPHOCYTES	33	20 - 40	%
MONOCYTES	02	1 - 8	%
EOSINOPHILS	03	0 - 5	%
BASOPHILS	00	0 - 1	%
ABSOLUTE NEUTROPHILS	3534	4000 - 7500	/cumm
ABSOLUTE LYMPHOCYTES	1881	800 - 4950	/cumm
ABSOLUTE MONOCYTE	114	0 - 880	/cumm
ABSOLUTE EOSINOPHIL	171	40 - 400	/cumm
ABSOLUTE BASOPHIL	00	0 - 110	/cumm
ESR	12	0 - 20	mm at end of 1
MP (MALARIA PARASITE)	.	-	

METHOD:- By five part automated analyzer (sysmex XS1000 i) Japan

**DR. MUKESH DUBEY**  
(MBBS, DCP) (DIRECTOR)

**DR. VIJAY BHURIYA**  
MBBS DMRD

**DR. YOGESH PAWDE**  
M. D. (CONS. PATHOLOGIST)

**DR. P.S. TRIPATHI**  
M.D. (RADIO DIAGNOSIS)

**DR. SANJAY YADAV**  
CON. MICROBIOLOGIST

Report Checked By:

Address : Agrawal Plaza, B-7, HIG Main Road, Indore Ph. : 0731-4289992-3  
Website : www.trivenidiagnostic.com email : trivenidiagnostic@yahoo.co.in

Page 1 of 1



# Triveni Diagnostic Centre

Reg No. : 98589 VISITID : 0000103217  
PATIENT NAME : Mr. MITHUN JAT SPEC. NO : 1905432887  
AGE/SEX : 34 YEARS/MALE SAMP. DATE : 09/11/2024 12:31:00  
REF. BY : Dr. ARCOFEMI HEALTHCARE LIMITED RESULT DATE : 09/11/2024 19:07:09


NAME OF TEST	RESULT VALUE		REFERENCE RANGE	UNIT
	IN RANGE	OUT RANGE		

## PERIPHERAL SMEAR EXAMINATION

PERIPHERAL SMEAR

### REMARKS :

- Rbcs are normocytic normochromic.
- Wbcs are normal in number and morphology.
- Platelets are adequate on smear and normal in morphology.
- No hemoparasite is seen.



DR. MUKESH DUBEY  
(MBBS, DCP) (DIRECTOR)

DR. VIJAY BHURIYA  
MBBS DMRD

DR. YOGESH PAWDE  
M. D. (CONS. PATHOLOGIST)

DR. P.S. TRIPATHI  
M.D. (RADIO DIAGNOSIS)

DR. SANJAY YADAV  
CON. MICROBIOLOGIST

Report Checked By :

Address : Agrawal Plaza, B-7, HIG Main Road, Indore Ph. : 0731-4289992-3  
Website : www.trivenidiagnostic.com email : trivenidiagnostic@yahoo.co.in





# Triveni Diagnostic Centre

Reg No. : 98589 VISITID : 0000103217  
PATIENT NAME : Mr. MITHUN JAT SPEC. NO : 1905432893  
AGE/SEX : 34 YEARS/MALE SAMP. DATE : 09/11/2024 12:31:00  
REF. BY : Dr. ARCOFEMI HEALTHCARE LIMITED RESULT DATE : 09/11/2024 19:03:42

## DEPARTMENT OF PATHOLOGY

NAME OF TEST	RESULT VALUE	REFERENCE RANGE	UNIT
<b>BLOOD GROUP</b>			
BLOOD GROUP	"O"	-	
RH FACTOR	Positive	-	
<b>RESULT REMARKS :</b>			
<b>FBS</b>			
FBS	99	70 - 110	mg / dl
<b>RESULT REMARKS :</b>	Test done by -"Roche COBAS- ENTEGRA 400 PLUS "fully bichemistry analyser .		
<b>PPBS</b>			
PPBS (POST PRANDIAL BLOOD SUGAR)	121	70 - 140	mg / dl
<b>RESULT REMARKS :</b>	Test done by -"Roche COBAS- ENTEGRA 400 PLUS "fully bichemistry analyser .		
<b>RENAL PROFILE</b>			
UREA	24	10 - 40	mg / dl
CREATININE	0.91	0.7 - 1.4	mg / dl
SERUM SODIUM	141.2	135 - 155	mmol/L
SERUM POTASIUM	4.01	3.5 - 5.5	mmol/L
<b>RESULT REMARKS :</b>			

DR. MUKESH DUBEY  
(MBBS, DCP) (DIRECTOR)

DR. VIJAY BHURIYA  
MBBS DMRD

DR. YOGESH PAWDE  
M. D. (CONS. PATHOLOGIST)

DR. P.S. TRIPATHI  
M.D. (RADIO DIAGNOSIS)

DR. SANJAY YADAV  
CON. MICROBIOLOGIST

Report Checked By :



# Triveni Diagnostic Centre

Reg No. : 98589 VISITID : 0000103217  
PATIENT NAME : Mr. MITHUN JAT SPEC. NO : 1905432892  
AGE/SEX : 34 YEARS/MALE SAMP. DATE : 09/11/2024 12:31:00  
REF. BY : Dr. ARCOFEMI HEALTHCARE LIMITED RESULT DATE : 09/11/2024 19:04:15

## BIO-CHEMISTRY

### HBA1 C (GLYCOSYLATED HEAMOGLOBIN)

NAME OF TEST	RESULT VALUE	REFERENCE RANGE	UNIT
HBA1 C (GLYCOSYLATED HEAMOGLOBIN)	5.8	Normal: 4-6 Good control: 6.1-7.0 Fair control: 7.0-8.2 Unsatisfactory control: 8.0-10.2 Poor control: Above 10.0	%
MEAN PLASMA GLUCOSE (MPG)	120	Excellent Control: 90-120 Good Control: 121-150 Average Control: 151-180 Action Suggested: 181-210 Panic value: >211	mg/dL

Test done by - "Roche COBAS- ENTEGRA 400 PLUS" fully biochemistry analyser .

METHOD BY: Turbidimetric inhibition immunoassay (TINIA)

Average blood glucose value is calculated from HBA1C value and indicates average blood sugar level over past three months.

DR. MUKESH DUBEY  
(MBBS, DCP) (DIRECTOR)

DR. VIJAY BHURIYA  
MBBS DMRD

DR. YOGESH PAWDE  
M. D. (CONS. PATHOLOGIST)

DR. P.S. TRIPATHI  
M.D. (RADIO DIAGNOSIS)

DR. SANJAY YADAV  
CON. MICROBIOLOGIST

Report Checked By:

Address : Agrawal Plaza, B-7, HIG Main Road, Indore Ph. : 0731-4289992-3  
Website : www.trivenidiagnostic.com email : trivenidiagnostic@yahoo.co.in

Page 1 of 1



# Triveni Diagnostic Centre

Reg No. : 98589 VISITID : O000103217  
PATIENT NAME : Mr. MITHUN JAT SPEC. NO : 1905432889  
AGE/SEX : 34 YEARS/MALE SAMP. DATE : 09/11/2024 12:31:00  
REF. BY : Dr. ARCOFEMI HEALTHCARE LIMITED RESULT DATE : 09/11/2024 19:04:46

NAME OF TEST	RESULT VALUE		REFERENCE RANGE	UNIT
	IN RANGE	OUT RANGE		
<b>LFT (LIVER FUNCTION TEST)</b>				
TOTAL BILIRUBIN	0.69		0.2 - 1.3	mg/dL
DIRECT BILIRUBIN	0.34		0.2 - 0.65	mg / dl
INDIRECT BILIRUBIN	0.35		0.2 - 0.8	mg / dl
SGOT(AST)	28		0 - 40	U / L
SGPT(ALT)	18		0 - 40	U / L
ALKALINE PHOSPHATASE	101		37 - 143	U / L
PROTEINS	7.10		6 - 8.3	g / dl
ALBUMIN	4.23		3.5 - 5	gm/dl
GLOBULIN	2.87		1.9 - 3.5	g / dl
A.G.RATIO	1.47		0.5 - 2	mg / dl
PT (PROTHROMBIN TIME)		14	-	seconds
CONTROL		14	-	seconds
(INR) INTERNATIONALNARMLISED RATIO		1.0	-	.

**REMARKS :**

METHOD: BY COBAS INTEGRA 400 PLUS.

**DR. MUKESH DUBEY**  
(MBBS, DCP) (DIRECTOR)

**DR. VIJAY BHURIYA**  
MBBS DMRD

**DR. YOGESH PAWDE**  
M. D. (CONS. PATHOLOGIST)

**DR. P.S. TRIPATHI**  
M.D. (RADIO DIAGNOSIS)

**DR. SANJAY YADAV**  
CON. MICROBIOLOGIST

Report Checked By :

Address : Agrawal Plaza, B-7, HIG Main Road, Indore Ph. : 0731-4289992-3  
Website : www.trivenidiagnostic.com email : trivenidiagnostic@yahoo.co.in



# Triveni Diagnostic Centre

Reg No. : 98589 VISITID : 0000103217  
PATIENT NAME : Mr. MITHUN JAT SPEC. NO : 1905432889  
AGE/SEX : 34 YEARS/MALE SAMP. DATE : 09/11/2024 12:31:00  
REF. BY : Dr. ARCOFEMI HEALTHCARE LIMITED RESULT DATE : 09/11/2024 19:05:15

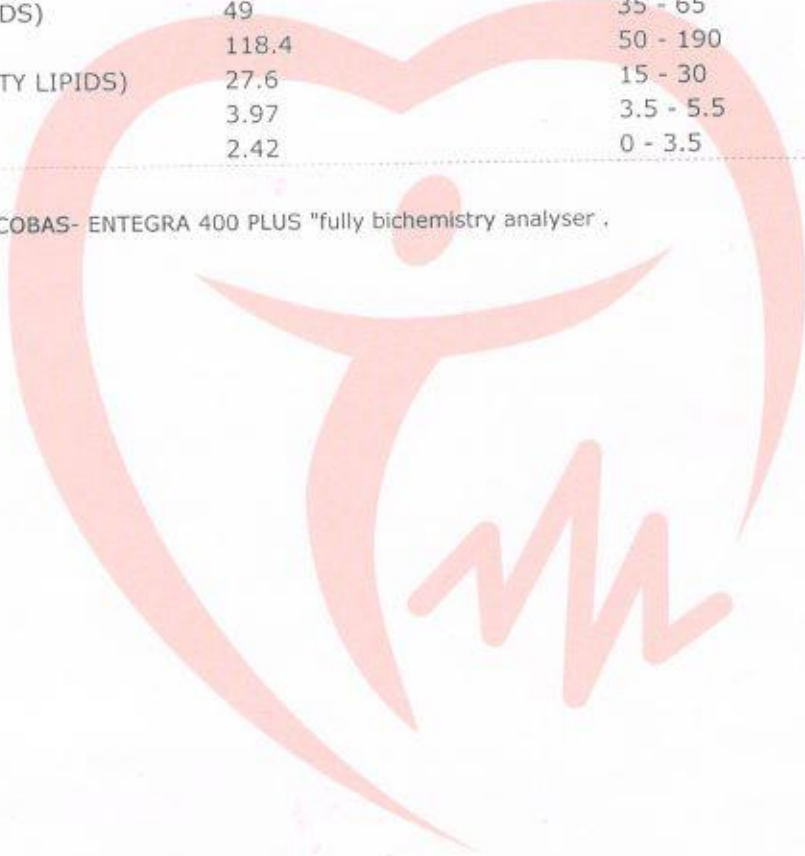
NAME OF TEST	RESULT VALUE		REFERENCE RANGE	UNIT
	IN RANGE	OUT RANGE		

## LIPID PROFILE

CHOLESTEROL	195		0 - 200	mg / dl
TRIGLYCERIDES	138		50 - 190	mg / dl
HDL(HIGH DENSITY LIPIDS)	49		35 - 65	mg / dl
LDL	118.4		50 - 190	mg / dl
VLDL (VERY LOW DENSITY LIPIDS)	27.6		15 - 30	mg / dl
Cholestrol : HDL	3.97		3.5 - 5.5	
LDL : HDL	2.42		0 - 3.5	mg / dl

## REMARKS :

Test done by -"Roche COBAS- ENTEGRA 400 PLUS "fully bichemistry analyser ,



DR. MUKESH DUBEY  
(MBBS, DCP) (DIRECTOR)

DR. VIJAY BHURIYA  
MBBS DMRD

DR. YOGESH PAWDE  
M. D. (CONS. PATHOLOGIST)

DR. P.S. TRIPATHI  
M.D. (RADIO DIAGNOSIS)

DR. SANJAY YADAV  
CON. MICROBIOLOGIST

Report Checked By :

Address : Agrawal Plaza, B-7, HIG Main Road, Indore Ph. : 0731-4289992-3  
Email : trivenidiagnostic@yahoo.co.in



# Triveni Diagnostic Centre

Reg No. : 98589 VISITID : 0000103217  
PATIENT NAME : Mr. MITHUN JAT SPEC. NO : 1905432890  
AGE/SEX : 34 YEARS/MALE SAMP. DATE : 09/11/2024 12:31:00  
REF. BY : Dr. ARCOFEMI HEALTHCARE LIMITED RESULT DATE : 09/11/2024 19:06:15

## CLINICAL-PATHOLOGY

### URINE EXAMINATION

NAME OF TEST	RESULT VALUE	REFERENCE RANGE	UNIT
<b>PHYSICAL EXAMINATION</b>			
QUANTITY	30	-	ml
COLOUR	Pale Yellow	-	
APPEARANCE	Clear	-	
REACTION	Acidic	-	
Specific Gravity	1.010	-	
<b>CHEMICAL EXAMINATION</b>			
ALBUMIN	Nil	-	
URINE SUGAR	Nil	-	
Ketone Bodies	Nil	-	
BLOOD	Nil	-	
Bile Pigment	Nil	-	
Bile Salts	Nil	-	
<b>MICROSCOPIC EXAMINATION</b>			
Pus Cells	3-4 /hpf	2 - 5	/hpf
Epithelial Cells	2-3 /hpf	5 - 10	/hpf
RBCs	Nil	-	
Casts	Nil	-	
Crystals	Nil	-	
Spermatozoa	Nil	-	
Bacteria	Nil	-	
Others		-	

DR. MUKESH DUBEY  
(MBBS, DCP) (DIRECTOR)

DR. VIJAY BHURIYA  
MBBS DMRD

DR. YOGESH PAWDE  
M. D. (CONS. PATHOLOGIST)

DR. P.S. TRIPATHI  
M.D. (RADIO DIAGNOSIS)

DR. SANJAY YADAV  
CON. MICROBIOLOGIST

Report Checked By:

Address : Agrawal Plaza, B-7, HIG Main Road, Indore Ph. : 0731-4289992-3  
Website : www.trivenidiagnostic.com email : trivenidiagnostic@yahoo.co.in

Page 1 of 1



# Triveni Diagnostic Centre

Reg. No. : 98589 Visit ID : 0000103217  
Patient Name : Mr. MITHUN JAT  
Age / Sex : 34 YEARS / MALE Order Date : 09/11/24 12:24PM  
Ref. By : Dr. ARCOFEMI HEALTHCARE LIMITED Report Date : 09/11/24 02:08PM

## X-RAY X-RAY CHEST PA

Left sided 4th rib appears bifid.

Trachea is central.

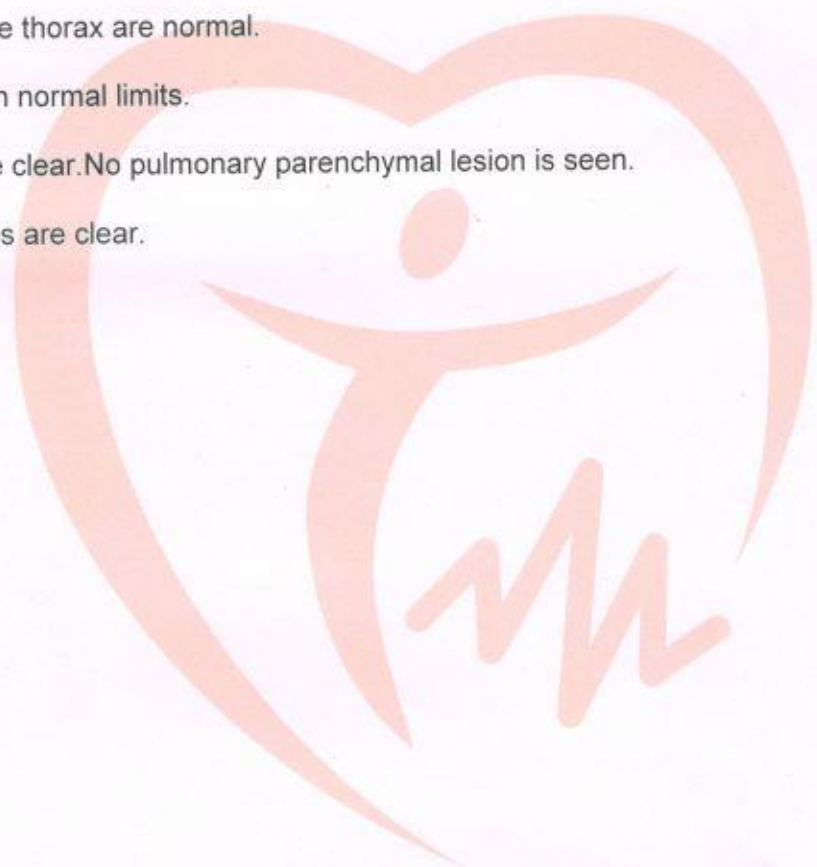
Soft tissue wall of the thorax are normal.

Cardiac size is within normal limits.

Both lungs fields are clear.No pulmonary parenchymal lesion is seen.

Costo-phrenic angles are clear.

Kindly correlate.



**DR. MUKESH DUBEY**  
(MBBS, DCP)

**DR. VIJAY BHURIYA**  
MBBS DMRD

**DR. AMIT SHANKHWAR**  
M.D. RADIO DIAGNOSIS

**DR. P.S.TRIPATHI**  
M.D.(RADIO DIAGONOSIS)

**DR. SANJAY YADAV**  
CONSULTANT MICROBIOLOGIST



# Triveni Diagnostic Centre

Reg. No. : 98589 Visit ID : 0000103217  
Patient Name : Mr. MITHUN JAT  
Age / Sex : 34 YEARS / MALE Order Date : 09/11/24 12:24PM  
Ref. By : Dr. ARCOFEMI HEALTHCARE LIMITED Report Date : 09/11/24 02:03PM

## SONOGRAPHY

### USG WHOLE ABDOMEN(MALE)

Liver is normal in size 12.3cm , shape and echotexture. No focal parenchymal lesion noted. Portal vein is of normal caliber. There is no evidence of dilatation of Intra and extra hepatic biliary radicals.

Gall bladder appears normal. **Approx 7.5mm size isoechoic structure seen adhere to anterior wall & 4.5mm size similar structure seen at posterior wall of gall bladder S/O small polyps.** Its walls are smooth and normal in wall thickness.

Pancreas is normal in size, shape and shows normal echogenecity, no localised solid or cystic mass is identified in pancreas. Pancreatic duct is not dilated.

Spleen is normal in size 9.9cm , and shows normal echogenecity, no localised or cystic mass is identified in spleen.

Both kidneys are normal in size (Rt. 10.9 x 5.3 cm & Lt. 9.7 x 5.3 cm), shape and echotexture. There is no evidence of dilation of collecting system of either of the kidney. Ureters are not dilated.

Visualised bowel loops appear normal.  
No evidence of any adenopathy or ascitis.

Urinary bladder is adequately filled with anechoic contents. The wall appears thin with smooth mucosa.

Prostate appears normal in size , shape and echotexture.

### IMPRESSION:- Gall bladder polyps.

Kindly correlate.

DR. MUKESH DUBEY  
(MBBS, DCP)

DR. VIJAY BHURIYA  
MBBS DMRD

DR. AMIT SHANKHWAR  
M.D. RADIO DIAGNOSIS

DR. P.S. TRIPATHI  
M.D. (RADIO DIAGNOSIS)

DR. SANJAY YADAV  
CONSULTANT MICROBIOLOGIST



# Triveni Diagnostic Centre

Reg. No. : 98589

Visit ID : 0000103217

Patient Name : Mr. MITHUN JAT

Age / Sex : 34 YEARS / MALE

Order Date : 09/11/24 12:24PM

Ref. By : Dr. ARCOFEMI HEALTHCARE LIMITED

Report Date : 09/11/24 02:21PM

## CARDIOLOGY

### 2D ECHO

**INTERPRETATION:- Normal 2-D Echo / Dopplar.**

**No LV RWMA seen.**

**LVEF IS 65 %.**

**2 IMAGING M** Mode examination revealed normal movement of both mitral leaflets during diastole. No SAM or mitral valve prolapsed is seen. Aortic cups are normal and enclosure line is central. Tricuspid valve is normal. Pulmonary valve is normal. Aortic root is normal in size.

Dimension of left atrium and left ventricles are normal.

**3. Dimaging in PLAX.SAX** and apical views revealed a normal left ventricle. Movement of septum anterior, posterior, inferior and lateral walls is normal. Global LVEF 65%. mitral valve opening is normal. No evidence of mitral valve prolapsed is seen. Aortic valve has three cups and its opening is not restricted. Right atrium & right ventricle are normal sized. Tricuspid valve leaflets move normally. Pulmonary valve is normal. Interatrial and intraventricular septa are intact. No intracardiac mass or thrombus is seen. No pericardial pathology is observed.

**Dr. RAHUL TALATI MD**

**DR. MUKESH DUBEY**  
(MBBS, DCP)

**DR. VIJAY BHURIYA**  
MBBS DMRD

**DR. AMIT SHANKHWAR**  
M.D. RADIO DIAGNOSIS

**DR. P.S. TRIPATHI**  
M.D. (RADIO DIAGNOSIS)

**DR. SANJAY YADAV**  
CONSULTANT MICROBIOLOGIST



Mr. Mithun Jat 09/11/2024

**Valve**

Aortic root diameter	2.8cms	2.0-3.7cm<2.2cm/M2
Aortic valve opening	1.8cms	1.5-2.6cm
Right ventricular dimension	2.0cms	0.7-2.5cm<2.2cm/M2
Left atrium dimension	3.4cms	1.9-4.0cm<2.2cm/M2
Left ventricular ED dimension	4.4cms	3.7-5.6cm<3.2cm/M2
Left ventricular ES dimension	2.7cms	2.2-4.0cm
Intraventricular ED septal thickness	0.9cms	0.6-1.2 cm
Left vent ED PW thickness	0.9cms	0.5- 1.0 cm
IVS/LVPW	<N	<1.3

**INDICES OF LEFT VENTRICLE FUNCTION:**

Mitral E – septal separation	.5	cms <0.9 cm
LV Ejection Fraction	65%	60 %- 80%

**COLOR DOPPER**

	PV(m/sec)	PG(mm of Hg)	Regurgitation
AV	1.5	9.06	NIL
MV	0.8	2.75	NIL
TV	N	N	NIL
PV	1.15	5.25	NIL

