

Patient Name : MRS. MITTAL ARPITA
Age : 36 YEARS
REF : MEDIBUDDY

ID No :55471
Sex :FEMALE
Date :15/02/2025

2D ECHOCARDIOGRAPHY & COLOR DOPPLER REPORT

DIMENSIONS (M MODE)

LA	27	mm
AO	24	mm
LVID (d)	43	mm
LVID (s)	27	mm
IVS(d)	7	mm
IVS(s)	11	mm
LVPW (d)	9	mm
LVPW(s)	13	mm

2 D ECHOCARDIOGRAPHY & DOPPLER FINDINGS:

ALL CARDIAC CHAMBERS ARE NORMAL IN DIMENSIONS

NO RWMA

LVEF = 60 %

GOOD LV SYSTOLIC FUNCTION

NORMAL LV DIASTOLIC FUNCTION

AORTIC VALVE – NORMAL OPENING.NO AR.NO AS.

MITRAL VALVE – NORMAL IN STRUCTURE AND MOBILITY, TRIVIAL MR

TRIVIAL TR

IVC NORMAL IN SIZE AND COLLAPSING WITH RESPIRATION

IAS/IVS INTACT

NO PULMONARY HYPERTENSION

Patient Name : MRS. MITTAL ARPITA
Age : 36 YEARS
REF : MEDIBUDDY

ID No :55471
Sex :FEMALE
Date :15/02/2025

NO CLOTS/ VEGETATIONS/EFFUSION.

CONCLUSIONS:

NORMAL LV SYSTOLIC FUNCTION (LVEF = 60 %)

NO RWMA

NORMAL LV DIASTOLIC FUNCTION

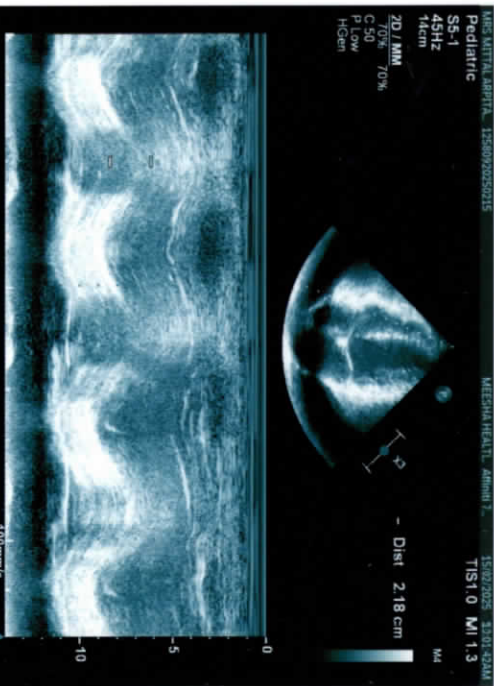
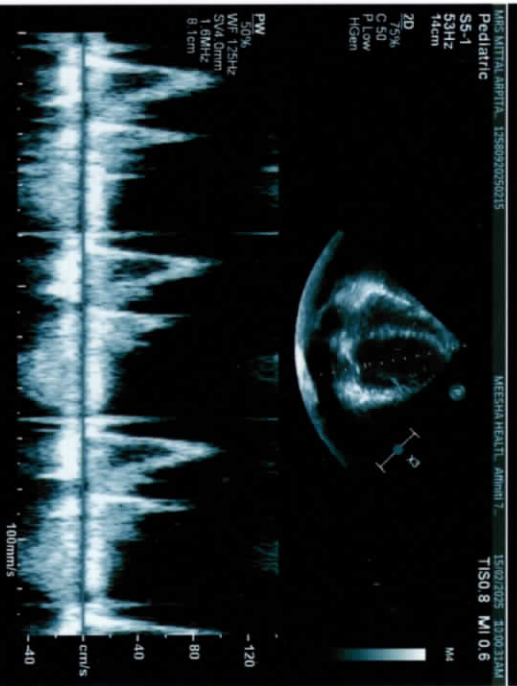
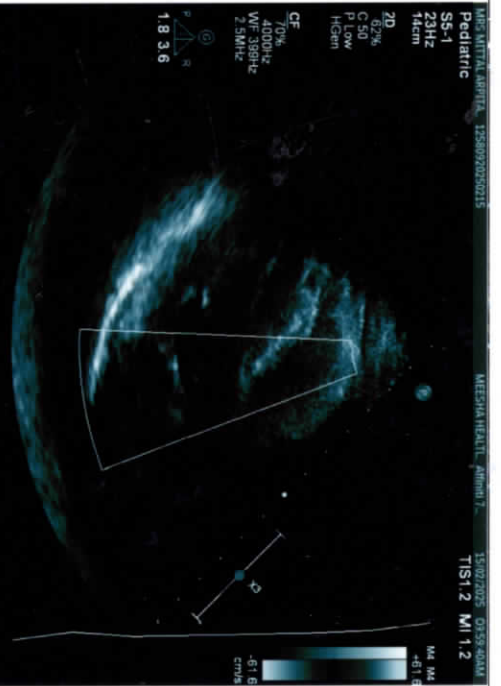
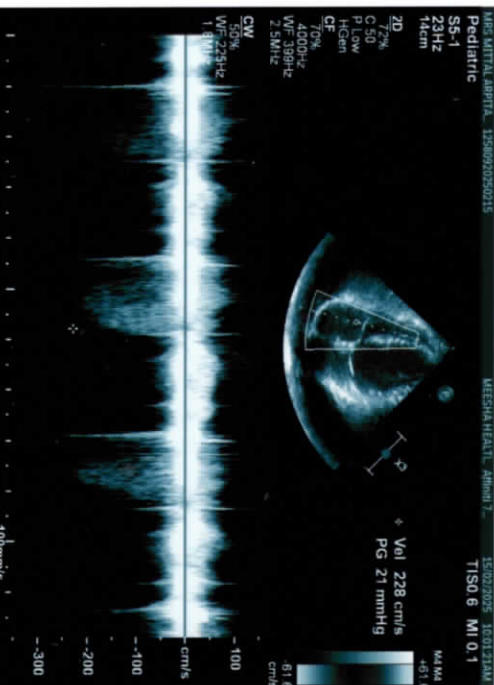
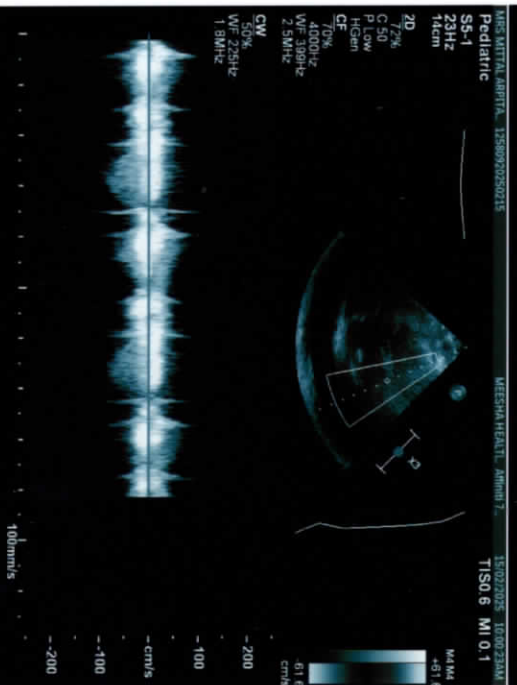
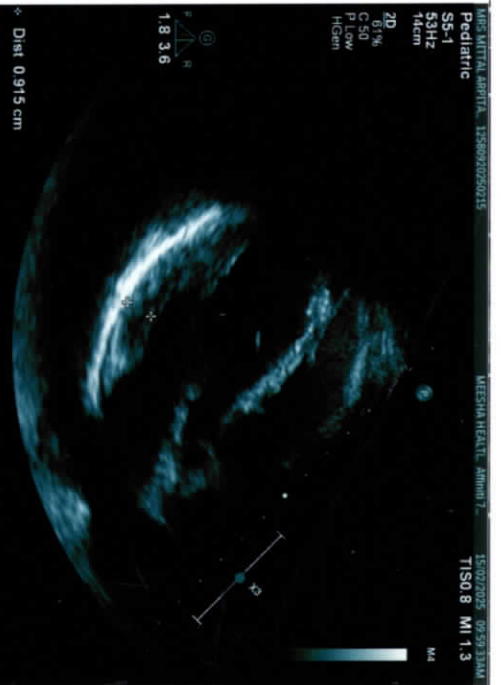
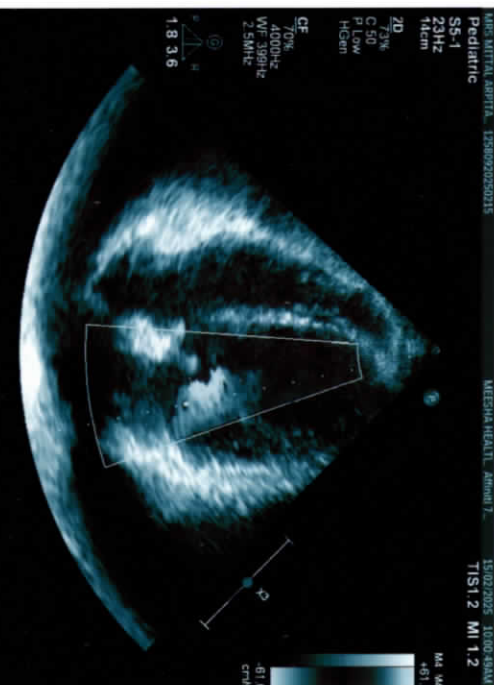
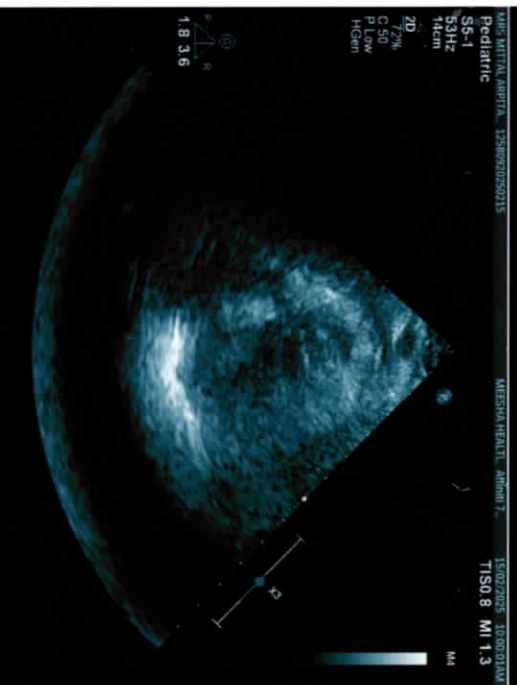
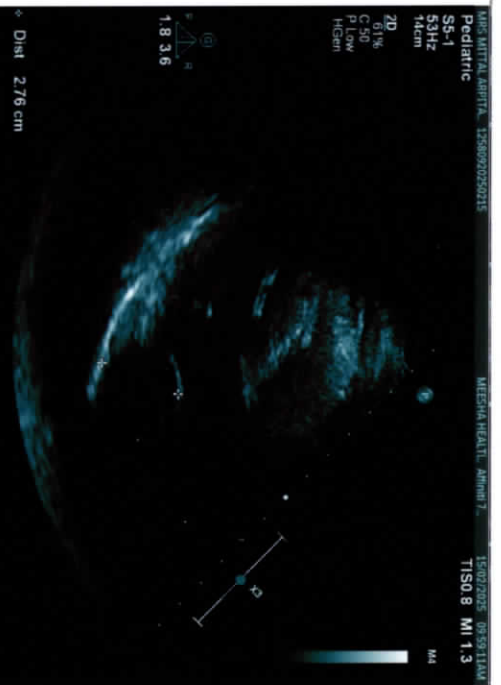
NORMAL VALVES. TRIVIAL MR,TR.

NO PULMONARY HYPERTENSION



DR. SHAIKH SALMAN
MD DM CARDIOLOGY
Interventional Cardiologist
MMC 2015/05/2270

DR SHAIKH SALMAN
MBBS, MD (MED), DM (CARDIOLOGY)
Consultant Interventional Cardiologist





MEESHA
DIAGNOSTICS AND POLYCLINIC

1st Floor, La View, B. J. Marg, Jacob Circle,
Mahalaxmi, Mumbai-400 011.
Tel. : +91 22 2305 3536 / 6538 3536
info@meeshahealth.com | www.meeshahealth.com

Timings : Monday to Saturday : 8.00 am to 9.00 pm

DENTAL PROFILE

15/2/2025

Dear Sir / Madam,

We have examined your teeth and oral cavity and we recommend the following

NAME Aspita Mittal Age : 36/F

1. Extraction of _____ teeth
2. Restorative treatment of _____ teeth
 - a) Crown _____
 - b) fillings
 - i) Silver _____
 - ii) Composite _____
 - iii) Inlays _____
 - c) Root canal fillings _____
3. Scaling and Gum Treatment _____
4. Replacement of _____ teeth
 - a) Removable _____
 - b) Fixed _____
 - c) Implant _____
5. Orthodontics _____
6. X-rays a) Dental _____ b) Orthopantomogram _____
7. Any Others _____

8. Remarks fastan (+) → Adv scaling
Spacing (+)
8/8
8/8 erupted. To observe



15-02-2025 10:50:08 AM
 ID: 55471
 MRS MITTAL ARPITA
 Female 26Years
 159cm 56kg

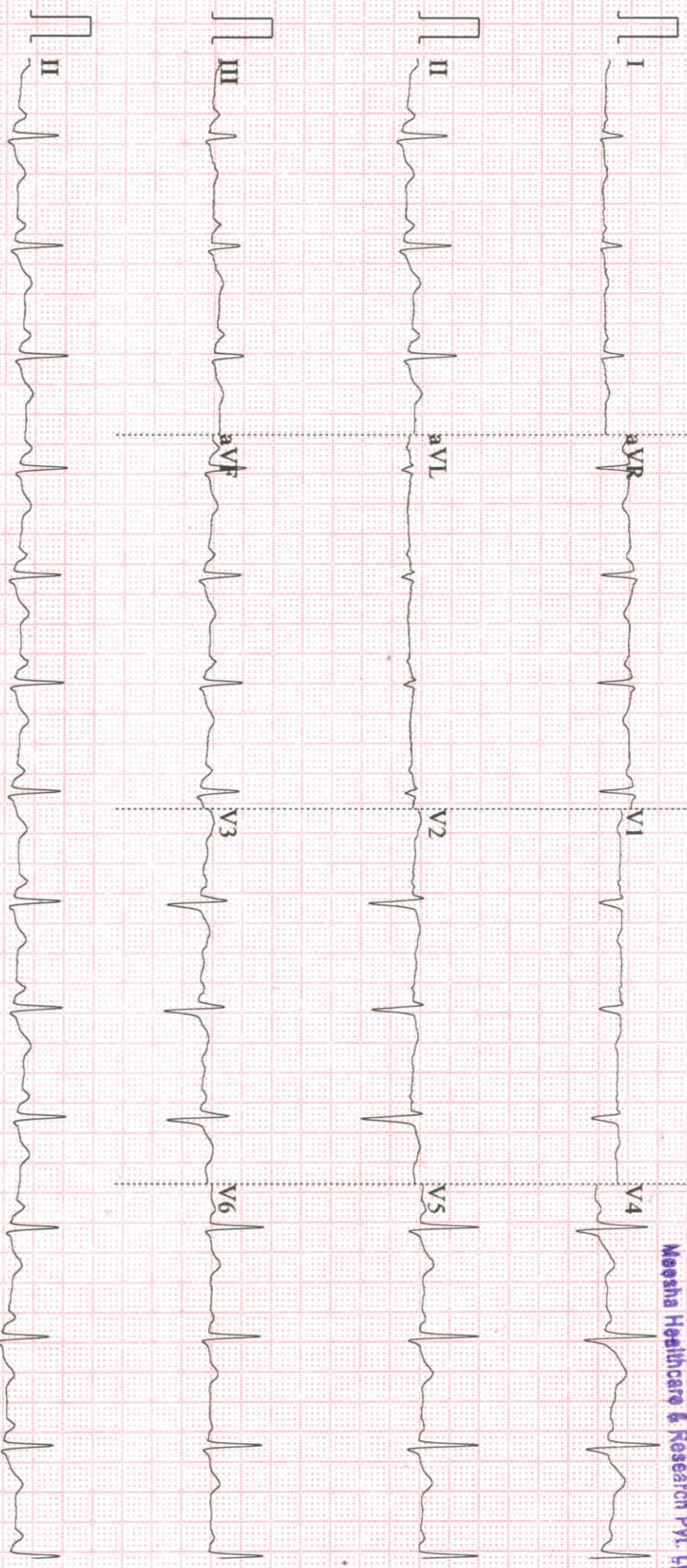
HR : 82 bpm
 P : 108 ms
 PR : 146 ms
 QRS : 95 ms
 QT/QTc : 371/435 ms
 P/QRS/T : 80/68/75 °
 RV5/SV1 : 0.970/0.389 mV

Diagnosis Information:

Ref-Phys: MEDIBUDDY
 Report Confirmed by:

Sm
with mild Ecm

DR (MRS) RAJNESH SINGH
 MBBS, DGO
 M M C REG. NO 49217
 Meesha Healthcare & Research Pvt. Ltd



NAME : Arpita Mittal
 DATE : 15/02/2025

AGE/SEX: F YEARS/ 36
 REFERRED BY: medic wheel

PERSONAL HISTORY:

Sleep	Disturbed / Sound	Acidity	No
Appetite	Good / Reduced / Increased	Exercise	No
Micturition	Burning / Normal	Diet	No
Bowel Movement	Regular / Irregular / Constipation	Marital Status	Married
Water Intake	<u>Normal</u>		

PAST HISTORY:

Any allergies	-	Coronary Heart Disease	-
Hypertension	-	Any Operations/ Surgery	LSCG
Diabetes	no	Treatment/Medication History	no
Tuberculosis	-	Hospitalization	-

last 1 month 125 mmHg

SOCIAL HISTORY: -

Drinking	-
Smoking	-

FAMILY HISTORY:

RELATIONSHIP	ALIVE/NOT ALIVE	IF ALIVE GIVE PRESENT STATE OF HEALTH/ IF NOT ALIVE SPECIFY CAUSE OF DEATH
Father	ALIVE	No Health issues (BP)
Mother	ALIVE	" (BP)
Sister	ALIVE	Healthy
Brother	ALIVE	Healthy
Wife/Husband	ALIVE	No Health issues
Children	7	

FEMALE PATIENTS

Frequency & Regularity of Periods Regular Any Children 1 L.M.P 28/1/2024
 Contraception _____ Full Term / Pre mature LSCG
 Pregnancy / Miscarriage / Termination 3

PHYSICAL EXAMINATION:

Hydration <u>Normal</u>	Joint swelling / Deformity _____	Nicotine Stains _____
Palms _____	Cyanosis / clubbing <u>no</u>	Pallor _____
Osler's nodes _____	Palpation of lymph nodes _____	Icterus <u>no</u>
Palmar erythema _____	Edema _____	
Yellow Skin _____	Pitting _____	
	Non Pitting _____	
	Dependent _____	

VITAL SIGNS:-

Temperature 96.4 f
 Respiratory Rate 20
 Pulse rate / rhythm 80/min
 Blood Pressure 110/80 mmhg

Basic Measurements

Height 159 cm
 Weight 56.1 kg
 BMI 22.2 Normal

ABDOMINAL EXAMINATION: No Hepatosplenomegaly, No Tenderness.

Inspection		Spleen	<u>N</u>
Palpation	<u>/ (N)</u>	Other	
Liver		Tenderness	<u>Nil</u>

NERVOUS SYSTEM: All reflexes and cranial nerves are normal. No sensory / motor deficit detected.

Reflexes	<u>(N)</u>	Sensory Nerve	<u>(N)</u>
Cranial Nerve	<u>(N)</u>	Motor System	
Sensory Nerve		Others	<u>Nil</u>

MUSCULO SKELETAL SYSTEM: No evident abnormality detected. All movements are normal.

Extremities	<u>(N)</u>		<u>(N)</u>
Movements			

CARDIO VASCULAR SYSTEM: Heart Sounds Normal. No other abnormality detected.**HEART SOUNDS:-**

Heart Sound 1	<u>(N)</u>	Murmur	<u>/ Nil</u>
Heart Sound 2		Other Findings	

RESPIRATORY SYSTEM: Air entry normal and equal on both sides. No added sounds or other abnormality detected.

Inspection of Thorax	<u>(N)</u>	Breathing	<u>(N)</u>
Auscultation		Added Sounds	
Air Entry		Other Findings	<u>/ Nil</u>

SUGGESTIONS:

Hb 9-9. ↓
Other reports normal

RECOMMENDATION:-

Cap Antin / crofer x 7
0 → 1 → 2 x 30 days
Cap Gentral 400 mg. 1 at night
x 3 days

DR (MRS) RAJNESH SINGH
MBBS, DGO
M M C REG. NO. 49217
Meeha Healthcare & Research Pvt. Ltd

Dr. Name: _____

भारत सरकार
GOVERNMENT OF INDIA



अर्पिता मिश्रा
Arpita Mittal
जन्म तिथि/ DOB: 11/06/1988
महिला / FEMALE



3628 3533 2150

माझी आधार, माझी ओळख


1800 300 1947
1947
help@uidai.gov.in
www.ww
P.O. Box No. 1947, Bengaluru-560 001

3628 3533 2150

महाराष्ट्र - 400011

मुंबई
उत्कल सर्कल, महालक्ष्मी ईस्ट, मुंबई,
प्लॉट, महालक्ष्मी हाइट्स सीएचएस,
W/O सुमित बंसल, बी-402 चौथा
Address: W/O Sumit Bansal, B-402 4th
Floor, Mahalaxmi Heights Chs,
Jacob Circle, Mahalaxmi East,
Mumbai, Mumbai,
Maharashtra - 400011

भारतीय पहचान प्राधिकरण
UNIQUE IDENTIFICATION AUTHORITY OF INDIA




YOUR PARTNER IN HEALTH



MEESHA

DIAGNOSTICS AND POLYCLINIC



*Agarwal
15/02/2025*




GPS Map Camera

Mumbai, Maharashtra, India

Shop No.9 And 10,ground Floor, La-view Shopping Centre, B.j.marg, Saat Rasta, Kasturba Quarters, Jacob Circle, Mumbai, Maharashtra 400011, India

Lat 18.98054° Long 72.827305°

15/02/25 12:23 PM GMT +05:30



Google



NAME: - *Ambika Muttal*
DATE: - *15/2/25*
REFERRED BY: - *Dr. Mediwheel*

REF No. :-
AGE/SEX: - *36yrs/f*

EYE CHECKUP

HISTORY OF EYE RELATED COMPLAINTS: *n/o using glass*
HISTORY OF SYSTEMIC ILLNESS :

EXAMINATION		RIGHT	LEFT
Distance vision	Without correction	<i>6/9 @</i>	<i>6/9</i>
	With correction	<i>6/6</i>	<i>6/6</i>
Near Vision	Without correction	<i>NG</i>	<i>NG</i>
	With correction		
ANTERIOR SEGMENT		<i>coller</i>	<i>coller</i>
LENS		<i>WM</i>	<i>WM</i>
POSTERIOR SEGMENT		<i>WM</i>	<i>WM</i>
ROPLAS		<i>MM</i>	<i>MM</i>
TENSION		<i>low</i>	<i>low</i>
COLOR VISION		<i>MM</i>	<i>MM</i>
DAIGNOSIS		<i>Refractive Error</i>	
ADVICE : <i>Glasses</i>			

	RIGHT				LEFT			
	SPH	CYL	AXIS	Vn	SPH	CYL	AXIS	Vn
DISTANCE	<i>-0.75</i>	<i>-</i>	<i>-</i>	<i>50</i>	<i>-0.50</i>	<i>-</i>	<i>-</i>	<i>60</i>
NEAR								

CONCLUSION:

Dr. SMITA DIXIT
DOMS, FCPS,
CONSULTANT OPHTHALMOLOGIST,
Reg. No. 2000 / 05 / 2092.

DR. SMITA DIXIT
DOMS.FC PS (OPHTHALMOLOGY)

POTEC PRK-7000

15/FEB/2025 10:30:38

NO: 00696

NAME:

[REF] UD: 0.0
Cyl. Form: MIX A

<R>	SPH	CYL	AX
	-0.75	+0.00	A
	-1.00	-0.25	52
AUE	-0.75	+0.00	

<L>	SPH	CYL	AX
	-0.75	+0.00	A
	-0.75	+0.00	A
AUE	-0.75	+0.00	

PD = 31mm

POTEC CO., LTD.

+82-42-632-3536



LAB REPORT

Printed Date: 2025-02-15 09:27 PM

Patient Id : 5133 **Patient Name** : Mrs. ARPITA MITTAL **TreatmentId** : 40207
Age/Gender : 36Y/Female **Mobile No** : 7045500413 **Ref. By** :
Registered On : 15-02-2025 08:52 AM **Collected On** : 15-02-2025 09:21 PM **Reported On** : 15-02-2025 09:27 PM
Nationality : Indian **Patient Type** : Sponsor **Sponsor Name** : MediBuddy (Phasorz Technologies Private Limited)

LFT - LIVER FUNCTION TEST

<u>Test Name</u>	<u>Test Result</u>	<u>Normal Values</u>	<u>Unit</u>
Serum Bilirubin Total	0.27	0.1 - 1.2	mg/dl
Serum Bilirubin Direct	0.15	0 - 0.5	mg/dl
Serum Bilirubin Indirect	0.12	0 - 0.9	mg/dl
Serum SGOT (AST)	31	0 - 40	IU/L
Serum SGPT (ALT)	17	0 - 40	IU/L
Serum Alkaline Phosphatase	63	40 - 111	IU/L
Serum GGT	12	11 - 50	U/L
Serum Total Proteins	6.03 L	6.4 - 8.3	g/dl
Serum Albumin	3.63	3.5 - 5.2	g/dl
Serum Globulin	2.40	1.6 - 3.5	g/dl
A/G Ratio	1.51	0 - 100	.

Equipment: ERBA-EM 200 FULLY AUTOMATED CLINICAL CHEMISTRY ANALYSER.

--End Of Report--

**AMAR JAYWANT
BANSODE (LAB
TECHNICIAN)**

**Dr. Aakriti Aggarwal
MBBS, MD (Pathology)
Consultant Pathologist**



LAB REPORT

Printed Date: 2025-02-15 09:27 PM

Patient Id : 5133	Patient Name : Mrs. ARPITA MITTAL	TreatmentId : 40207
Age/Gender : 36Y/Female	Mobile No : 7045500413	Ref. By :
Registered On : 15-02-2025 08:52 AM	Collected On : 15-02-2025 09:21 PM	Reported On : 15-02-2025 09:27 PM
Nationality : Indian	Patient Type : Sponsor	Sponsor Name : MediBuddy (Phasorz Technologies Private Limited)

CREATININE

<u>Test Name</u>	<u>Test Result</u>	<u>Normal Values</u>	<u>Unit</u>
Serum Creatinine	0.82	0.6 - 1.3	mg/dl

Equipment: ERBA-EM 200 FULLY AUTOMATED CLINICAL CHEMISTRY ANALYSER.

--End Of Report--

AMAR JAYWANT
BANSODE (LAB
TECHNICIAN)

Dr. Aakriti Aggarwal
MBBS, MD (Pathology)
Consultant Pathologist



LAB REPORT

Printed Date: 2025-02-15 09:27 PM

Patient Id : 5133	Patient Name : Mrs. ARPITA MITTAL	TreatmentId : 40207
Age/Gender : 36Y/Female	Mobile No : 7045500413	Ref. By :
Registered On : 15-02-2025 08:52 AM	Collected On : 15-02-2025 09:21 PM	Reported On : 15-02-2025 09:27 PM
Nationality : Indian	Patient Type : Sponsor	Sponsor Name : MediBuddy (Phasorz Technologies Private Limited)

BUN /CREATININE RATIO

<u>Test Name</u>	<u>Test Result</u>	<u>Normal Values</u>	<u>Unit</u>
Serum BUN	6.8	0 - 20	mg/dl
Serum Creatinine	0.82	0.6 - 1.3	mg/dl
BUN / Creat Ratio	8.29 L	30 - 40	/cumm

Equipment: ERBA-EM 200 FULLY AUTOMATED CLINICAL CHEMISTRY ANALYSER.

--End Of Report--

AMAR JAYWANT
BANSODE (LAB
TECHNICIAN)

Dr.Aakriti Aggarwal
MBBS,MD (Pathology)
Consultant Pathologist



LAB REPORT

Printed Date: 2025-02-15 09:27 PM

Patient Id : 5133	Patient Name : Mrs. ARPITA MITTAL	TreatmentId : 40207
Age/Gender : 36Y/Female	Mobile No : 7045500413	Ref. By :
Registered On : 15-02-2025 08:52 AM	Collected On : 15-02-2025 09:21 PM	Reported On : 15-02-2025 09:27 PM
Nationality : Indian	Patient Type : Sponsor	Sponsor Name : MediBuddy (Phasorz Technologies Private Limited)

BUN

<u>Test Name</u>	<u>Test Result</u>	<u>Normal Values</u>	<u>Unit</u>
Serum BUN	6.8	0 - 20	mg/dl

Equipment: ERBA-EM 200 FULLY AUTOMATED CLINICAL CHEMISTRY ANALYSER.

--End Of Report--

AMAR JAYWANT
BANSODE (LAB
TECHNICIAN)

Dr. Aakriti Aggarwal
MBBS, MD (Pathology)
Consultant Pathologist



LAB REPORT

Printed Date: 2025-02-15 09:27 PM

Patient Id : 5133	Patient Name : Mrs. ARPITA MITTAL	TreatmentId : 40207
Age/Gender : 36Y/Female	Mobile No : 7045500413	Ref. By :
Registered On : 15-02-2025 08:52 AM	Collected On : 15-02-2025 09:21 PM	Reported On : 15-02-2025 09:27 PM
Nationality : Indian	Patient Type : Sponsor	Sponsor Name : MediBuddy (Phasorz Technologies Private Limited)

URIC ACID SERUM

<u>Test Name</u>	<u>Test Result</u>	<u>Normal Values</u>	<u>Unit</u>
Serum Uric Acid	3.4	2.5 - 6.8	mg/dl

Equipment: ERBA-EM 200 FULLY AUTOMATED CLINICAL CHEMISTRY ANALYSER.

--End Of Report--

AMAR JAYWANT
BANSODE (LAB
TECHNICIAN)

Dr. Aakriti Aggarwal
MBBS, MD (Pathology)
Consultant Pathologist



LAB REPORT

Printed Date: 2025-02-15 09:27 PM

Patient Id : 5133	Patient Name : Mrs. ARPITA MITTAL	TreatmentId : 40207
Age/Gender : 36Y/Female	Mobile No : 7045500413	Ref. By :
Registered On : 15-02-2025 08:52 AM	Collected On : 15-02-2025 09:21 PM	Reported On : 15-02-2025 09:27 PM
Nationality : Indian	Patient Type : Sponsor	Sponsor Name : MediBuddy (Phasorz Technologies Private Limited)

LIPID PROFILE

<u>Test Name</u>	<u>Test Result</u>	<u>Normal Values</u>	<u>Unit</u>
Serum Cholesterol Total	158	140 - 250	mg/dl
Serum HDL Cholesterol	33.7	30 - 70	mg/dl
Serum Triglycerides	64.3	0 - 165	mg/dl
Serum LDL Cholesterol	111.4	85 - 130	mg/dl
Serum VLDL Cholesterol	12.86	0 - 40	mg/dl
LDL - HDL Ratio	3.31 L	3.5 - 5.0	.

Equipment: ERBA-EM 200 FULLY AUTOMATED CLINICAL CHEMISTRY ANALYSER.

--End Of Report--

**AMAR JAYWANT
BANSODE (LAB
TECHNICIAN)**

**Dr. Aakriti Aggarwal
MBBS, MD (Pathology)
Consultant Pathologist**



LAB REPORT

Printed Date: 2025-02-15 09:27 PM

Patient Id : 5133 **Patient Name** : Mrs. ARPITA MITTAL **TreatmentId** : 40207
Age/Gender : 36Y/Female **Mobile No** : 7045500413 **Ref. By** :
Registered On : 15-02-2025 08:52 AM **Collected On** : 15-02-2025 09:21 PM **Reported On** : 15-02-2025 09:27 PM
Nationality : Indian **Patient Type** : Sponsor **Sponsor Name** : MediBuddy (Phasorz Technologies Private Limited)

T3,T4,TSH (THYROID PROFILE)

<u>Test Name</u>	<u>Test Result</u>	<u>Normal Values</u>	<u>Unit</u>
SERUM T3 (Tri-Iodothyronine)	85	55 - 205	ng/dl
SERUM T4 (Tetra-Iodothyronine)	11.51	3.5 - 12.5	ug/dl
SERUM TSH (Thyroid Stimulating Hormone)	3.50	0.25 - 5.0	ÅµIU/ml

Interpretation: REFERENCE RANGE : a. ADULT :-Euthyroid : 0.25 - 5.0 IU/ml
Hypothyroid : >7.0 IU/ml
Hyperthyroid:< 0.15 IU/ml

NOTE : TSH values between 0.15 - 0.25 IU/ml and between 5.0 - 7.0 IU/ml are to be considered as a borderline. Repeat results after 2 weeks.

b. PREGNANCY :- First Trimester : 0.25 - 4.0 IU/ml
Second Trimester : 0.5 - 4.0 IU/ml
Second Trimester : 0.5 - 4.0 IU/ml
Third Trimester : 0.4 - 5.0 IU/ml

c. NEWBORN :
1 - 4 days : 1.0 - 39.0 IU/ml
1 - 4 weeks : 1.7 - 9.1 IU/ml
1 - 12 months : 0.8 - 8.2 IU/ml
1 - 5 years : 0.7 - 5.7 IU/ml

NOTE : This assay is performed as per the standard kit protocol.

Equipment: BIOMERIEUX VIDAS

--End Of Report--

AMAR JAYWANT
BANSODE (LAB
TECHNICIAN)

Dr.Aakriti Aggarwal
MBBS,MD (Pathology)
Consultant Pathologist



LAB REPORT

Printed Date: 2025-02-15 09:27 PM

Patient Id : 5133 **Patient Name** : Mrs. ARPITA MITTAL **TreatmentId** : 40207
Age/Gender : 36Y/Female **Mobile No** : 7045500413 **Ref. By** :
Registered On : 15-02-2025 08:52 AM **Collected On** : 15-02-2025 09:21 PM **Reported On** : 15-02-2025 09:27 PM
Nationality : Indian **Patient Type** : Sponsor **Sponsor Name** : MediBuddy (Phasorz Technologies Private Limited)

HBa1c (GLYCOSYLATED HAEMOGLOBIN)

<u>Test Name</u>	<u>Test Result</u>	<u>Normal Values</u>	<u>Unit</u>
GLYCOSYLATED HAEMOGLOBIN(HBA1C)	5.7	4.6 - 6.2	%
MEAN PLASMA GLUCOSE	116.89	0 - 154	mg/dl

Interpretation: 6.2 - 7.0 %----- Near Normal Glycemia
7.0 - 8.0 %----- Fair Control
8.0 - 10.0 % ----- Unsatisfactory Control
Above 10.0 % ----- Poor control

TRACIBILITY :
The method has been certified by the National Glycohaemoglobin Standardization Program

CLINICAL SIGNIFICANCE :
HbA1c is a glycated form of haemoglobin formed by the attachment of glucose residues in the blood to the haemoglobin molecules. The level of HbA1c is proportional to the level of glucose in the blood & has been widely accepted as an indicator of the mean blood glucose concentration in the preceding 6-8 weeks. It is therefore a long term indicator of diabetic control. For routine use HbA1c levels should be monitored every 3-4 months.

Equipment: mispa-i2

--End Of Report--

**AMAR JAYWANT
BANSODE (LAB
TECHNICIAN)**

**Dr.Aakriti Aggarwal
MBBS,MD (Pathology)
Consultant Pathologist**



LAB REPORT

Printed Date: 2025-02-15 09:27 PM

Patient Id : 5133	Patient Name : Mrs. ARPITA MITTAL	TreatmentId : 40207
Age/Gender : 36Y/Female	Mobile No : 7045500413	Ref. By :
Registered On : 15-02-2025 08:52 AM	Collected On : 15-02-2025 09:21 PM	Reported On : 15-02-2025 09:27 PM
Nationality : Indian	Patient Type : Sponsor	Sponsor Name : MediBuddy (Phasorz Technologies Private Limited)

BSF AND PP

<u>Test Name</u>	<u>Test Result</u>	<u>Normal Values</u>	<u>Unit</u>
Blood Sugar (F)	82	70 - 110	mg/dl
Blood Sugar (PP)	85	70 - 140	mg/dl

Equipment: ERBA-EM 200 FULLY AUTOMATED CLINICAL CHEMISTRY ANALYSER.

--End Of Report--

AMAR JAYWANT
BANSODE (LAB
TECHNICIAN)

Dr. Aakriti Aggarwal
MBBS, MD (Pathology)
Consultant Pathologist



LAB REPORT

Printed Date: 2025-02-15 09:27 PM

Patient Id : 5133	Patient Name : Mrs. ARPITA MITTAL	TreatmentId : 40207
Age/Gender : 36Y/Female	Mobile No : 7045500413	Ref. By :
Registered On : 15-02-2025 08:52 AM	Collected On : 15-02-2025 09:21 PM	Reported On : 15-02-2025 09:27 PM
Nationality : Indian	Patient Type : Sponsor	Sponsor Name : MediBuddy (Phasorz Technologies Private Limited)

BLOOD GROUP AND Rh TYPING

<u>Test Name</u>	<u>Test Result</u>
Blood Group	O
Rh Factor (D)	Positive

Interpretation: -1. Agglutination is a positive result and indicates the presence of A, B or D (Rho) Antigen
2. No agglutination is a negative result and indicates the absence of A, B or D (Rho) Antigen

--End Of Report--

**AMAR JAYWANT
BANSODE (LAB
TECHNICIAN)**

**Dr.Aakriti Aggarwal
MBBS,MD (Pathology)
Consultant Pathologist**



LAB REPORT

Printed Date: 2025-02-15 09:27 PM

Patient Id : 5133	Patient Name : Mrs. ARPITA MITTAL	TreatmentId : 40207
Age/Gender : 36Y/Female	Mobile No : 7045500413	Ref. By :
Registered On : 15-02-2025 08:52 AM	Collected On : 15-02-2025 09:21 PM	Reported On : 15-02-2025 09:27 PM
Nationality : Indian	Patient Type : Sponsor	Sponsor Name : MediBuddy (Phasorz Technologies Private Limited)

URINE ROUTINE

<u>Test Name</u>	<u>Test Result</u>
PHYSICAL EXAMINATION	
Quantity	40 ml
Appearance	Clear
Colour	Pale Yellow
Specific Gravity	1.020
Blood	Absent
CHEMICAL EXAMINATION	
Reaction (pH)	Acidic 5.0
Albumin	Absent
Glucose	Absent
Ketone Bodies	Absent
Bile Pigment	Absent
Urobilinogen	Normal
Occult blood	Absent
MICROSCOPIC EXAMINATION	
Epithelial Cells	0-1/hpf
Pus Cells	0-1/hpf
Red Blood Cells	Negative
Yeast cell	Absent
Casts	Absent
Crystals	Absent
Amorphous Deposit	Absent
Bacteria	Absent

--End Of Report--

**AMAR JAYWANT
BANSODE (LAB
TECHNICIAN)**

**Dr. Aakriti Aggarwal
MBBS, MD (Pathology)
Consultant Pathologist**



LAB REPORT

Printed Date: 2025-02-15 09:27 PM

Patient Id : 5133	Patient Name : Mrs. ARPITA MITTAL	TreatmentId : 40207
Age/Gender : 36Y/Female	Mobile No : 7045500413	Ref. By :
Registered On : 15-02-2025 08:52 AM	Collected On : 15-02-2025 09:21 PM	Reported On : 15-02-2025 09:27 PM
Nationality : Indian	Patient Type : Sponsor	Sponsor Name : MediBuddy (Phasorz Technologies Private Limited)

ESR (Erythrocyte Sedimentation Rate)

<u>Test Name</u>	<u>Test Result</u>	<u>Normal Values</u>	<u>Unit</u>
ESR	43 H	0 - 20	mm/hr

--End Of Report--

AMAR JAYWANT
BANSODE (LAB
TECHNICIAN)

Dr. Aakriti Aggarwal
MBBS, MD (Pathology)
Consultant Pathologist

LAB REPORT

Printed Date: 2025-02-15 09:27 PM

Patient Id : 5133 **Patient Name** : Mrs. ARPITA MITTAL **TreatmentId** : 40207
Age/Gender : 36Y/Female **Mobile No** : 7045500413 **Ref. By** :
Registered On : 15-02-2025 08:52 AM **Collected On** : 15-02-2025 09:21 PM **Reported On** : 15-02-2025 09:27 PM
Nationality : Indian **Patient Type** : Sponsor **Sponsor Name** : MediBuddy (Phasorz Technologies Private Limited)

CBC (COMPLETE BLOOD COUNT)

<u>Test Name</u>	<u>Test Result</u>	<u>Normal Values</u>	<u>Unit</u>
Haemoglobin	9.9 L	12 - 15	g/dl
R.B.C. Count	4.45	3.8 - 4.8	mill/cumm
Hematocrit(PCV)	32.9 L	36 - 46	%
M.C.V.	73.93 L	76 - 90	fl
M.C.H.	22.25 L	27 - 32	pg
M.C.H.C.	30.09 L	31 - 35	g/dl
RDW-CV	15.7 H	11.5 - 14	%
RDW-SD	44.1		
Platelet Count	377000	150000 - 400000	/cumm
Platelet On Smear	Adequate		
TOTAL WHITE BLOOD CELLS	7800	4000 - 10500	/cumm
Neutrophils	72 H	40 - 70	%
Band cells	00	0 - 10	%
Eosinophils	02	1 - 6	%
Lymphocytes	24	20 - 40	%
Monocytes	02	2 - 10	%
Basophils	00	0 - 02	%
R.B.C. Morphology	Normocytic Normochromic		
W.B.C Morphology	Normal		
Parasite	-		
Comment	-		

Equipment: CELL COUNTER ERBA H 360

--End Of Report--



**AMAR JAYWANT
BANSODE (LAB
TECHNICIAN)**



**Dr.Aakriti Aggarwal
MBBS,MD (Pathology)
Consultant Pathologist**

Patient Name : MRS ARPITA MITTAL
Age : 36 YEARS
Ref. By : MEDI BUDDY

ID No : 55471
Sex : FEMALE
Date : 15.02.2025

ULTRASONOGRAPHY OF THE ABDOMEN AND PELVIS

Liver

Is normal in size and shows normal echotexture.
No focal or diffuse lesion is seen.
The biliary tree and portal vein radicals are normal.

Gall bladder

Is physiologically distended and reveals an anechoic lumen.
No gallstone or evidence of cholecystitis is seen. There is no peri-cholecystic fluid.

Pancreas

Reveals a homogenous normal parenchymal echotexture and appears normal in size.
No solid or cystic mass lesion is seen. No pancreatic calcification or duct dilatation is seen.

Spleen

Is normal in size. The parenchymal echotexture is normal.
No focal mass lesion is seen.

Kidneys

The right kidney measures 10.5 x 4.0 cms. The left kidney measures 10.3 x 4.3 cms
Both kidneys are normal in size, shape and reveal normal differentiation of cortex, medulla and central echo complex.
No hydronephrosis, calculus or scarring is seen.

Urinary bladder

Was distended and revealed no intrinsic abnormality.

No para aortic lymphadenopathy or ascites is seen.

Patient Name : MRS ARPITA MITTAL
Age : 36 YEARS
Ref. By : MEDI BUDDY

ID No : 55471
Sex : FEMALE
Date : 15.02.2025

Uterus

Is anteverted and normal in size. Uterus measures 7.3 x 4.3 x 4.2 cms.
The myometrium and endometrium reveal normal echogenicity.
No mass lesion is seen.
Endometrium thickness is normal and measures 8.1. mm.

Ovaries

Both ovaries appear normal in size and echotexture.
Right ovary measures 3.6 x 1.8 cms.
Left ovary measures 3.7 x 2.1 cms.

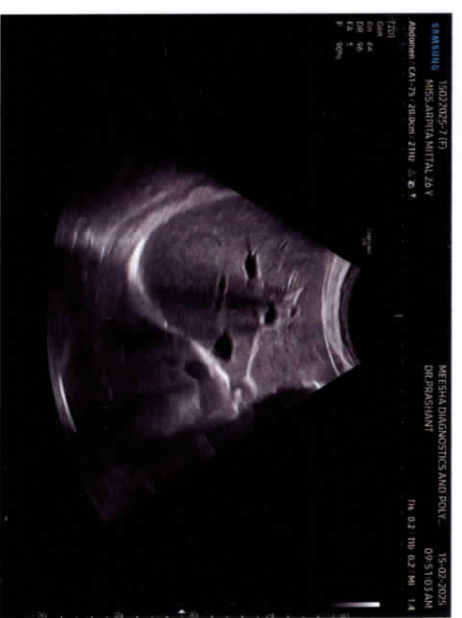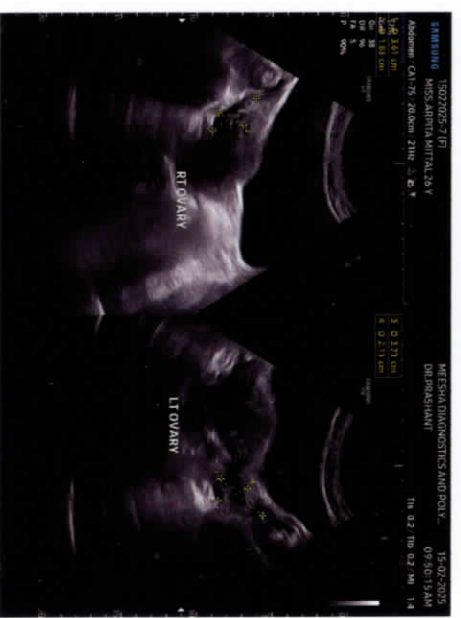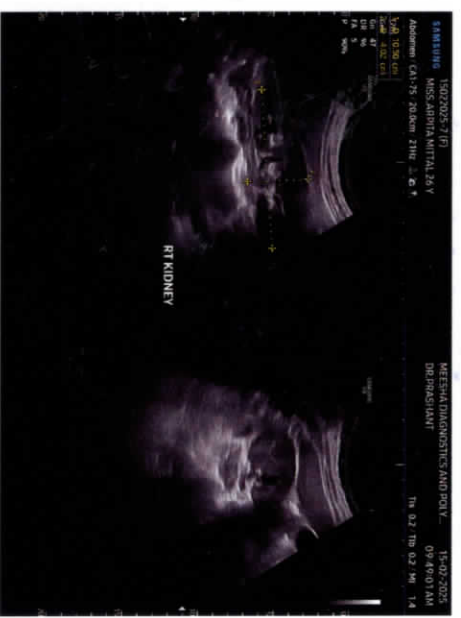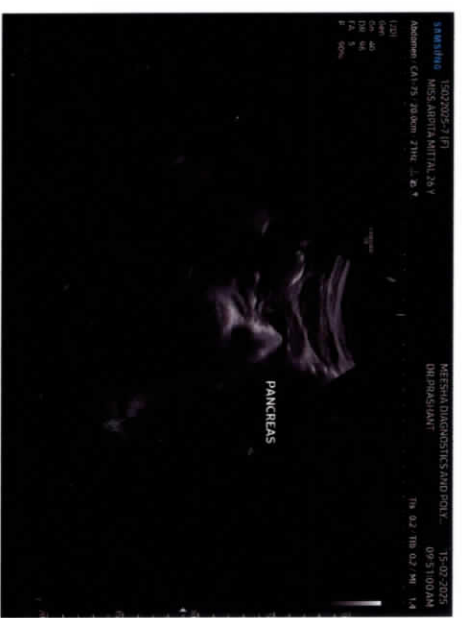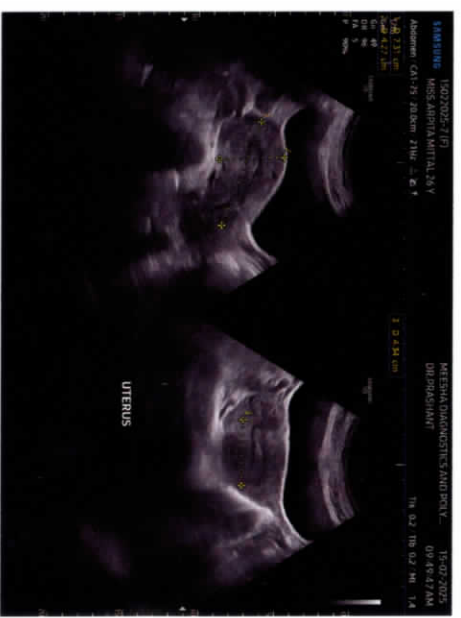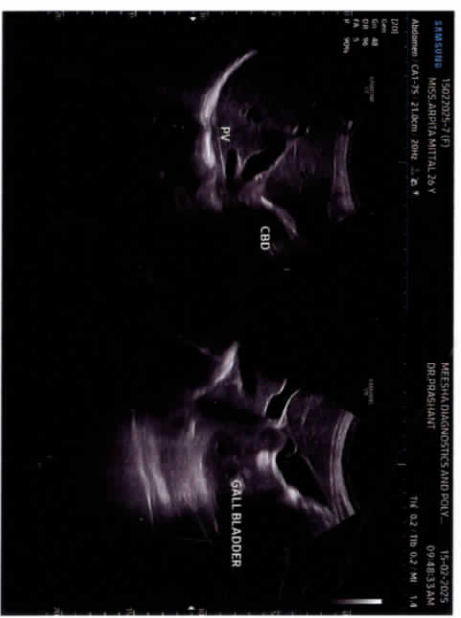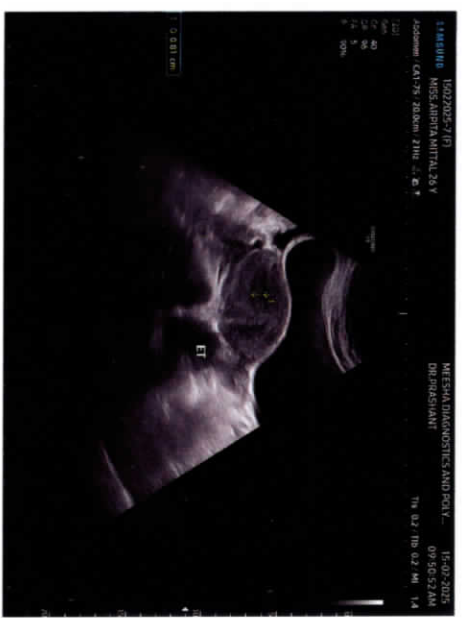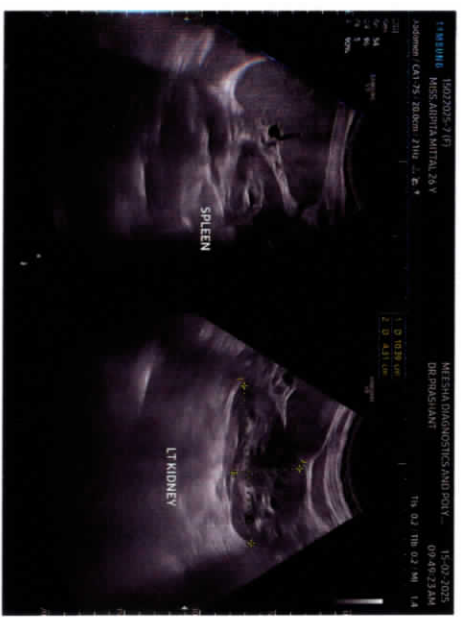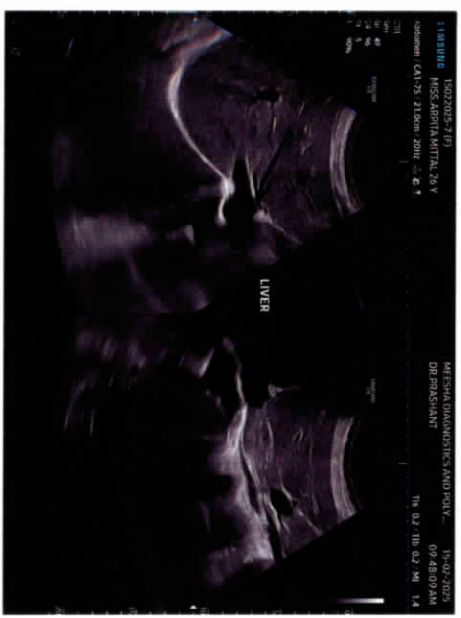
Cul de sac is unremarkable.

IMPRESSION :

No significant abnormality is seen in the abdomen and pelvis.

DR. PRASHANT VAIDYA
M.B.B.S. DMRE
Reg. No. 2002/02/593

DR. PRASHANT VAIDYA
D.M.R.E
CONSULTANT RADIOLOGIST



Patient ID: 55471 Patient Name: MITTAL ARPITA
Age: 026Y Sex: F
Study Date: 15/2/2025 10:45:30 AM Ref. By: MEDIBUDDY

**RADIOLOGY REPORT
EXAM:X RAY CHEST**

TECHNIQUE:

Frontal projection of the chest was obtained

FINDINGS:

Both lung fields are clear.

Both costophrenic angles appear normal.

The tracheal lucency is centrally placed.


The mediastinal and diaphragmatic outlines appear normal.

The heart shadow is normal.

The bony thoracic cage and soft tissues are normal.

IMPRESSION:

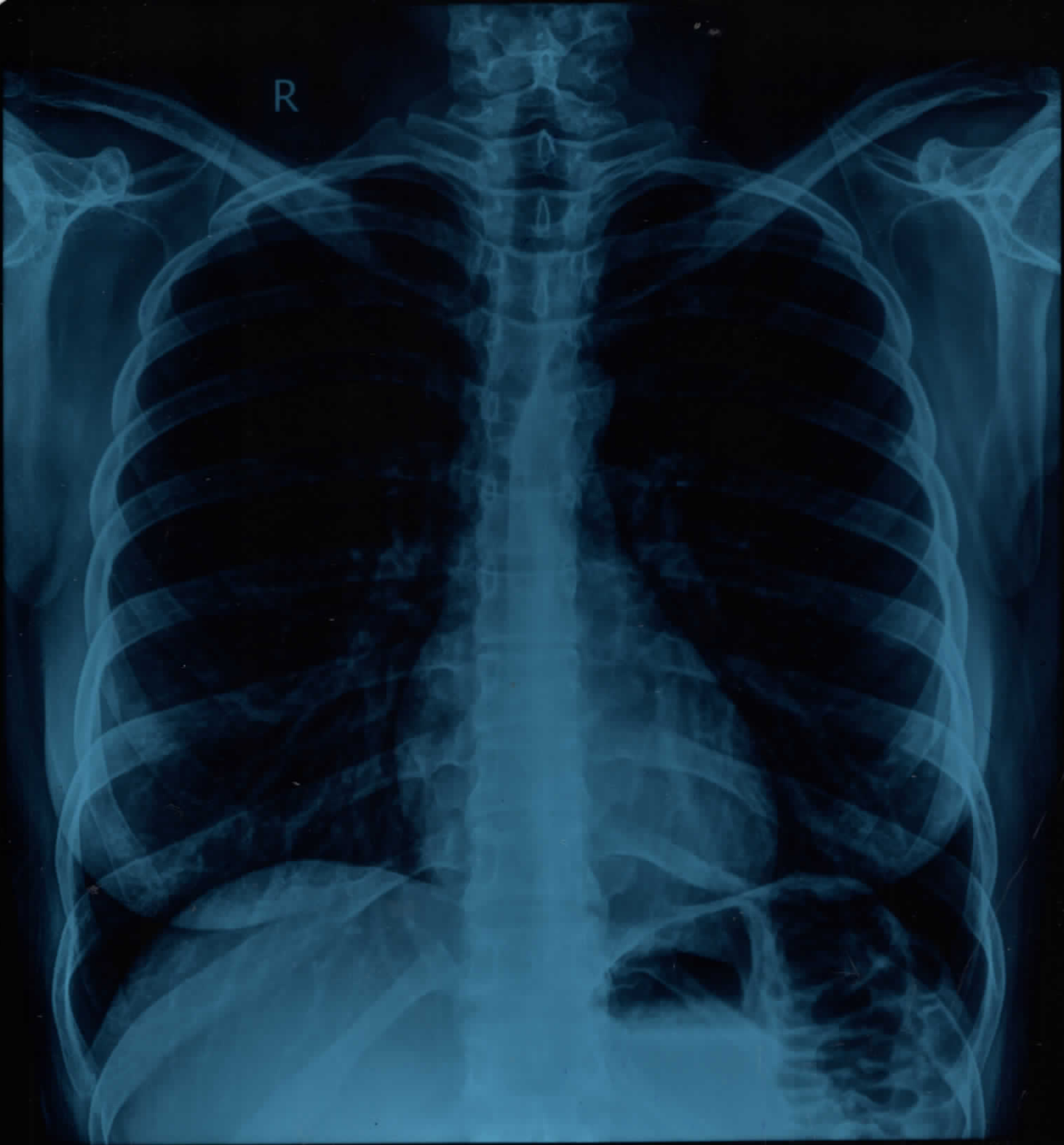The study is within normal limits.



Dr. Aditya Viras
MMC 2021/07/6884
MD (UCN) 2018030024



R



MILITARY MEDICAL COLLEGE
MUMBAI
MEESHA HEALTHCARE & RESEARCH PVT. LTD.
YOUR PARTNER IN HEALTH