



37

भारतीय विशिष्ट पहचान प्राधिकरण

भारत सरकार

Unique Identification Authority of India

Government of India


नामांकन क्रम / Enrollment No.: 1392/13120/13275

To
 भारत मलिक
 Bharat Malik
 S/O: Vinod Malik
 D-72 Gali no. 1
 Chander Nagar
 Krishna Nagar
 Krishna Nagar
 Gandhi Nagar East Delhi
 Delhi 110051
 8860394613

05/09/2014
168415978



ML684159784FT



आपका आधार क्रमांक / Your Aadhaar No. :

3176 6179 4976

आधार - आम आदमी का अधिकार



भारत सरकार

Government of India



भारत मलिक
 Bharat Malik
 जन्म तिथि / DOB : 04/09/1987
 पुरुष / Male

MALIK RADIX HEALTH CARE PVT. LTD.
 C-217, C-218, Nirman Vihar,
 Delhi-110092
 Ph.: 011-49287458, 011-61381379
 Regd. No. 607



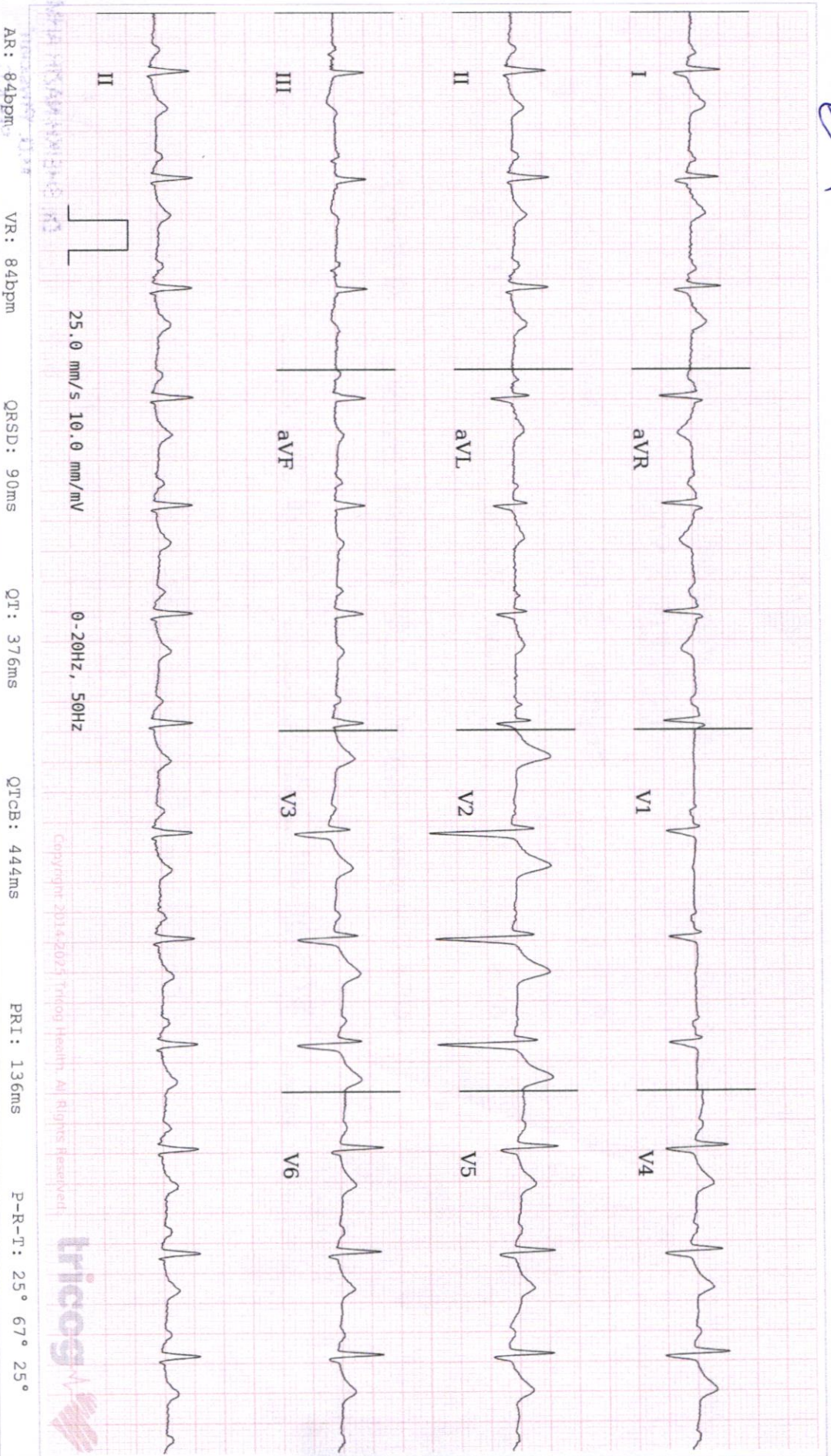
3176 6179 4976

आधार - आम आदमी का अधिकार



Age / Gender: 37/Male
Patient ID: 9560789797

Date and Time: 8th Mar 25 1:56 PM



ECG Within Normal Limits: Sinus Rhythm. Please correlate clinically.

Disclaimer: Analysis in this report is based on ECG alone and should only be used as an adjunct to clinical history, symptoms and results of other invasive and non-invasive tests and must be interpreted by a qualified physician.

REPORTED BY

Pradhina S.K.

Dr Pradhina S.K



Malik Radix HealthCare.

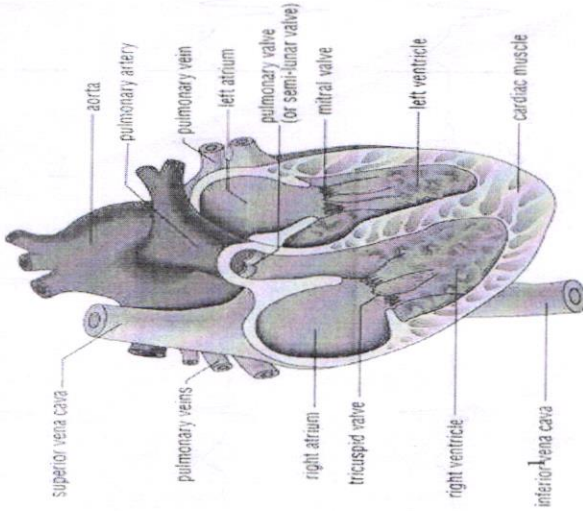
ELECTROCARDIOGRAM

Name: MR. BHARAT MALIK

Age & Sex: 37 YRS/MALE

Ref by: MEDIWHEEL

DATE: 08/03/2025



ECG FINDINGS:

Rate 84 bpm Rhythm Sinus Mechanism Normal


Axis Normal Wave Normal PR Interval 0.13/Sec

QRS Complex Normal QT Interval Normal Q Wave Normal

ST Segment Normal T Wave Normal

Conclusion Sinus Rhythm (HR- 84 bpm), Normal Axis, To be correlate.

Doctors Signa **Dr. SHEIKH NAZIR AHMED**
 M.D. Physician
 PGDCC
 DMC-46490




Echocardiogram Report

Patient Name	MR. BHARAT MALIK
Date of Test	08/03/2025
Age	37YRS/MALE
Ref. by	MEDIWHEEL

Dimensions	Result	Normal Range
AO (ed)	2.7 cm	(2.1 -3.7cm)
LA (es)	3.5 cm	(2.1 -3.7cm)
RVID (ed)	2.3 cm	(1.1-3.0cm)
LVID (ed)	3.6 cm	(3.6 – 5.5 cm)
LVID (es)	2.5 cm	(2.3-3.9cm)
IVS (ed)	1.0 cm	(0.6 – 1-2 cm)
LVPW (ed)	1.1 cm	(0.6 – 1-2 cm)
EF	60 %	
FS	31 %	(28 % - 42 %)

Impression:

- NO REGIONAL WALL MOTION ABNORMALITY SEEN.
- LVEF= 60 %
- NORMAL CHAMBER DIMENSIONS.
- NORMAL MIP.
- NORMAL COLOR FLOW
- NO INTRA CARDIAC CLOT/MASS/ VEGETATION/PERICARDIAL EFFUSION SEEN.


Dr. SHEIKH NAZIR AHMED
 M.D. "Physician" DCC
 (Consultant Non-Invasive Cardiologist)
 PGDCC
 DMG-48499

Facilities Available

- Multispeciality Hospital - 24 Hours Emergency - X-Ray/ ECG/ Ultrasound/ CT Scan - Dental- Fully Equipped Operation Theatre
 - Fully Functional Lab - 24/7 Casualty/ ICU-Nursery 24/7 Pharmacy - Labour Room - All Speciality OPD - Laproscopic Surgery -
 ECHO - Plastic Surgery



EYE EXAMINATION (AHC)

Name: <u>Mr. Bharat Malik</u>	Age & Gender: <u>37/M</u>
Ref.by: <u>Medicwheel</u>	Date: <u>08/03/2025</u>

Without Correction	With Correction <u>Rest used</u>
Distance - Right <u>6/6</u> Left <u>6/6</u>	Distance - Right _____ Left _____
Near - Right <u>N6</u> Left <u>N6</u>	Near - Right _____ Left _____

Color Vision: Normal Abnormal

Diagnosis: no error

Treatment Recommended: _____

Dr. Nidhi Gupta
Dr. Nidhi Gupta
 MBBS, MS, DNB
 Casualty Ophthalmologist
 Malik Radix Healthcare Pvt. Ltd.
 DMC No: 121661

Facilities Available

- Multispeciality Hospital - 24 Hours Emergency - X-Ray/ ECG/ Ultrasound/ CT Scan - Dental- Fully Equipped Operation Theatre
- Fully Functional Lab - 24/7 Casualty/ ICU-Nursery 24/7 Pharmacy - Labour Room - All Speciality OPD - Laproscopic Surgery - ECHO - Plastic Surgery



CONSULTANTS ON PANEL

PAEDIATRICS

Dr Ravi Malik (MBBS, MD)
Dr Harit Prasad (MBBS, MD, Pdi)
Dr Ritu Jain (MBBS, MD)

GYNAECOLOGY

Dr Renu Malik (MBBS, MD)
Dr Meena Malhotra (MBBS, MD)
Dr Rajni (MBBS, MD)
Dr Manju Gupta (MBBS, MS)
Dr Vaishali Saini (MBBS, DGO)
Dr Rupam Arora (MBBS, MD)

DENTAL

Dr Shruti Malik (BDS, MDS)
Dr Annu Saini (BDS, MDS)
Dr Rachit Thukral (BDS, MDS)
Dr Mohit Mangla (BDS, MDS)
Dr Tarun Mittal (BDS, MDS)
Dr Geetika Sharma (BDS)
Dr Shilpa Verma (BDS)

CHILD GASTROENTROLOGY

Dr S. K Mittal (MBBS, MD)

MEDICINE

Dr A S Talwar (MBBS, MD)
Dr Sunny Uppal (MBBS, MD)
Dr Surendra Rajpal (MBBS, MD)

RESPIRATORY MEDICINE / PULMONOLOGY

Dr Abhinav Bhanot (MBBS, DNB)

LAPAROSCOPY SURGERY

Dr Ajay Jain (MBBS, MS)
Dr Deepak Saran (MBBS, MS)
Dr Pradeep Saini (MBBS, MS)
Dr G. S Garg (MBBS, MS)

ORTHOPAEDICS

Dr Vikas Bhardwaj (MBBS, MS ORTHO, DNB)
Dr Prabhat Aggarwal (MBBS, MS ORTHO)
Dr KB Tiwari (MBBS, MS ORTHO)
Dr Deepak Kumar Arora (MBBS, MS ORTHO)

EYE/OPTHALMOLOGY

Dr Nidhi Gupta (MBBS, MS, DNB, PGDM)
Dr Himanshu Singh Pundir (MBBS, MS)

ENT

Dr Sharad Kumar Singhi (MBBS, MS)
Dr Prateek Sharma (MBBS, MS)
Dr Ashok Singh (MBBS, MS)
Dr A K Lahiri (MBBS, MS)

RADIOLOGY (ULTRASOUND)

Dr K K Sinha (MBBS DNRB)
Dr T K Vohra (MBBS, MD)
Dr Rajesh Malhotra (MBBS, MD)
Dr Ashish Tomar (MBBS, MD)

PATHOLOGY

Dr Reema Dahiya (MBBS, MD PATH)
Dr Meenu Aggarwal (MBBS, MD PATH)

ANAESTHESIA

Dr Rajesh Dhall (MBBS, MD)
Dr Rakesh Atrey (MBBS, MD)
Dr R K Arora (MBBS, MD)
Dr Swaraj Garg (MBBS, MD)

DERMATOLOGY

Dr Niharika Jha (MBBS, MD)

PLASTIC & COSMETIC SURGERY

Dr Ayush Jain (MBBS, MS, MCh)

PAEDIATRIC SURGERY

Dr Dharmendra Singh (MBBS, MS, M.Ch)

Dr Satish Aggarwal (MBBS, MS, M.Ch)

PAEDIATRIC NEPHROLOGY

Dr A S Vasudev (MD, Dip.in. Paed.)

NEPHROLOGY

Dr Javed (MBBS, MD, Nephro)

CARDIOLOGY

Dr Nishant Tyagi (MBBS, MD)

NEUROLOGY

Dr Amit Batra (MBBS, MD)

GASTROENTROLOGY

Dr Deepak Lahoti (MBBS, MD)

Dr Naresh Aggarwal (MBBS, MD)

Dr Ashok Goyal (MBBS, MD)

Dr Ankur Singhal (MBBS, MD)

UROLOGY

Dr Nikhil Sharma (MBBS, Mch)

Dr Ankur Singhal (MBBS, MD)

PSYCHIATRY

Dr Mohit Sharma (MBBS, MD)

PHYSIOTHERAPY

Dr Kirti Dwivedi

Dr Ravi Kumar

NUTRITIONIST

Dr Deepika Kohli

Dr Sakshi Rana

CLINICAL PSYCHOLOGIST

Dr. Sarika Singh

Dr. Shruti Malik

BDS, MDS (Endodontics)

+91-9899561092

Name : Bharat

Age/Sex : 27 yrs / M

Date : 8/3/25

**Timings : 10:00 am. to 2:00 pm.
6:00 pm. to 8:30 pm.**

For Appointment

011-45152510
+91-9999254639

CLINICAL EXAMINATION:-

Regular checkup

1. TMJ:-

M/H - N.R.H.

2. DENTAL STATUS:

- a. Caries Teeth :
- b. Fracture Teeth :
- c. Root Stumps :
- d. Gingivitis :
- e. Periodontitis :
- f. Impacted Teeth :
- g. Malaligned Teeth :

Stains +++ calculus +++

Carious 8/

Adv - scaling & polishing.

3. ORAL LESIONS:-

-> Mouth - Fluoridation

4. DIAGNOSIS:-

-> OPG. X 3 months.

5. TREATMENT PLANNING:

6. FOLLOW UP:-

Referral To Other Consultant: Yes/ No

If Yes, please mention the Name:

Doctor's Signature *[Signature]*
8/3/25.

Facilities Available :

- ★ MULTI-SPECIALITY HOSPITAL ★ MODULAR FULLY EQUIPPED OT ★ NURSERY ★ LAPROSCOPIC SURGERY
- ★ 24X7 EMERGENCY ★ OPG ★ DENTAL ★ 24X7 DIAGNOSTICS ★ LABOUR ROOM ★ ECHO ★ EEG ★ DIGITAL X-RAY ★ CT SCAN
- ★ ECG ★ ULTRASOUND ★ RICU/ICU ★ ALL SPECIALITY OPD ★ PLASTIC & COSMETIC SURGERY ★ DIALYSIS ★ PHARMACY



LAB REPORT

Reg. Date	08/03/2025	Patient Id	2503080001	DOB.	04/09/1987
Name	MR. BHARAT MALIK	Gender	M	Perm. ID	
Age	37 Yrs. 6 Mn. 4 Day	Panel	MEDIWHEEL	Reported	08/03/2025 18:12:00
Ref. By	MEDIWHEEL				

Test Name	Result	Units	Ref. Range
MEDIWHEEL ANNUAL PLUS			

HAEMATOLOGY

COMPLETE HAEMOGRAM

HAEMOGLOBIN (HB%)	12.7	gm/dl	13 - 18
TOTAL LEUCOCYTE COUNT (TLC)	9,670	/cumm	4000 - 11000
DIFFERENTIAL LEUCOCYTE COUNT (DLC)			
NEUTROPHIL	78.4	%	40 - 80
LYMPHOCYTE	16.2	%	28 - 55
MONOCYTE	4.4	%	02 - 10
EOSINOPHIL	0.7	%	01 - 06
BASOPHIL	0.3	%	0 - 0
ESR (WESTEGREN'S METHOD)	13	mm/1st hr.	0 - 10
R B C COUNT	6.99	Millions/cmm	4.5 - 5.5
P.C.V / HAEMATOCRIT	43.6	%	40 - 54
M C V	62.4	fl.	80 - 100
M C H	18.2	Picogram	27.0 - 31.0
M C H C	29.1	gm/dl	33 - 37
PLATELET COUNT	2.16	Lakh/cu mm	1.50 - 4.50
BLOOD GROUP ABO	" O "		
RH TYPING	Positive		
BLOOD SUGAR FASTING	95.29	mg/dl	70 - 100
BLOOD SUGAR PP	120.59	mg/dl	90 - 140
HB A1C	6.37	%	04 - 5.7

Interpretation

Checked by : _____
Page 1 Contd...2

If test results are alarming or unexpected, patient is advised to contact the laboratory immediately for possible remedial action.

Facilities Available

- Multispeciality Hospital - 24 Hours Emergency - X-Ray/ ECG/ Ultrasound/ CT Scan - Dental- Fully Equipped Operation Theatre
- Fully Functional Lab - 24/7 Casualty/ ICU-Nursery 24/7 Pharmacy - Labour Room - All Speciality OPD - Laproscopic Surgery -
ECHO - Plastic Surgery



LAB REPORT

Reg. Date	08/03/2025	Patient Id	2503080001	DOB.	04/09/1987
Name	MR. BHARAT MALIK	Gender	M	Perm. ID	
Age	37 Yrs. 6 Mn. 4 Day	Panel	MEDIWHEEL	Reported	08/03/2025 18:12:00
Ref. By	MEDIWHEEL				

Test Name	Result	Units	Ref. Range
NON- DIABETIC	:<5.7 %		
PRE DIABETES	: 5.7- 6.4%		
DIABETES	: >6.5%		
GOOD CONTROL DIABETES	: <7 %		

The Glycosylated haemoglobin assay has been validated as a reliable indicator Of mean blood glucose levels for a period of 8-12 week period. ADA recommended the testing twice a year in patients with stable blood glucose and quarterly. If treatment change, or if blood glucose levels are unstable.

TO BE CORRELATED CLINICALLY.

THYROID PROFILE

Free T3 ELFA	1.16	ng/ml	02 - 04
Free T4 ELFA	1.31	ug/dl	0.8 - 2.7
TSH Serum/ELFA	2.470	uIU/ml	0.25 - 5.50 uIU/ml

Interpretation

Clinical Use

- Diagnose Hypothyroidism and Hyperthyroidism
- Monitor T4 replacement or T4 suppressive Therapy
- Quantify TSH levels in the subnormal range

Increased Levels : Primary Hypothyroidism Subclinical Hypothyroidism, TSH dependent, Thyroid Hormone Resistance.

Checked by : _____
Page 2 Contd...3

If test results are alarming or unexpected, patient is advised to contact the laboratory immediately for possible remedial action.

Facilities Available

- Multispeciality Hospital - 24 Hours Emergency - X-Ray/ ECG/ Ultrasound/ CT Scan - Dental- Fully Equipped Operation Theatre
- Fully Functional Lab - 24/7 Casualty/ ICU-Nursery 24/7 Pharmacy - Labour Room - All Speciality OPD - Laproscopic Surgery - ECHO - Plastic Surgery



LAB REPORT

Reg. Date	08/03/2025	Patient Id	2503080001	DOB.	04/09/1987
Name	MR. BHARAT MALIK	Gender	M	Perm. ID	
Age	37 Yrs. 6 Mn. 4 Day	Panel	MEDIWHEEL	Reported	08/03/2025 18:12:00
Ref. By	MEDIWHEEL				

Test Name	Result	Units	Ref. Range
-----------	--------	-------	------------

Decreased Levels : Grave's Disease, Autonomous Thyroid Hormone Secretion, TSH Deficiency

LIPID PROFILE

TOTAL CHOLESTEROL	148.62	mg/dL	130.0 - 200.0 (<200)
TRIGLYCERIDES	102.79	mg/dL	80.5 - 150.0 (<150)
H D L CHOLESTEROL DIRECT	35.80	mg/dL	35.0 - 60.0 (<40->59)
V L D L	20.6	mg/dL	4.0 - 30. (23-45)
L D L CHOLESTEROL	92.2	mg/dL	50.0 - 150.0 (50-150)
TOTAL CHOLESTEROL / HDL RATIO	4.2		3.3 - 5.1
LDL / HDL CHOLESTEROL RATIO	2.6		1.5 - 3.5

LIVER FUNCTION TEST (LFT)

BILIRUBIN TOTAL	0.71	mg/dl	0.2 - 1.2
CONJUGATED (D. BILIRUBIN)	0.27	mg/dl	0.00 - 0.3
UNCONJUGATED (I.D.BILIRUBIN)	0.44	mg/dl	0.2 - 0.9
SGOT / AST	23.30	IU/L	0 - 35
SGPT / ALT	47.1	IU/L	0 - 35
ALKALINE PHOSPHATASE	68.80	U/L	64 - 306
TOTAL PROTEIN	7.00	gm/dl	6.0 - 8.3
ALBUMIN	4.38	gm/dl	3.2 - 5.0
GLOBULIN	2.62	gm/dl	2.5 - 5.6
A/G RATIO	1.67		0.9 - 2.0
GAMMA GT	25.60	IU/L	0.0 - 45.0

Checked by : _____
Page 3 Contd...4

If test results are alarming or unexpected, patient is advised to contact the laboratory immediately for possible remedial action.

Facilities Available

- Multispeciality Hospital - 24 Hours Emergency - X-Ray/ ECG/ Ultrasound/ CT Scan - Dental- Fully Equipped Operation Theatre
- Fully Functional Lab - 24/7 Casualty/ ICU-Nursery 24/7 Pharmacy - Labour Room - All Speciality OPD - Laproscopic Surgery -
ECHO - Plastic Surgery



LAB REPORT

Reg. Date	08/03/2025	Patient Id	2503080001	DOB.	04/09/1987
Name	MR. BHARAT MALIK	Gender	M	Perm. ID	
Age	37 Yrs. 6 Mn. 4 Day	Panel	MEDIWHEEL	Reported	08/03/2025 18:12:00
Ref. By	MEDIWHEEL				

Test Name	Result	Units	Ref. Range
SERUM CREATININE	0.87	mg/dl	0.7 - 1.4
SERUM URIC ACID	7.32	mg/dl	3.4 - 7.0
BLOOD UREA NITROGEN (BUN)	18.40	mg/dl	6.0 - 21.0
BUN/CREAT RATIO	21.1	mg/dl	10 - 20
Urine Routine Examination			
PHYSICAL EXAMINATION			
QUANTITY	10	ml.	
COLOUR	Pale Yellow		Pale Yellow
TRANSPARENCY	Clear		
SPECIFIC GRAVITY	1.015		
PH	6.5		
CHEMICAL EXAMINATION			
ALBUMIN	Nil		
SUGAR	Nil		
MICROSCOPIC EXAMINATION			
PUS CELLS	1-2	/HPF	
RBC'S	Nil	/HPF	
CASTS	Nil		
CRYSTALS	NIL		
EPITHELIAL CELLS	1-2	/HPF	
BACTERIA	Nil		
OTHERS	Nil		

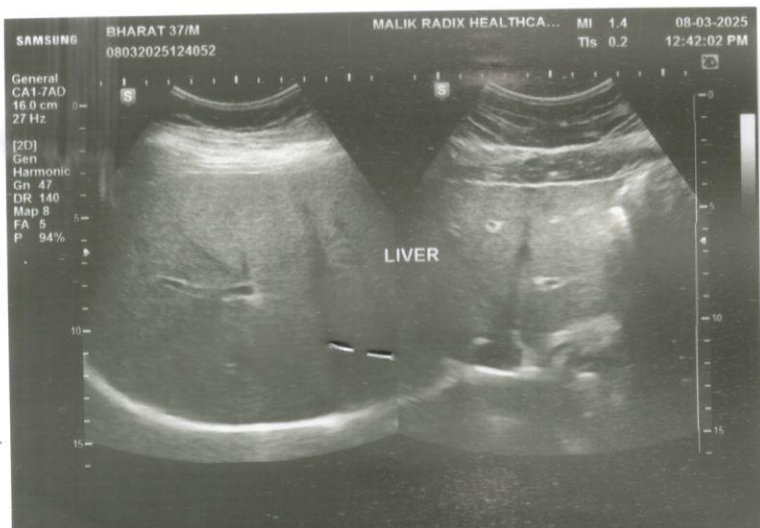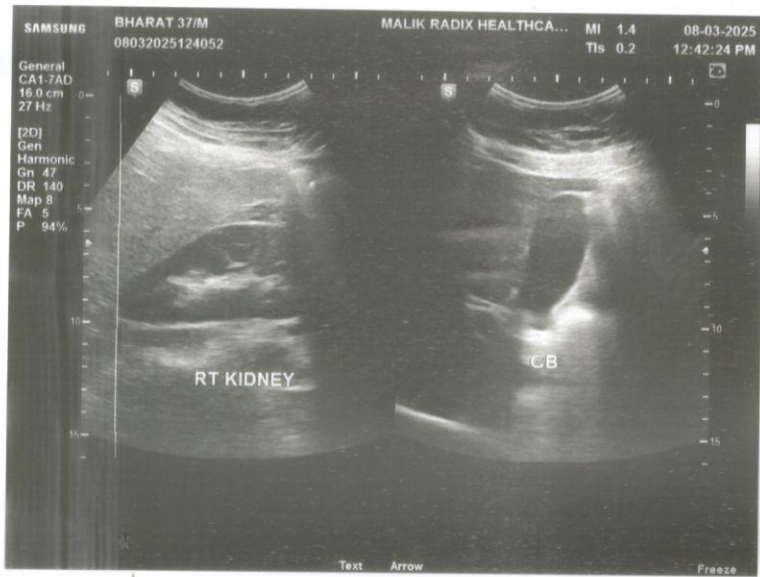
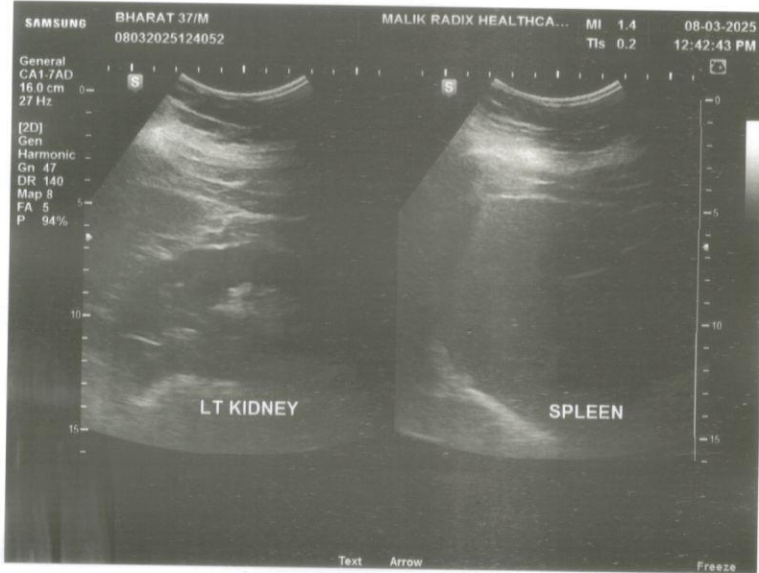
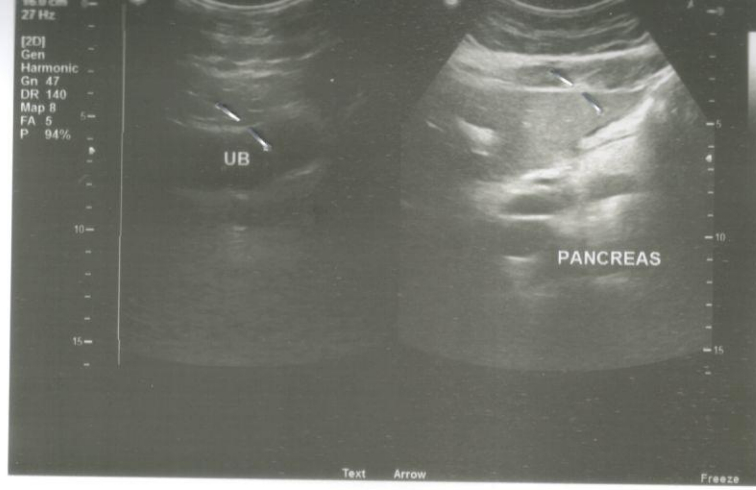
DR. REEMA DAHYA
M.B.B.S. AND (Path)
Malik Radix Healthcare Pvt. Ltd.
Checked by: Nirman Vihar,
C-217, C-218, Vikas Marg,
Delhi-110092

DR. MEENU AGGARWAL
M.B.B.S, MD (Path.)

If test results are alarming or unexpected, patient is advised to contact the laboratory immediately for possible remedial action.

Facilities Available

Speciality Hospital - 24 Hours Emergency - X-Ray/ ECG/ Ultrasound/ CT Scan - Dental- Fully Equipped Operation Theatre
Functional Lab - 24/7 Casualty/ ICU-Nursery 24/7 Pharmacy - Labour Room - All Speciality OPD - Laproscopic Surgery -
ECHO - Plastic Surgery




RADIX
HEALTH
care



Malik Radix Healthcare

C/217, C/218, Vikas Marg, Nirman Vihar, New Delhi-110092
A Unit of Malik Radix Healthcare
Toll Free - 1800-120-5457, Tel. : 011 49287456, 61381379
Whatsapp No. - 9811550650
E-mail: radixhealthcare@yahoo.co.in
Website: www.radixhealthcare.org



NAME	MR BHARAT MALIK	AGE	37 YRS/M
REFD. BY.	HEALTH CHECK UP	DATE	08.03.25

Ultrasound Examination of Whole Abdomen & Pelvis:

Liver: Grade-I fatty liver. No focal SOL is seen in liver. IHBR & portal radicles are normal.

Gallbladder: Gallbladder shows normal anechoic pattern. No evidence of cholecystitis or cholelithiasis seen. Common bile duct is normal in course & caliber.

Pancreas: Pancreas shows normal size & echotexture.

Spleen: Spleen shows normal size, outline & echotexture.

Kidneys: Kidneys show normal size, shape, position & echotexture. No calculus, hydronephrosis or SOL is seen in kidneys. Cortico- medullary differentiation and cortical thickness is normal on both sides.

No supra- renal mass seen.

Great abdominal vessels are normal.

Domes of diaphragm are seen to move normally & synchronously in respiration. No infra- or supradiaphragmatic collection seen.

No ascites or pericardial effusion seen.

No para-aortic lymph nodes seen.

Urinary bladder: Urinary bladder shows normal anechoic pattern. No calculus, SOL or diverticulum seen.

Prostate: Prostate and seminal vesicles are sonographically normal.

IMP:- Grade-I fatty liver.

Regards.

Dr Mukesh Koshal MD (Rad- diag)
Regn. No. DMC 10407

RADIOLOGIST :

Facilities Available

- Multispeciality Hospital - 24 Hours Emergency - X-Ray/ ECG/ Ultrasound/ CT Scan - Dental- Fully Equipped Operation Theatre
- Fully Functional Lab - 24/7 Casualty/ ICU-Nursery 24/7 Pharmacy - Labour Room - All Speciality OPD - Laproscopic Surgery
- FICU - Plastic Surgery

R

NIRMAN VIHARA



UHID	PT236503	LAB No.	XRY2423394
Name	Mr. BHARAT MALIK	Regn. No.	GEN2446026
Age / Sex	37 Yrs / M	Receiving Dt/Time	08-Mar-2025 13:14
		Reporting Dt/Time	08-Mar-2025 08:05 PM



XRAY

CHEST (PA)

Both lung fields are normal.

Cp angles are clear.

Hila are normal...

Heart size appears within normal limits.

Soft tissue shadows and bony thorax are normal.

Advised....please correlate clinically.

***** END OF REPORT *****

Approved By :

Approval Date :

00:00:00

DR. K.K. SINHA
 M.B.B.S., D.M.R.D.
 SENIOR CONSULTANT
 Reg. No. 29437 (DMC)

DR. T. K VOHRA
 MD (RADIOLOGICAL DIAGNOSIS)
 SENIOR CONSULTANT
 Reg. No. 3272 (DMC)

DR. MUKESH KOSHAL
 MBBS, MD (RADIOLOGY)
 CONSULTANT RADIOLOGY
 Reg.No.DMC10407

Facilities Available