

**Saturday, March 08, 2025**  
**NEERAJ SHARMA**  
**37 YEARS/MALE**

**CHEST X RAY PA VIEW**

Both the lung fields appear normal.

Both costophrenic angles appear clear.

Cardiac silhouette appear normal.


Both hila appears normal.

Bony thorax appears normal.

No evidence of free gas seen under dome of diaphragm.

**COMMENTS:**

- **NORMAL BOTH LUNG FIELDS.**
- **NORMAL CARDIAC SIZE.**

  
**DR SARJAN VASAVA**  
M.B.B.S., D.M.R.D.  
Reg. No. G-26527  
**SAMANVAY HOSPITALS**

**Digitally signed by**  
**DR SARJAN VASAVA,**  
**CONSULTANT RADIOLOGIST.**



ZO12 X 2280  
Wt: 128-MW: 256

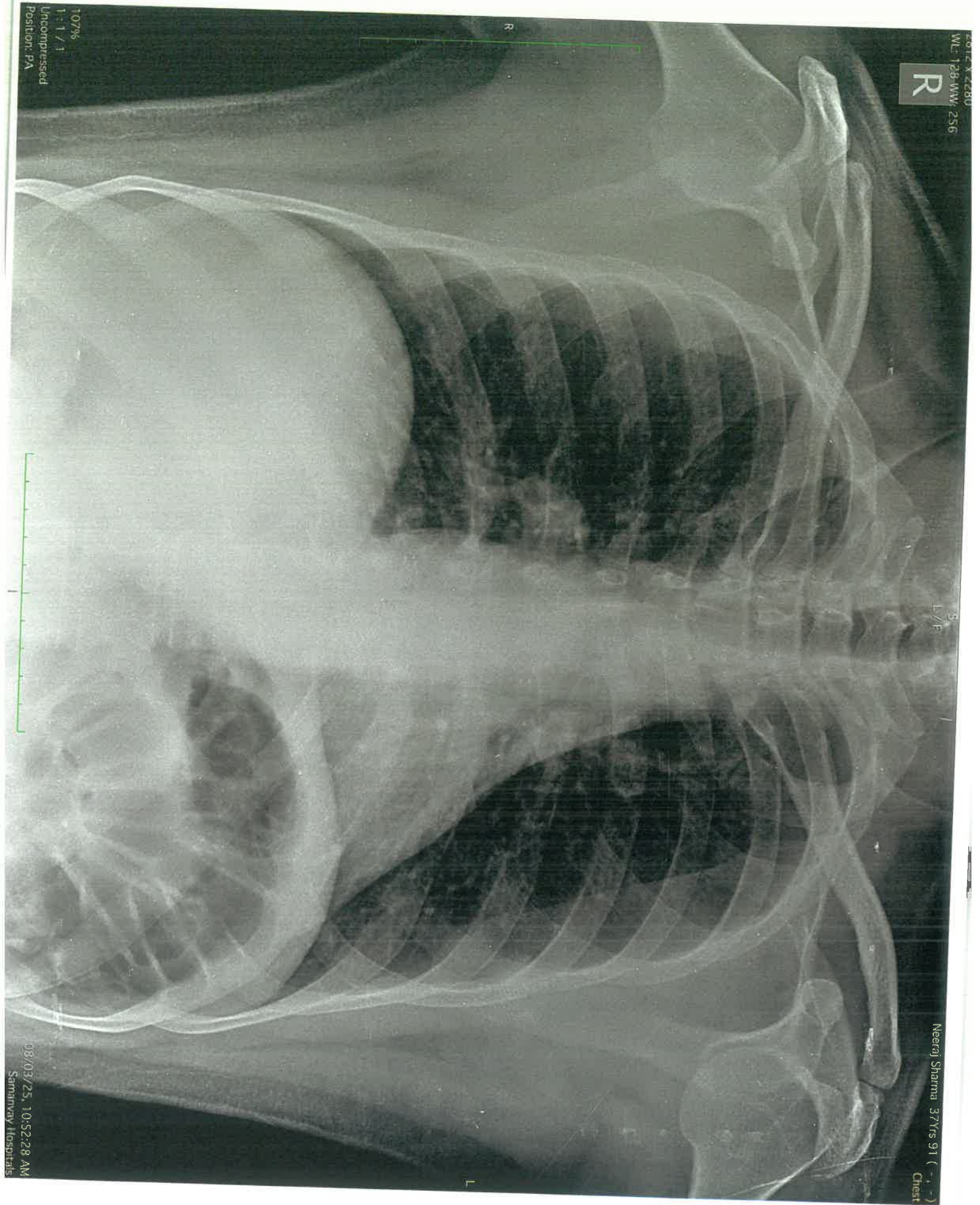
R

L/R

Neeraj Sharma 37Yrs 91 (-, -)  
Chest

100%  
1:1/1  
Uncompressed  
Position: PA

08/03/25, 10:52:28 AM  
Samarway Hospitals



## **2D ECHOCARDIOGRAPHY AND COLOUR DOPPLER STUDY**

**NAME : MR.NEERAJ SHARMA**

**DATE :08-03-25**

**AGE/SEX :39 YRS /M    WARD :HCP    REF BY :SAMANVAY HOSPITAL**

### **OBSERVATION:**

- NORMAL LV SIZE WITH NORMAL LV SYSTOLIC FUNCTION
- LVEF 56%, NO RWMA AT REST
- E/O NO LV DIASTOLIC DYSFUNCTION, NORMAL LA SIZE
- AORTIC VALVE, NO AR, NO AS
- MITRAL VALVE, MILD MR, NO MS
- TRIVIAL TR, MILD PAH, RVSP 30 MMHG
- NORMAL SIZED RA, RV WITH NORMAL RV FUNCTION
- PULMONARY VALVE- NO PR, NO PS, NORMAL SIZED PA & ITS BRANCHES
- IAS, IVS ARE INTACT
- NO INTRACARDIAC CLOT, VEGETATION
- PERICARDIUM NORMAL, NO PERICARDIAL EFFUSION
- IVC NORMAL

### **MEASUREMENTS:**

M MODE: AORTA: 28 MM    LA: 37 MM    LV DD/DS: 46/25 MM    IVS/PW: 12/12 MM  
DOPPLER: MV RATIO E/A: 0.7/0.5 M/S    AV VMAX: 1.0 M/S    PV VMAX: 0.6 M/S

### **CONCLUSION:**

**NORMAL LV SIZE AND LV SYSTOLIC FUNCTION**  
**LVEF 56%, NO RWMA AT REST**  
**MILD MR, TRIVIAL TR, MILD PAH**  
**E/O NO LV DIASTOLIC DYSFUNCTION**



**DR. PAVAN ROY**  
MD, DM (CARDIOLOGY)  
CONSULTANT CARDIOLOGIST  
REG. NO. G-23390  
M No. 9305988158

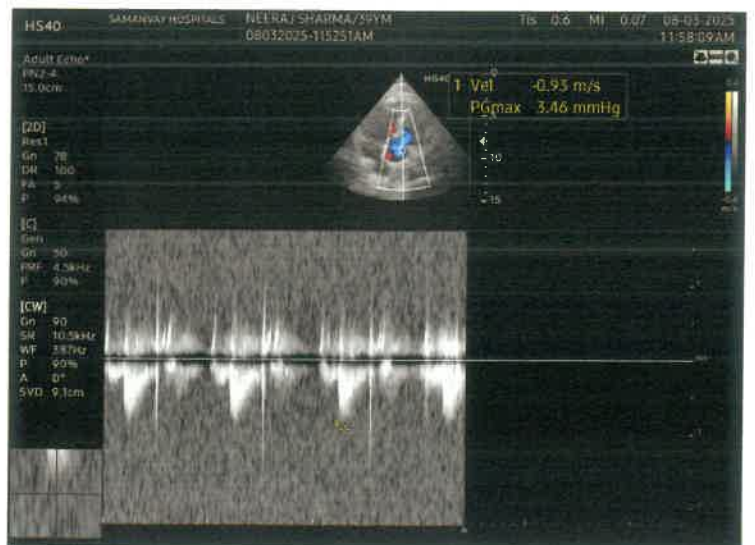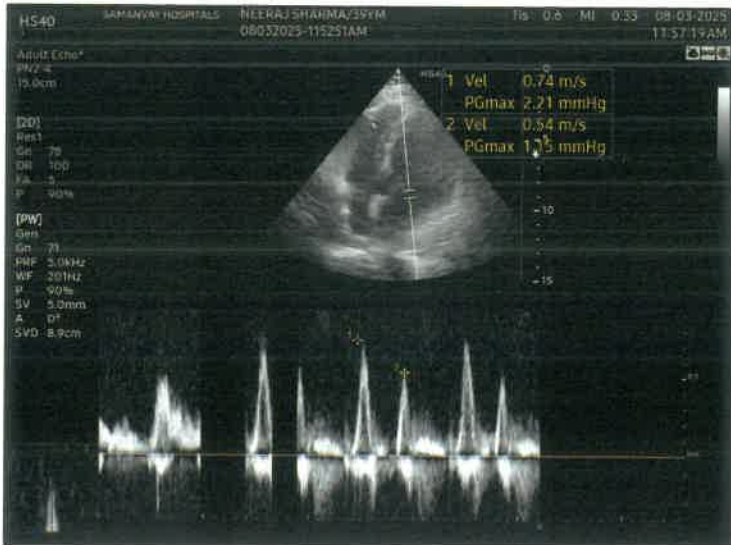
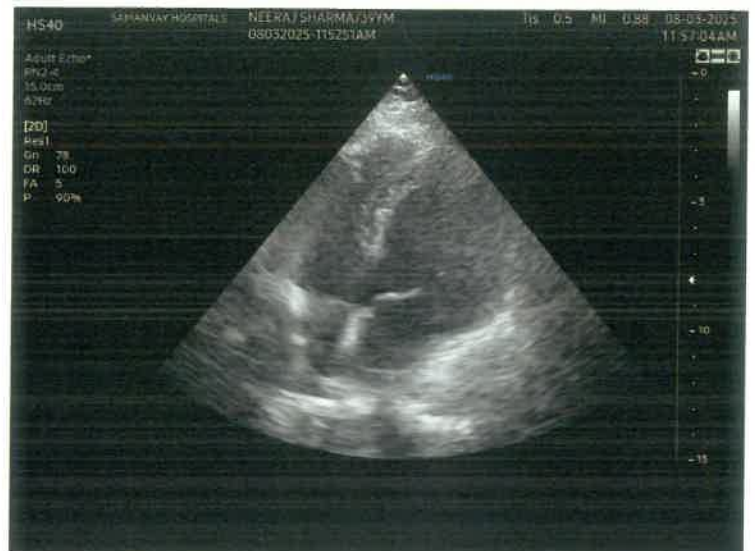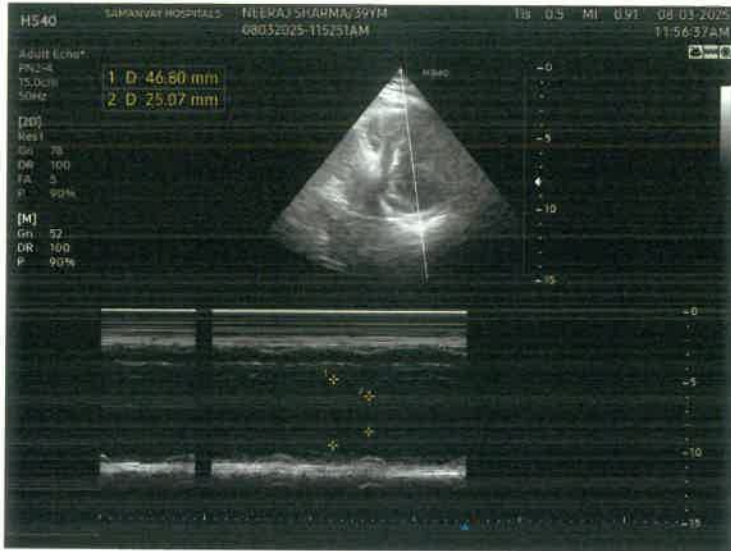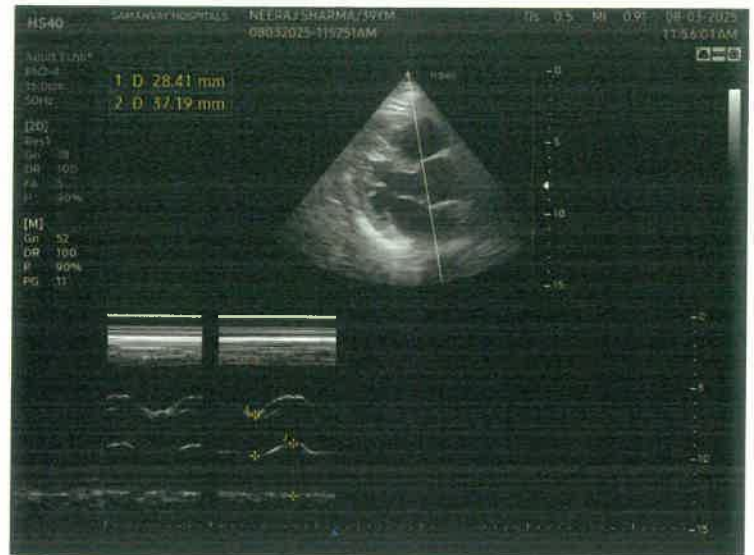
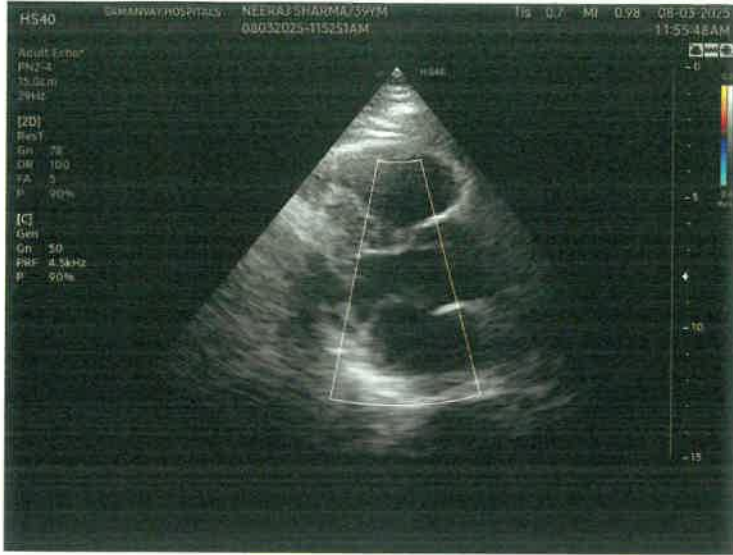**DR. PAVAN ROY**  
MD, DM (CARDIOLOGY), REG NO. G-23390  
CONSULTANT INTERVENTIONAL CARDIOLOGIST

Patient

ID 08032025-115251AM  
 Name NEERAJ SHARMA/39YM  
 Birth Date  
 Gender

Exam

Accession #  
 Exam Date 08-03-2025  
 Description  
 Operator



NEERAJ SHARMA

M / 39 YEARS

DATE: 08/03/2025

**REAL TIME SONOGRAPHY OF THE ABDOMEN & PELVIS**

**LIVER** - It is normal in size (13.5 cm). It shows bright echo pattern. No evidence of solid or cystic focal lesion is seen. The intrahepatic biliary system is normal and shows no dilatation of the radicles. The portal vein, CBD and hepatic veins appear normal.

**GALL BLADDER** - It is distended and appears normal. No evidence of sludge or calculus is seen. The wall appears normal.

**PANCREAS** - It is visualized and appears normal.

**SPLEEN** - It appears normal in size (10.8 cm), normal in shape and echotexture. No focal lesions.

**KIDNEYS** - . Both the kidneys appear normal in size, shape and show normal corticomedullary differentiation. Normal echogenicity of both kidneys.

Right kidney measures 9.0 x 4.7 cm. Left kidney measures 9.3 x 4.8 cm.

No calculus or hydronephrosis is seen on either side.

Urinary bladder is distended and appears normal. No cystitis or mass lesion noted.

Prostate appears normal in size vol - 15 cc . No focal lesion.

No evidence of any lymphadenopathy or ascites is noted.

No evidence of dilated bowel loops or bowel wall thickening noted.

**IMPRESSION:**

**FATTY LIVER GRADE-I.**



**DR. SARJAN VASAVA,**  
**CONSULTANT RADIOLOGIST.**

**DR SARJAN VASAVA**  
**M.B.B.S., D.M.R.D.**  
**Reg. No. G-26527**  
**SAMANVAY HOSPITALS**







SAMANWAY HOSPITALS

# EYE CHECK UP

Reg. No. : \_\_\_\_\_ Date : \_\_\_\_\_

Name : \_\_\_\_\_ Age / Sex : \_\_\_\_\_

	RIGHT EYE	LEFT EYE
DISTANCE : (With / Without Glasses)	6/18	6/6
NEAR VISION : ( With / Without Glasses)	N8	N6
ANTERIOR SEGMENT :	- WNL -	-
IOP (MM of Hg)	- digitally wnl -	-
FUNDUS :	- wnl -	-
COLOR VISION :	- wnl -	-
CLINICAL IMPRESSION :	- (RE) amblyopia -	-
ADVICE :	- Nil -	-

Doctor's Signature: PS Shah





### COMPREHENSIVE HEALTH CHECK UP

Case No. : \_\_\_\_\_ Date : 8/3/25

Name : Neeraj Sharma Age/Sex : 39/M

MEDICAL HISTORY : \_\_\_\_\_

PERSONAL HISTORY : \_\_\_\_\_

Appetite : \_\_\_\_\_ Smoking : \_\_\_\_\_

Sleep : \_\_\_\_\_ H/O Alcohol : \_\_\_\_\_

Bladder : \_\_\_\_\_ Lifestyle : Active

Bowel : \_\_\_\_\_ Exercise : \_\_\_\_\_

DRUG HISTORY : \_\_\_\_\_

PAST HISTORY : \_\_\_\_\_

FAMILY HISTORY : Paternal H/O Diabetes

### GENERAL PHYSICAL EXAMINATION :

Built and Nourishment :

Height : 168cm SP02 98.1

B. P. : 110/80 mm of Hg Weight : 69.5 Kg

Character : \_\_\_\_\_ Pulse : 78 / Min

Nails : \_\_\_\_\_ Odema : \_\_\_\_\_

Tonsils : \_\_\_\_\_ Skin : \_\_\_\_\_

Tongue : \_\_\_\_\_ Sclera : \_\_\_\_\_

Eat. & Joints : \_\_\_\_\_ Glands : \_\_\_\_\_



Adv  
90d. { Tb. ROSEPTA 710 007



Dentist

Pt: Nisay Sharma

Date: 8/3/25

Age 89 male

Obs: Stain + Calculus +  
- Carious +  
- Missing  $\frac{8}{8}$

Adv: Scaling  
- Rest<sup>n</sup> +

