



Shree Ram Multispeciality Hospital (SRMH)

L o k a h S a m a s t a S u k h i n o B h a v a n t u



OPD - ID : 02024 - 2025-0002124
UH-ID : SRMH-25022089

PT. TYPE : FREE OPD
PRINT DATE : 22-02-2025 / 09:45:16



6874558

PATIENT NAME	: MR. MITHLESH KUMAR KACHLAM	OPD-DATE	: 22-Feb-2025 - 09:44 AM
AGE / SEX	: 42-Y 0-M 0-D / MALE	DEPARTMENT	: GENERAL MEDICINE
DOB	:	CONSULTANT	: DR. AJIT KUMAR
OB-NO	: 9644516860	COMPANY NAME	: SHREE RAM MULTISPECIALITY HOSPITAL
GUARDIAN NAME	: S/o MR. BHARAT LAL KACHLAM	OPD PAID FEE	: 0.00
ADDRESS	: AAMAKHERWA, RAIPUR, C.G.		

Weight : 72.5 kg Height : 5'8" Temp : 95.7 F B.P. : 133/79 Pulse : 81b/m SPO2 : 94%



● Near Railway Under Bridge, Basant Vihar Gate No. 1, Gondwara Chowk, Gudhiyari, Raipur (Chhattisgarh)

☎ 0771-43 43 161, 0771-43 40 162, 📞 8404 8404 79

✉ shreeramhospital.op@gmail.com 🌐 www.srmhraipur.com





Shree Ram Multispeciality Hospital (SRMH)

L o k a h S a m a s t a S u k h i n o B h a v a n t u



D - ID	:02024-2025-0002124	PT.TYPE	:NEW REGISTRATION
-ID	:SRMH-25022089	PRINTDATE	:22-02-2025/09:50AM
TIENTNAME	:MR. MITHLESH KUMAR KACHLAM	DEPARTMENT	:ENT
E/SEX	:42Y/ M D / MALE	DOB	:
NSULT-DATE	:22/02/2025	COMPANYNAME	:MEDIWHEEL
IB-NO	:9644516860	OPDPAIDFEE	:0.00
ARDIANNNAME	:S/O MR. BHARAT LAL KACHLAM		
DRESS	:AAMAKHERWA MANENDRAGARH, KORIYA		
ght :	Temp :	B.P. :	Pulse :
			SPO2 :

Indicate whether you are presently suffering from anyone of the following symptoms:

	Yes	No
--	-----	----

Nose, Mouth, Throat

ear pain	0	0
ear itch	0	0
ear drainage	0	0
dizziness/ Loss of balance	0	0
loss of Hearing	0	0
ringing Noise	0	0
vertigo	0	0
nosebleeds	0	0
post-nasal Drip	0	0
facial pain	0	0
facial pressure	0	0
nasal congestion	0	0
loss of smell/taste	0	0
metallic taste	0	0
hoarse Throat	0	0
throat tickle	0	0
dry Mouth / Throat	0	0
throat clearing	0	0
choking	0	0

Present chief complaints:-

Signature

FOLLOW-UP DATE

ADVICE FOR ADMISSION

Near Railway Under Bridge, Basant Vihar Gate No. 1, Gondwara Chowk, Gudhiyari, Raipur (Chhattisgarh)

☎ 0771-43 43 161, 0771-43 40 162, 📞 8404 8404 79

✉ shreeramhospital.op@gmail.com 🌐 www.srmhraipur.com





Shree Ram Multispeciality Hospital (SRMH)

Lokah Samasta Sukhino Bhavantu



NAME : MR. MITHLESH KUMAR KACHLAM
E NO : 9644516860 TEST NO 1400
DR : DR. AJIT KUMAR
ORDERED BY : SELF

AGE / SEX : 42Y/MALE
UH ID NO. : SRMH-25022089
COLLECTION : 22-02-2025
REPORTING : 22-Feb-2025

HAEMATOLOGY

TEST NAME	RESULT	UNIT	NORMAL VALUES
BLOOD GROUPING AND RH TYPING			
BLOOD GROUP	"A"		-
RH FACTOR	POSITIVE		-
CBC (COMPLETE BLOOD COUNT)			
HAEMOGLOBIN (Hb)	11.7	gm%	13.5 - 17.5
TOTAL RBC COUNT	4.01	Million/cumm	4.5 - 5.9
HAEMATOCRIT (PCV)	35.1	%	41.5 - 50.4
RBC INDICES			
MCV	100.1	f l	78 - 96
MCH	29.1	pg	27 - 32
MCHC	29.0	%	33 - 37
RDW	11.8	%	11 - 16
TOTAL WBC COUNT (TLC)	4600	/cumm	4000 - 11000
DIFFERENTIAL COUNT			
NEUTROPHILS	64	%	40 - 70
LYMPHOCYTES	31	%	22 - 48
EOSINOPHILS	02	%	0 - 6
MONOCYTES	03	%	0 - 8
BASOPHILS	00	%	00 -
PLATELET COUNT	1.09	/cumm	1.50 - 4.50
PCT	0.13	%	0.10 - 0.28
MPV(MEAN PLATELET VOLUME)	12.4	µm ³	8 - 11
PDW	16.6	%	11 - 18

-- End Of Report --

TECHNICIAN

Dr. Dhananjay Prasad
MBBS, MD (Pathologist)

This Report is not for medicolegal purpose

Near Railway Under Bridge, Basant Vihar Gate No. 1, Gondwara Chowk,
Gudhiyari, Raipur (Chhattisgarh)

☎ 0771-43 43 161, 0771-43 40 162, 📞 8404 8404 79

✉ shreeramhospital.op@gmail.com 🌐 www.srmhraipur.com



SHREE RAM MULTISPECIALITY HOSPITAL

Lokah Samasta Sukhino Bhavantu



Near Railway Under Bridge, Basant Vihar Gate No. 1, Gondwara Chowk, Gudhiyari, Raipur (C.G.)

Phone: 0771-4343161, 08404840479 Email: Shreeramhospital.op@gmail.com

MR. MITHLESH KUMAR KACHLAM
 9644516860
 DR. AJIT KUMAR
 SELF

AGE / SEX : 42Y/MALE
 UH ID NO. : SRMH-25022089
 COLLECTION : 22-02-2025
 REPORTING : 22-Feb-2025

TEST NO
 1400

BIOCHEMISTRY

NAME	RESULT	UNIT	NORMAL VALUES
LIVER FUNCTION TEST (LFT)			
BILIRUBIN TOTAL	0.49	mg/dL	0.2 - 1
BILIRUBIN DIRECT	0.21	mg / dl	0.1 - 0.6
BILIRUBIN INDIRECT	0.28	mg / dl	0.1 - 0.4
SGOT	25.5	U / L	0 - 46
SGPT	33.6	U / L	0 - 40
ALKALINE PHOSPHATASE	184.5	U / L	0 - 240
TOTAL PROTEIN	6.39	g / dl	6 - 8
ALBUMIN	3.74	g/dl	3.5 - 5.0
GLOBULIN	2.65	g / dl	2 - 3.5
A/G RATIO	1.41		1 - 2.5

Significance

Alanine transaminase (ALT)
 is an enzyme found in the liver that helps your body metabolize protein. When the liver is damaged, ALT is released into the bloodstream and levels increase.

Aspartate transaminase (AST)
 is an enzyme that helps metabolize alanine, an amino acid. Like ALT, AST is normally present in blood at low levels. A rise in AST levels may indicate liver damage or muscle damage.


Alkaline phosphatase (ALP)
 is an enzyme in the liver, bile ducts and bone. Higher-than-normal levels of ALP may indicate liver damage or disease, such as a blocked bile duct, or certain bone diseases.

Albumin and total protein
 Albumin is one of several proteins made in the liver. Your body needs these proteins to fight infections and to perform other functions. Lower-than-normal levels of albumin and total protein might indicate liver damage or disease.

Bilirubin
 Bilirubin is a substance produced during the normal breakdown of red blood cells. Bilirubin passes through the liver and is excreted in stool. Elevated levels of bilirubin (jaundice) might indicate liver damage or disease or certain types of anemia.

-- End Of Report --


 TECHNICIAN


 Dr. Dhananjay Prasad
 MBBS, MD (Pathologist)

This Report is not for medicolegal purpose

SHREE RAM MULTISPECIALITY HOSPITAL

Lokah Samasta Sukhino Bhavantu



Near Railway Under Bridge, Basant Vihar Gate No. 1, Gondwara Chowk, Gudhiyari, Raipur (C.G.)
Phone: 0771-4343161, 08404840479 Email: Shreeramhospital.op@gmail.com

NAME : MR. MITHLESH KUMAR KACHLAM
NO : 9644516860
R : DR. AJIT KUMAR
ED BY : SELF

AGE / SEX : 42Y/MALE
UH ID NO. : SRMH-25022089
COLLECTION : 22-02-2025
REPORTING : 22-Feb-2025

TEST NO
1400

BIOCHEMISTRY


NAME	RESULT	UNIT	NORMAL VALUES
LIPID PROFILE			
CHOLESTEROL	209.8	mg / dl	150 - 220
SERUM TRYGLYCERIDE	116.7	mg / dl	60 - 165
HDL	36.1	mg / dl	35 - 80
LDL	173.7	mg/dL	90 - 160
VLDL	23.34	mg/dL	20 - 50
CHOLESTEROL / HDL RATIO	5.81	mg/dL	3.5 - 5.5
LDL/HDL Ratio	4.81	mg / dl	2.5 - 3.5

PATHOLOGY

NAME	RESULT	UNIT	NORMAL VALUES
GGT (GAMMA GLUTAMYL TRANSFERASE)			
GGT	14.6	U / L	12.00 - 18.00

-- End Of Report --

CHNICIAN


Dr. Dhananjay Prasad
MBBS, MD (Pathologist)

This Report is not for medicolegal purpose

SHREE RAM MULTISPECIALITY HOSPITAL

Lokah Samasta Sukhino Bhavantu



Near Railway Under Bridge, Basant Vihar Gate No. 1, Gondwara Chowk, Gudhiyari, Raipur (C.G.)
Phone: 0771-4343161, 08404840479 Email: Shreeramhospitalop@gmail.com

NAME : MR. MITHLESH KUMAR KACHLAM
LE NO : 9644516860
FOR : DR. AJIT KUMAR
RED BY : SELF

AGE / SEX : 42Y/MALE
UH ID NO. : SRMH-25022089
COLLECTION : 22-02-2025
REPORTING : 22-Feb-2025

TEST NO
1400

BIOCHEMISTRY

TEST NAME	RESULT	UNIT	NORMAL VALUES
-----------	--------	------	---------------

BUN (BLOOD UREA NITROGEN)

BUN	12.2	mg / dl	7.00 - 20.00
Serum Creatinine	0.81	mg / dl	0.55 - 1.20
BUN / Creatinine Ratio	15.06		10.1 - 20.1

UREA AND CREATININE

SERUM CREATININE	0.81	mg/dL	0.6 - 1.2
SERUM URIC ACID	4.98	mg/dL	3.6 - 7.7

IMMUNOASSAY

TEST NAME	RESULT	UNIT	NORMAL VALUES
-----------	--------	------	---------------

SERUM PSA TOTAL

PSA (TOTAL)	1.10	ng/mL	0 - 4
--------------	------	-------	-------

-- End Of Report --

TECHNICIAN

This Report is not for medicolegal purpose

Dr. Dhananjay Prasad
MBBS, MD (Pathologist)

SHREE RAM MULTISPECIALITY HOSPITAL

Lokah Samasta Sukhino Bhavantu



Near Railway Under Bridge, Basant Vihar Gate No. 1, Gondwara Chowk, Gudhiyari, Raipur (C.G.)
Phone: 0771-4343161, 08404840479 Email: Shreeramhospital.op@gmail.com

MR. MITHLESH KUMAR KACHLAM	AGE / SEX : 42Y/MALE	TEST NO
9644516860	UH ID NO. : SRMH-25022089	1400
DR. AJIT KUMAR	COLLECTION : 22-02-2025	
BY: SELF	REPORTING : 22-Feb-2025	

HAEMATOLOGY

NAME	RESULT	UNIT	NORMAL VALUES
ESR (ERYTHROCYTE SEDIMENTATION RATE)			
ESR	10	mm at end of 1 h	0 - 20

IMMUNOASSAY

TEST NAME	RESULT	UNIT	NORMAL VALUES
THYROID PROFILE (T3, T4, TSH)			
T3 (TRIIODOTHYRONINE)	1.01	ng/ml	0.8 - 2
T4 (THYROXINE)	8.41	ug/dl	5.13 - 14.06
TSH	1.02	uIU/ml	0.27 - 4.2

-- End Of Report --

TECHNICIAN

Dr. Dhananjay Prasad
MBBS, MD (Pathologist)

Note: This Report is not for medicolegal purpose

SHREE RAM MULTISPECIALITY HOSPITAL

Lokah Samasta Sukhino Bhavantu



Near Railway Under Bridge, Basant Vihar Gate No. 1, Gondwara Chowk, Gudhiyari, Raipur (C.G.)
 Phone: 0771-4343161, 08404840479 Email: Shreeramhospitalop@gmail.com

NAME : MR. MITHLESH KUMAR KACHLAM	AGE / SEX : 42Y/MALE	TEST NO
MOBILE NO : 9644516860	UH ID NO. : SRMH-25022089	1400
CTOR : DR. AJIT KUMAR	COLLECTION : 22-02-2025	
REFERRED BY : SELF	REPORTING : 22-Feb-2025	

BIOCHEMISTRY

TEST NAME	RESULT	UNIT	NORMAL VALUES
BLOOD SUGAR - FASTING AND PP			
BLOOD SUGAR FASTING	90.8	mg/dL	70 - 110
BLOOD SUGAR PP	115.6	mg/dL	80 - 140

HbA1c -Glycosylated hemoglobin

HbA1c -Glycosylated hemoglobin	4.69	%	Normal Range : <6% Good Control : 6-7% fair Control : 7-8% Unsatisfactory Control : 8-10% Poor Control : >10% - 80 - 120
Estimated average plasma glucose	89.66	mg/dl	

CLINICAL PATHOLOGY

TEST NAME	RESULT	UNIT	NORMAL VALUES
URINE SUGAR FASTING AND PP			
URINE SUGAR FASTING	Absent		Absent -
URINE SUGAR PP	Absent		Absent -

-- End Of Report --

LAB TECHNICIAN

Dr. Dhananjay Prasad
 MBBS, MD (Pathologist)

Note : This Report is not for medicolegal purpose

SHREE RAM MULTISPECIALITY HOSPITAL

Lokah Samasta Sukhino Bhavantu

Near Railway Under Bridge, Basant Vihar Gate No. 1, Gondwara Chowk, Gudhiyari, Raipur (C.G.)
 Phone: 0771-4343161, 08404840479 Email: Shreeramhospital.op@gmail.com



NAME : MR. MITHLESH KUMAR KACHLAM
 ID NO : 9644516860
 DR : DR. AJIT KUMAR
 ORDERED BY : SELF

AGE / SEX : 42Y/MALE
 UH ID NO. : SRMH-25022089
 COLLECTION : 22-02-2025
 REPORTING : 22-Feb-2025

TEST NO
 1400

CLINICAL PATHOLOGY

TEST NAME	RESULT	UNIT	NORMAL VALUES
-----------	--------	------	---------------

URINE ROUTINE AND MICROSCOPY

PHYSICAL EXAMINATION

QUANTITY	20	ml	-
COLOUR	Pale Yellow		Pale Yellow -
APPEARANCE	Clear		Clear -
REACTION	Acitic		Acitic -

CHEMICAL EXAMINATION

ALBUMIN	Absent		Absent -
SUGAR	Absent		Absent -
KETONE	Absent		Absent -
BILE SALT	Absent		Absent -
BILE PIGMENT	Absent		Absent -

MICROSCOPIC EXAMINATION

PUS CELLS	3-4	/hpf	2 - 5
EPITHELIAL CELLS	2-3	/hpf	1 - 5
RBC	Nil	/hpf	0 - 3
CAST	Nil	/lpf	Nil -
YEAST	Nil		Nil -
CRYSTAL	Nil	/lpf	Nil -
BACTERIA	Nil		Nil -
OTHERS	-		-

-- End Of Report --

LAB TECHNICIAN

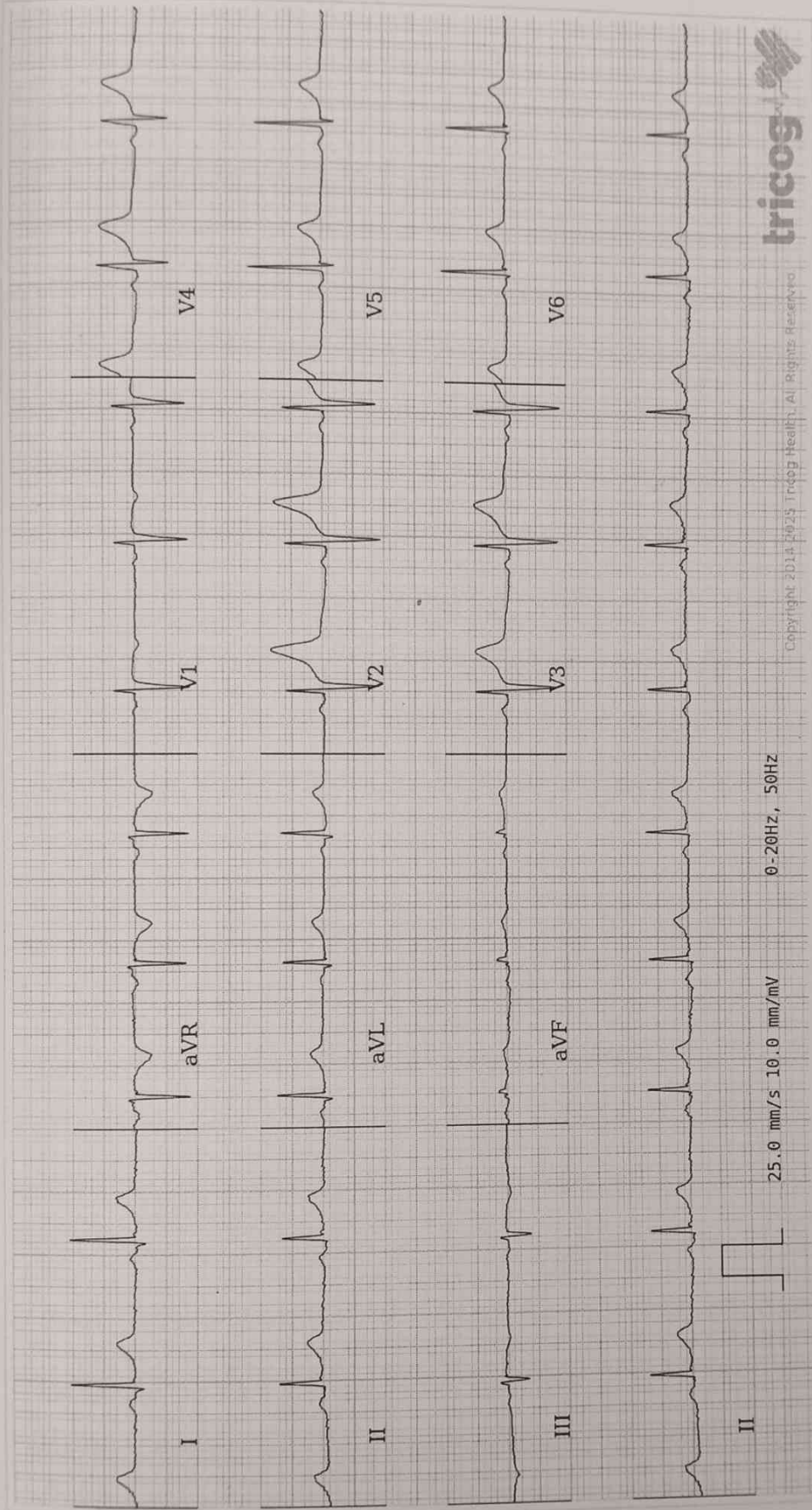
Dr. Dhananjay Prasad
 MBBS, MD (Pathologist)

Note: This Report is not for medicolegal purpose



Age / Gender: 41/Male
Patient ID: 5
Patient Name: Mithlesh

Date and Time: 22nd Feb 25 12:33 PM



Copyright 2014-2023 Tricog Health. All Rights Reserved

0-20Hz, 50Hz

25.0 mm/s 10.0 mm/mV

AR: 66bpm VR: 67bpm QRSd: 80ms QT: 378ms QTcB: 399ms PRI: 154ms P-R-T: 29° 16° 20°

Disclaimer: Analysis in this report is based on ECG alone and should only be used as an adjunct to clinical history, symptoms and results of other invasive and non-invasive tests and must be interpreted by a qualified physician.



Bhawani

DIAGNOSTIC CENTRE

Near Wallfort Ozone, Fafadih Chowk,
Raipur (C.G.) Ph.: 0771-4017333

www.bhawanidiagnostic.com



3 Tesla M.R.I.



96 Slice CT Scan



5D Color Doppler Sonography



Digital X-Ray O.P.G./CEPH.



Dexa-Scan/BMD



Mammography



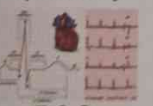Hi-Tech Pathology



EEG, EMG




Spirometry



E.C.G.



LITHOTRIPSY



Uroflowmetry

PT. NAME: MR. MITHLESH KUMAR

AGE/SEX: 41 Y/M

REF. DR. BY : SHREE RAM SHANTI HOSPITAL

DATE 22/02/2025

USG STUDY OF WHOLE ABDOMEN

OBSERVATIONS :

LIVER:- The liver is normal in size, shape and has smooth margins. It has increased echotexture, has normally distributed and normal size biliary and portal radicals and is without solid or cystic mass lesion or calcification.

PORTAL VEIN :- It measures normal in size & is normal in its intra & extra hepatic course . It shows normal variation in size during respiration.

GALL BLADDER:- The gall bladder is seen as a well distended, pear shaped bag with uniformly thin and regular walls, without, gall stones or mass lesions.

COMMON BILE DUCT:- The common bile duct is normal in caliber. Its measures 2.1 mm at porta hepatis. No evidence of calculus is noted in common bile duct.

PANCREAS:- The pancreas is normal in size, shape, contours and echotexture. No evidence of solid or cystic mass lesion is noted.

KIDNEYS:- The Right kidney measures: 10.9 X 4.0 cm. Normal in Size, Shape & Echotexture. No Evidence Of Calculi or hydronephrosis seen , Corticomedullary Differentiation Normal.

The Left kidney measures:- 11.0 X 4.7cm. Normal in Size, Shape & Echotexture. No Evidence Of Calculi or hydronephrosis seen. Corticomedullary Differentiation Normal.

URINARY BLADDER:- The urinary bladder is well distended. It shows uniformly thin walls and sharp mucosa. No evidence of calculus is seen. No evidence of mass or diverticulum is noted.

SPLEEN: The spleen is normal in size, shape. Its echotexture is homogeneous. No evidence of focal lesion is noted.

PROSTATE:- Appear normal in size. Normal in shape and echotexture.

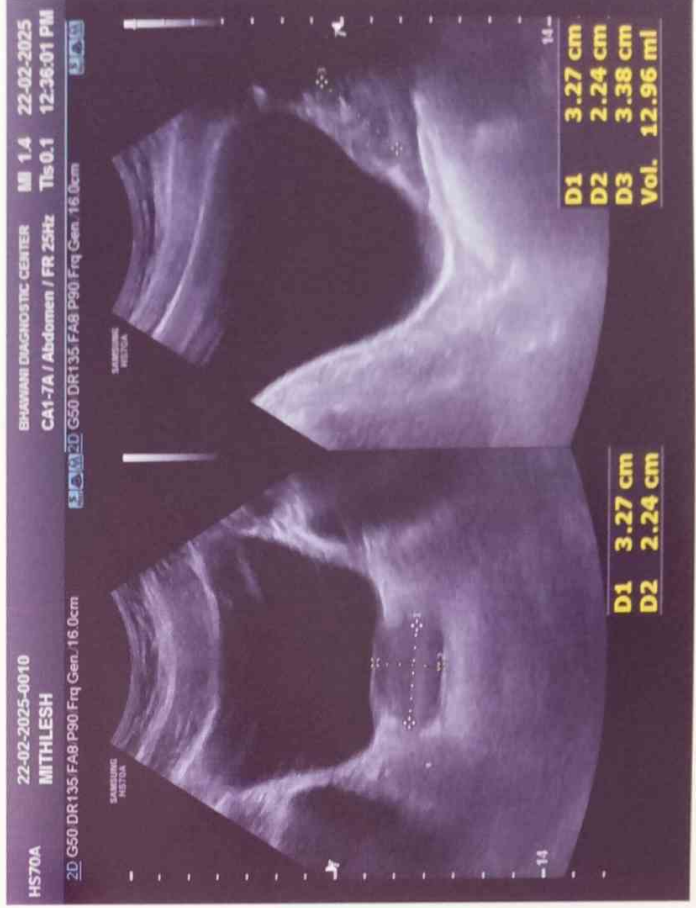
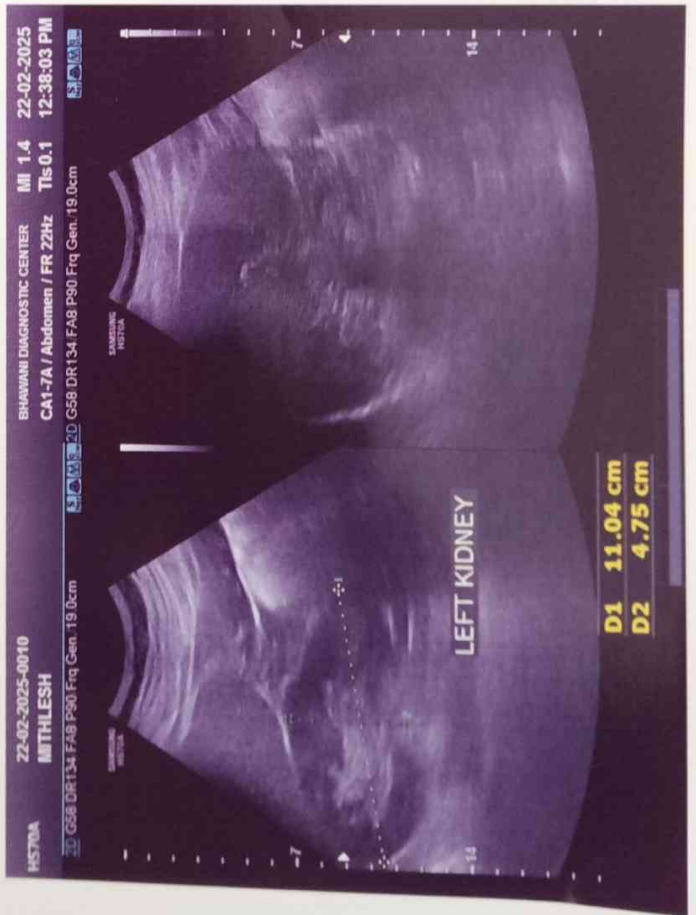
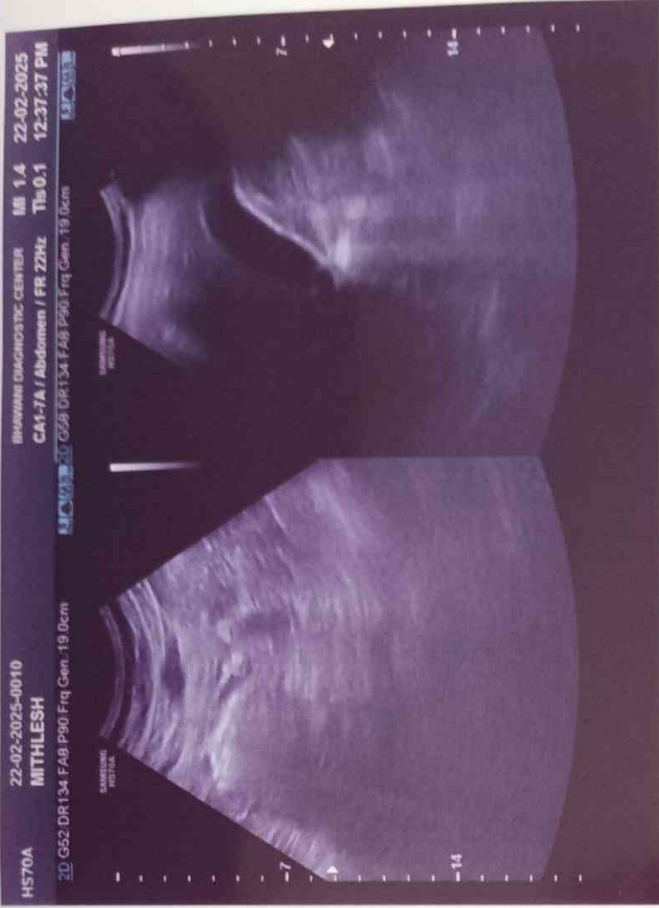
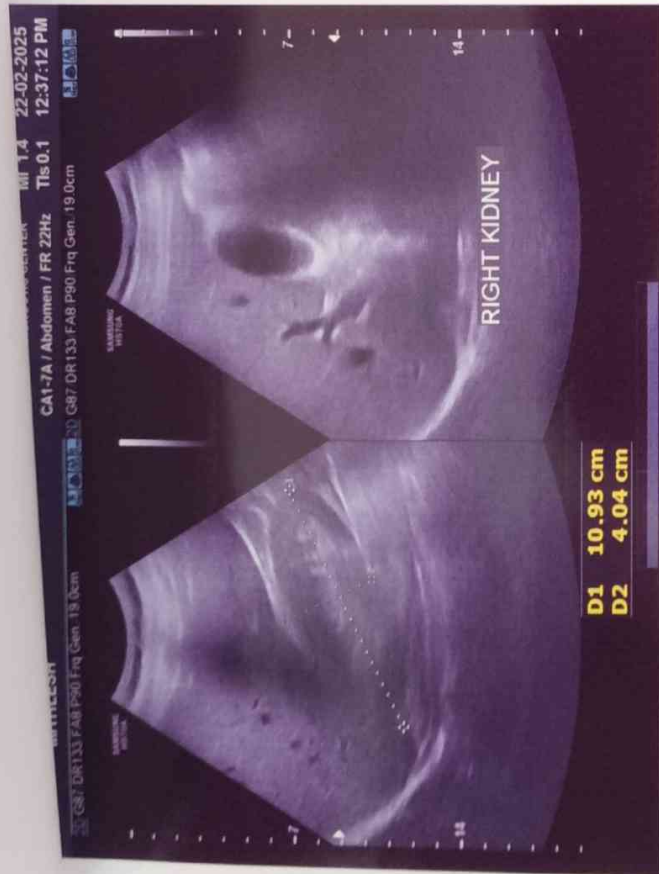* No ASCITES, No pleural effusion.

* No ABDOMINAL lymphadenopathy.

IMPRESSION:- GRADE I FATTY LIVER.

DR. UJWALA GOSWAMI
MD

RADIOLOGIST & SONOLOGIST



MR. MITHLESH KUMAR

REF BY:

SHREE RAM MULTISPECIALTY HOSPITAL, INFRONT GONDWARA UNDERBRIDGE, GUDHIYARI RAMPUR, PH: 0771-4343161

42 year(s)

Male

Chest Chest PA

22/02/2025 10:27:53 AM

