



**MEDICOVER  
HOSPITALS**

A UNIT OF SAHRUDAYA HEALTHCARE PVT LTD.

# Medicover Hospitals

VENKOJIPALAM VISAKHAPATNAM - 530017

ANDHRA PRADESH - INDIA

PHONE NO : 0891-6829999

**Dr. REDDY THRIVENI**  
**MBBS, MD**  
**INTERNAL MEDICINE**

NAME : B. VENKATAPANASI AGE 37

Uric acid - 8.3  
↑ G. 272

WT: 57 kg  
BP: 140/80 mm  
PR 60/min

R  
T. Adilip 135mg  
LPHI x (90)  
T. Febustal 40mg  
LPHI x (15)

Review  
in 3  
month

Uplid  
Profelo A

R



**MEDICOVER  
HOSPITALS**

A UNIT OF SAHRUDAYA HEALTHCARE PVT LTD

**Medicover Hospitals**  
VENKOJIPALAM VISKHAPATNAM -530017  
ANDHRA PRADESH -INDIA  
PHONO NO : 0891-6829999

**OPHTHALMOLOGIST CONSULTATION**

NAME: Venkata Venay's AGE: \_\_\_\_\_

DATE: 9/11/24

Vn f G19P.  
c 6/6  
gram

no complaint  
←

Answer

hul f odh / m  
odh / m

Diag: - Myopia

Xlu  
gram

ARJ SV

Q



**MEDICOVER  
HOSPITALS**

A UNIT OF SAHRUDAYA HEALTHCARE PVT LTD.

## MEDICOVER HOSPITALS

VENKOJIPALEM VISAKHAPATNAM -530017  
ANDHRA PRADESH -INDIA  
PHOppNE NO ; 0891-6829999

### Dr. DENTAL CONSULTATION CONSULTANT DENTAL

NAME : B, VENKATA NAWAJI

AGE : 37/M

clo discoloration in the ant front tooth.

D/E Class I Ellis fracture +

Adv RCT with crown +

calculus +

stain +

Adv oral prophylaxis

**Medicover Unit - I**  
# 18-1-3, KGH Down, Maharani-peta,  
Jagadamba Junction, Visakhapatnam  
Andhrapradesh - 530 002.  
Ph: +91 96526 69351

**Medicover Unit - III**  
Sry. No.27, Plot No.05, BRTS Road,  
Health City, Arilova, Chinnagadhili Mandal,  
Visakhapatnam, Andhrapradesh - 530 040.  
Ph: +91 0891 6677888

**Medicover - MVP**  
# 1-1-83, Sector-6, Venkojipalem,  
MVP Colony, Visakhapatnam,  
Andhrapradesh-530017.  
Ph: +91 8886655677



**MEDICOVER  
HOSPITALS**

A UNIT OF SATHUDATA HEALTHCARE PVT LTD.

: Mr.BARATAM VENKATA NANAJI

Age /Sex

37 Y (S)/MALE

Bill No.

: MCB48241104985

UMR No.

: 482411001337

### LABORATORY REPORT : BIOCHEMISTRY

Parameters	Result	Reference Range	Units
<b>PLBS (POST LUNCH BLOOD GLUCOSE )</b>			
( Bill Date : 09-Nov-2024 10:15 AM      Result ID : RU4241112015)			
POST LUNCH BLOOD GLUCOSE <i>Hexokinase</i>	102	Normal Range : <140 Impaired Glucose Tolerance : 140 -199 Diabetes Mellitus: >=200	mg/dL

*Md. Simi Iqbal*

DR.MOHAMMAD SIMI IQBAL  
M.B.B.S, M.D CONSULTANT  
BIOCHEMIST



**MEDICOVER  
HOSPITALS**

<b>Name</b>	: Mr. BARATAM VENKATA NANAJI	<b>Age /Sex</b>	: 37 Y (S)/MALE
<b>Bill No.</b>	: MCB48241104985	<b>UMR No.</b>	: 482411001337

**LABORATORY REPORT : BIOCHEMISTRY**

Parameters	Result	Reference Range	Units
<b>BUN(BLOOD UREA NITROGEN)</b>			
( Bill Date : 09-Nov-2024 08:41 AM      Result ID : RU4241112011)			
BLOOD UREA <i>Urease kinetic</i>	17	16.6 - 48.5	mg/dL
<b>HBA1C (GLYCOSYLATED HAEMOGLOBIN)</b>			
( Bill Date : 09-Nov-2024 08:41 AM      Result ID : RU4241112012)			
HBA1C <i>Turbidimetric inhibition immunoassay</i>	5.4	Normal : <= 5.6% Pre diabetic : 5.7 % - 6.4 % Diabetic : >= 6.5 %	%
<b>LIPID PROFILE</b>			
( Bill Date : 09-Nov-2024 08:41 AM      Result ID : RU4241112013)			
TOTAL CHOLESTEROL <i>Enzymatic colorimetric</i>	155	Desirable :: < 200 mg/dL Borderline High :: 200 - 239 mg/dL High risk : > 240 mg/dL	mg/dL
HDL CHOLESTEROL <i>Homogeneous enzymatic colorimetric</i>	26	Low :: < 40 mg/dL High :: > 60 mg/dL	mg/dL
LDL CHOLESTEROL <i>Direct-Enzymatic colorimetric</i>	75	Very High : - > 190 mg/dL Optimal : - < 100 mg/dL Near Optimal : 100 - 129 mg/dL High : 160 - 189 mg/dL Borderline High:130-159 mg/dl	mg/dL
VLDL <i>Calculation</i>	54 *	2 - 30 mg/dL	mg/dL
SERUM TRYGLYCERIDES <i>Enzymatic colorimetric</i>	272 *	< 150 mg/dL Borderline High : 150 - 199 mg/dL High : 200 - 499 mg/dL	mg/dL
CHO/HDL RATIO <i>Calculation</i>	5.96 *	Normal : - < 3.5 High Risk : - > 5.0	
LDL/HDL RATIO	2.88		
<b>FBS (FASTING BLOOD GLUCOSE WITH URINE GLUCOSE)</b>			
( Bill Date : 09-Nov-2024 08:41 AM      Result ID : RU4241112014)			
FASTING BLOOD GLUCOSE <i>Hexokinase</i>	96	Normal Range : 70 - 99 Impaired Glucose tolerance : 100 -125 Diabetes Mellitus : >=126	mg/dL



<b>Name</b>	: Mr. BARATAM VENKATA NANAJI	<b>Age /Sex</b>	: 37 Y (S)/MALE
<b>Bill No.</b>	: MCB48241104985	<b>UMR No.</b>	: 482411001337

**SERUM CREATININE**

( Bill Date : 09-Nov-2024 08:41 AM      Result ID : RU4241112015)

CREATININE	0.6 *	0.7 - 1.2	mg/dL
<i>Jaffe</i>			

**BUN / CREATININE RATIO**

( Bill Date : 09-Nov-2024 08:41 AM      Result ID : RU4241112016)

BUN / CREATININE RATIO	13.23	10-20 mg/dL	mg/dL
<i>CALCULATED</i>			

**T3,T4 AND TSH**

( Bill Date : 09-Nov-2024 08:41 AM      Result ID : RU4241112017)

T3	1.32	0.8 - 2.0	ng/mL
<i>ECLIA</i>			

T4	11.46	5.1 - 14.1	ug/dL
<i>ECLIA</i>			

TSH(THYROID STIMULATING HORMONE)	1.81	0.270 - 4.20	uIU/mL
<i>ECLIA</i>			

**LFT(LIVER FUNCTION TEST)**

( Bill Date : 09-Nov-2024 08:41 AM      Result ID : RU4241112018)

TOTAL BILIRUBIN	0.6	<1.2	mg/dL
<i>DIAZO</i>			

DIRECT BILIRUBIN	0.2	<=0.20	mg/dL
<i>DIAZO</i>			

INDIRECT BILIRUBIN	0.4	<=1.0	mg/dL
<i>CALCULATION</i>			

SGPT (ALT)	44 *	<=41	U/L
<i>UV without P5P</i>			

SGOT (AST)	40	<=40	U/L
<i>UV without P5P</i>			

ALKALINE PHOSPHATASE (ALP)	56	40-129 U/L	U/L
<i>PNPP, AMP Buffer - IFCC Ref.</i>			

TOTAL PROTEINS	7.5	6.0 - 8.0 g/dL	g/dL
<i>Biuret method</i>			



**MEDICOVER  
HOSPITALS**

Name : Mr. BARATAM VENKATA NANAJI  
Bill No. : MCB48241104985

Age /Sex : 37 Y(S)/MALE  
UMR No. : 482411001337  
DAYA HEALTHCARE PVT LTD.

SERUM ALBUMIN 4.5 3.5 - 5.2 g/dL g/dL  
Bromocresol Green (BCG)

**SERUM URIC ACID**

( Bill Date : 09-Nov-2024 08:41 AM Result ID : RU4241112019)

SERUM URIC ACID 8.3 \* 3.4-7.0 mg/dL  
uricase

*Md. Simi Iqbal*

DR.MOHAMMAD SIMI IQBAL  
M.B.B.S, M.D CONSULTANT  
BIOCHEMIST



**MEDICOVER  
HOSPITALS**

Name : Mr. BARATAM VENKATA NANAJI Age /Sex : 37 Y Y(S)/MALE  
Bill No. : MCB48241104985 UMR No. : 482411001337  
DAYA HEALTHCARE PVT LTD.

**LABORATORY REPORT : BLOOD BANK**

Parameters Result Reference Range Units

**BLOOD GROUPING AND RH**

( Bill Date : 09-Nov-2024 08:41 AM Result ID : RU4241112021)

BLOOD GROUP "O"  
*Automated microcolumn gel method*

RH TYPE POSITIVE

**INTERPRETATION**

1. If Rh is Du positive it is best considered as Rh negative as recipient and Rh positive as donor. Proper Cross matching is recommended before transfusion.
2. In case of forward and reverse grouping discrepancy, clinical correlation and repeat sample analysis is recommended.
3. For Infants below 6 months only forward grouping is performed.
4. A sub-grouping is recommended after the age of 6 months.

*Handwritten signature*

Dr. K.S. Sarat Srinivas, MBBS, MD.  
CONSULTANT PATHOLOGIST





**MEDICOVER  
HOSPITALS**

Name : Mr. BARATAM VENKATA NANAJI  
Bill No. : MCB48241104985

Age /Sex : 37Y Y(S)/MALE  
UMR No. : 482411001337  
A UNIT OF SAMRUDDHA HEALTHCARE PVT LTD.

**LABORATORY REPORT : CLINICAL PATHOLOGY**

Parameters	Result	Reference Range	Units
<b>CUE(COMPLETE URINE EXAMINATION)</b>			
( Bill Date : 09-Nov-2024 08:41 AM      Result ID : RU4241112020)			
SPECIFIC GRAVITY	1.015	1.000 - 1.030	
PH	6.5	5.0 - 8.0	
PROTEIN	NIL	NIL (<15 mg/dL)	
GLUCOSE	NIL	NIL (<25 mg/dL)	
UROBILINOGEN	NIL	NIL	
KETONE	NIL	NIL (<5 mg/dL)	
BLOOD	NIL		
BILIRUBIN	NIL	NIL (<0.5 mg/dL)	
NITRITE	NIL	NEGATIVE	
LEUCOCYTES	NIL		

**MICROSCOPIC EXAMINATION**

PUS CELLS	3-5	0 - 5 /hpf
EPITHELIAL CELLS	2-3	0 - 5 /hpf
RBC	NIL	0 - 5 /hpf
CASTS	NIL	NIL
CRYSTALS	NIL	NIL

*Handwritten signature*

Dr. K.S. Sarat Srinivas, MBBS, MD.  
CONSULTANT PATHOLOGIST



**MEDICOVER  
HOSPITALS**

<b>Name</b>	: Mr. BARATAM VENKATA NANAJI	<b>Age /Sex</b>	: 37Y Y(S)/MALE
<b>Bill No.</b>	: MCB48241104985	<b>UMR No.</b>	: 482411001337

**LABORATORY REPORT : HAEMATOLOGY**

Parameters	Result	Reference Range	Units
<b>ESR</b>			
( Bill Date : 09-Nov-2024 08:41 AM      Result ID : RU4241112022)			
ESR <i>MODIFIED WESTERGREN'S METHOD</i>	08	0 - 10	mm/1st hour

**CBP(COMPLETE BLOOD PICTURE)**

Parameters	Result	Reference Range	Units
( Bill Date : 09-Nov-2024 08:41 AM      Result ID : RU4241112023)			
HEMOGLOBIN <i>Photometric</i>	15.4	13.0 - 17.0 gms/dL	gms/dL
R B C COUNT <i>Electrical Impedance</i>	5.10	4.5 - 5.5 10 <sup>12</sup> /L	10 <sup>12</sup> /L
PCV/HCT <i>Calculated</i>	43.9	40 - 50	%
MCV <i>Calculated</i>	85.9	83 - 101	fl
MCH <i>Calculated</i>	30.1	27 - 32	pg
MCHC <i>Calculated</i>	35.0	31 - 37	g/dL
RDW(cv)	15.6 *	11.6 - 14.0 %	%
TLC (TOTAL LEUCOCYTE COUNT) <i>Impedance</i>	7.84	4.0 - 11.0	10 <sup>3</sup> /μl
NEUTROPHILS <i>DHSS/Microscopy</i>	65	40 - 80 %	
LYMPHOCYTES <i>DHSS/Microscopy</i>	27	20 - 40 %	
MONOCYTES <i>DHSS/Microscopy</i>	05	02 - 10 %	
EOSINOPHILS <i>DHSS/Microscopy</i>	03	00 - 06 %	
BASOPHILS <i>DHSS/Microscopy</i>	00	00 - 01 %	



**MEDICOVER  
HOSPITALS**

Name : Mr. BARATAM VENKATA NANAJI  
Bill No. : MCB48241104985

Age /Sex : 37 Y (S)/MALE  
UMR No. : 482411001337  
MOH OF SAMRUDDHA HEALTHCARE PVT LTD.

PLATELET COUNT  
Electrical Impedance

232

150 - 400  $10^3/\mu\text{L}$

$10^3/\mu\text{L}$

*Forward*

Dr. K.S. Sarat Srinivas, MBBS, MD.  
CONSULTANT PATHOLOGIST



Mr. BARATAM VENKATA NANAJI

Bill Date : 09-Nov-2024 08:41 AM

Rec. Dt : 09-Nov-2024 11:30 AM

Rept Dt : --

Ref By : Dr. ER PHYSICIAN

Age/Sex : 037Y/MALE

UMR No : 482411001337

Bill No : HC482411000443\_9

Result No : HC482411000443\_9

Ref Unit : --

A UNIT OF SAHRUDAYA HEALTHCARE PVT LTD.



### Cardiology 2D Echo With Colour Doppler

#### MEASUREMENTS :

LVID (d) : 4.2 Cms

LVID (s) : 3.0 Cms

LVEF : 60 %

IVSD (d) : 1.0 Cms

PWD (d) : 1.0 Cms

#### VALVES :

Mitral Valve : NORMAL

Aortic Valve : NORMAL

Tricuspid Valve : NORMAL

Pulmonary Valve : NORMAL

#### CHAMBERS :

Right Atrium : NORMAL

A UNIT OF SAHRUDAYA HEALTHCARE PVT LTD.



Name : Mr. BARATAM VENKATA NANAJI

Age/Sex : 037Y/MALE

Bill Date : 09-Nov-2024 08:41 AM

UMR No : 482411001337

Rec. Dt : 09-Nov-2024 11:30 AM

Bill No : HC482411000443\_9

Rept Dt : --

Result No : HC482411000443\_9

Ref By : Dr. ER PHYSICIAN

Ref Unit : --



Right Ventricle : NORMAL

Left Atrium : 3.0 Cms

Left Ventricle : NORMAL

RWMA : NO

Dystolic Function : GOOD

Diastolic Dysfunction : NO

Clot : NO

InterAtrial Septum : INTACT

InterVentricular Septum : INTACT

GREAT ARTERY AND OTHERS :

Aorta : 2.7 Cms

Pulmonary Artery : NORMAL

Pericardium : NORMAL

SVC / IVC / CS : NORMAL

A UNIT OF SAHRUDAYA HEALTHCARE PVT LTD.



Name : Mr. BARATAM VENKATA NANAJI

Age/Sex : 037Y/MALE

Bill Date : 09-Nov-2024 08:41 AM

UMR No : 482411001337

Rec. Dt : 09-Nov-2024 11:30 AM

Bill No : HC482411000443\_9

Rept Dt : --

Result No : HC482411000443\_9

Ref By : Dr. ER PHYSICIAN

Ref Unit : --

**DOPPLER STUDY :**

Mitral Flow : E > A

Aortic Flow : 1.2 M/sec

Pulmonary Flow : 1.0 M/sec

Tricuspid Flow : NORMAL

Other Flows : NIL

**COLOUR DOPPLER :**

MR : NO

AR : NO

TR : NO

**FINAL IMPRESSION :**

\* NO RWMA OF LV

\* GOOD LV SYSTOLIC FUNCTION (EF : 60 %)

\* NO MR / AR / TR

A UNIT OF SAHRUDAYA HEALTHCARE PVT LTD.



**MEDICOVER**  
HOSPITALS

Name : Mr. BARATAM VENKATA NANAJI

Bill Date : 09-Nov-2024 08:41 AM

Rec. Dt : 09-Nov-2024 11:30 AM

Rept Dt : --

Ref By : Dr. ER PHYSICIAN

Age/Sex : 037Y/MALE

UMR No : 482411001337

Bill No : HC482411000443\_9

Result No : HC482411000443\_9

Ref Unit : --

A UNIT OF SAHRUDAYA HEALTHCARE



**DR.B.SRIKANTH, MD,DM**

**CONSULTANT CARDIOLOGIST**

DRAFT

A UNIT OF SAHRUDAYA HEALTHCARE PVT LTD.

Medicover Unit - I  
# 18-1-3, KGH Down, Maharani-peta,  
Jagadam, Visakhapatnam  
Andhrapradesh - 530 002.  
Ph: +91 9827089311  
medicoverhospitals.in

Medicover Unit -III  
Sry.No.27, Plot No.05, BRTS Road,  
Health City, Arilova, Chinnagadhili Mandal,  
Visakhapatnam, Andhrapradesh - 530 040.  
Ph: +91 0891 6677888

Medicover - MVP  
# 1-1-83, Sector 6, Venkojipalem,  
MVP Colony, Visakhapatnam,  
Andhrapradesh 530017.  
Ph: +91 8886655677



Patient ID:	482411001337	Patient Name:	B VENKATANAMA H
Age:	37 Years	Sex:	M
Accession Number:		Modality:	DX
Referring Physician:		Study:	CHEST
Study Date:	09-Nov-2024		

### X-RAY CHEST - PA VIEW

#### **Findings :**

Trachea central and appears normal.

Cardiac silhouette appears normal.

Both hila appear normal.

Visualised both lung fields clear.

Both costophrenic angles clear.

Visualised bony thorax and soft tissues appear normal.

#### **IMPRESSION:**

\* **No significant abnormality detected .**

  
VULAPU CHENNAKRISHNA RAO, .  
MBBS, DNB  
CONSULTANT RADIOLOGIST

Date: 09-Nov-2024 11:09:47

#### **Medicover Unit - I**

# 18-1-3, KGH Down, Maharani-peta,  
Jagadamba Junction, Visakapatnam,  
Andhrapradesh - 530 002.  
Ph : +91 96526 69351

#### **Medicover Unit - III**

Sry. No. 27, Plot No. 05, BRTS Road,  
Health City, Arilova, Chinagadili mandal,  
Visakhapatnam, Andhrapradesh-530 040.  
Ph: +91 08916677888

#### **Medicover - MVP**

# 1-1-83, Sector-6, Venkojipalem,  
MVP Colony, Visakapatnam,  
Andhrapradesh-530017.  
Ph : +91 8886655677





Patient ID:	482411001337	Patient Name:	B VENKATA NANAJI A UNIT OF SAHRIIDAYA HEALTHCARE PVT LTD.
Age:	37	Sex:	M
Accession Number:		Modality:	US
Referring Physician:		Study:	USG ABDOMEN
Study Date:	09-Nov-2024		

### USG ABDOMEN (MALE)

#### Findings:

##### **Liver:**

Measuring 13.9 cm. Normal in size with normal homogeneous echotexture. Calcification of size measuring 3 mm noted in right lobe of liver.

There is no evidence of IHBR/EHBR dilatation seen. The portal, hepatic vessels are normal.

##### **Gall bladder:**

Normal in volume and wall thickness. No evidence of intraluminal calculi/ masses seen. C.B.D appears normal with no intraluminal mass/ calculi.

##### **Pancreas:**

Head, Body & Tail are identified with normal echopattern & smooth outlines. The pancreatic duct system appears normal. The peri pancreatic fat planes are well preserved.

##### **Spleen:**

Normal in size (10.4 cm) with homogenous echotexture.

##### **Right kidney:**

Measuring 8.6 cm. Normal in size and echopattern. Cortico-Medullary differentiation is normal. No evidence of mass / calculi / hydronephrosis seen.

##### **Left kidney:**

Measuring 9.2 cm. Normal in size and echopattern. Cortico-Medullary differentiation is normal. No evidence of mass / calculi / hydronephrosis seen.

##### **Urinary bladder:**

Partially distended. Wall thickness is normal. No intraluminal mass / calculi noted.

##### **Prostate:**

Normal in size and echopattern. No evidence of ascites/ pleural effusion seen.

#### Medicover Unit - I

# 18-1-3, KGH Down, Maharanipeta,  
Jagadamba Junction, Visakapatnam,  
Andhrapradesh - 530 002.  
Ph : +91 96526 69351

#### Medicover Unit - III

Sry. No. 27, Plot No. 05, BRTS Road,  
Health City, Arilova, Chinagadili mandal,  
Visakhapatnam, Andhrapradesh-530 040.  
Ph: +91 08916677888

#### Medicover - MVP

# 1-1-83, Sector-6, Venkajipalem,  
MVP Colony, Visakapatnam,  
Andhrapradesh-530017.  
Ph : +91 8886655677



A UNIT OF SAHRUDAYA HEALTHCARE PVT LTD.

**Impression:**

**\* Small hepatic calcification.**

A handwritten signature in black ink, appearing to read 'Dr. Venkata Suman Kuna'.

**Dr. VENKATA SUMAN KUNA, MBBS, M.D.,**  
PDCC(MSK)  
CONSULTANT RADIOLOGIST

Date: 09-Nov-2024 11:08:26

**Medicover Unit - I**

# 18-1-3, KGH Down, Maharanipeta,  
Jagadamba Junction, Visakapatnam,  
Andhrapradesh - 530 002.  
Ph : +91 96526 69351

**Medicover Unit - III**

Sry. No. 27, Plot No. 05, BRTS Road,  
Health City, Arilova, Chinagadili mandal,  
Visakhapatnam, Andhrapradesh-530 040.  
Ph: +91 08916677888

**Medicover - MVP**

# 1-1-83, Sector-6, Venkojipalem,  
MVP Colony, Visakapatnam,  
Andhrapradesh-530017.  
Ph : +91 8886655677

09/11/2024 09:18:50

B VENKATA NANAJI

37 Years

Male

MEDCOVER HOSPITALS MVP VZAG

WELLNESS

Rate 90 . SINUS RHYTHM.....normal P axis, V-rate 50- 99  
 . . . . . EARLY PRECORDIAL R/S TRANSITION.....QRS area positive in V2  
 . . . . . BORDERLINE T ABNORMALITIES, INFERIOR LEADS.....T flat/neg, II III aVF

FR 124  
 QRSD 70  
 QT 336  
 QTc 411

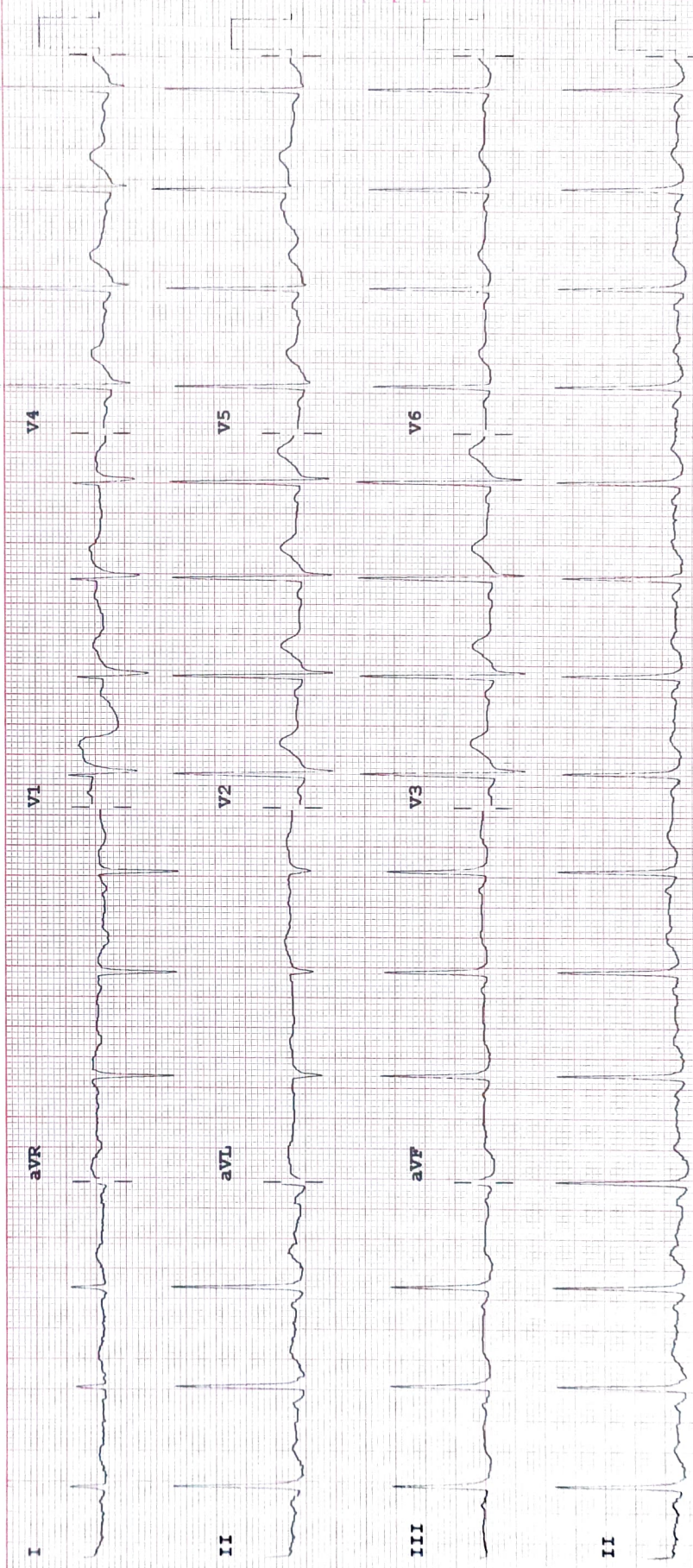
--AXIS--

P 70  
 QRS 74  
 T -3

12 Lead; Standard Placement

- BORDERLINE ECG -

Unconfirmed Diagnosis



Device:

Speed: 25 mm/sec Limb: 10 mm/mV Chest: 10.0 mm/mV

F 50~0.50~40 Hz W

PH090A CL