



MEDICOVER HOSPITALS

MEDICAL HEALTH CHECK- UP ASSESMENT FORM

NAME : Mr / Mrs Mona Goel

DATE: 8/3/25

AGE : 44

SEX: Male/ Female

UMR NO : 542503000528

DOCTOR'S NAME:

Health checkup

TEMP :	<u>96.2</u>	° f	BP :	<u>110 / 80</u>	mmHg
PULSE :	<u>70</u>	b/m	HEIGHT :	<u>157</u>	cm
RR :	<u>20</u>	b/m	WEIGHT :	<u>79.0</u>	kg
SPO2 :	<u>99</u>	%	HGT:		

REMARK:

Patient ID:	542503000528	Patient Name:	MONA GOEL
Age:	44YRS	Sex:	F
Accession Number:	HC	Modality:	US
Referring Physician:	DMO	Study:	USG ABDOMEN PELVIS
Study Date:	08-Mar-2025		

ULTRASOUND EXAMINATION OF ABDOMEN & PELVIS

The Liver is normal in size (14.9 cm) and shows increase in parenchymal reflectivity. No focal lesion is seen. The Hepatic veins appear normal. There is no evidence of any dilated IHBR. The portal vein appears normal.

The gall bladder is distended with normal wall thickness. There is no evidence of gallstones. C.B.D. is of normal caliber.

The Pancreas is normal in size and shows homogeneous reflectivity. There is no evidence of any calcification or ductal dilatation.

The spleen is normal in size and shows a homogeneous echotexture. It measures 10.1 cm in long axis. There is no evidence of any focal lesion.

Both kidneys are normal in position and size. They show normal cortical reflectivity and cortico-medullary distinction.

The Right Kidney measures 10.2 x 4.3 cm.

The Left Kidney measures 10.0 x 4.6 cm.

There is no evidence of renal calculi, hydronephrosis, or mass noted.

There is no evidence of ascites or para aortic lymphadenopathy.

The Urinary bladder is distended and shows normal wall thickness. No evidence of any intraluminal mass or calculi.

The uterus is Anteverted. It measures 7.4 x 4.6 x 5.2 cm.

The uterine myometrial echotexture is homogeneous. No focal lesion is seen.

The Endometrial thickness is 11.8 mm.

Both ovaries are visualized and appear normal in size and reflectivity.

The Right ovary measures 3.5 x 2.5 cm. A cyst of size 21 x 20 mm is seen in right ovary, likely follicular cyst.

The Left ovary measures 2.6 x 1.7 cm.

No evidence of any fluid collection in the pelvis.

HC 528
44 Years

MONA GOEL
Female

3/8/2025 1:34:33 PM

Rate 85 . Sinus rhythm.....normal P axis, V-rate 50- 99
. Low voltage, precordial leads.....precordial leads <1.0mV

PR 150
QRSD 101
QT 341
QTc 406

--AXIS--

P 53
QRS 7
T 28

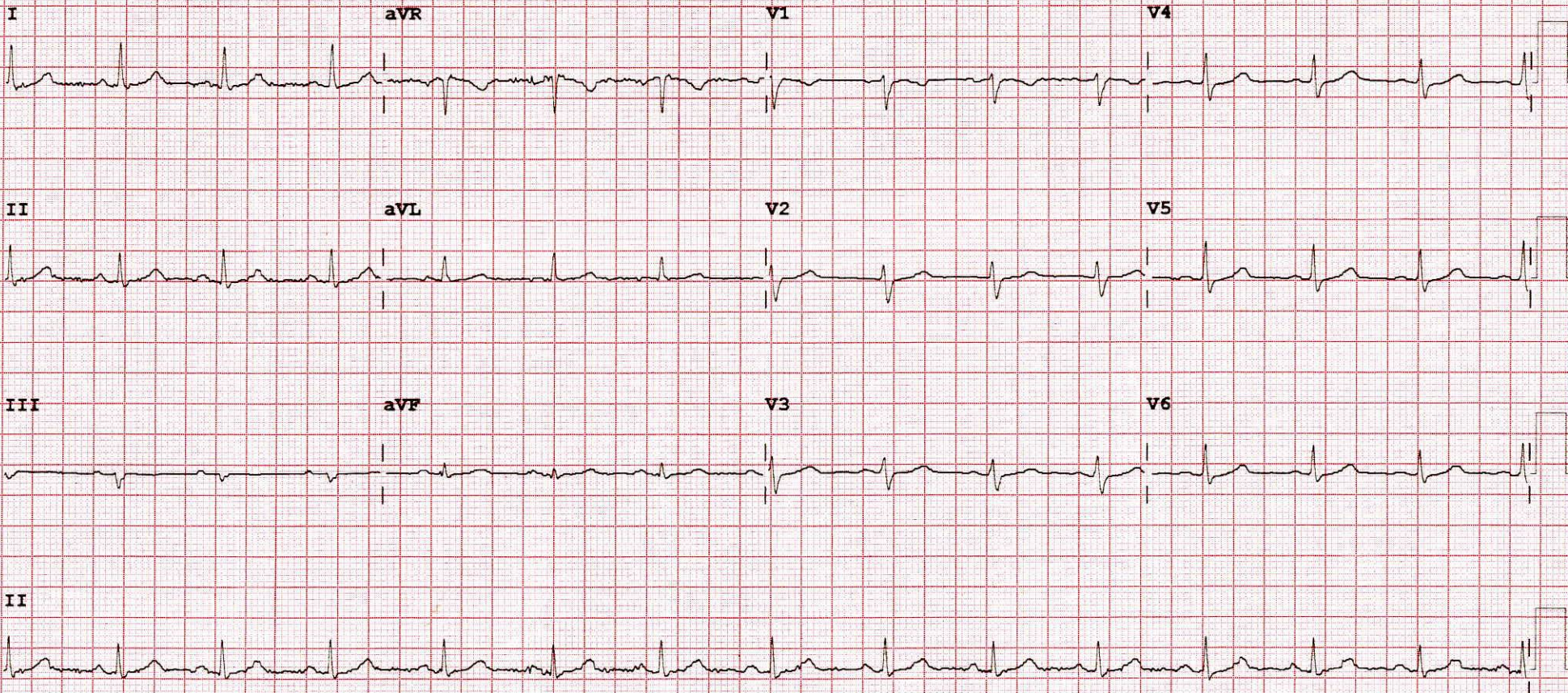
12 Lead; Standard Placement

- OTHERWISE NORMAL ECG -

Unconfirmed Diagnosis

W

AW





MEDICOVER
HOSPITALS

NAVI MUMBAI

2D ECHO CARDIOGRAPHY WITH COLOR DOPPLER


<i>Name</i>	: Mrs. Mona Goel	Date:- 08/03/2025
<i>Age / Sex</i>	: 44 Yrs / Female	UMR No. 0000000528
<i>Referred By</i>	: Health Check Up	

FINDINGS:

- No left ventricle regional wall motion abnormality.
- Normal left ventricle systolic function. LVEF = 60%.
- Grade I left ventricle diastolic dysfunction.
- No mitral regurgitation.
- No aortic regurgitation. No aortic stenosis.
- Trivial tricuspid regurgitation. No pulmonary hypertension.
PASP = 22 mm Hg.
- No left ventricle clot / vegetation / pericardial effusion.
- Intact IAS and IVS.
- Normal left atrium and left ventricle dimensions.
- Normal right atrium and right ventricle dimensions.
- Normal right ventricle systolic function. No hepatic congestion.

IMP:

- No RWMA.
- Grade I left ventricle diastolic dysfunction.
- Trivial TR. No PH.
- Normal LV and RV systolic function.


DR. KESHAV KALE
DNB (Cardiology), MD (Medicine), MBBS
PhD (Cardiology), MNAMS, LL.B (Law)
FSCAI (USA), AFACC (USA), FESC (EU)
Consultant & Interventional Cardiologist





MEDICOVER
HOSPITALS

NAVI MUMBAI

M-MODE MEASUREMENTS:

LA	34	mm
AO root	27	mm
AO CUSP SEP	18	mm
LVID(s)	31	mm
LVID(d)	43	mm
IVS(d)	11	mm
LVPW(d)	10	mm
RVID(d)	29	mm
RA	31	mm
LVEF	60	%

	PEAK	MEAN	Vmax	Gradient of Regurgitation
MITRAL	N			Nil
AORTIC	8			Nil
TRICUSPID	22			Trivial
PULMONERY	4.1			Nil



MEDICAL HEALTH CHECK- UP ASSESMENT FORM

NAME : Mr / Mrs Monna Goel

DATE: 8/3/25

AGE : 44

SEX: Male/ Female

UMR NO : 542503000528

DOCTOR'S NAME:

Health checkup

TEMP :	<u>96.2</u>	° f	BP :	<u>110/80</u>	mmHg
PULSE :	<u>70</u>	b/m	HEIGHT :	<u>157</u>	cm
RR :	<u>20</u>	b/m	WEIGHT :	<u>79.0</u>	kg
SPO2 :	<u>99</u>	%	HGT:		

REMARK:

**LABORATORY REPORT : Biochemistry**

Name	: Mrs. MONA GOEL	Age /Sex	: 043Y Y(s)/FEMALE
Sample Collected On	: 09-Mar-2025 03:15 PM	UMR No.	: B2B25031539
Department Receiving	: 09-Mar-2025 04:45 PM	Bill No.	: MOPB250305250
Reported Date	: 10-Mar-2025 04:19 PM	Result No	: RJB250303795
Advised By	: MEDICOVER HOSPITAL	Sample ID	: JBH250302570
Sample Type	: Whole blood	Client Name	: Medicover Hospitals Navi Mumbai

1, 25-DIHYDROXY VITAMIN D

<u>Parameters</u>	<u>Result</u>	<u>BRI</u>	<u>Units</u>
1,25 HYDROXY VITAMIN D CLIA	39.6	19.9-79.3	pg/mL

INTERPRETATION


The biosynthesis of the dihydroxylated forms of vitamin D3 begins with the action of solar ultraviolet light on 7-dehydrocholesterol to form vitamin D3 in the skin. Once Vitamin D3 enters the circulation it is rapidly taken up by the liver where it is metabolized to 25-hydroxyvitamin D3 (25-OH-D3). The liver will also hydroxylate dietary vitamin D2 to 25-hydroxyvitamin D2 (25-OH-D2). Following hepatic hydroxylation, 25-OH-D is transported in association with vitamin D binding protein to the kidney where further hydroxylation takes place. The addition of a hydroxyl at position 1 yields 1,25 dihydroxyvitamin D (1,25 (OH)2 D).

1,25 dihydroxyvitamin D is the most potent naturally occurring vitamin D metabolite discovered so far, and its production is tightly regulated through concentrations of serum calcium, phosphorus, and parathyroid hormone. During times of calcium stress, 1,25 (OH)2 D is the most important vitamin D metabolite produced by the kidney. This is due to its essential role in the efficient active absorption of calcium and phosphorus, as well as their normal metabolism. In secondary hyperparathyroidism the parathyroid glands become enlarged and hyperactive. Kidney failure is a common cause of secondary hyperparathyroidism and usually occurs as a complication of renal disease where the kidney is unable to remove the phosphorus produced by the body and is also unable to produce enough of the active form of vitamin D (1,25 (OH)2 D). The build up of phosphorus leads to low levels of calcium in the blood, which in turn stimulates the parathyroid glands to increase PTH production, causing the parathyroid glands to enlarge. As the disease progresses, the parathyroid glands no longer respond normally to calcium or vitamin D. The clinical practice guidelines such as the Kidney Disease Outcomes Quality Initiatives (KDOQI), and the Kidney Disease: Improving Global Outcomes (KDIGO) recommend activated vitamin D therapeutic regimens for chronic kidney disease (CKD) patients. Consequently, the measurement of 1,25 (OH)2 D is rapidly becoming an efficient tool in the research of diseases and conditions that affect the normal metabolism of phosphorus and calcium.

*** End Of Report ***

Suggested Clinical Correlation * If necessary, Please discuss

Verified By :
ID -15850


DR Meraj Sultana
MBBS MD(BIOCHEMISTRY)

**LABORATORY REPORT : Cytology**

Name	: Mrs. MONA GOEL	Age /Sex	: 043Y Y(s)/FEMALE
Sample Collected On	: 10-Mar-2025 08:25 PM	UMR No.	: B2B25031750
Department Receiving	: 11-Mar-2025 11:25 AM	Bill No.	: MOPB250305933
Reported Date	: 12-Mar-2025 10:41 AM	Result No	: RJB250304201
Advised By	: DR ER PHYSICIAN	Sample ID	: JBH250302862
Sample Type	:	Client Name	: Medicover Hospitals Navi Mumbai

LBC**CYTOLOGY NO.**

CY-996/25

CLINICAL HISTORY

LMP- 15/2/25. Cervix / Vagina - Unhealthy, nabothian cyst around os, bleeds on touch.

SPECIMEN TYPE

Liquid- based preparation.

SPECIMEN ADEQUACY

Satisfactory for evaluation with evidence of transformation zone component.

GENERAL CATEGORIZATION

Negative for intraepithelial lesion or malignancy.

MICROSCOPIC EXAMINATION

Smear contains superficial, intermediate and parabasal cells. Scant inflammatory cells present.

ORGANISMS

Not present.

INTERPRETATION

NEGATIVE FOR INTRAEPITHELIAL LESION OR MALIGNANCY.

*** End Of Report ***

Suggested Clinical Correlation * If necessary, Please discuss

Verified By :

ID -15730

Dr Amrutha T
CONSULTANT PATHOLOGIST
TSMC/FMR/26706

LABORATORY REPORT : BIOCHEMISTRY

Name	: Mrs.MONA GOEL	Age /Sex	: 43Y Y(s)/FEMALE
Bill Date	: 08-Mar-2025 09:45 AM	UMR No.	: 542503000528
Rec. Dt	: 08-Mar-2025 02:04 PM	Bill No.	: MCB54250302167
Rept. Dt	: 11-Mar-2025 12:20 PM	Result No	: RMI250307631
Ref By	: Dr. ER PHYSICIAN	Sample ID	: MCNMI6117887
Sample Type	: SERUM		

T3,T4 AND TSH

<u>Parameters</u>	<u>Result</u>	<u>Reference Range</u>	<u>Units</u>
T3 ECLIA	131.2	70 - 204	ng/dL
T4 ECLIA	7.64	5.1 - 14.1	ug/dL
TSH(THYROID STIMULATING HORMONE) ECLIA	4.15	0.270 - 4.20	uIU/mL

*** End Of Report ***

Suggested Clinical Correlation * If necessary, Please discuss

Sharada N
N SHARADA
MD PATHOLOGY, HEAD - LAB SERVICES



OUT PATIENT DEPARTMENT

Patient Name : Mrs.MONA GOEL	UMR No : 542503000528
Age/Gender : 43Years, 6Months/FEMALE	Bill No : HC542503000369_16 Bill Dt : 08-Mar-2025
Mobile : 7045634788	Visit Dt. : 08-Mar-2025 Visit Type : Single
Organisation : AROCFEMI HEALTHCARE PVT LTD (MEDIWHEEL)	

Vitals :

BP Sit	BP Stand	BMI						
0/	0/	--						

Consultant :

DR.Anushree Sameer Vankar

CONSULTANT

Ophthalmology History :

HEALTH CHECKUP

Assessment And Plan :

VN (RE) : 6I6P N6 (LE): 6/6 N6
COLOUR VISION : (BE) NORMAL
REF : (RE) : -0.50DC@90 --6/6 (LE) : PLANO--:6/6
ANT SEG (BE) - WNL DISC (BE) - 0.5

Rx :

DR.Anushree Sameer Vankar

CONSULTANT

OUT PATIENT DEPARTMENT

Patient Name : Mrs.MONA GOEL	UMR No : 542503000528
Age/Gender : 43Years, 6Months/FEMALE	Bill No : HC542503000369_17 Bill Dt : 08-Mar-2025
Mobile : 7045634788	Visit Dt. : 08-Mar-2025 Visit Type : Single
Organisation : AROCFEMI HEALTHCARE PVT LTD (MEDIWHEEL)	

Vitals :

BP Sit	BP Stand	BMI						
0/	0/	--						

Consultant :

Dr.Binota Singh

BDS, eMBA

CONSULTANT

Final Diagnosis :

gen gingivitis

Chief Complaint :

routine check up

Assessment And Plan :

stains and calculus

caries 28 , 36

Advice :

scaling and polishing

filling irt 28 , 36

Rx :

Dr.Binota Singh

BDS, eMBA

CONSULTANT

Patient ID:	542503000528	Patient Name:	MONA GOEL
Age:	44YRS	Sex:	F
Accession Number:	HC	Modality:	US
Referring Physician:	DMO	Study:	USG ABDOMEN PELVIS
Study Date:	08-Mar-2025		

ULTRASOUND EXAMINATION OF ABDOMEN & PELVIS

The Liver is normal in size (14.9 cm) and shows increase in parenchymal reflectivity. No focal lesion is seen. The Hepatic veins appear normal. There is no evidence of any dilated IHBR. The portal vein appears normal.

The gall bladder is distended with normal wall thickness. There is no evidence of gallstones. C.B.D. is of normal caliber.

The Pancreas is normal in size and shows homogeneous reflectivity. There is no evidence of any calcification or ductal dilatation.

The spleen is normal in size and shows a homogeneous echotexture. It measures 10.1 cm in long axis. There is no evidence of any focal lesion.

Both kidneys are normal in position and size. They show normal cortical reflectivity and cortico-medullary distinction.

The Right Kidney measures 10.2 x 4.3 cm.

The Left Kidney measures 10.0 x 4.6 cm.

There is no evidence of renal calculi, hydronephrosis, or mass noted.

There is no evidence of ascites or para aortic lymphadenopathy.

The Urinary bladder is distended and shows normal wall thickness. No evidence of any intraluminal mass or calculi.

The uterus is Anteverted. It measures 7.4 x 4.6 x 5.2 cm.

The uterine myometrial echotexture is homogeneous. No focal lesion is seen.

The Endometrial thickness is 11.8 mm.

Both ovaries are visualized and appear normal in size and reflectivity.

The Right ovary measures 3.5 x 2.5 cm. A cyst of size 21 x 20 mm is seen in right ovary, likely follicular cyst.


The Left ovary measures 2.6 x 1.7 cm.

No evidence of any fluid collection in the pelvis.

Patient ID:	542503000528	Patient Name:	MONA GOEL
Age:	44YRS	Sex:	F
Accession Number:	HC	Modality:	US
Referring Physician:	DMO	Study:	USG ABDOMEN PELVIS
Study Date:	08-Mar-2025		

IMPRESSION:

- Grade I fatty liver.



DR. RIYAJUL HAQUE
MD RADIODIAGNOSIS.

Patient ID:	542503000528	Patient Name:	MONA GOEL
Age:	43 Years	Sex:	F
Accession Number:	HC	Modality:	DX
Referring Physician:		Study:	CHEST
Study Date:	08-Mar-2025		

RADIOGRAPH CHEST PA VIEW

Both lungs are clear.

The frontal cardiac dimensions are normal.

The pleural spaces are clear.


Both hilar shadows are normal in position and density.

No diaphragmatic abnormality is seen.

The soft tissues and bony thorax are normal.

Impression:

- **No significant abnormality is seen.**



DR. RIYAJUL HAQUE
MD RADIODIAGNOSIS.



Name	: Mrs.MONA GOEL	Age /Sex	: 43Y Y(s)/FEMALE
Bill No.	: MCB54250302167	UMR No.	: 542503000528

LABORATORY REPORT : BIOCHEMISTRY

Parameters	Result	Reference Range	Units
BUN / CREATININE RATIO			
(Bill Date : 08-Mar-2025 09:45 AM Result ID : RMI250307616)			
BUN / CREATININE RATIO <i>CALCULATED</i>	14.4	10-20	
SERUM URIC ACID			
(Bill Date : 08-Mar-2025 09:45 AM Result ID : RMI250307620)			
SERUM URIC ACID <i>uricase</i>	6.6 *	2.4-5.7	mg/dL
LFT(LIVER FUNCTION TEST)			
(Bill Date : 08-Mar-2025 09:45 AM Result ID : RMI250307621)			
TOTAL BILIRUBIN <i>DIAZO</i>	0.3	<1.2	mg/dL
DIRECT BILIRUBIN <i>DIAZO</i>	0.1	<=0.20	mg/dL
INDIRECT BILIRUBIN <i>Calculated</i>	0.2	<=1.0	mg/dL
SGPT (ALT) <i>UV without P5P</i>	33	<=33	U/L
SGOT (AST) <i>UV without P5P</i>	24	<= 32	U/L
ALKALINE PHOSPHATASE (ALP) <i>PNPP, AMP Buffer - IFCC Ref.</i>	102	35 - 105	U/L
TOTAL PROTEINS <i>Biuret method</i>	7.6	6.0 - 8.0 g/dL	g/dL
SERUM ALBUMIN <i>Bromcresol Green (BCG)</i>	4.3	3.5 - 5.2 g/dL	g/dL
GLOBULINS <i>Calculated</i>	3.3	2.5 - 3.5 g/dL	g/dL
A/G RATIO <i>Calculation</i>	1.30	1.2 - 2.5	
GAMMA GLUTAMYL TRANSFERASE(GGT) <i>G-glutamyl-carboxy-nitroanilide-IFCC</i>	47	6-42	U/L



Name	: Mrs.MONA GOEL	Age /Sex	: 43Y Y(s)/FEMALE
Bill No.	: MCB54250302167	UMR No.	: 542503000528

SERUM CREATININE

(Bill Date : 08-Mar-2025 09:45 AM Result ID : RMI250307623)

CREATININE <i>Jaffe</i>	0.76	0.6 - 1.2	mg/dL
----------------------------	------	-----------	-------

LIPID PROFILE

(Bill Date : 08-Mar-2025 09:45 AM Result ID : RMI250307624)

TOTAL CHOLESTEROL <i>Enzymatic colorimetric</i>	153	Desirable : : < 200 mg/dL Borderline High : : 200 - 239 mg/dL High risk : > 240 mg/dL	mg/dL
--	-----	---	-------

HDL CHOLESTEROL <i>Homogeneous enzymatic colorimetric</i>	41	Low : : < 40 mg/dL High : : > 60 mg/dL	mg/dL
--	----	---	-------

LDL CHOLESTEROL <i>Direct-Enzymatic colorimetric</i>	87	Very High : - > 190 mg/dL Optimal : - < 100 mg/dL Near Optimal : 100 - 129 mg/dL High : 160 - 189 mg/dL Borderline High:130-159 mg/dl	mg/dL
---	----	---	-------

VLDL <i>Calculation</i>	23	2 - 30 mg/dL	mg/dL
----------------------------	----	--------------	-------

SERUM TRYGLYCERIDES <i>Enzymatic colorimetric</i>	115	< 150 mg/dL Borderline High : 150 - 199 mg/dL High : 200 - 499 mg/dL	mg/dL
--	-----	--	-------

CHO/HDL RATIO <i>Calculation</i>	3.73 *	Normal : - < 3.5 High Risk : - > 5.0	
-------------------------------------	--------	---	--

LDL/HDL RATIO	2.12		
---------------	------	--	--

HBA1C (GLYCOSYLATED HAEMOGLOBIN)

(Bill Date : 08-Mar-2025 09:45 AM Result ID : RMI250307625)

HBA1C <i>HPLC</i>	6.0 *	" Normal : < 5.7% Pre diabetic : 5.7 % - 6.5 % Diabetic : > 6.5 %	
----------------------	-------	---	--

BUN(BLOOD UREA NITROGEN)

(Bill Date : 08-Mar-2025 09:45 AM Result ID : RMI250307626)

BUN (Blood Urea Nitrogen.) <i>Calculated</i>	11	7 - 21.0	mg/dL
---	----	----------	-------

VITAMIN B12

(Bill Date : 08-Mar-2025 09:45 AM Result ID : RMI250307629)

VITAMIN B12 <i>ECLIA</i>	779.8 *	197-771	pg/mL
-----------------------------	---------	---------	-------



Name	: Mrs.MONA GOEL	Age /Sex	: 43Y Y(s)/FEMALE
Bill No.	: MCB54250302167	UMR No.	: 542503000528

FBS (FASTING BLOOD GLUCOSE WITH URINE GLUCOSE)

(**Bill Date** : 08-Mar-2025 09:45 AM **Result ID** : RMI250307630)

FASTING BLOOD GLUCOSE <i>Hexokinase</i>	93	Normal Range : 70 - 99 Impaired Glucose tolerance : 100 -125 Diabetes Mellitus : >=126	mg/dL
--	----	--	-------

FASTING URINE GLUCOSE NIL

PLBS (POST LUNCH BLOOD SUGAR WITH URINE SUGAR)

(**Bill Date** : 08-Mar-2025 09:45 AM **Result ID** : RMI250308143)

PLBS (POST LUNCH BLOOD GLUCOSE)	87	Normal Range : <140 Impaired Glucose Tolerance : 140 -199 Diabetes Mellitus: >=200
------------------------------------	----	--

URINE SUGAR NIL

Sharada N
N SHARADA
MD Pathology, Head - Lab Services



Name	: Mrs.MONA GOEL	Age /Sex	: 43Y Y(s)/FEMALE
Bill No.	: MCB54250302167	UMR No.	: 542503000528

LABORATORY REPORT : BLOOD BANK

Parameters	Result	Reference Range	Units
------------	--------	-----------------	-------

BLOOD GROUPING AND RH


(**Bill Date** : 08-Mar-2025 09:45 AM **Result ID** : RMI250307618)

BLOOD GROUP <i>Tube agglutination</i>	B
--	---

RH TYPE	POSITIVE
---------	----------

INTERPRETATION

1. If Rh is Du positive it is best considered as Rh negative as recipient and Rh positive as donor. Proper Cross matching is recommended before transfusion.
2. In case of forward and reverse grouping discrepancy, clinical correlation and repeat sample analysis is recommended.
3. For Infants below 6 months only forward grouping is performed.
4. A sub-grouping is recommended after the age of 6 months.



N SHARADA

MD Pathology, Head - Lab Services



Name	: Mrs.MONA GOEL	Age /Sex	: 43Y Y(s)/FEMALE
Bill No.	: MCB54250302167	UMR No.	: 542503000528

LABORATORY REPORT : CLINICAL PATHOLOGY

Parameters	Result	Reference Range	Units
------------	--------	-----------------	-------

CUE(COMPLETE URINE EXAMINATION)

(Bill Date : 08-Mar-2025 09:45 AM Result ID : RMI250307619)

PHYSICAL EXAMINATION

VOLUME	25ML		ml
COLOUR	PALE YELLOW	PALE YELLOW	
APPEARANCE	SLIGHTLY HAZY	CLEAR	

CHEMICAL EXAMINATION

DEPOSIT	ABSENT	ANSENT
SPECIFIC GRAVITY <i>Bromthymol blue</i>	1.030	1.000 - 1.030
PH <i>Bromthymol blue</i>	5.0	5.0 - 8.0
PROTEIN <i>Tetra-bromophenol blue/Heat coagulation test</i>	NIL	NIL (<15 mg/dL)
GLUCOSE <i>Glucose oxidase Peroxidase/Benedict's test</i>	NIL	NIL (<25 mg/dL)
UROBILINOGEN <i>Diazonium salt</i>	NIL	NIL
KETONE <i>Sodium nitroprusside/Rothera's test.</i>	NIL	NIL (<5 mg/dL)
BILIRUBIN <i>Dipstick/Fouchets test</i>	NIL	NEGATIVE
BILE SALT <i>Hays sulphur powder</i>	NIL	NEGATIVE
BILE PIGMENT <i>Fouchet test</i>	NIL	NEGATIVE
NITRITE <i>Sulfanilic acid</i>	NIL	NEGATIVE
LEUCOCYTE ESTERASE	NIL	NEGATIVE



Name	: Mrs.MONA GOEL	Age /Sex	: 43Y Y(s)/FEMALE
Bill No.	: MCB54250302167	UMR No.	: 542503000528

MICROSCOPIC EXAMINATION

PUS CELLS	2-3	0 - 5 /hpf	
EPITHELIAL CELLS	1-2	0 - 5	hpf
RBC	NIL	0 - 5 /hpf	
CAST	NIL	NIL	
<i>Microscopy examination</i>			
CRYSTALS	NIL	NIL	
BACTERIA	NIL		
<i>Microscopic examination</i>			
YEAST	NIL		
<i>Microscopic examination</i>			
AMORPHOUS DEPOSITS	NIL		
<i>Microscopic examination</i>			
MUCUS THREAD	NIL		
<i>Microscopic examination</i>			

NOTE

Microscopic examination of urine is carried out on centrifuged urinary sediment



Dr Neeta Shrivastava
MBBS, MD, DNB (Microbiology)



Name	: Mrs.MONA GOEL	Age /Sex	: 43Y Y(s)/FEMALE
Bill No.	: MCB54250302167	UMR No.	: 542503000528

LABORATORY REPORT : HAEMATOLOGY

Parameters	Result	Reference Range	Units
CBP(COMPLETE BLOOD PICTURE)			
(Bill Date : 08-Mar-2025 09:45 AM Result ID : RMI250307617)			
R B C COUNT <i>Electrical Impedance</i>	4.47	3.8-4.8	10 ¹² /L
HEMOGLOBIN <i>Photometric</i>	11.7 *	12.0 - 15.0	gms/dL
PCV/HCT <i>Calculated</i>	36.9	36 - 46	%
MCV <i>Calculated</i>	82.6 *	83 - 101	fl
MCH <i>Calculated</i>	26.2 *	27 - 32	pg
MCHC <i>Calculated</i>	31.7	31.5 - 34.5	g/dL
RDW(cv)	16.7 *	11.6 - 14.0 %	%
TLC (TOTAL LEUCOCYTE COUNT) <i>Impedance</i>	8.79	4.0 - 10.0	10 ³ /μL

DIFFERENTIAL COUNT

NEUTROPHILS <i>DHSS/Microscopy</i>	69	40 - 80 %	
LYMPHOCYTES <i>DHSS/Microscopy</i>	25	20 - 40 %	
MONOCYTES <i>DHSS/Microscopy</i>	04	02 - 10 %	
EOSINOPHILS <i>DHSS/Microscopy</i>	02	00 - 06 %	
BASOPHILS <i>DHSS/Microscopy</i>	00	00 - 01 %	
PLATELET COUNT <i>Electrical Impedance</i>	317	150 - 400 10 ³ /μL	10 ³ /μL

ESR

(Bill Date : 08-Mar-2025 09:45 AM Result ID : RMI250307622)

ESR <i>MODIFIED WESTERGREN'S METHOD</i>	16	0 - 20	mm/1st hour
--	----	--------	-------------



MEDICOVER HOSPITALS



UNIT NO.04,BASEMENT, C/O MEDICOVER
HOSPITALS,PLOT NO.01,SECTOR
NO.10,KHARGHAR,PANVEL (RAIGAD ZONE 1
)MAHARASHTRA INDIA 410210., Navimumbai

Name	: Mrs.MONA GOEL	Age /Sex	: 43Y Y(s)/FEMALE
Bill No.	: MCB54250302167	UMR No.	: 542503000528

Sharada N
N SHARADA

MD Pathology, Head - Lab Services