



Shree Ram Multispeciality Hospital (SRMH)

Lokah Samasta Sukhino Bhavantu



OPD - ID : 02024 - 2025-0002122
UH-ID : SRMH-25022087

PT. TYPE : FREE OPD
PRINT DATE : 22-02-2025 / 09:16:22



6874556

PATIENT NAME	: MR SUJIT KUMAR SINGH	OPD-DATE	: 22-Feb-2025 - 09:14 AM
AGE / SEX	: 34-Y 6-M 19-D / FEMALE	DEPARTMENT	: GENERAL MEDICINE
DOB	:	CONSULTANT	: DR. AJIT KUMAR
MOB-NO	: 8980009134	COMPANY NAME	: MEDIWHEEL
GUARDIAN NAME	: S/o SHIVJI CHANDARMA SINGH	OPD PAID FEE	: 0.00
ADDRESS	: AT POST CHANOD BG 2 ASTHA VIHAR DESAI WAD VAPI TA-PARDI, RAIPUR, C.G.		

Weight : 65.8kg Height : 5'9" Temp : 98.6°F B.P. : 111/80 Pulse : 81 SPO2 : 97%



Near Railway Under Bridge, Basant Vihar Gate No. 1, Gondwara Chowk, Gudhiyari, Raipur (Chhattisgarh)

☎ 0771-43 43 161, 0771-43 40 162, 📞 8404 8404 79

✉ shreeramhospital.op@gmail.com 🌐 www.srmhraipur.com





Shree Ram Multispeciality Hospital (SRMH)

L o k a h S a m a s t a S u k h i n o B h a v a n t u



OPD - ID : 02024-2025-0002122 PT. TYPE : NEW REGISTRATION
 H-ID : SRMH-25022087 PRINTDATE : 22-02-2025/09:22AM TOKENNO. : 4

PATIENTNAME : MR. SUJIT KUMAR SINGH DEPARTMENT : ENT
 AGE/SEX : 34Y/ M / b / MALE DOB :
 CONSULT-DATE : 22/02/2025
 MOB-NO : 8980009134 COMPANYNAME : MEDIWHEEL
 GUARDIANNAME : S/O MR. SHIVJI CHANDARMA SINGH OPDPAIDFEE : 0.00
 ADDRESS : AT POST CHANOD BG 2 VIHAR DESAI WAD VAPI TA- PARDI

Weight : Temp : B.P. : Pulse : SPO2 :

Please indicate whether you are presently suffering from anyone of the following symptoms:

Yes No

Ear, Nose, Mouth, Throat

Ear pain	0	0
Ear itch	0	0
Ear drainage	0	0
Dizziness/ Loss of balance	0	0
Loss of Hearing	0	0
Whispering Noise	0	0
Tinnitus	0	0
Nosebleeds	0	0
Post-nasal Drip	0	0
Nose pain	0	0
Nose pressure	0	0
Nasal congestion	0	0
Loss of smell/taste	0	0
Bitterness	0	0
Sore Throat	0	0
Throat tickle	0	0
Hoarse Mouth / Throat	0	0
Throat clearing	0	0
Snoring	0	0

Present chief complaints:-

Signature

FOLLOW-UP DATE

ADVICE FOR ADMISSION

● Near Railway Under Bridge, Basant Vihar Gate No. 1, Gondwara Chowk, Gudhiyari, Raipur (Chhattisgarh)

☎ 0771-43 43 161, 0771-43 40 162, 📞 8404 8404 79

✉ shreeramhospital.op@gmail.com 🌐 www.srmhraipur.com





Shree Ram Multispeciality Hospital (SRMH)

L o k a h S a m a s t a S u k h i n o B h a v a n t u



NAME : MR SUJIT KUMAR SINGH
 MOBILE NO : 8980009134 TEST NO 1401
 DOCTOR : DR. AJIT KUMAR
 REFERRED BY : SELF

AGE / SEX : 34Y 6M 19D/MALE
 UH ID NO. : SRMH-25022087
 COLLECTION : 22-02-2025
 REPORTING : 22-Feb-2025

HAEMATOLOGY

TEST NAME	RESULT	UNIT	NORMAL VALUES
-----------	--------	------	---------------

BLOOD GROUPING AND RH TYPING

BLOOD GROUP	"B"		-
RH FACTOR	POSITIVE		-

CBC (COMPLETE BLOOD COUNT)

HAEMOGLOBIN (Hb)	12.2	gm%	13.5 - 17.5
TOTAL RBC COUNT	4.91	Million/cumm	4.5 - 5.9
HAEMATOCRIT (PCV)	36.6	%	41.5 - 50.4
RBC INDICES			
MCV	87.3	fl	78 - 96
MCH	24.8	pg	27 - 32
MCHC	28.4	%	33 - 37
RDW	11.8	%	11 - 16
TOTAL WBC COUNT (TLC)	6200	/cumm	4000 - 11000
DIFFERENTIAL COUNT			
NEUTROPHILS	67	%	40 - 70
LYMPHOCYTES	28	%	22 - 48
EOSINOPHILS	02	%	0 - 6
MONOCYTES	03	%	0 - 8
BASOPHILS	00	%	00 -
PLATELET COUNT	1.18	/cumm	1.50 - 4.50
PCT	0.16	%	0.10 - 0.28
MPV(MEAN PLATELET VOLUME)	13.8	µm ³	8 - 11
PDW	16.3	%	11 - 18

-- End Of Report --

TECHNICIAN

Dr. Dhananjay Prasad
 Dr. Dhananjay Prasad
 MBBS, MD (Pathologist)

This Report is not for medicolegal purpose

Near Railway Under Bridge, Basant Vihar Gate No. 1, Gondwara Chowk,
 Gudhiyari, Raipur (Chhattisgarh)

☎ 0771-43 43 161, 0771-43 40 162, 📠 8404 8404 79

✉ shreeramhospital.op@gmail.com 🌐 www.srmhraipur.com



SHREE RAM MULTISPECIALITY HOSPITAL

Lokah Samasta Sukhino Bhavantu

Near Railway Under Bridge, Basant Vihar Gate No. 1, Gondwara Chowk, Gudhiyari, Raipur (C.G.)
Phone: 0771-4343161, 08404840479 Email: Shreeramhospitalop@gmail.com



PATIENT NAME : MR SUJIT KUMAR SINGH
MOBILE NO : 8980009134
DOCTOR : DR. AJIT KUMAR
REFERRED BY : SELF

AGE / SEX : 34Y 6M 19D/MALE
UH ID NO. : SRMH-25022087
COLLECTION : 22-02-2025
REPORTING : 22-Feb-2025

TEST NO
1401

BIOCHEMISTRY

TEST NAME	RESULT	UNIT	NORMAL VALUES
-----------	--------	------	---------------

LIVER FUNCTION TEST (LFT)

BILIRUBIN TOTAL	0.54	mg/dL	0.2 - 1
BILIRUBIN DIRECT	0.25	mg / dl	0.1 - 0.6
BILIRUBIN INDIRECT	0.29	mg / dl	0.1 - 0.4
SGOT	24.3	U / L	0 - 46
SGPT	29.5	U / L	0 - 40
ALKALINE PHOSPHATASE	181.6	U / L	0 - 240
TOTAL PROTEIN	6.47	g / dl	6 - 8
ALBUMIN	3.81	g/dl	3.5 - 5.0
GLOBULIN	2.66	g / dl	2 - 3.5
A/G RATIO	1.43		1 - 2.5

Clinical Significance

Alanine transaminase (ALT)

ALT is an enzyme found in the liver that helps your body metabolize protein. When the liver is damaged, ALT is released into the bloodstream and levels increase.

Aspartate transaminase (AST)

AST is an enzyme that helps metabolize alanine, an amino acid. Like ALT, AST is normally present in blood at low levels. A decrease in AST levels may indicate liver damage or muscle damage.

Alkaline phosphatase (ALP)

ALP is an enzyme in the liver, bile ducts and bone. Higher-than-normal levels of ALP may indicate liver damage or disease, such as a blocked bile duct, or certain bone diseases.

Albumin and total protein

Albumin is one of several proteins made in the liver. Your body needs these proteins to fight infections and to perform other functions. Lower-than-normal levels of albumin and total protein might indicate liver damage or disease.

Bilirubin

Bilirubin is a substance produced during the normal breakdown of red blood cells. Bilirubin passes through the liver and is excreted in stool. Elevated levels of bilirubin (and associated symptoms) might indicate liver damage or disease or certain types of anemia.

-- End Of Report --

TECHNICIAN

This Report is not for medicolegal purpose

Dr. Dhananjay Prasad
MBBS, MD (Pathologist)



SHREE RAM MULTISPECIALITY HOSPITAL

Lokah Samasta Sukhino Bhavantu

Near Railway Under Bridge, Basant Vihar Gate No. 1, Gondwara Chowk, Gudhiyari, Raipur (C.G.)

Phone: 0771-4343161, 08404840479 Email: Shreeramhospitalop@gmail.com



PATIENT NAME : MR SUJIT KUMAR SINGH
MOBILE NO : 8980009134
DOCTOR : DR. AJIT KUMAR
REFERRED BY : SELF

AGE / SEX : 34Y 6M 19D/MALE
UH ID NO. : SRMH-25022087
COLLECTION : 22-02-2025
REPORTING : 22-Feb-2025
TEST NO : 1401

BIOCHEMISTRY

TEST NAME	RESULT	UNIT	NORMAL VALUES
-----------	--------	------	---------------

LIPID PROFILE

CHOLESTEROL	199.3	mg / dl	150 - 220
SERUM TRYGLYCERIDE	98.4	mg / dl	60 - 165
HDL	36.1	mg / dl	35 - 80
LDL	163.2	mg/dL	90 - 160
VLDL	19.68	mg/dL	20 - 50
CHOLESTEROL / HDL RATIO	5.52	mg/dL	3.5 - 5.5
LDL/HDL Ratio	4.52	mg / dl	2.5 - 3.5

PATHOLOGY

TEST NAME	RESULT	UNIT	NORMAL VALUES
-----------	--------	------	---------------

GGT (GAMMA GLUTAMYL TRANSFERASE)

GGT	15.8	U / L	12.00 - 18.00
-----	------	-------	---------------

-- End Of Report --

TECHNICIAN

This Report is not for medicolegal purpose

Dr. Dhananjay Prasad
MBBS, MD (Pathologist)

SHREE RAM MULTISPECIALITY HOSPITAL

Lokah Samasta Sukhino Bhavantu



Near Railway Under Bridge, Basant Vihar Gate No. 1, Gondwara Chowk, Gudhiyari, Raipur (C.G.)
 Phone: 0771-4343161, 08404840479 Email: Shreeramhospitalop@gmail.com

NAME : MR SUJIT KUMAR SINGH	AGE / SEX : 34Y 6M 19D/MALE	TEST NO
PHILE NO : 8980009134	UH ID NO. : SRMH-25022087	1401
CTOR : DR. AJIT KUMAR	COLLECTION : 22-02-2025	
ERED BY : SELF	REPORTING : 22-Feb-2025	

BIOCHEMISTRY

TEST NAME	RESULT	UNIT	NORMAL VALUES
-----------	--------	------	---------------

BLOOD SUGAR - FASTING AND PP

BLOOD SUGAR FASTING	235.3	mg/dL	70 - 110
BLOOD SUGAR PP	368.4	mg/dL	80 - 140

HbA1c -Glycosylated hemoglobin

HbA1c -Glycosylated hemoglobin	8.01	%	Normal Range : <6% Good Control : 6-7% fair Control : 7-8% Unsatisfactory Control : 8-10% Poor Control : >10% - 80 - 120
Estimated average plasma glucose	207.85	mg/dl	

CLINICAL PATHOLOGY

TEST NAME	RESULT	UNIT	NORMAL VALUES
-----------	--------	------	---------------


URINE SUGAR FASTING AND PP

URINE SUGAR FASTING	Present(+)		Absent -
URINE SUGAR PP	Present(+++)		Absent -

-- End Of Report --

INICIAN

s Report is not for medicolegal purpose


 Dr. Dhananjay Prasad
 MBBS, MD (Pathologist)

SHREE RAM MULTISPECIALITY HOSPITAL

L o k a h S a m a s t a S u k h i n o B h a v a n t u

Near Railway Under Bridge, Basant Vihar Gate No. 1, Gondwara Chowk, Gudhiyari, Raipur (C.G.)
 Phone: 0771-4343161, 08404840479 Email: Shreeramhospitalop@gmail.com



NAME : MR SUJIT KUMAR SINGH	AGE / SEX : 34Y 6M 19D/MALE	TEST NO
MOBILE NO : 8980009134	UH ID NO. : SRMH-25022087	1401
CTOR : DR. AJIT KUMAR	COLLECTION : 22-02-2025	
REFERRED BY : SELF	REPORTING : 22-Feb-2025	

BIOCHEMISTRY

TEST NAME	RESULT	UNIT	NORMAL VALUES
<u>BUN (BLOOD UREA NITROGEN)</u>			
BUN	17.2	mg / dl	7.00 - 20.00
Serum Creatinine	0.84	mg / dl	0.55 - 1.20
BUN / Creatinine Ratio	20.4		10.1 - 20.1

UREA AND CREATININE


SERUM CREATININE	0.84	mg/dL	0.6 - 1.2
SERUM URIC ACID	4.98	mg/dL	3.6 - 7.7

IMMUNOASSAY

TEST NAME	RESULT	UNIT	NORMAL VALUES
<u>SERUM PSA TOTAL</u>			
PSA (TOTAL)	1.32	ng/mL	0 - 4

-- End Of Report --


 TECHNICIAN


 Dr. Dhananjay Prasad
 MBBS, MD (Pathologist)

This Report is not for medicolegal purpose

SHREE RAM MULTISPECIALITY HOSPITAL

Lokah Samasta Sukhino Bhavantu

Near Railway Under Bridge, Basant Vihar Gate No. 1, Gondwara Chowk, Gudhiyari, Raipur (C.G.)
Phone: 0771-4343161, 08404840479 Email: Shreeramhospitalop@gmail.com



NAME : MR SUJIT KUMAR SINGH
MOBILE NO : 8980009134
CTOR : DR. AJIT KUMAR
REFERRED BY : SELF

AGE / SEX : 34Y 6M 19D/MALE
UH ID NO. : SRMH-25022087
COLLECTION : 22-02-2025
REPORTING : 22-Feb-2025

TEST NO
1401

HAEMATOLOGY

TEST NAME	RESULT	UNIT	NORMAL VALUES
ESR (ERYTHROCYTE SEDIMENTATION RATE)			
ESR	10	mm at end of 1 h	0 - 20

IMMUNOASSAY

TEST NAME	RESULT	UNIT	NORMAL VALUES
THYROID PROFILE (T3, T4, TSH)			
T3 (TRIIODOTHYRONINE)	0.86	ng/ml	0.8 - 2
T4 (THYROXINE)	11.2	ug/dl	5.13 - 14.06
TSH	1.02	uIU/ml	0.27 - 4.2

-- End Of Report --

TECHNICIAN

This Report is not for medicolegal purpose

Dr. Dhananjay Prasad
MBBS, MD (Pathologist)



SHREE RAM MULTISPECIALITY HOSPITAL

Lokah Samasta Sukhino Bhavantu
 Near Railway Under Bridge, Basant Vihar Gate No. 1, Gondwara Chowk, Gudhiyari, Raipur (C.G.)
 Phone: 0771-4343161, 08404840479 Email: Shreeramhospitalop@gmail.com



PT. NAME : MR SUJIT KUMAR SINGH
 MOBILE NO : 8980009134
 DOCTOR : DR. AJIT KUMAR
 REFERED BY: SELF

AGE / SEX : 34Y 6M 19D/MALE
 UH ID NO. : SRMH-25022087
 COLLECTION : 22-02-2025
 REPORTING : 22-Feb-2025

TEST NO
1401

CLINICAL PATHOLOGY

TEST NAME

RESULT

UNIT

NORMAL VALUES

URINE ROUTINE AND MICROSCOPY

PHYSICAL EXAMINATION

QUANTITY	20	ml	-
COLOUR	Pale Yellow		-
APPEARANCE	Clear		Pale Yellow -
REACTION	Acitic		Clear -

CHEMICAL EXAMINATION

ALBUMIN	Absent		-
SUGAR	Present(+)		Absent -
KETONE	Absent		Absent -
BILE SALT	Absent		Absent -
BILE PIGMENT	Absent		Absent -

MICROSCOPIC EXAMINATION

PUS CELLS	4-5	/hpf	2 - 5
EPITHELIAL CELLS	3-4	/hpf	1 - 5
RBC	Nil	/hpf	0 - 3
CAST	Nil	/lpf	Nil -
YEAST	Nil		Nil -
CRYSTAL	Nil	/lpf	Nil -
BACTERIA	Nil		Nil -
OTHERS	-		-

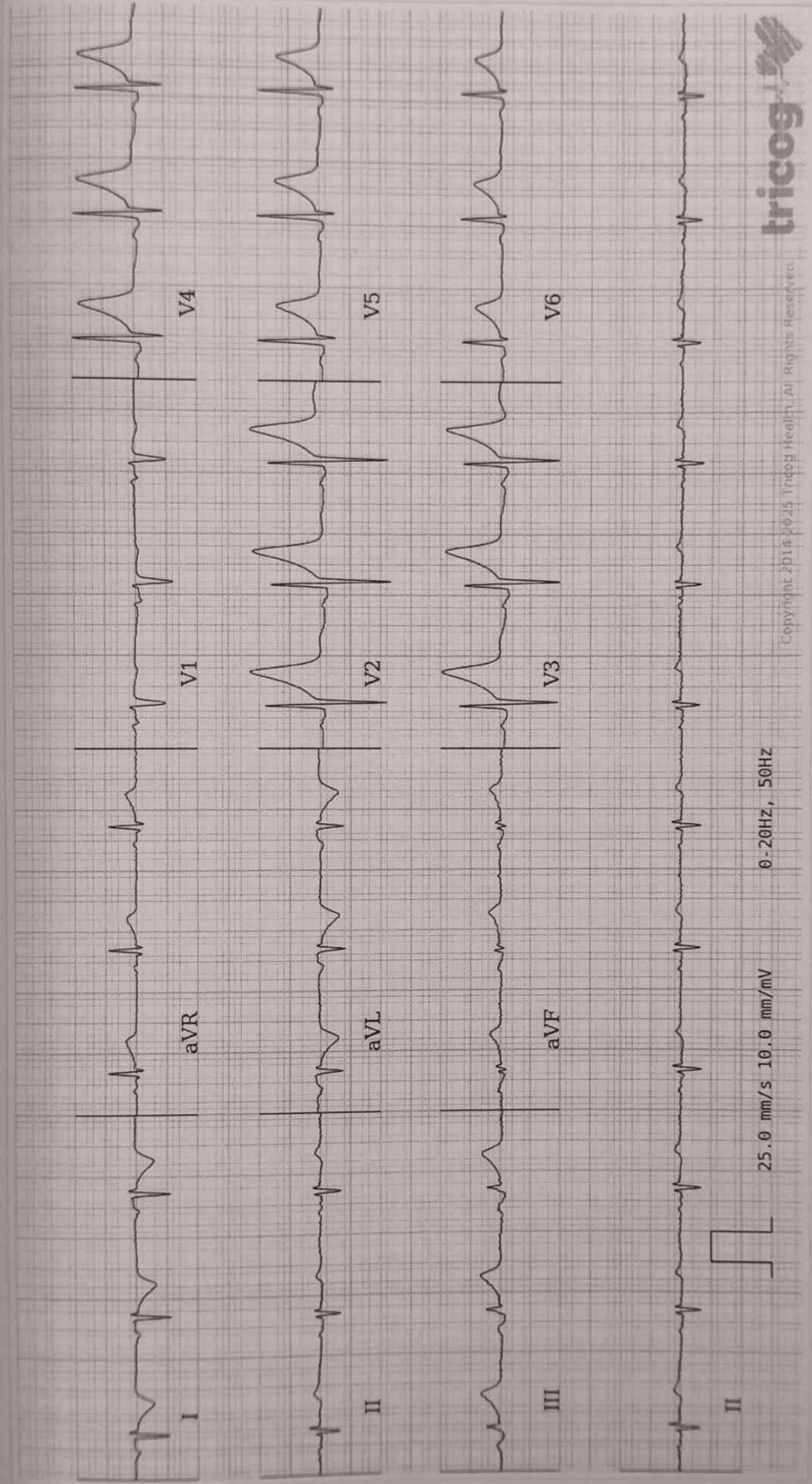
-- End Of Report --

TECHNICIAN

This Report is not for medicolegal purpose

Dr. Dhananjay Prasad
 MBBS, MD (Pathologist)

Patient ID: 3
Patient Name: Sujit



AR: 76bpm VR: 75bpm QRS: 80ms QT: 360ms QTcB: 402ms PRI: 136ms P-R-T: 99° 149° -36°

Copyright 2014-2025 Tripp Health, All Rights Reserved. tricog

Disclaimer: Analysis in this report is based on ECG alone and should only be used as an adjunct to clinical history, symptoms and results of other invasive and non-invasive tests and must be interpreted by a qualified physician.



Bhawani

DIAGNOSTIC CENTRE

Near Wallfort Ozone, Fafadih Chowk,
Raipur (C.G.) Ph.: 0771-4017333

www.bhawanidiagnostic.com



3 Tesla M.R.I.



96 Slice CT Scan



5D Color Doppler
Sonography



Digital X-Ray
O.P.G./CEPH.



Dexa-Scan/BMD



Mammography



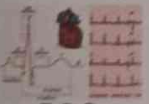Hi-Tech Pathology



EEG, EMG



Spirometry



E.C.G.



LITHOTRIPSY



Uroflowmetry

PT. NAME: MR. SUJEET KUMAR SINGH

AGE/SEX: 34 Y/M

REF. DR. BY : SHREE RAM SHANTI MULTI HOSPITAL

DATE 22/02/2025

USG STUDY OF WHOLE ABDOMEN

OBSERVATIONS :

LIVER:- The liver is normal in size, shape and has smooth margins. It has increased echotexture, has normally distributed and normal size biliary and portal radicals and is without solid or cystic mass lesion or calcification.

PORTAL VEIN :- It measures normal in size & is normal in its intra & extra hepatic course . It shows normal variation in size during respiration.

GALL BLADDER:- The gall bladder is seen as a well distended, pear shaped bag with uniformly thin and regular walls, without, gall stones or mass lesions.

COMMON BILE DUCT:- The common bile duct is normal in caliber. Its measures 2.1 mm at porta hepatis. No evidence of calculus is noted in common bile duct.

PANCREAS:- The pancreas is normal in size, shape, contours and echotexture. No evidence of solid or cystic mass lesion is noted.

KIDNEYS:- The Right kidney measures: 11.8 x 5.1 cm. Normal in Size, Shape & Echotexture. No Evidence Of Calculi or hydronephrosis seen , Corticomedullary Differentiation Normal.

The Left kidney measures:- 10.1 x 5.9 cm. Normal in Size, Shape & Echotexture. No Evidence Of Calculi or hydronephrosis seen. Corticomedullary Differentiation Normal.

URINARY BLADDER:- The urinary bladder is well distended. It shows uniformly thin walls and sharp mucosa. No evidence of calculus is seen. No evidence of mass or diverticulum is noted.

SPLEEN: The spleen is normal in size, shape. Its echotexture is homogeneous. No evidence of focal lesion is noted.

PROSTATE:- Appear normal in size. Normal in shape and echotexture.

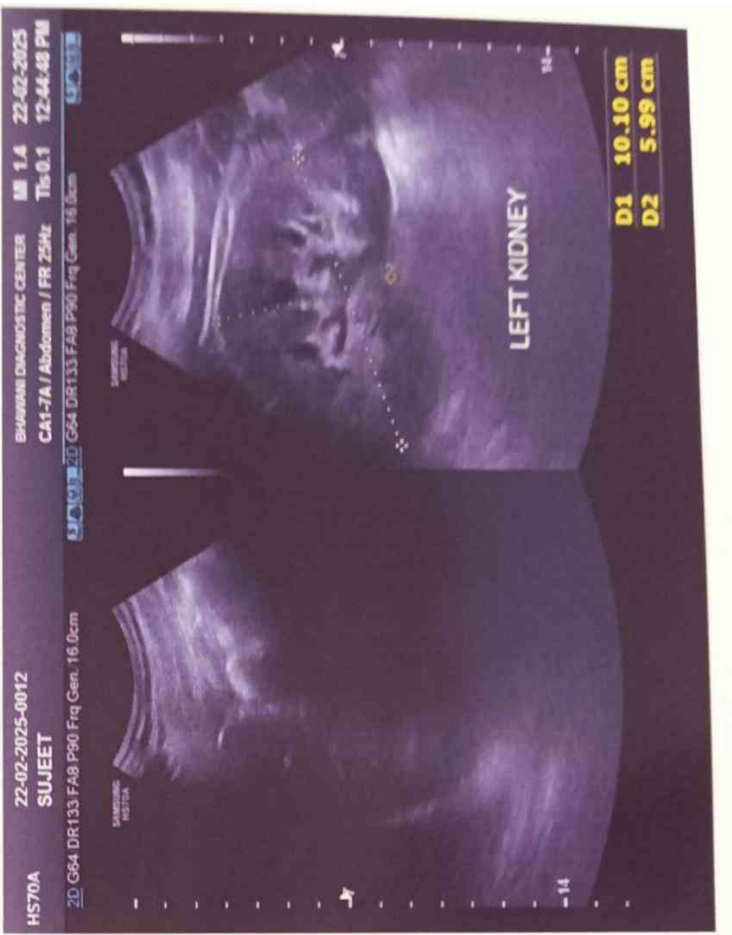
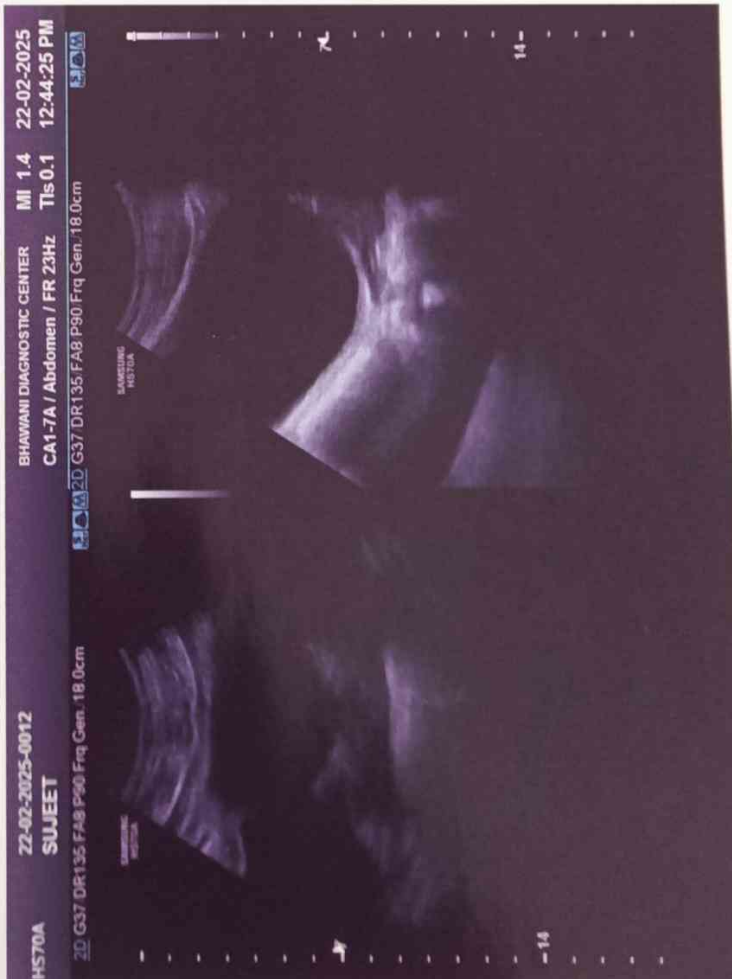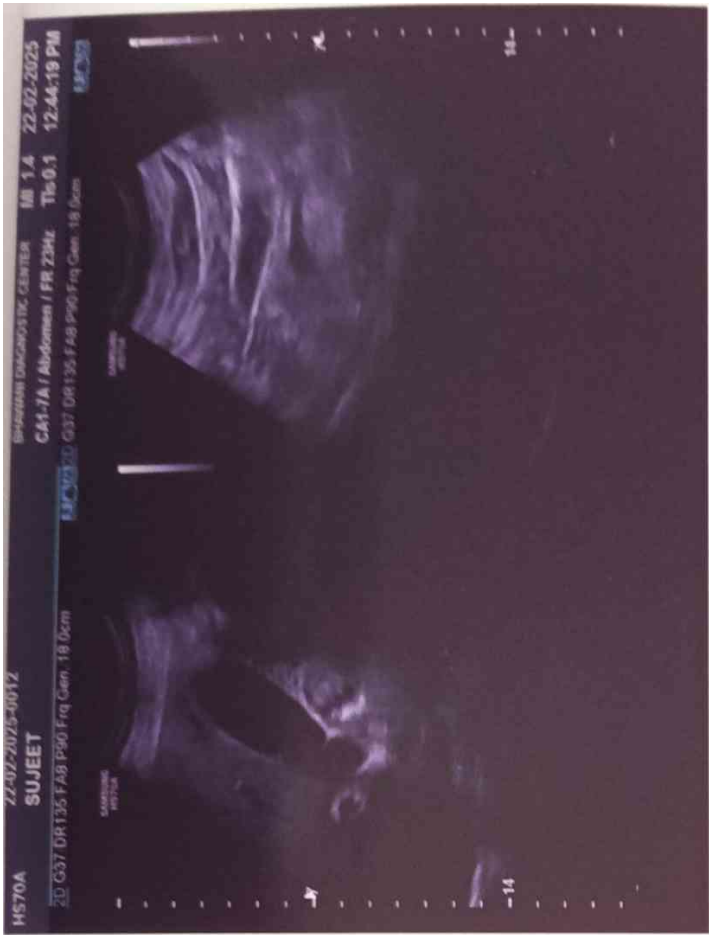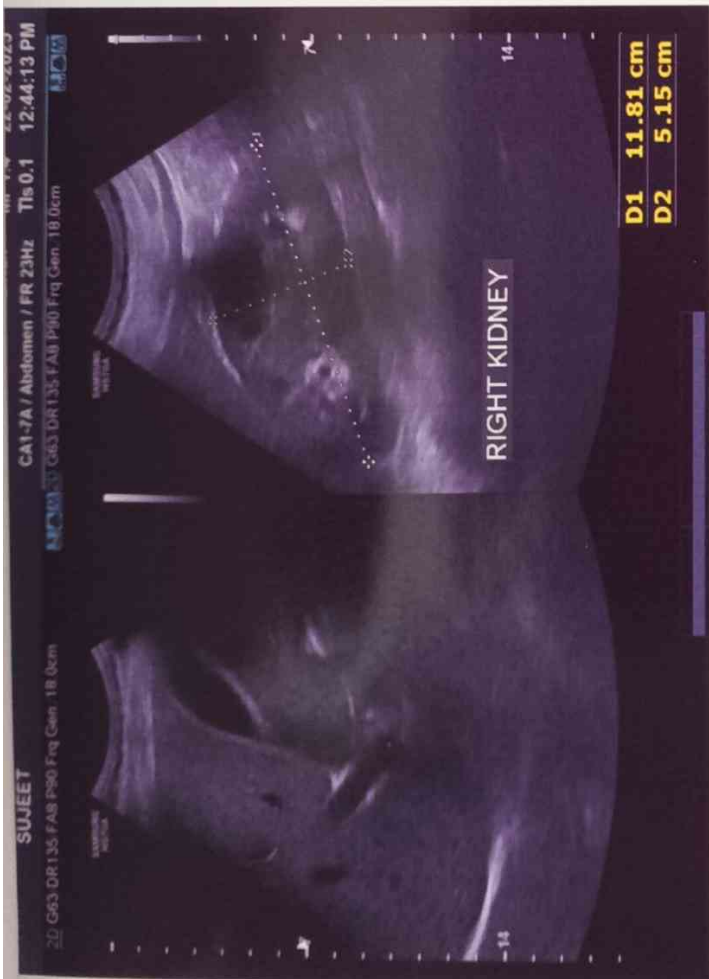
* No ASCITES, No pleural effusion.

* No ABDOMINAL lymphadenopathy.

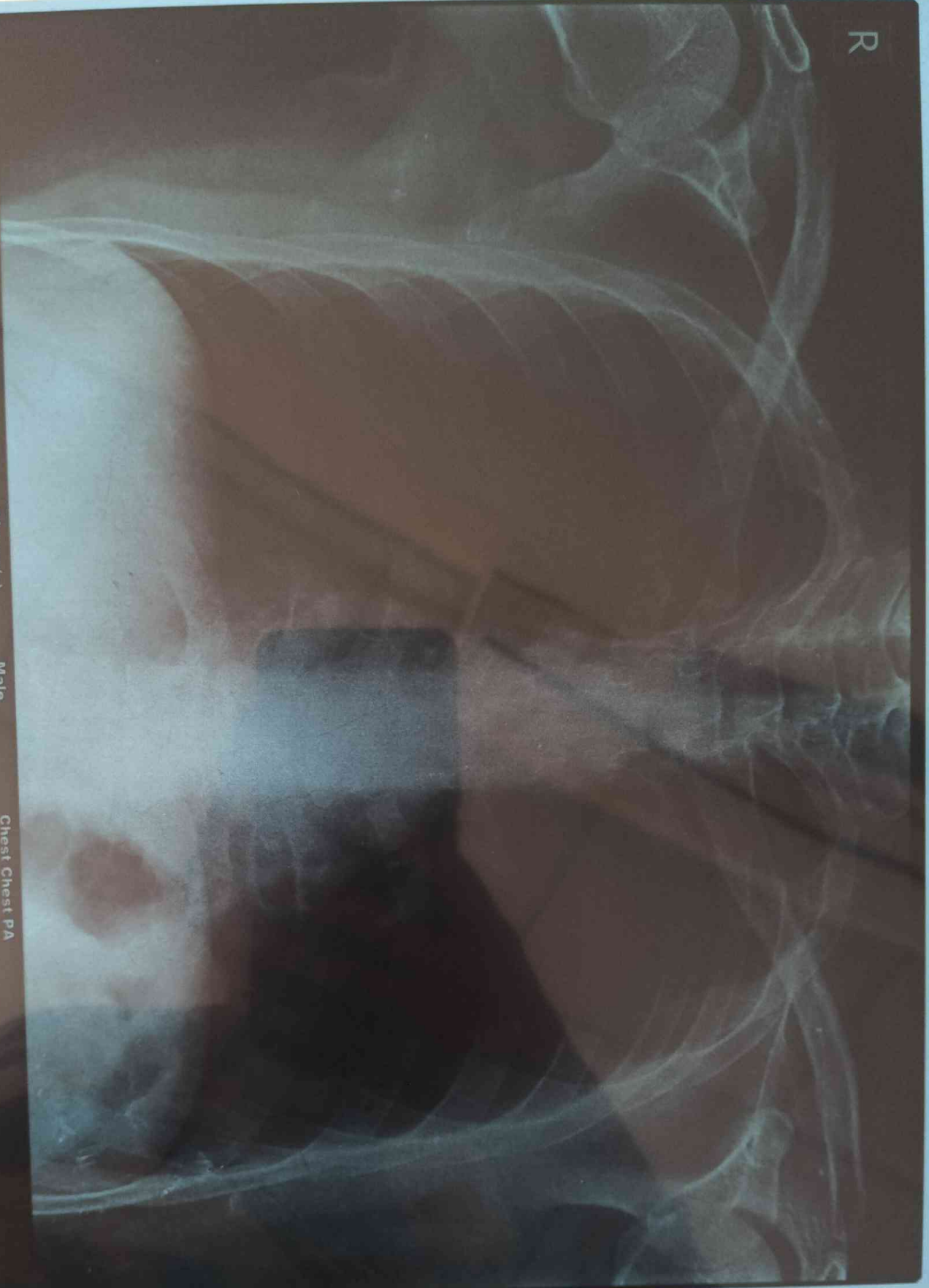IMPRESSION:- GRADE I FATTY LIVER.

DR. UJJWALA GOSWAMI
MD

RADIOLOGIST & SONOLOGIST



R



MR. SUJIT KUMAR

34 year(s)

Male

Chest Chest PA

REF BY:

SHREE RAM MULTISPECIALITY HOSPITAL, INFRONT GONDWARA UNDERBRIDGE, GUDDHIYARI, RAIPUR , PH: 0771-4343161

22/02/2025 10:38:11 AM