



Name: TAJBIJE VISHNU
Age & Sex: 57 Year /M
Exam: CHEST X RAY,
Physician:

Study Date: 19-Feb-2025
Accession: 158478133814
PID: P00000476993
OP

Health Check

Radiograph Chest PA View :

Both lung fields normal.

Both costo-phrenic angles are clear.

Cardiac silhouette and aortic knuckle are normal.

Both hilar shadows and the diaphragmatic contours are normal.

Thoracic soft tissues and the rib cage normal.

Impression :

No significant abnormality noted.

DR. POOJA SHRIRAMWAR
MBBS, DMRE
CONSULTANT RADIOLOGIST

19-Feb-2025 05:26:05 PM



Name: TAJBIJE VISHNU	Exam Date: 19-Feb-2025
Age & Sex: 57 Year /M	Accession: 158496135206
Exam: ABDOMEN AND PELVIS	PID: P00000476993
Physician:	OP/IP:

ULTRASOUND OF ABDOMEN AND PELVIS

Liver is normal in size and shows increased echogenecity suggestive of Grade I fatty changes. No focal lesion is seen. No intrahepatic biliary radicle dilatation seen. The portal vein and CBD appear normal.

Gall bladder is well distended with normal wall thickness. No calculus or sludge is seen. Pancreas appears normal in size and echotexture. No focal lesion is seen. Spleen appears normal in size and echotexture. No focal lesion is seen.

Ri Both kidneys appear normal in size, shape & echotexture. They show good cortico-medullary differentiation. There is no hydronephrosis, hydroureter, or calculus seen on either side.

The urinary bladder is well distended. Wall thickness is normal. No mass lesion or calculus is seen.

Prostate is normal in size, shape and echotexture.

Visualised bowel loops are non-dilated and show normal peristalsis. There is no ascites or significant lymphadenopathy seen.

IMPRESSION :

Grade I fatty liver.

No other significant abnormality noted.

Suggest : clinical coreelation



DR. POOJA SHRIRAMWAR
MBBS, DMRE
CONSULTANT RADIOLOGIST

19-Feb-2025 02:51:23 PM



RUBY HALL CLINIC PIMPLE SAUDAGAR

Name: VISHNU TAJBIJE . **Date:** 19-02-2025 **Time:** 12:22

Age: 54 **Gender:** M **Height:** 172 cms **Weight:** 68 Kg **ID:** PS011133

Clinical History:

Medications:

Test Details:

Protocol: Bruce **Predicted Max HR:** 166 **Target HR:** 141

Exercise Time: 0:06:34 **Achieved Max HR:** 148 (89% of Predicted MHR)

Max BP: 140/80 **Max BP x HR:** 20720 **Max Mets:** 7.4

Test Termination Criteria:

Protocol Details:

Stage Name	Stage Time	METS	Speed kmph	Grade %	Heart Rate bpm	BP mmHg	RPP	Max ST Level mm	Max ST Slope mV/s
Supine	00:08	1	0	0	76	120/80	9120	0.9 V2	-0.7 aVR
Standing	00:07	1	0	0	73	120/80	8760	0.9 V2	-0.6 aVR
HyperVentilation	00:18	1	0	0	73	120/80	8760	-1.3 V1	-0.7 aVR
PreTest	00:14	1	1.6	0	78	120/80	9360	-0.8 aVR	0.4 V2
Stage: 1	02:00	3.1	2.7	10	107	120/80	12840	-0.9 aVR	0.6 II
Stage: 2	02:00	4.7	4	12	112	120/80	13440	0.9 V2	0.8 II
Peak Exercise	02:34	7.4	5.5	14	148	140/80	20720	-0.7 II	0.6 V2
Recovery1	01:00	1	0	0	107	140/80	14980	1 V2	-0.8 aVR
Recovery2	00:37	1	0	0	101	120/80	12120	0.8 V2	-0.8 aVR

Interpretation

Negative Stress Test The Patient Exercised according to Bruce Protocol for 0:06:34 achieving a work level of 7.4 METS.

Resting Heart Rate, initially 76 bpm rose to a max. heart rate of 148bpm (89% of Predicted Maximum Heart Rate).

Resting Blood Pressure of 120/80 mmHg, rose to a maximum Blood Pressure of 140/80 mmHg

Good Effort Tolerance

Normal HR & BP Response

No Angina or Arrhythmias

No Significant ST-T Changes Noted During Exercise

Negative Stress Test



Ref. Doctor: ---

Doctor: DR.KEDAR KULKARNI

ID:

Name: ✓

MR. TABBLE WISHNU

Year's

1100 Sinus rhythm

9110 ** normal ECG **

19-Feb-2025 11:20

Sex: M

cm

Medication:

Symptoms:

History:

Vent. rate

PR int

QRS dur

QT/QTc(ED) int

P/QRS/T axis

RV5/SV1 amp

RV5+SV1 amp



Ref: P5011133-Reg: OP500002934

54.11.9M -NH - 19/02/2025

P00000476993 -

75 bpm

144 ms

86 ms

346/ 376 ms

53/ 24/ 42

1.05/ 0.75 mV

1.80 mV

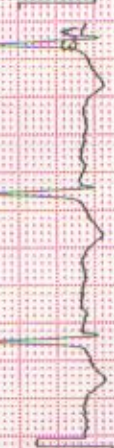
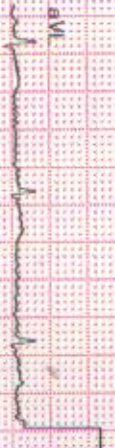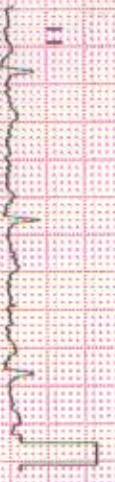
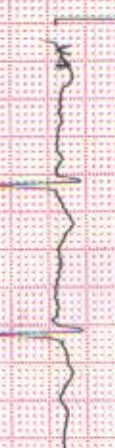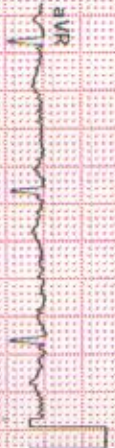10 mm/mV 25 mm/s

Filter = H50 D 35 Hz 10 mm/mV

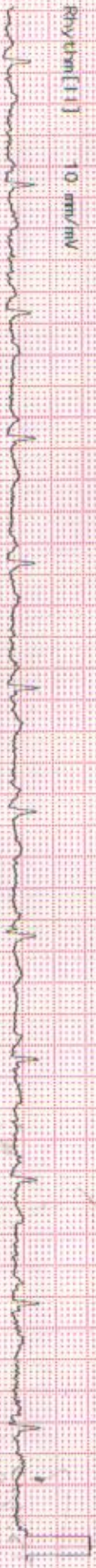
10 mm/mV

10 mm/mV

Uncertified Report
Reviewed by:



Rhythm [1] 10 mm/mV



Z350K 02-03 04-05

Dept.

Exam: RUBY HALL CLINIC HINJEWADI



Grant Medical Foundation

Ruby Hall Clinic

Pimple Saudagar

Dr Karuna

9890285357

19/02/25

O/E.- Caries +++

Stains ++

Gingivitis in lower anterior
region

Adms - Scaling.

Dr

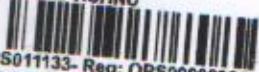



OPHTHALMOLOGY

NAME

MR. TAJBIJE VISHNU



Ref: PS011133- Reg: OPS00002934
 54.11.9/M - NH - 19/02/2025
 000000476001

AGE: 57 (m)

R +1.00/-0.75 X 70

L +1.25/-0.75 X 90

Add +2.50 (BE)

- 1) Vision $\left\{ \begin{array}{l} \text{unaided} \quad \underline{6/6} \\ \text{w glasses} \quad \underline{6/6} \end{array} \right.$
- 2) Near Vision $\left\{ \begin{array}{l} \text{unaided} \quad \underline{N/6} \\ \text{w glasses} \quad \underline{N/6} \end{array} \right.$
- 3) Binocular Vision $\underline{\checkmark}$
- 4) Colour Vision $\underline{\checkmark}$
- 5) Tension $\underline{\checkmark}$
- 6) Anterior Segment $\underline{\checkmark}$
- 7) Pupils $\underline{\checkmark}$
- 8) Lens $\underline{\text{Progressive Glucosol}}$
- 9) Media & Fundus _____
- 10) Remarks _____

Date: 19/2/25

(Signature)