

Dr. Siddharth Malaiya

MBBS, MS (Ophthalmology), FLVPEI, Hyd. (Cornea & LASIK)

FBHIEC, Australia (Ocular surface & Stem cells)

Fellow L V Prasad Eye Institute, Hyderabad, Ex-Faculty ASG Eye Hospital, Jodhpur

Consultant Ophthalmologist & Cornea Super-specialist

Phaco-refractive & Cornea transplant surgeon



Name: Mr. Sandeep Badarinarayan Age/Sex: 33/M

Date: 24/01/2024

C/o Regul Eye test
MHC

Vision	UCVA	Glasses	Pinhole	AR
RE	6/12 (P)	6/6	6/6	R -1.50 / 0.75 X 80°
LE	6/12	6/6	6/6	L -1.75 DS PL

vision 38/38 BE

Eye	Sphere	Cylinder	Axis	BCVA	PG
RE	-1.00 D	-0.50 D	50°	6/6	R
LE	-1.25 D			6/6	L ?
Add	Near	vision	Nil	BE	

Dr. Siddharth Malaiya
 MS Ophthalmology, FRCO, FRCR
 Consultant Ophthalmologist & Cornea Specialist
 Registered Surgeon



Name - Mrs. Sandeep Bhadoriya.

Age - 33yr/M

PMH → pt IS hypertensive - pt IS on medication

c/c pt came for regular check-up

OLE - Gen. gingival bleeding

- Gen. periodontal pocket ⊕

- Cal ++

- pathological Migration ⊕ I II

T ⊕ Adv

OPG

- Scaling and root planing.

- others T ⊕ After OPG Review

Dr. Richa Jain



24.10.2024 09:47:30

Male

QRS : 100 ms
QT / QTcBaz : 424 / 402 ms
PR : 164 ms
P : 110 ms
RR / PP : 1100 / 1111 ms
P / QRS / T : 38 / 6 / 6 degrees

Sinus bradycardia
Early repolarization
Otherwise normal ECG

Handwritten signature

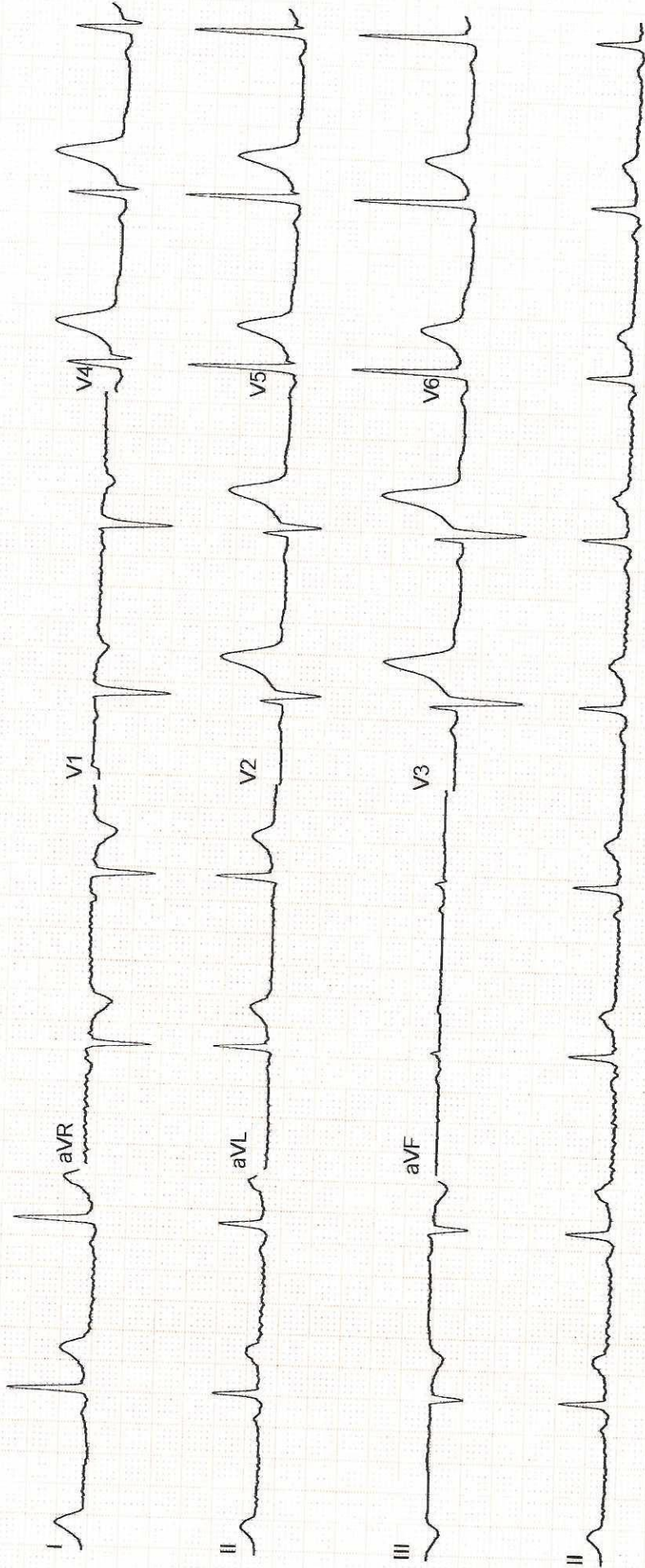
Location: R
Order Number:
Indication:
Medication 1:
Medication 2:
Medication 3:

Technician:
Ordering Ph:
Referring Ph:
Attending Ph:

54 bpm
-- / -- mmHg

LOT D800

CE





ECHOCARDIOGRAPHY REPORT

Patient's Name	Sandeep Bhadouriya	Date	24/10/2024
Age/Sex	33Y/M	UHID	HC -31487
Referred By	Health Check	Done By	Dr.Gaurav Khandelwal

-Left Ventricle : Normal Left Ventricular Size, Wall Thickness & Function.

-Left Ventricular Ejection Fraction is within Normal Limits (LVEF : 60%)

-Left Atrium : Normal Left Atrial Size & Functions.

-Right Ventricle : Normal Right Ventricular Size & Functions.

-Right Atrium : Normal Right Atrial Size & Function.

-Valvular Structures : Normal Mitral, Tricuspid, Pulmonic & Aortic Valve Structures.

-Trivial TR & No PAH

-No Evidence of Pericardial Effusion.

-No LA / LV Clot


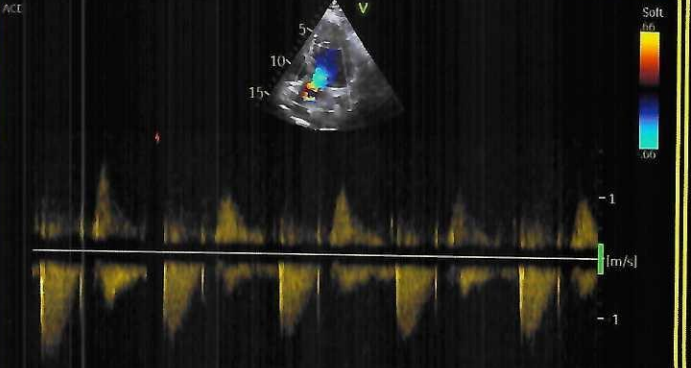
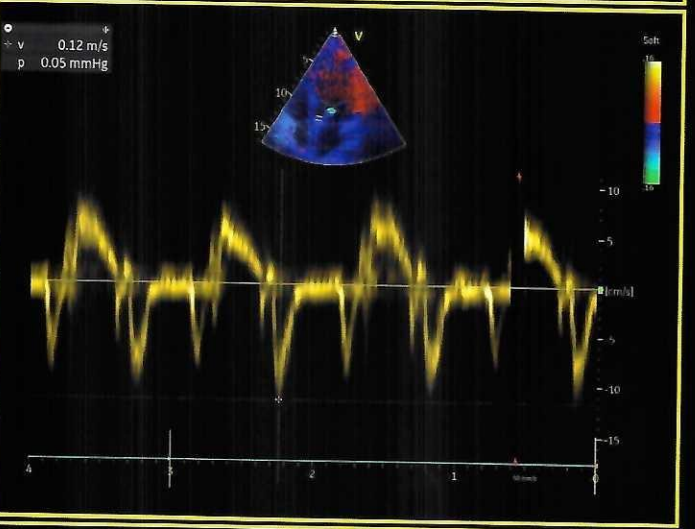
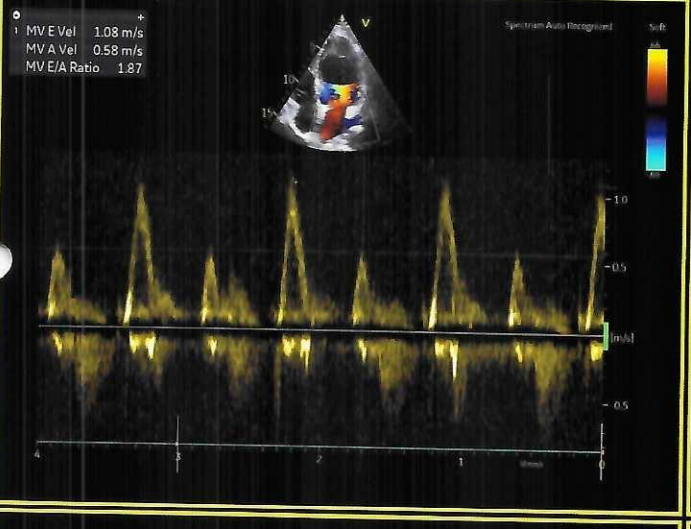
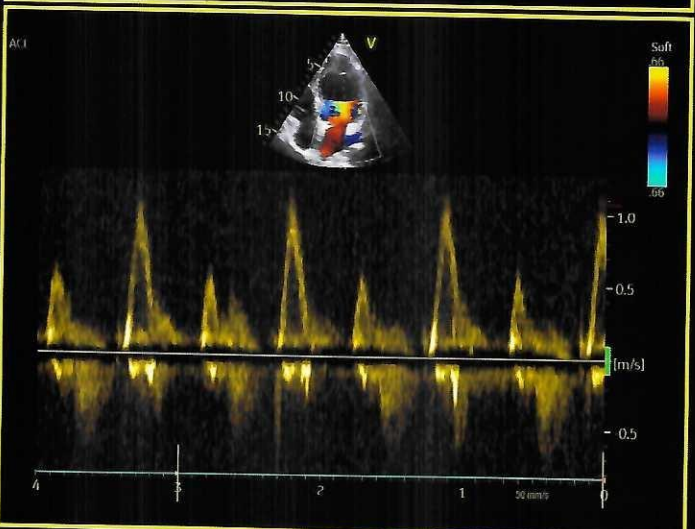
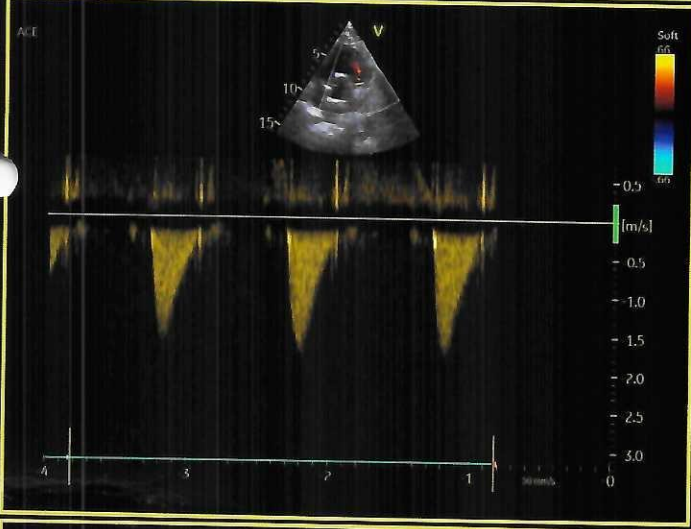
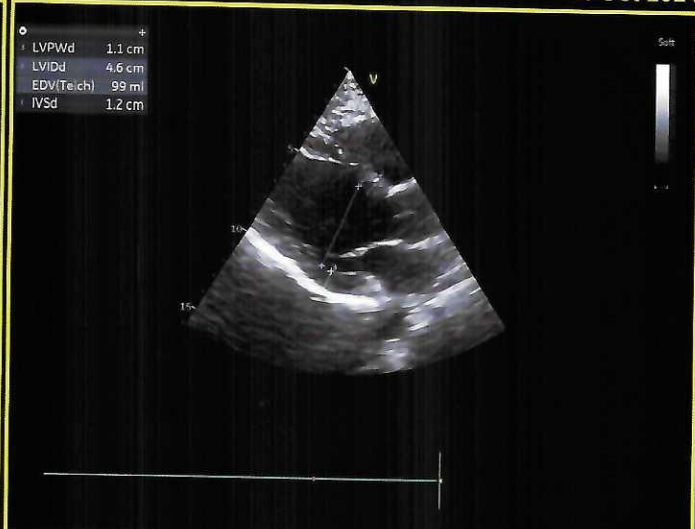
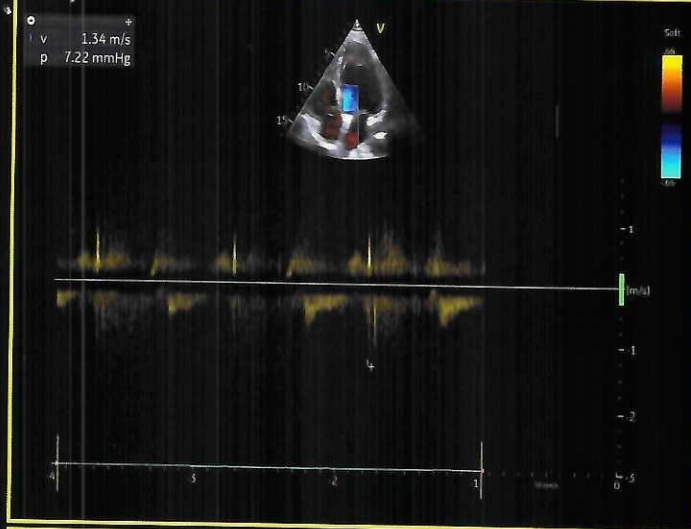
DR. GAURAV KHANDELWAL

**DM (Cardiology), FACC, FESC, FSCAI, FIC
INTERVENTIONAL CARDIOLOGIST**

Apollo Sage Hospitals

Name : SANDEEP BHADOURIYA

24 Oct 2024



Patient Name:	SANDEEP BHADOURIYA	Patient ID:	ASHB.0000031487
Age:	33 Years	Sex:	M
Accession Number:	17101.224012459	Modality:	US
Referring Physician:	Akhil Kumar Tiwari	Study:	ULTRASOUND - WHOLE ABDOMEN
Study Date:	24-Oct-2024		

ULTRA SONOGRAPHY ABDOMEN

Liver:- is enlarged in size (16.4cm) and shows mild increase in hepatic parenchymal echotexture. Portal and hepatic venous system appears normal. Intra and extra hepatic biliary radicals are not dilated.

Gall Bladder:- is normal in size and shape. Its lumen is echofree.

Pancreas is normal in size outline and echopattern.

Spleen is normal in size and echopattern.

Both kidneys are normal in size, shape and echogenicity. Central pelvicalyceal sinus and corticomedullary ratio are normal.

Right kidney measures:- 10.6x4.5cm.

Left kidney measures:- 11.0x4.8cm.

Urinary bladder is normal in shape and contour. Its wall is normal.

Prostate is borderline enlarged in size and shows homogeneous parenchymal echotexture. Estimated volume is- 25cc.

No evidence of ascites is seen.

IMPRESSION:- Sonography Study Reveals:-

- **Hepatomegaly with grade-I fatty liver.**
- **Borderline prostatomegaly (25cc).**

ADV:- Clinical Correlation.



DR. KRATI KHANDELWAL
CONSULTANT RADIOLOGIST



