

--

Name : Mrs. SONAM KATIYAR Age : 34Yr 6Mth 12Days Gender : Female
UHID : ASHB.0000030415 /BPLAH11710 W/BNo/RefNo: AHC
SIN \ LRN : 200815 \ 200816 \ 200817 \ 200818 \ 79934
Specimen : Blood
Ref Doctor : Dr. Gopal Batni



ASHB.0000030415

Collected on : 09-NOV-2024 09:21:29 AM Received on : 09-NOV-2024 10:21:06 AM Reported on : 09-NOV-2024 12:49:29 PM

MEDIWHEEL FULL BODY HEALTH ANNUAL PLUS CHECK FEMALE

TEST NAME	RESULT	BIOLOGICAL REFERENCE INTERVALS	UNITS
GLUCOSE - SERUM / PLASMA (FASTING)	93	70-100	mg/dL
GLUCOSE - PLASMA (FASTING)			
GLUCOSE - SERUM / PLASMA (POST PRANDIAL)	90	70-140	mg/dL
GLUCOSE - PLASMA - (POST PRANDIAL)			
GLYCOSYLATED HEMOGLOBIN (HBA1C) - WHOLE BLOOD	5.6	4.0-5.6	%
CHOLESTEROL - SERUM / PLASMA	193	Desirable: <200 Borderline High: 200-239 High >240	mg/dL
HDL CHOLESTEROL - SERUM / PLASMA	71	>40	mg/dL
LDL CHOLESTEROL - SERUM / PLASMA	123 *	Optimal: <100 Above optimal: 100-129 Borderline high: 130-159 High: 160-189 Very high: >190	mg/dL
TRIGLYCERIDES - SERUM / PLASMA	89	Normal<150 Borderline high 150-199 High 200-499 Very high: ≥ 500	mg/dL
VLDL CHOLESTEROL - SERUM	18	15-30	

Name : **Mrs. SONAM KATIYAR** Age : **34Yr 6Mth 12Days** Gender : **Female**
 UHID : ASHB.0000030415 / BPLAH11710 W/BNo/RefNo : AHC
 SIN \LRN : 200814 \ 200821 \ 79934
 Specimen : Urine
 Ref Doctor : Dr. Gopal Batni



Collected on : 09-NOV-2024 09:21:29 AM Received on : 09-NOV-2024 11:20:54 AM Reported on : 09-NOV-2024 02:24:48 PM

MEDIWHEEL FULL BODY HEALTH ANNUAL PLUS CHECK FEMALE

<u>TEST NAME</u>	<u>RESULT</u>	<u>BIOLOGICAL REFERENCE INTERVALS</u>	<u>UNITS</u>
URINE ROUTINE (CUE)			
MACROSCOPIC EXAMINATION			
Specific Gravity(Automated – Reflectance Spectrometer)	1.005	1.005 - 1.025	
Colour:(Naked Eye Examination)	Pale-Yellow		
Transparency:(Naked Eye Examination)	Clear		
pH(Automated – Reflectance Spectrometer)	Acidic		
Protein :(Automated – Reflectance Spectrometer/Sulpho salicylic acid method)	Nil		
Sugar:(Automated - Reflectance Spectrometer/ Benedict's Test)	Nil		
Ketone(Automated – Reflectance Spectrometer/Rothera's test)	Nil		
Bilirubin: (Automated – Reflectance Spectrometer/Fouchet's method)	Nil		
Cells:			
RBC(Automated - Reflectance spectrometer/Microscopy/Flow cytometric)	Nil		
Pus Cells(Automated – Reflectance spectrometer/Microscopy/Flow	2-4	0.0 - 5.0/HPF	/hpf

Name : **Mrs. SONAM KATIYAR** Age : **34Yr 6Mth 12Days** Gender : **Female**
 UHID : ASHB.0000030415 / BPLAH11710 W/BNo/RefNo : AHC
 SIN \LRN : 200814 \ 200821 \ 79934
 Specimen : Urine
 Ref Doctor : Dr. Gopal Batni



Collected on : 09-NOV-2024 09:21:29 AM Received on : 09-NOV-2024 11:20:54 AM Reported on : 09-NOV-2024 02:24:48 PM

cytometric)			
Epithelial Cells(Microscopic /Flow cytometric)	2-4	<20	/hpf
Yeast Cells	Absent		
Bacteria:	Absent		
Casts:(Microscopic /Flow cytometric)	Absent	ABSENT	
Crystals:(Microscopic /Flow cytometric)	Absent		
CBC			
HAEMOGLOBIN	13.8	12.0 to 15.1	g/dL
Packed cell volume (Calculated)	43.0	35.5 to 44.9	%
RBC COUNT(Impedance)	5.39 *	4.00-5.20	Million/ul
MCV-	79.8 *	80-100	fl
MCH-	25.7 *	27-32	pg
MCHC-	32.2	32-36	g/dL
RDW (Derived from RBC histogram)	17.4 *	12.2 - 16.1	%
TLC COUNT	7.56	4.0-11.0	10 ³ /mm ³
DIFFERENTIAL COUNT			
Neutrophils	62	40-80	%
Lymphocytes	30	20-40	%
Monocytes	6	2-10	%
Eosinophils	2	1-6	%
Basophils	0	0-2	%
Platelet Count(Impedance)	368.5	150-450	10 ³ /mm ³
Mean Platelet Volume	7.45	6.5-12.0	fl
ERYTHROCYTE SEDIMENTATION RATE (ESR)	37 *	0-20	mm/1st hr

Name : Mrs. SONAM KATIYAR Age : 34Yr 6Mth 12Days Gender : Female
UHID : ASHB.0000030415 / BPLAH11710 W/BNo/RefNo : AHC
SIN \LRN : 200814 \ 200821 \ 79934
Specimen : Urine
Ref Doctor : Dr. Gopal Batni



Collected on : 09-NOV-2024 09:21:29 AM Received on : 09-NOV-2024 11:20:54 AM Reported on : 09-NOV-2024 02:24:48 PM

Report Status:Final

* END OF REPORT *

CHECKED BY : 154494
727938

A handwritten signature in black ink, appearing to read 'Dr. Shubhra Prasad', located in the bottom right area of the report.

Dr. Shubhra Prasad
Consultant Pathologist

Printed On : 12-NOV-2024 10:56:43 AM

Name : Mrs. SONAM KATYAR Age : 34Yr 6Mth 12Days Gender : Female
UHID : ASHB.0000030415 / BPLAH11710 W/BNo/RefNo : AHC
SIN \LRN : 200819 \ 79934
Specimen : Blood
Ref Doctor : Dr. Gopal Batni



Collected on : 09-NOV-2024 09:21:29 AM Received on : 09-NOV-2024 11:34:15 AM Reported on : 09-NOV-2024 11:45:20 AM

MEDIWHEEL FULL BODY HEALTH ANNUAL PLUS CHECK FEMALE

TEST NAME RESULT

BLOOD GROUPING AND TYPING (ABO and Rh)

ABO Group: **O**
Rh (D) Type: **Positive**

Report Status:Final

* END OF REPORT *

CHECKED BY : 154612
 725449



Dr. Samir Singh
Consultant Blood Bank

Printed On : 12-NOV-2024 10:57:35 AM

Dr. Siddharth Malaiya

MBBS, MS (Ophthalmology), FLVPEI, Hyd. (Cornea & LASIK)

FBHIEC, Australia (Ocular surface & Stem cells)

Fellow L V Prasad Eye Institute, Hyderabad, Ex-Faculty ASG Eye Hospital, Jodhpur

Consultant Ophthalmologist & Cornea Super-specialist

Phaco-refractive & Cornea transplant surgeon



Name: Mrs. Sonam

Age/Sex: 34/R

Date: 9/11/21

Chc MHe.

Vision	UCVA	Glasses	Pinhole	AR	R
RE	6/6				
LE	6/6				

Eye	Sphere	Cylinder	Axis	BCVA	PG	R
RE						
LE						
Add						

[Handwritten signature]

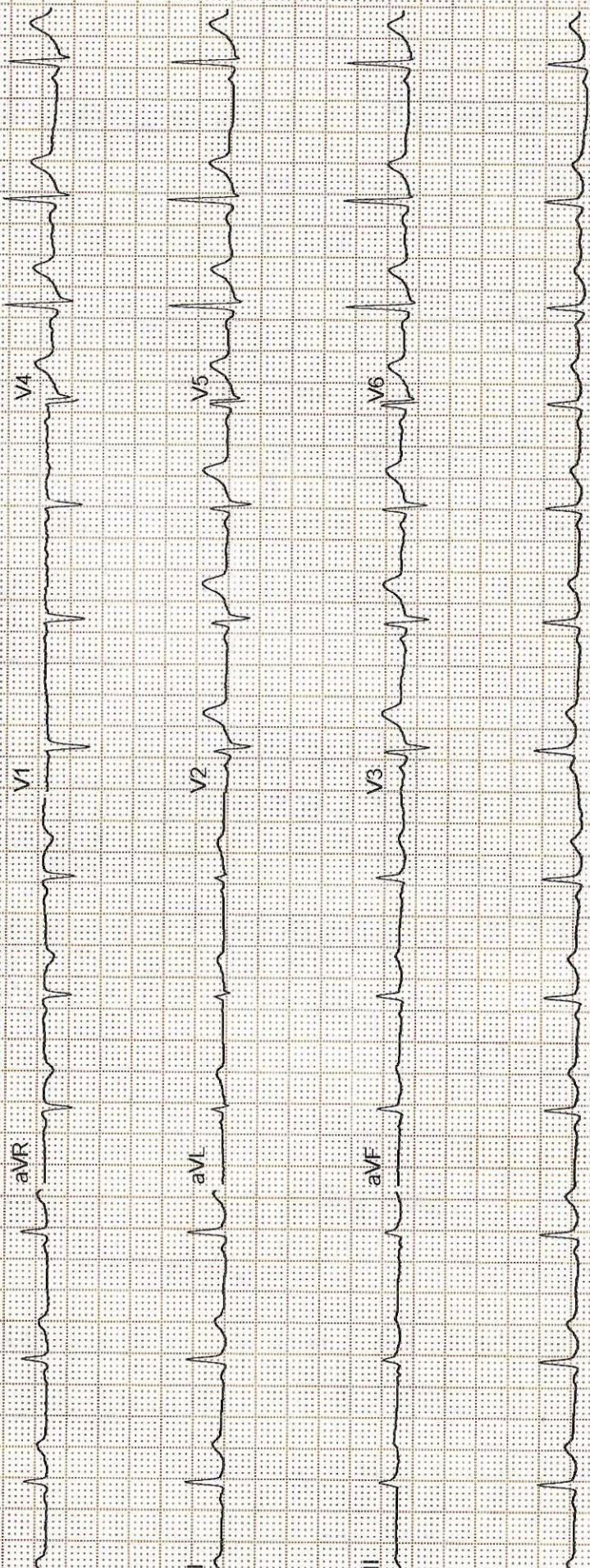
Order Nu
Indication
Medication 1
Medication 2
Medication 3

Technician
Ordering Ph
Referring Ph
Attending Ph

Normal sinus rhythm with sinus arrhythmia
Normal ECG



Female
QRS: 70 ms
QT / QTcBaz: 358 / 410 ms
PR: 112 ms
P: 86 ms
RR / PP: 756 / 759 ms
P / QRS / T: 23 / 53 / 37 degrees



ECHOCARDIOGRAPHY REPORT

Patient's Name	Sonam Katiyar	Date	09/11/2024
Age/Sex	34Y/F	UHID	HC -30415
Referred By	Health Check	Done By	Dr.Gaurav Khandelwal

M- Mode / 2D Measurements:

LA	30mm	Ao	24mm
IVSd	10mm	IVSs	14mm
LVEDd	40mm	LVESs	25mm
PWd	10mm	PWs	18mm
RA	29mm	RV	24mm

Doppler Study :-


Valves	Measurements			
Mitral Valve	E : 0.93m/sec	A : 0.54m/sec	E/A :1.72	E' : m/sec
Aortic Valve	AV Vmax : 1.42m/sec	-	-	-
Tricuspid Valve	TR PG : 19mmHg	-	-	-
Pulmonary Valve	PV Vmax :0.97m/sec	-	-	-

2D ECHO Doppler

Dimentions : Normal Chamber Dimentions
Mitral Valve : Normal
Aortic Valve : Normal
Tricuspid Valve : Normal
Pulmonary Valve : Normal
Pericardium : Normal
IVC :Normal
Diastolic Function :Normal
IAS/ IVS : Intact
RWMA :No **LVEF : 60%**

Impression :

- Normal 2D ECHO & Doppler Study
- No RWMA at Rest (LVEF: 60%)


DR. GAURAV KHANDELWAL
 DM (Cardiology), FACC, FESC, FSCAI, FIC
 INTERVENTIONAL CARDIOLOGIST

ULTRA SONOGRAPHY ABDOMEN

Patient Name:	SONAM KATIYAR	Patient ID:	ASHB.0000030415
Age:	34 Years	Sex:	F
Accession Number:	17101.224013165	Modality:	US
Referring Physician:	Gopal Batni	Study:	ULTRASOUND - WHOLE ABDOMEN
Study Date:	09-Nov-2024		

Liver:- is normal in size and shows mild increase in hepatic parenchymal echotexture . Portal and hepatic venous system appears normal. Intra and extra hepatic biliary radicals are not dilated.

Gall Bladder:- is normal in size and shape. Its lumen is echofree.

Pancreas is normal in size outline and echopattern.

Spleen is normal in size and echopattern.

Both kidneys are normal in size, shape and echogenicity. Central pelvicalyceal sinus and corticomedullary ratio are normal.

Right kidney measures:- 9.7x3.6cm.

Left kidney measures:- 10.9x5.1cm.

No evidence of ascites is seen.

Urinary bladder is normal in shape and contour. Its wall is normal.

Uterus:- Uterus is anteverted , mildly bulky in size and shows inhomogeneous echopattern with evidence of a tiny heterogeneously hypoechoic lesion measuring ~ 0.9x0.8cm in the fundal region. Cervix shows inhomogeneous echopattern.

Uterus measures:- 10.8x3.9x5.6cm. Endometrial thickness is 17.3mm.

Ovaries:- Both ovaries are normal in size , follicular pattern and show normal stromal echotexture.

Right ovary measures 4.9x1.1x2.3cm, volume- 6.6cc.

Left ovary measures ~ 3.5x1.7x1.2cm volume- 4cc – *It shows a tiny cystic lesion measuring ~ 1.6x0.9cm seen- Dominant follicle.*

No adnexal mass.

No free fluid in POD.

IMPRESSION:- Sonography Study Reveals:-

- Grade-I fatty liver.
- Tiny intramural fundal fibroid with no endometrial involvement.
- No adnexal mass lesion.

ADV:- Clinical Correlation.


DR. KRATI KHANDELWAL
CONSULTANT RADIOLOGIST



Patient Name:	SONAM KATIYAR	Patient ID:	ASHB.0000030415
Age:	34 Years	Sex:	F
Accession Number:	17101.124019572	Modality:	DX
Referring Physician:	Gopal Batni	Study:	CHEST
Study Date:	09-Nov-2024		

X-RAY CHEST (PA VIEW)

Both lung fields are clear. No active pleural or parenchymal lesion is seen.

The hila, mediastinum, bony thoracic cage and the diaphragmatic domes are normal.


The costophrenic and cardiophrenic angles are clear.

The cardiac silhouette is unremarkable.

IMP:- RADIOGRAPHIC IMAGE REVEALS:-

No significant abnormality detected.

Thanks for Ref



DR. HARI SANTOSH
CONSULTANT RADIOLOGIST

Date: 09-Nov-2024 12:13:38

