



PANACEA HOSPITAL

B 36/44 F.K KABIR NAGAR, DURGAKUND
TOLLFREE NO-18001233070. Whatsapp No - 8795832852
www.piire.org
panaceaquery@gmail.com|panceahospital@gmail.com



OP Slip

Print Date : 15-Nov-2024 11:52AM



UHID No	:- UD-24250004378	OP No	:- OP-24250013058	OP Date	:- 15 Nov 2024 11:52AM
Patient Name	:- Mr BHAGWAN DAS	Age/Sex	:- 28 Y/Male	Mobile No	:- 9536286650
Father	:- DAMODAR SINGH	Department	:- OPHTHALMOLOGY		
Pay Type	:- Cr	Consultant	:- Dr SANTOSH VERMA (MBBS,MS)		
Token No	:- NOR. - 6	Paid	:- 0.00		
Patient Type	:- Normal				
Address	:- BURAHARA,KHERAGAHEH,283121,Agra				

BP :- 177/74 **Rx**
 height :- 178
 Weight (kg) :- 85
 BMI :- 26.82

SPO2 - 98
 PR - 87
 NC - 38
 WC - 96
 CH - 100
 PEF - 350

VA $\left\{ \begin{array}{l} 6/6 \\ 6/6 \end{array} \right.$

Near $\left\{ \begin{array}{l} NG \\ NG \end{array} \right.$

BE. Fundus. WNL

Locally BE.

1. Carboxymethyl cellulose
 sodium - RTO
 0000

Printed By : Ms. Anjali Prajapati
 Created By : Ms. Anjali Prajapati

Dr. SANTOSH VERMA
 MBBS, MS (Ophthalmologist)
 MCI Reg. No. 09-34327



PANACEA HOSPITAL

B 36/44 F.K KABIR NAGAR, DURGAKUND
TOLLFREE NO-18001233070. Whatsapp No - 8795832852
www.piire.org
panaceaquery@gmail.com|panaceahospital@gmail.com

8795832848



OP Slip

Print Date : 15-Nov-2024 11:53AM



UHID No	:- UD-24250004378	OP No	:- OP-24250013059	OP Date	:- 15 Nov 2024 11:53AM
Patient Name	:- Mr BHAGWAN DAS	Age/Sex	:- 28 Y/Male	Mobile No	:- 9536286650
Father	:- DAMODAR SINGH	Department	:- DERMATOLOGY		
Pay Type	:- Cr	Consultant	:- Dr DR ASHUTOSH MISHRA (MBBS,MD)		
Token No	:- NOR. - 7	Paid	:- 0.00		
Patient Type	:- Normal				
Address	:- BURAHARA,KHERAGAHE,283121,Agra				

BP :- 177/124 **Rx**
 height :- 178
 Weight (kg) :- 85
 BMI :- 26.82

SpO2 - 98
 PR - 87
 MC - 38
 WC - 96
 CH - 100
 PEFr - 350

Rx
 • Calculated rbs OD & LTR
 • memosa ex Ci face
 • Edema gel → LTR (face)

Ad
 © KFFF

Today



Printed By : Ms. Anjali Prajapati
 Created By : Ms. Anjali Prajapati



PANACEA HOSPITAL

B 36/44 F.K KABIR NAGAR, DURGAKUND
TOLLFREE NO-18001233070. Whatsapp No - 8795832852
www.piire.org
panaceaquery@gmail.com|panaceahospital@gmail.com



OP Slip

Print Date : 15-Nov-2024 11:51AM



UHID No :- UD-24250004378	OP No :- OP-24250013057	OP Date :- 15 Nov 2024 11:51AM
Patient Name :- Mr BHAGWAN DAS	Age/Sex :- 28 Y/Male	Mobile No :- 9536286650
Father :- DAMODAR SINGH	Department :- DENTAL	
Pay Type :- Cr	Consultant :- Dr SHRUTI MISHRA (AA)	
Token No :- NOR. - 7	Paid :- 0.00	
Patient Type :- Normal		
Address :- BURAHARA,KHERAGAHEH,283121,Agra		

BP :- 177/74
 height :- 178
 Weight (kg) :- 85
 BMI :- 26.82

SpO2 - 98
 PR - 87
 MC - 38
 WC - 96
 CH - 100
 PEFr - 350

Rx cl => patient came for routine dental check up.

O/E => stain/calculus ++/++

P/P => chronic gen gingivitis

T/A => Scaling & polishes

Shruti

Dr. SHRUTI MISHRA
 BDS, (DENTIST)
 MCI Reg. No. (A-09784)

Printed By : Ms. Anjali Prajapati
 Created By : Ms. Anjali Prajapati



PANACEA HOSPITAL

B 36/44 F.K KABIR NAGAR, DURGAKUND
TOLLFREE NO-18001233070. Whatsapp No - 8795832852
www.piire.org
panaceaquery@gmail.com|panaceahospital@gmail.com



Print Date : 15-Nov-2024 11:50AM

OP Slip



UHID No :- UD-24250004378	OP No :- OP-24250013056	OP Date :- 15 Nov 2024 11:50AM
Patient Name :- Mr BHAGWAN DAS	Age/Sex :- 28 Y/Male	Mobile No :- 9536286650
Father :- DAMODAR SINGH	Department :- GENERAL MEDICINE	
Pay Type :- Cr	Consultant :- Dr Pallavi Mishra (MBBS,MD,MBBS)	
Token No :- NOR. - 7	Paid/Bal :- 0.00 /1030.00	
Patient Type :- Normal		
Address :- BURAHARA,KHERAGAEH,283121,Agra		

BP :- 127/74 **Rx**
 height :- 178
 Weight (kg) :- 85 kg
 BMI :- 26.82

SpO2 98%
 RR 87/min
 RBS
 UC 38
 WC 96
 PFR 350
 CH 100

Rx
 Tab Nutripure B12 OD
 Tab Antihelmo $\lt \circ$
 Pow Avacal 60 SUN/THU
 Pow Nutrimix 2TSF BD
 00 ——— 00

RIA 1 month

Printed By : Ms. Anjali Prajapati
 Created By : Ms. Anjali Prajapati

Dr. Pallavi Misra
 MBBS, MD (General Medicine)
 MCI Reg. No. 52033

Facilities:
 All clinical Biomedical & Hematology Investigations including Bone Marrow Examination
 VPT, Podiascan & Complete Foot Care (First Time in Purvanchal)
 All Hormonal Investigation by Chemiluminescent Method
 Visceral Fat by (AB-140) Ambulatory BP Monitoring
 CGMS & Insulin Pump Available
 PFT, 2D-ECHO (Color Doppler), Holter, TMT, Cardiac-3 available
 VIA, VILI, Colposcopy available
 Special Endocrinological Investigation Protocols.

ISO 9001:2008 Certified
 Mobile: 9389994334, 9554572190, 9453837595



Panacea Pathology

Clinical Reference Lab

Persistence, Preparedness and Precision
 EQAS (CMC Vellore Attached) & IQAS System
 पूर्वांचल की सर्वोत्तम गुणवत्ता वाली पैथोलॉजी

UHID No :- UD-24250004378 **Booking No/Date** :- 11 / 15-Nov-2024 11:56 AM
Patient Name :- Mr BHAGWAN DAS **Age/Sex** :- 28 Y/M
Father :- DAMODAR SINGH **Reg No** :- 24250004378
Address :- BURAHARA,KHERAGAEH,283121 , Agra **Mobile No** :- 9536286650
Consultant :- **Referred By** :- DR SELF

Investigations Observations Biological Ref. Interval Unit

HAEMATOLOGY

CBC

HAEMOGLOBIN <small>DefaultMethod / test Machine</small>	14.2	13.00 - 16.00	gm/dl
TLC <small>Methology / Carm</small>	6500	4000.00 - 11000.00	Cells/cumm.
DLC DIFFERENTIAL LEUCOCYTE COUNT			
NEUTROPHILS	63	40.00 - 75.00	%
LYMPHOCYTES	33	20.00 - 45.00	%
EOSINOPHILS	02	1.00 - 6.00	%
MONOCYTES	02	2.00 - 10.00	%
BASOPHILS	00	<1-2	%
PLATELET COUNT	1.47	1.50 - 4.10	lacs /cumm
PCV	44.2	33.00 - 42.00	%
RBC <small>Methology / Carm</small>	4.86	4.50 - 5.50	million/cumm
MCV(MEAN CELL VOLUME)	91.0	83.00 - 101.00	fl
MCH(MEAN CELL HAEMOGLOBIN)	29.2	27.00 - 32.00	pg
MCHC	32.1	31.50 - 35.00	gm%
RDW-CV	14.2	11.00 - 16.00	%
RDW-SD	52.4	37.00 - 57.00	fl

Consulting Pathologist
Dr. UMESH KUMAR
 MBBS, MD (Pathologist)
 M.D. Pathology
 MCI Reg. No. 41413

Lab Technician

Timing : 24/7 hrs

This Report is not valid for medico legal purpose

Note: These tests have technical limitations. Clinico-pathological interpretation is necessary. In case of any disparity test may be repeated immediately.

Address : 36/44 FK Kabir Nagar, Durgakund, Varanasi – 221005

Email: dramishra@gmail.com, drpallaviojha@gmail.com Website: panaceahospital.org

Facilities:

All clinical Biomedical & Hematology Investigations including Bone Marrow Examination
 VPT, Podiascan & Complete Foot Care (First Time in Purvanchal)
 All Hormonal Investigation by Chemiluminescent Method
 Visceral Fat by (AB-140) Ambulatory BP Monitoring
 CGMS & Insulin Pump Available
 PFT, 2D-ECHO (Color Doppler), Holter, TMT, Cardiac-3 available
 VIA, VILI, Colposcopy available
 Special Endocrinological Investigation Protocols.

ISO 9001:2008 Certified
 Mobile: 9389994334, 9554572190, 9453837595



Panacea Pathology

Clinical Reference Lab

Persistence, Preparedness and Precision
 EQAS (CMC Vellore Attached) & IQAS System
 पूर्वांचल की सर्वोत्तम गुणवत्ता वाली पैथोलॉजी

UHID No :- UD-24250004378 **Booking No/Date** :- 11 / 15-Nov-2024 11:56 AM
Patient Name :- Mr BHAGWAN DAS **Age/Sex** :- 28 Y/M
Father :- DAMODAR SINGH **Reg No** :- 24250004378
Address :- BURAHARA,KHERAGAEH,283121 , Agra **Mobile No** :- 9536286650
Consultant :- **Referred By** :- DR SELF

Investigations**Observations****Biological Ref. Interval****Unit****URINE EXAMINATION****URINE ROUTINE EXAMINATION****PHYSICAL EXAMINATION**

QUANTITY	25		ml
COLOR <small>Methology</small>	STRAW	CLEAR YELLOW	
APPEARANCE <small>DefaultMethod</small>	CLEAR	CLEAR	

CHEMICAL EXAMINATION

SPECIFIC GRAVITY	1.010	1.01 - 1.03	
PH	6.0	4.60 - 8.00	
GLUCOSE	NIL	60.00 - 100.00	mg/dl
PROTEIN-	NIL		

MICROSCOPIC EXAMINATION

PUS CELLS	NIL	2.00 - 3.00	/HPF
RBCS (RED BLOOD CELLS)	NIL	4.50 - 5.50	/HPF
EPITHELIAL CELLS	01-02		/HPF
CASTS	ABSENT	ABSENT	
CRYSTALS	ABSENT	ABSENT	

Consulting Pathologist
Dr. UMESH KUMAR
 MBBS, MD (Pathologist)
 M.D. Pathology
 MCI Reg. No. 41413

Lab Technician

Timing : 24/7 hrs

This Report is not valid for medico legal purpose

Note: These tests have technical limitations. Clinico-pathological interpretation is necessary. In case of any disparity test may be repeated immediately.

Address : 36/44 FK Kabir Nagar, Durgakund, Varanasi – 221005

Email: dramishra@gmail.com, drpallaviojha@gmail.com Website: panaceahospital.org

Facilities:

All clinical Biomedical & Hematology Investigations including Bone Marrow Examination
 VPT, Podiascan & Complete Foot Care (First Time in Purvanchal)
 All Hormonal Investigation by Chemiluminescent Method
 Visceral Fat by (AB-140) Ambulatory BP Monitoring
 CGMS & Insulin Pump Available
 PFT, 2D-ECHO (Color Doppler), Holter, TMT, Cardiac-3 available
 VIA, VILI, Colposcopy available
 Special Endocrinological Investigation Protocols.

ISO 9001:2008 Certified
 Mobile: 9389994334, 9554572190, 9453837595



Panacea Pathology

Clinical Reference Lab

Persistence, Preparedness and Precision
 EQAS (CMC Vellore Attached) & IQAS System
 पूर्वांचल की सर्वोत्तम गुणवत्ता वाली पैथोलॉजी

UHID No :- UD-24250004378 **Booking No/Date** :- 11 / 15-Nov-2024 11:56 AM
Patient Name :- Mr BHAGWAN DAS **Age/Sex** :- 28 Y/M
Father :- DAMODAR SINGH **Reg No** :- 24250004378
Address :- BURAHARA,KHERAGAEH,283121 , Agra **Mobile No** :- 9536286650
Consultant :- **Referred By** :- DR SELF

Investigations	Observations	Biological Ref. Interval	Unit
HAEMATOTOLOGY			
ESR	18.0	0.00 - 15.00	mm at 1 hr
BLOOD GROUP ABO & RH FACTOR			
BLOOD GROUP	"O"		
RH FACTOR	POSITIVE		
HBA1C -(BY GOLD STANDARD METHOD :HPLC)	5.4	Normal: 4.0 - 5.4 Prediabetic : 5.5 -6.3 Diabetes mellitus := 6.4	%
BIOCHEMISTRY			
HDL CHOLESTEROL	39.0	35.30 - 79.50	mg/dl
LDL CHOLESTEROL	70.6	<130	mg/dl
TRIGLYCERIDES	142.0	35.00 - 160.00	mg/dl
BILIRUBIN [TDI]			
TOTAL BILIRUBIN	0.67	0.00 - 1.20	mg/dl
DIRECT BILIRUBIN	0.24	0.00 - 0.30	
INDIRECT BILIRUBIN	0.43	0.20 - 0.70	mg/dl
S.CREATININE	0.76	0.60 - 1.40	mg/dl
BLOOD UREA	21.0	10.00 - 50.00	mg/dl
URIC ACID			
URIC ACID	3.76	3.60 - 7.70	mg/dl

Lab Technician

Consulting Pathologist

Dr. UMESH KUMAR
 MBBS, MD (Pathology)
 MCI Reg. No. 41413

Timing : 24/7 hrs

This Report is not valid for medico legal purpose

Note: These tests have technical limitations. Clinico-pathological interpretation is necessary. In case of any disparity test may be repeated immediately.

Address : 36/44 FK Kabir Nagar, Durgakund, Varanasi – 221005

Email: dramishra@gmail.com, drpallaviojha@gmail.com Website: panaceahospital.org

Facilities:

All clinical Biomedical & Hematology Investigations including Bone Marrow Examination
 VPT, Podiascan & Complete Foot Care (First Time in Purvanchal)
 All Hormonal Investigation by Chemiluminescent Method
 Visceral Fat by (AB-140) Ambulatory BP Monitoring
 CGMS & Insulin Pump Available
 PFT, 2D-ECHO (Color Doppler), Holter, TMT, Cardiac-3 available
 VIA, VILI, Colposcopy available
 Special Endocrinological Investigation Protocols.

ISO 9001:2008 Certified
 Mobile: 9389994334, 9554572190, 9453837595



Panacea Pathology

Clinical Reference Lab

Persistence, Preparedness and Precision
 EQAS (CMC Vellore Attached) & IQAS System
 पूर्वांचल की सर्वोत्तम गुणवत्ता वाली पैथोलॉजी

UHID No :- UD-24250004378 **Booking No/Date** :- 11 / 15-Nov-2024 11:56 AM
Patient Name :- Mr BHAGWAN DAS **Age/Sex** :- 28 Y/M
Father :- DAMODAR SINGH **Reg No** :- 24250004378
Address :- BURAHARA,KHERAGAEH,283121 , Agra **Mobile No** :- 9536286650
Consultant :- **Referred By** :- DR SELF

Investigations Observations Biological Ref. Interval Unit

IMMUNOLOGY

THYROID PROFILE (T3,T4,TSH)

Investigations	Observations	Biological Ref. Interval	Unit
T3	1.0	0.60 - 1.81	ng/ml
T4	7.6	4.50 - 10.90	ug/dl
TSH	2.15	0.39 - 6.10	uIU/mL

BIOCHEMISTRY

BLOOD SUGAR FASTING

Investigations	Observations	Biological Ref. Interval	Unit
GLUCOSE	88.0	60.00 - 100.00	mg/dl
PRE-DIABETICS(IMPAIRED FASTING TOLER)	-	100.00 - 125.00	mg/dl
DIABETICS	-	upto 126	mg/dl
TARGET IN DM	-	80.00 - 130.00	mg/dl

PARASITOLOGY

STOOL ROUTINE

GROSS EXAMINATON

Investigations	Observations	Biological Ref. Interval	Unit
COLOR <i>Methology</i>	YELLOW	CLEAR YELLOW	
CONSISTANCY	NORMAL		
BLOOD	ABSENT		
MUCUS	PRESNT		

Consulting Pathologist
Dr. UMESH KUMAR
 MBBS, MD (Pathologist)
 MCh, Reg. Pathology 41413

Lab Technician

Timing : 24/7 hrs

This Report is not valid for medico legal purpose

Note: These tests have technical limitations. Clinico-pathological interpretation is necessary. in case of any disparity test may be repeated immediately.

Address : 36/44 FK Kabir Nagar, Durgakund, Varanasi – 221005

Email: dramishra@gmail.com, drpallaviojha@gmail.com Website: panaceahospital.org

Facilities:

All clinical Biomedical & Hematology Investigations including Bone Marrow Examination
 VPT, Podiascan & Complete Foot Care (First Time in Purvanchal)
 All Hormonal Investigation by Chemiluminescent Method
 Visceral Fat by (AB-140) Ambulatory BP Monitoring
 CGMS & Insulin Pump Available
 PFT, 2D-ECHO (Color Doppler), Holter, TMT, Cardiac-3 available
 VIA, VILI, Colposcopy available
 Special Endocrinological Investigation Protocols.

ISO 9001:2008 Certified

Mobile: 9389994334, 9554572190, 9453837595



Panacea Pathology

Clinical Reference Lab

Persistence, Preparedness and Precision
 EQAS (CMC Vellore Attached) & IQAS System
 पूर्वांचल की सर्वोत्तम गुणवत्ता वाली पैथोलॉजी

UHID No :- UD-24250004378 **Booking No/Date** :- 11 / 15-Nov-2024 11:56 AM
Patient Name :- Mr BHAGWAN DAS **Age/Sex** :- 28 Y/M
Father :- DAMODAR SINGH **Reg No** :- 24250004378
Address :- BURAHARA,KHERAGAEH,283121 , Agra **Mobile No** :- 9536286650
Consultant :- **Referred By** :- DR SELF

Investigations	Observations	Biological Ref. Interval	Unit
<u>MICROSCOPIC EXAMINATION</u>			
OVA OR EGGS OF HELMINTHS	ABSENT		
CYST OF PROTOZOA	ABSENT		
VEG. FORMS OF PROTOZOA	ABSENT		
PUS CELLS	02-03	2.00 - 3.00	/HPF
RBC <i>Methology / Carm</i>	NIL	4.50 - 5.50	million/cumm

* END OF REPORT *

Consulting Pathologist
Dr. UMESH KUMAR
 Dr. Umesh Kumar
 MBBS, MD (Pathologist)
 MCI Reg. No. 41113

Lab Technician

Timing : 24/7 hrs

This Report is not valid for medico legal purpose

Note: These tests have technical limitations. Clinico-pathological interpretation is necessary. In case of any disparity test may be repeated immediately.

Address : 36/44 FK Kabir Nagar, Durgakund, Varanasi – 221005

Email: dramishra@gmail.com, drpallaviojha@gmail.com Website: panaceahospital.org

Facilities:

All clinical Biomedical & Hematology Investigations
 including Bone Marrow Examination
 VPT, Podiascan & Complete Foot Care (First Time in Purvanchal)
 All Hormonal Investigation by Chemiluminescent Method
 Visceral Fat by (AB-140) Ambulatory BP Monitoring
 CGMS & Insulin Pump Available
 PFT, 2D-ECHO (Color Doppler), Holter, TMT, Cardiac-3 available
 VIA, VILI, Colposcopy available
 Special Endocrinological Investigation Protocols.

ISO 9001:2008 Certified

Mobile: 9389994334, 9554572190, 9453837595



Panacea Pathology

Clinical Reference Lab

Persistence, Preparedness and Precision
 EQAS (CMC Vellore Attached) & IQAS System
 पूर्वाचल की सर्वोत्तम गुणवत्ता वाली पैथोलॉजी

UHID No	: - UD-24250004378	Booking No/Date	: - 103 / 15-Nov-2024 02:59 PM
Patient Name	: - Mr BHAGWAN DAS	Age/Sex	: - 28 Y/M
Father	: - DAMODAR SINGH	Reg No	: - 24250004378
Address	: - BURAHARA,KHERAGAEH,283121 , Agra	Mobile No	: - 9536286650
Consultant	: - Dr PALLAVI MISHRA (MBBS)		

Investigations**Observations****Biological Ref. Interval****Unit****BIOCHEMISTRY****CALCIUM**

9.24

8.60 - 10.40

mg/dl

* END OF REPORT *

Lab Technician**Consulting Pathologist**

Dr. UMESH KUMAR
 Dr. Umesh Kumar
 MBBS, MD (Pathologist)
 MCT Reg. No. 41413

Timing : 24/7 hrs**This Report is not valid for medico legal purpose**

Note: These tests have technical limitations. Clinico-pathological interpretation is necessary. In case of any disparity test may be repeated immediately.

Address : 36/44 FK Kabir Nagar, Durgakund, Varanasi – 221005

Email: dramishra@gmail.com, drpallaviojha@gmail.com Website: panaceahospital.org



Call Now - 1800-123-3070

PANACEA HOSPITAL



A shelter for many hearts A Home for many lives

(An ISO 9001:2008 Certified Organisation)
Lab Attached with CMC Under EQAS Scheme

Dept. of Radiodiagnosis - 32 Slice CT Scan, 3D/4D USG, 2D ECHO, Colour Doppler, Intervention Procedures, Digital X-Ray

PATIENT NAME	BHAGWAN DAS	AGE/SEX	28YRS/M
REF. BY DR.	DR. ASHUTSOH MISHRA	DATE	15/11/2024

X-RAY CHEST (AP VIEW)

- Lung fields show hazy opacities in both parahilar, basal zone with mild prominent brochopulmonary markings.
- Rest of the bilateral lung fields appear normal.
- Trachea and mediastinum appear normal in position.
- Both hila appear normal in size and are symmetrical.
- Transverse cardiac diameter is within normal limits.
- Both CP angles appear clear. Normal position and contour diaphragms noted.
- Bony rib cage and soft tissue shadows appear normal.

Thanks for reference.

Radiologist
Dr. Rahul Kumar Tiwari
MBBS, MD (Radio Diagnosis)
MCI Reg. No. 57557

Disclaimer: This report is not valid for Madicolegal or Judicial Purpose. Radiological diagnosis is solely interpretation of images produced by tissue & may not be always conclusive.

Address : B36/44 B4 Kabir Nagar (Near Sanjay Shiksha Niketan), Durgakund, Varanasi

Mobile : 9554572190 / 9453837595 / Recpn, 9389994334

Email : dramishra@gmail.com, drpallaviojha@gmail.com, Website : www.paire.org

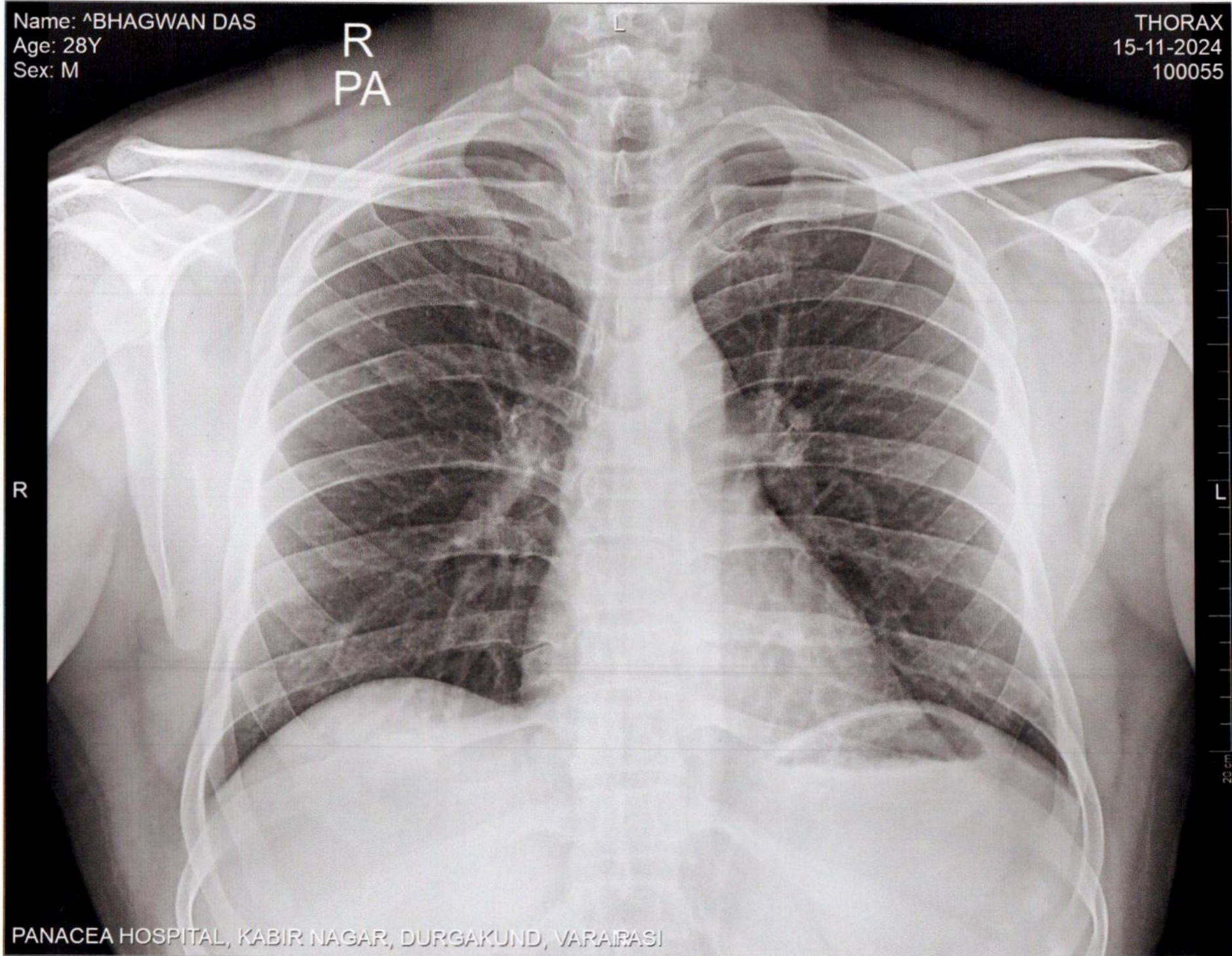
Name: ^BHAGWAN DAS
Age: 28Y
Sex: M

R
PA

THORAX
15-11-2024
100055

R

PANACEA HOSPITAL, KABIR NAGAR, DURGAKUND, VARANASI





PANACEA HOSPITAL



A shelter for many hearts A Home for many lives
 (An ISO 9001:2008 Certified Organisation)
 Lab Attached with CMC Under EQAS Scheme

Dept. of Radiodiagnosis - 32 Slice CT Scan, 3D/4D USG, 2D ECHO, Colour Doppler, Intervention Procedures, Digital X-Ray

NAME: BHAGWAN DAS

AGE/SEX: 28YRS/MALE

REF. DR. DR. ASHUTOSH MISHRA (MD)

DATE: 15/11/2024


Echo - Cardiography

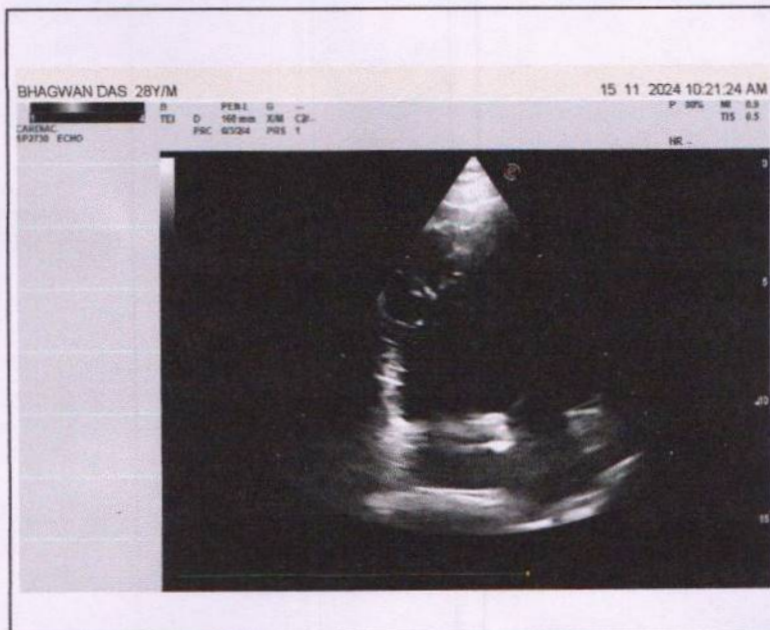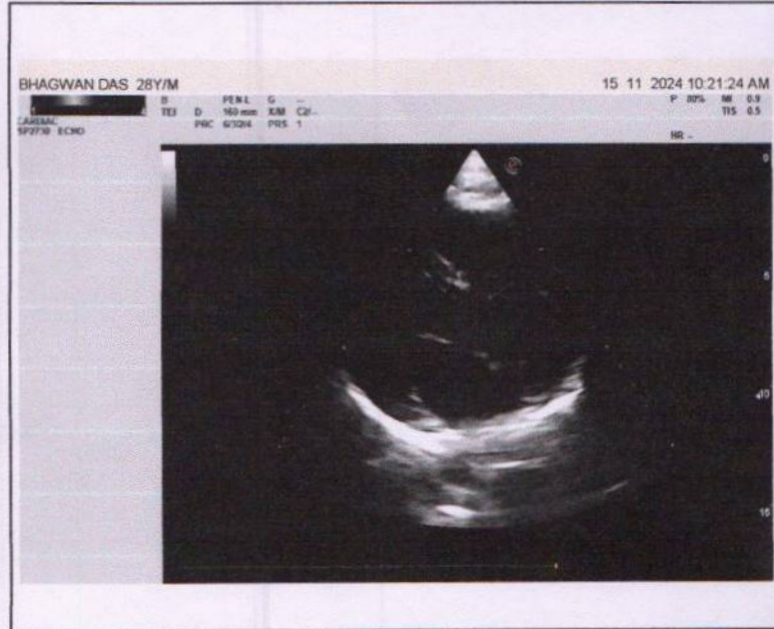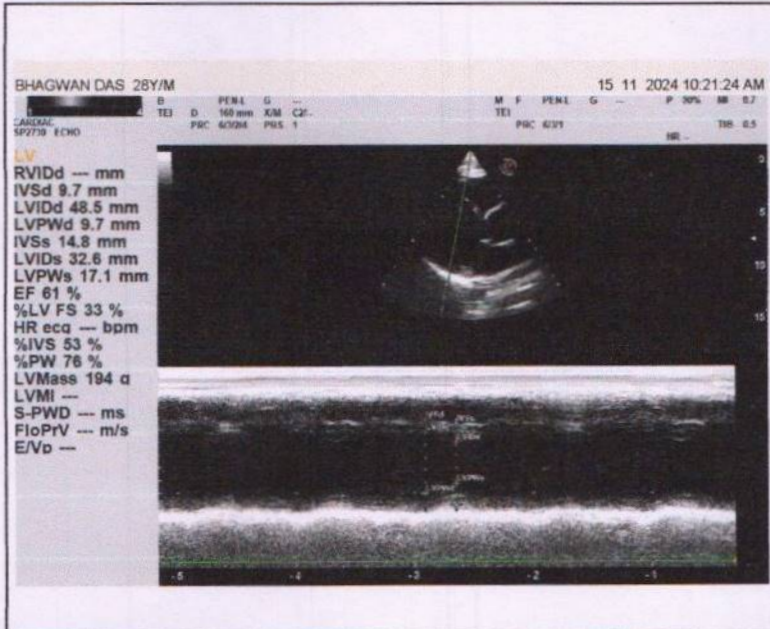
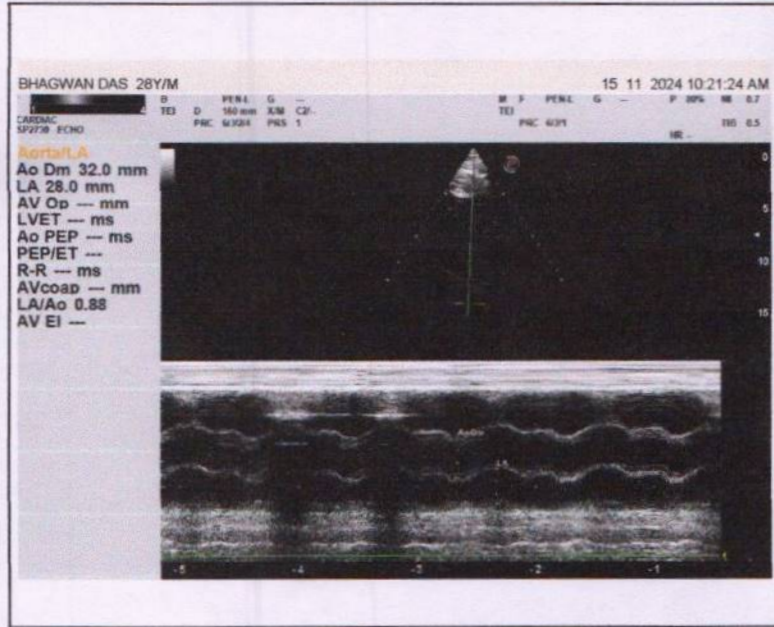
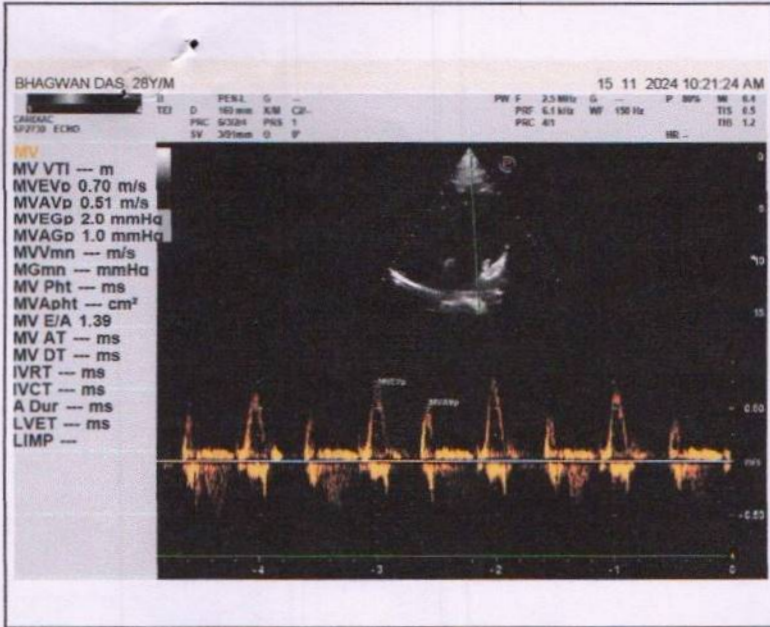
MITRAL VALVE Doppler	AML - normal morphology MV Flow - E - 0.7 A-0.5 E/A=1.39	PML - normal morphology MVA - 3.0 cm ² Mitral Regurgitation - No
TRICUSPID VALVE Doppler	Normal TV Flow - No	Tricuspid Regurgitation - No
PULMONARY VALVE Doppler	Normal PV Flow - No	Pulmonary Regurgitation - No
AORTIC VALVE Doppler	Trileaflet-No AV Flow - no	Aortic Regurgitation - No
MEASUREMENT	Aorta - 32.0 (20-38) mm IVS ed - 9.7 (6-12) mm LVID ed - 48.5 (35-55) mm LVPW ed - 9.7 (6-12) mm OA - 7 (> 5) mm	LA - 28.0 (24-32) mm IVS es - 14.8 (6-12) mm LVID es - 32.6 (24-40) mm LVPW es - 17.1 (6-12) mm EPSS - 4 (< 9) mm

CONCLUSION All cardiac chamber dimensions are WNL
 No valvular abnormalities
 Good LV systolic function present Modified Simpson's method (4C, 2C) (LVEF-61%)
 No diastolic dysfunction present (E/A = 1.39)
 No pericardial effusion
 No RWMA
 Intact IAS / IV
 No PAH
 No intra cardiac mass /thrombus /vegetation

IMPRESSION Normal Echocardiogram


 Niraj Mishra
 Physician Assistant
 (PIIRE)


 Dr. Pallavi Mishra
 MBBS, MD (MFD) Lucknow
 Echocardiography Specialist, WMAE
 Non-invasive cardiologist
 Women Cardiologist
 MCI Reg. No. 52033





Call Now - 1800-123-3070

PANACEA HOSPITAL



A shelter for many hearts A Home for many lives
(An ISO 9001:2008 Certified Organisation)
Lab Attached with CMC Under EQAS Scheme

Dept. of Radiodiagnosis - 32 Slice CT Scan, 3D/4D USG, 2D ECHO, Colour Doppler, Intervention Procedures, Digital X-Ray

NAME: BHAGWAN DAS
REF.DR.ASHUTOSH MISHRA(MD)

AGE/SEX: 28 YRS/MALE
DATE: 15/11/2024

ULTRASOUND WHOLE ABDOMEN REPORT

Liver: Normal in size(134mm), shape, & echogenicity. Intra & extra hepatic biliary radicals & vascular structures are normal. Margins are smooth and regular.

Gall bladder: Normally distended with echo free lumen.

Portal vein: Normal in course and caliber.

CBD diameter: Visualized part normal in course & caliber.

Pancreas: Normal in size, shape & echogenicity. Margins are smooth & regular. No diffuse/ focal lesion seen. Pancreatic duct not visualized.

Spleen: Normal in size, shape & echogenicity. Margins are smooth & regular. No diffuse / focal lesion seen.

Kidney: Both normal in size, shape echogenicity & position. Cortical-medullary differentiation is maintained. Pelvicalyceal system normal. No evidence of any calculus/mass lesion seen. No hydronephrosis/ hydroureter seen. No suprarenal mass lesion.

Urinary bladder: Normally distended with normal wall thickness. No echogenic foci lumen or diverticula seen. Both VUJ appears normal. No evidence of calculus / mass lesion seen.

Prostate: Normal in size(31X35X33mmVol19.9ml), shape & echogenicity.

Others: No free fluid in peritoneal cavity.
No free fluid in bilateral pleural cavity.
No evidence of significantly enlarged retroperitoneal/ mesenteric lymph nodes noted.

IMPRESSION: - **NO OBVIOUS SONOLOGICAL ABNORMALITY SEEN.**

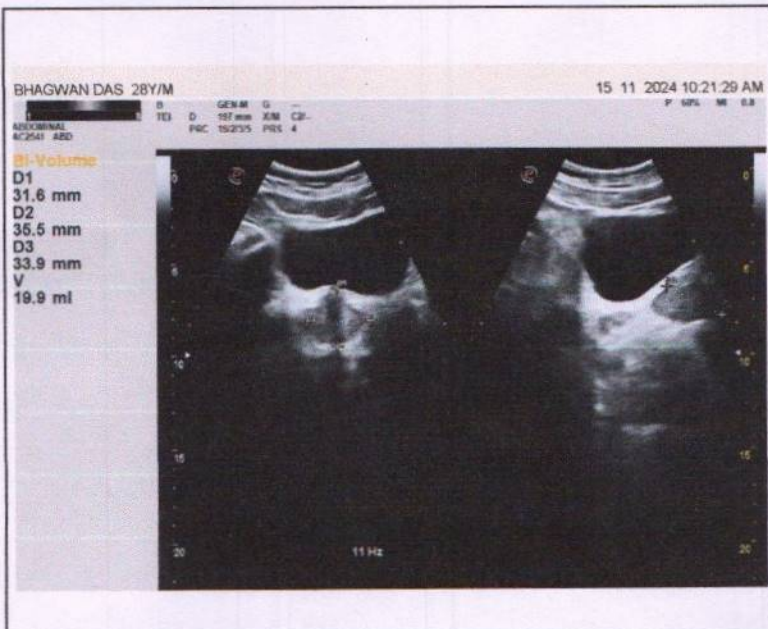
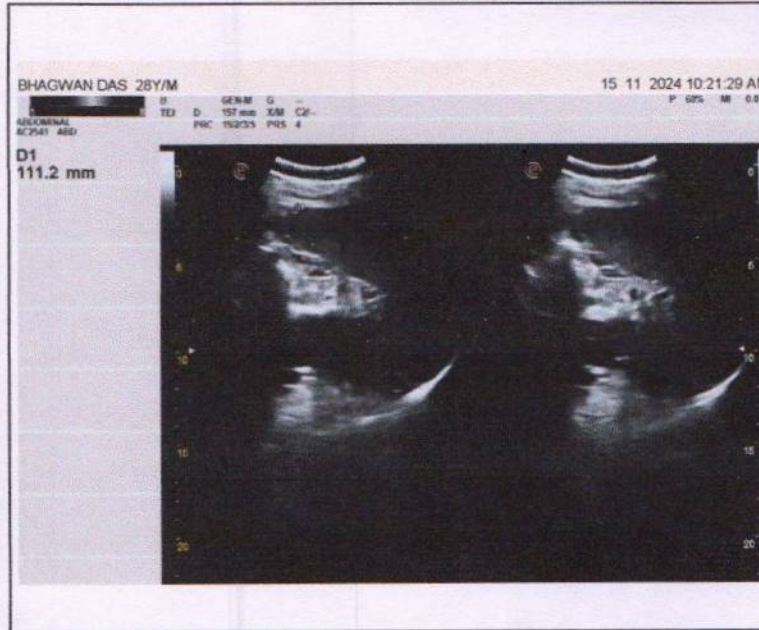
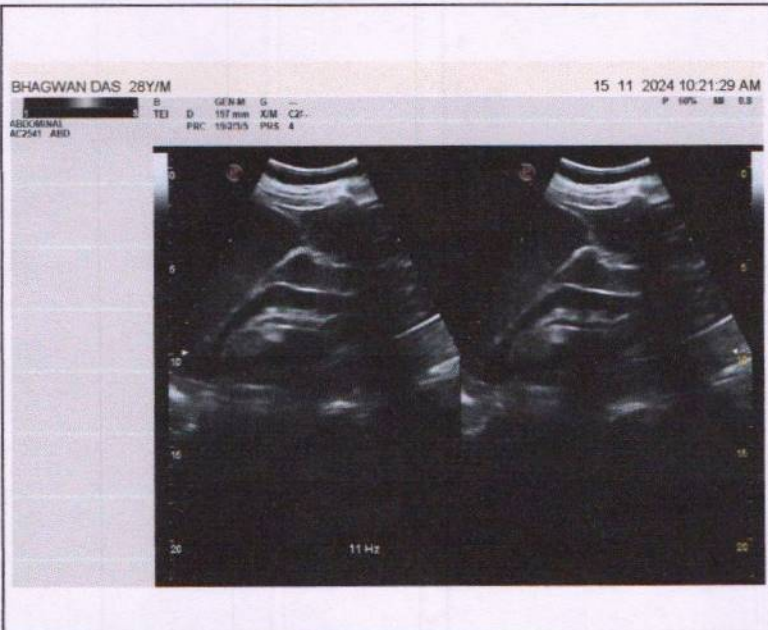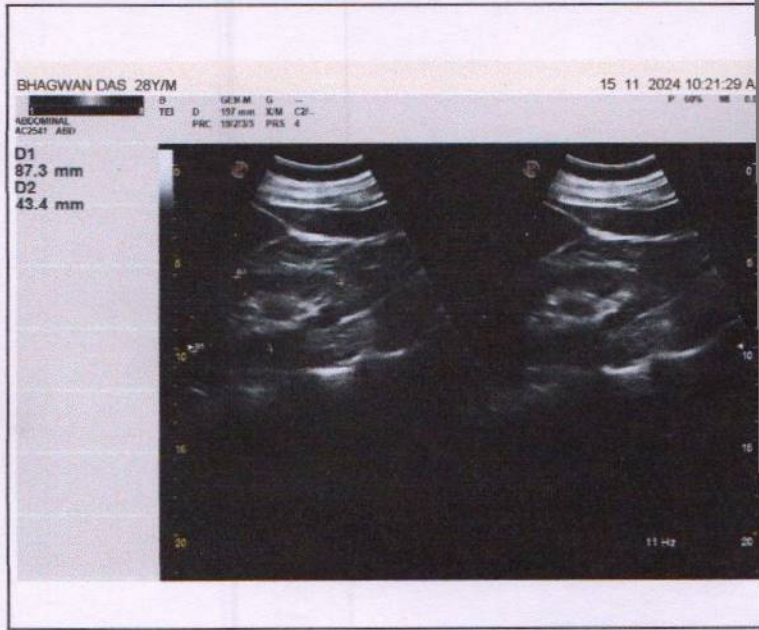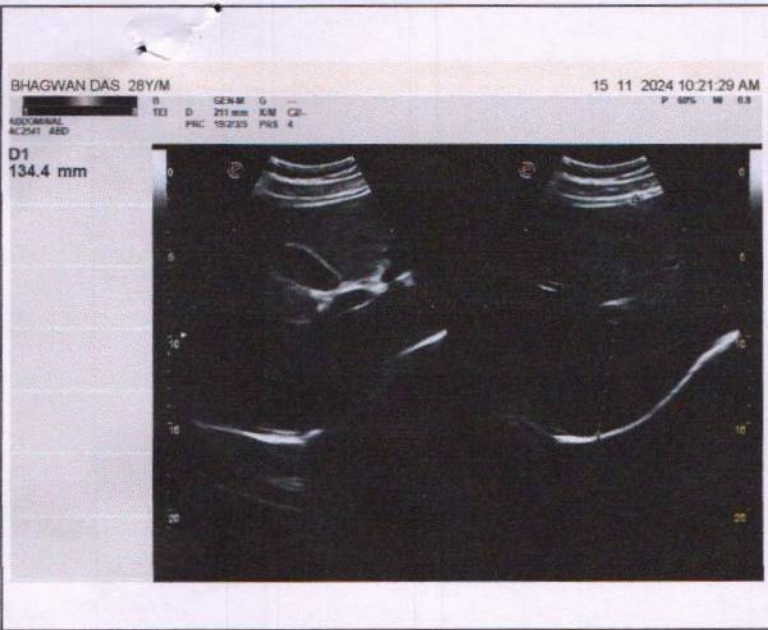
Please correlate clinically and further investigations.

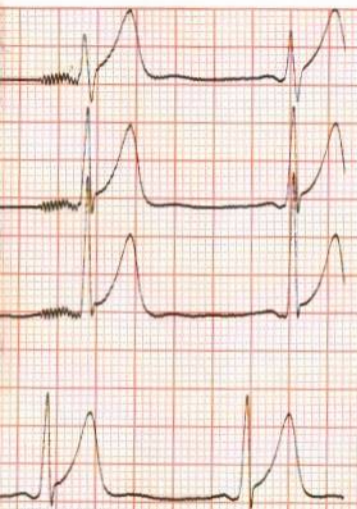
Sonologist
Dr. Rahul Kumar Tiwari
MBBS, MD (Radio Diagnosis)
MCI Reg. No. 57557

Note: (1) This report is not valid for medico-legal purposes.
(2) In case of any discrepancy due typing error, please get it Rectified immediately.

Disclaimer: This report is not valid for Madicolegal or Judicial Purpose. Radiological diagnosis is solely interpretation of images produced by tissue & may not be always conclusive.

Address : B36/44 B4 Kabir Nagar (Near Sanjay Shiksha Niketan), Durgakund, Varanasi
Mobile : 9554572190 / 9453837595 / Recpn, 9389994334
Email : dramishra@gmail.com, drpallaviojha@gmail.com, Website : www.piire.org

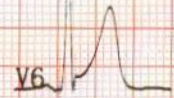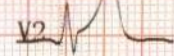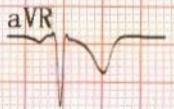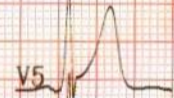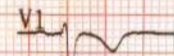
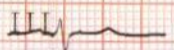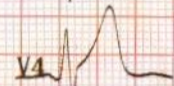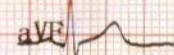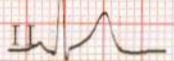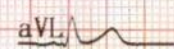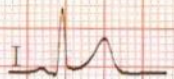




10mm/mV

10mm/mV

10mm/mV



25mm/s

2024-11-15 10:17

<< Conclusions >>

ID :
 Name : **Bhagwan Das**
 Sex : **M** Age : **28**
 Height : **178** Weight : **85Kg**
 SYS :
 DIA :

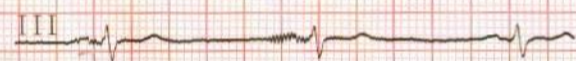
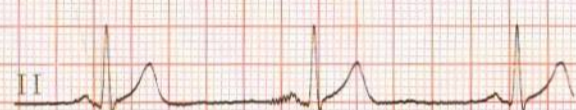
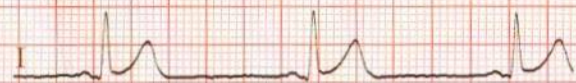Sinus mode Bradycardia,
 Longitudinal Left axis deviation,
 Report need physician confirm

HR [bpm] : 56
 PR Interval ms : 132
 P Duration ms : 120
 QRS Duration ms : 83
 T Duration ms : 205
 QT/QTc [ms] : 355/343
 P/QRS/T Axis deg : 60.6/28.0/36.8
 R(V5)/S(V1) mV : 1.36/0.71
 R(V5)+S(V1) mV : 2.08

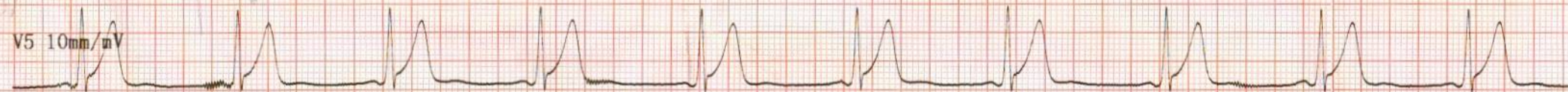Dr. Pallavi Mishra
 BBS, MD (General Medicine)
 MCI Reg. No. 52033

Physician _____

AUTO 10mm/mV

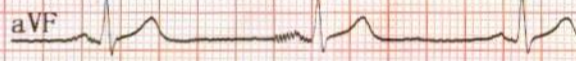
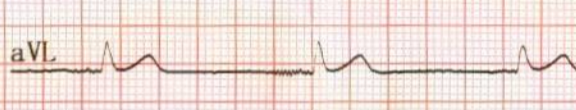
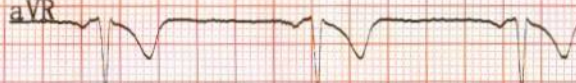V5 10mm/mV

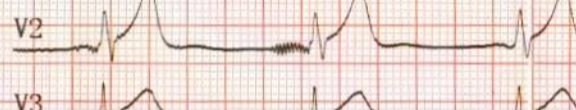
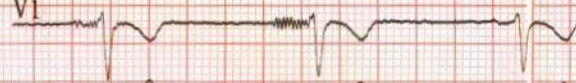
25mm/s AC50Hz+EMG35Hz+DFT

10mm/mV



10mm/mV



10mm/mV

