

neeral sharma
 Age: Male
 cm / kg

HR 66/min
 Interval: RR 903 ms
 P 104 ms
 PR 158 ms
 QR5 90 ms
 QT 388 ms
 QTc 408 ms

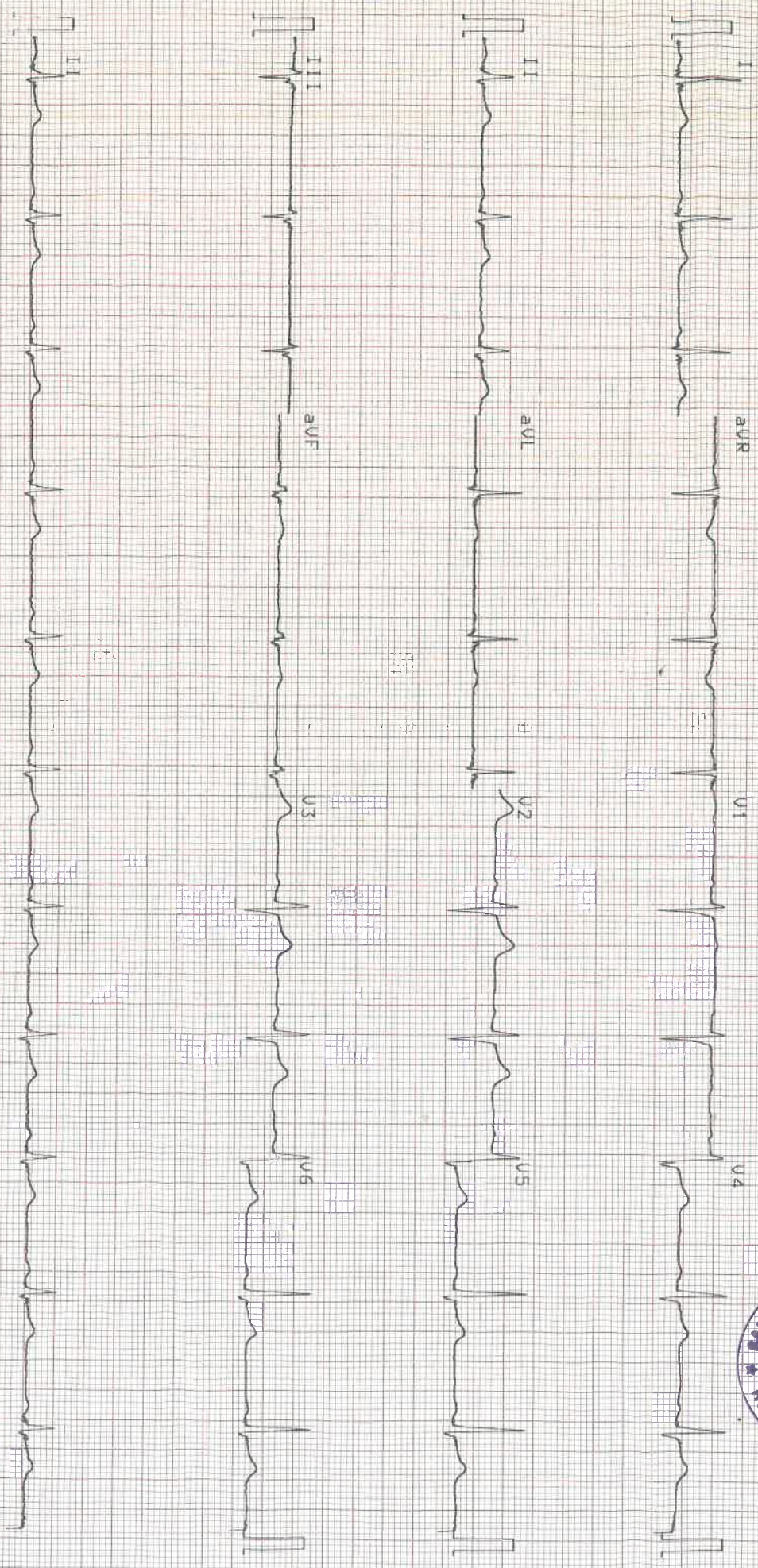

Raxis: P 30°
 QR5 -21°
 T 25°

P (II) 0.06 mV
 S (V1) -0.86 mV
 R (V5) 1.25 mV
 Sokol: 2.11 mV

SINUS RHYTHM
 LEFTWARD AXIS
 OTHERWISE NORMAL ECG

UNCONFIRMED REPORT

DR. PAVAN ROY
 MD, DM (CARDIOLOGY)
 CONSULTANT CARDIOLOGIST
 REG. NO. G-23390
 M No. 9305993199



25 mm/s
 10 mm/mV
 SCHILLER

50 55F 505 5a 08 MAR 25 11:29:39 samanvay hospital baroda Part No.2.157037M 01.02 1.33 C1m