

25.10.2024 10:36:22

73 bpm
-- / -- mmHg

Female

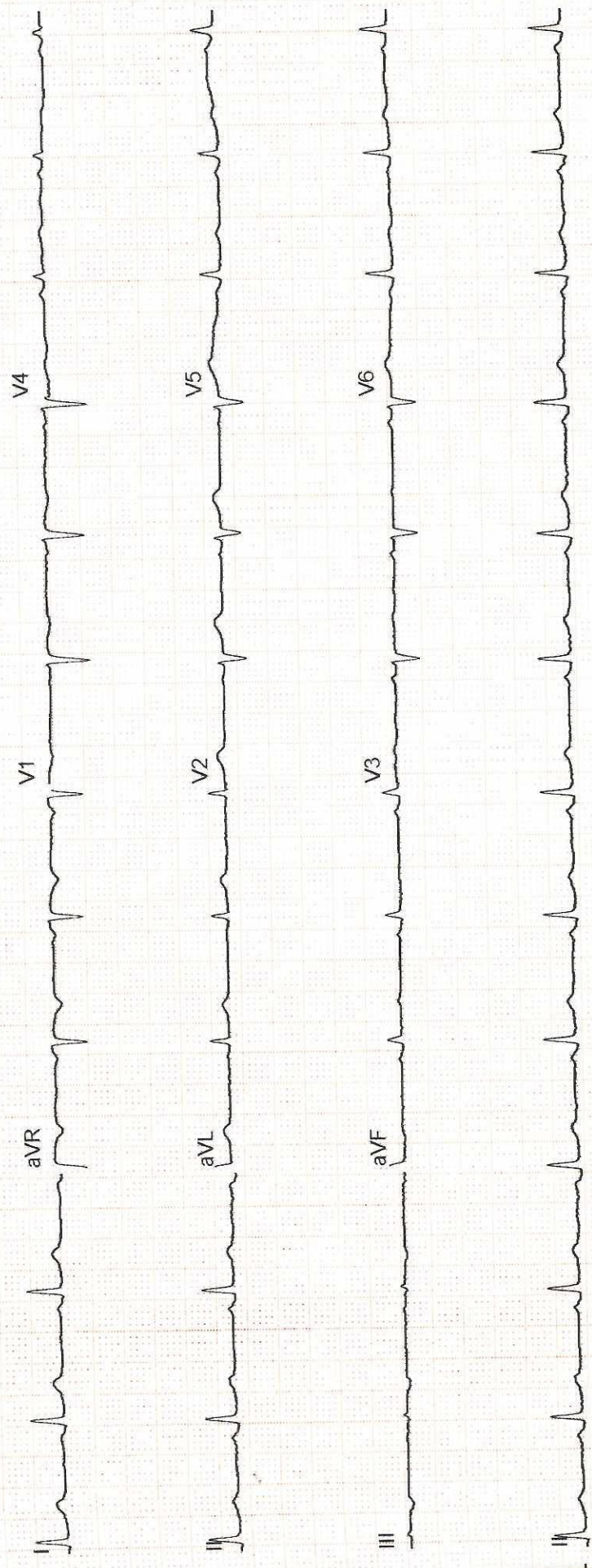
QRS : 74 ms
QT / QTcBaz : 350 / 385 ms
PR : 122 ms
P : 90 ms
RR / PP : 816 / 821 ms
P / QRS / T : 40 / 30 / 19 degrees

Normal sinus rhythm
Low voltage QRS
Cannot rule out Anterior infarct , age undetermined
Abnormal ECG

Technician:
Ordering Ph:
Referring Ph:

Normal Sinus Rhythm
[Signature]


Location:
F: M:
Order Nu. Jr:
Indication:
Medication 1:
Medication 2:
Medication 3:

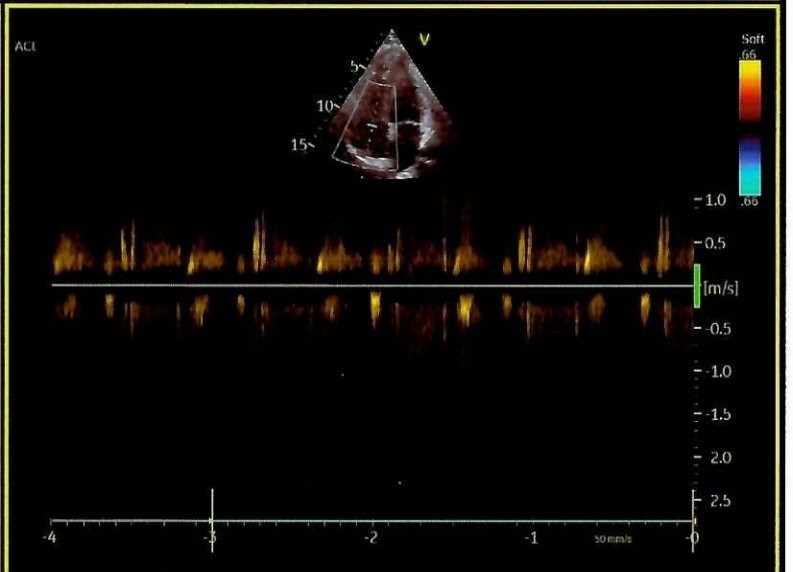
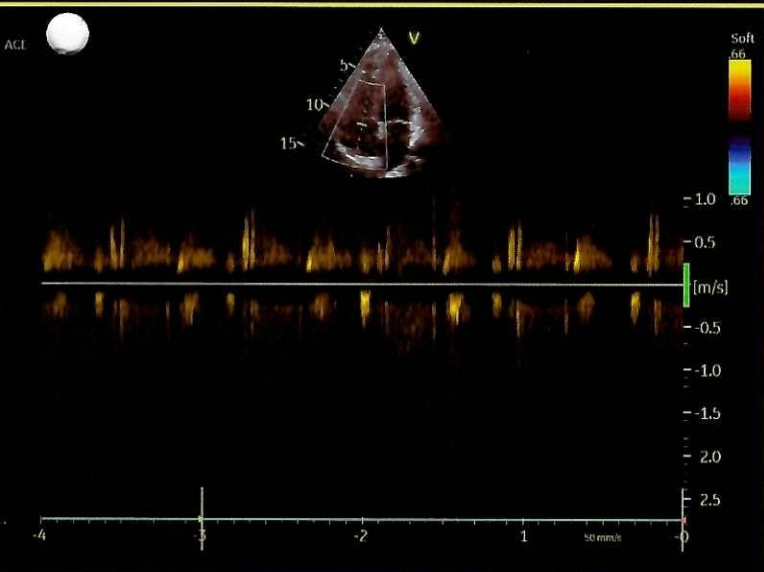
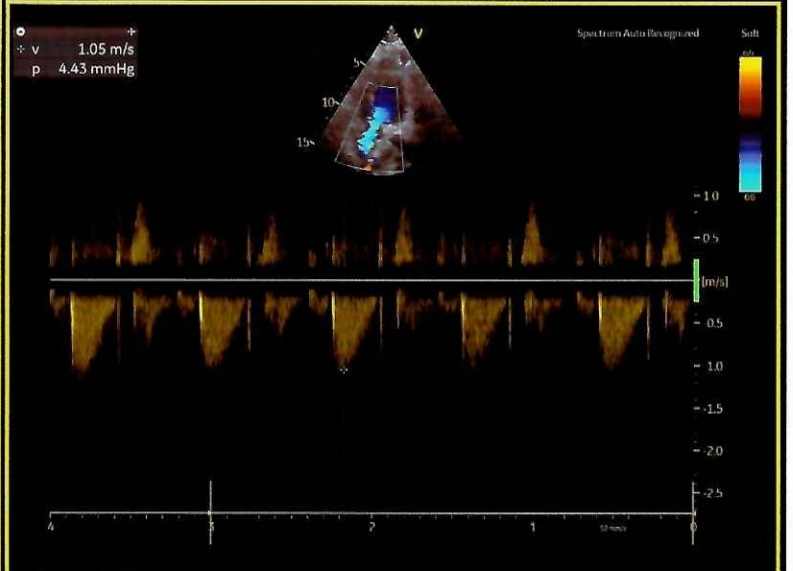
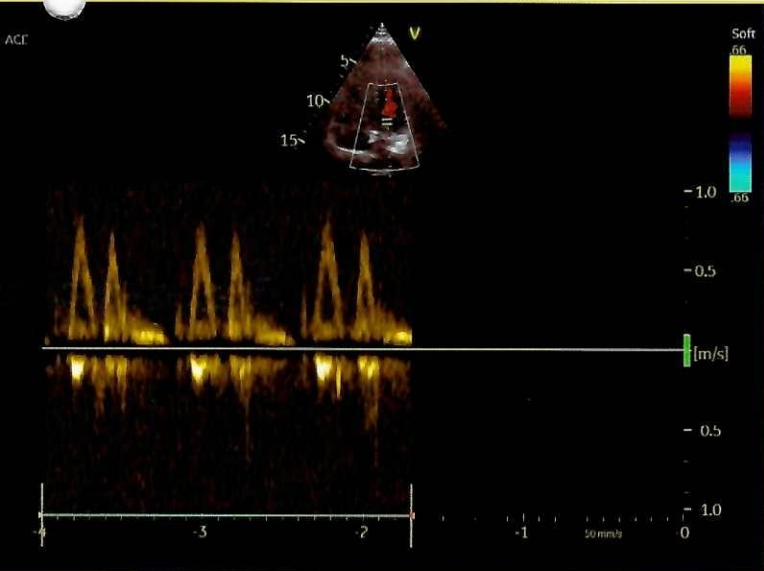
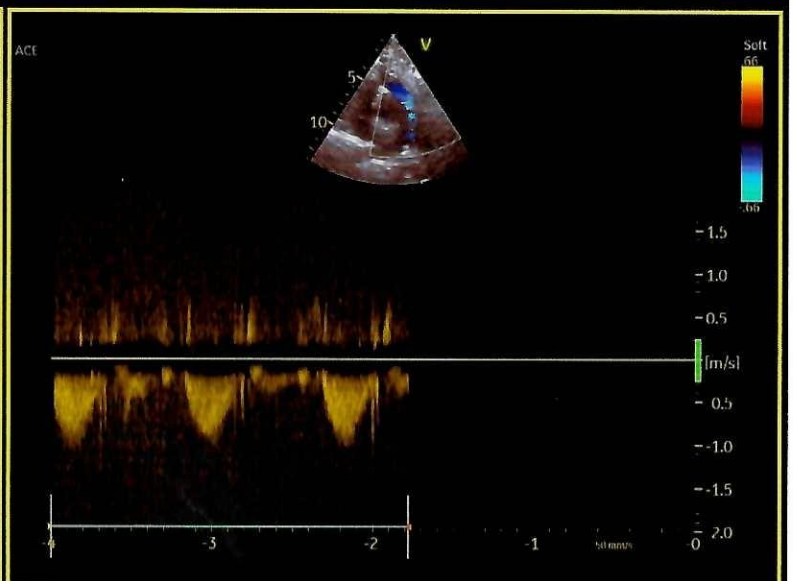
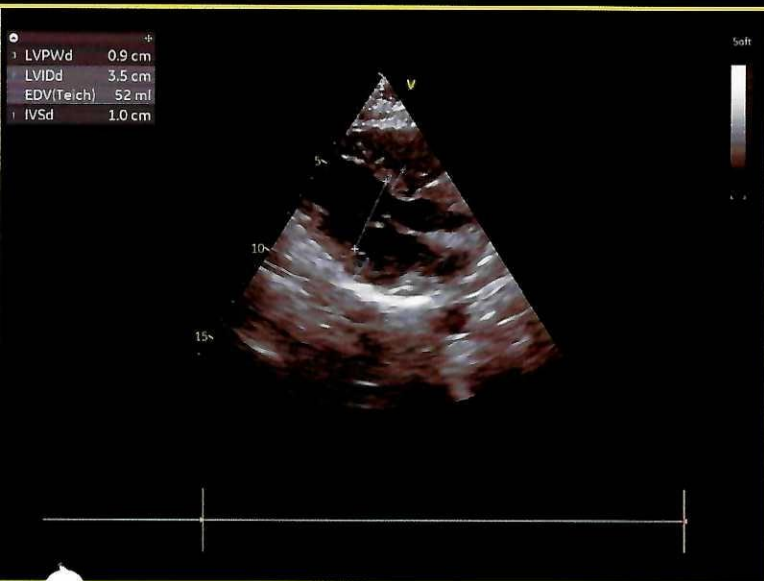

ECHOCARDIOGRAPHY REPORT

Patient's Name	Ankita Singh	Date	25/10/2024
Age/Sex	35Y/F	UHID	HC -54223
Referred By	Health Check	Done By	Dr.Gaurav Khandelwal

- Left Ventricle : Normal Left Ventricular Size, Wall Thickness & Function.*
- Left Ventricular Ejection Fraction is within Normal Limits (LVEF : 60%)*
- Left Atrium : Normal Left Atrial Size & Functions.*
- Right Ventricle : Normal Right Ventricular Size & Functions.*
- Right Atrium : Normal Right Atrial Size & Function.*
- Valvular Structures : Normal Mitral, Tricuspid, Pulmonic & Aortic Valve Structures.*
- Aortic Root is Normal.*
- No Evidence of Pericardial Effusion.*
- No LA / LV Clot*


DR. GAURAV KHANDELWAL
DM (Cardiology), FACC, FESC, FSCAI, FIC
INTERVENTIONAL CARDIOLOGIST



ULTRA SONOGRAPHY ABDOMEN

NAME	Mrs. Ankita Singh	UHID NUMBER:-	ASHB.0000054223	
REF. BY	ASH.	DATE	25-10-24	AGE/SEX:- 35y/F

Liver:- is normal in size and shows mild increase in hepatic parenchymal echotexture . Portal and hepatic venous system appears normal. Intra and extra hepatic biliary radicals are not dilated.

Gall Bladder:- is normal in size and shape. Its lumen is echofree.

Pancreas is normal in size outline and echopattern.

Spleen is normal in size and echopattern.

Both kidneys are normal in size, shape and echogenicity. Central pelvicalyceal sinus and corticomedullary ratio are normal.

Right kidney measures:- 11.2x2.7cm

Left kidney measures:- 9.1x4.2cm

No evidence of ascites is seen.

Urinary bladder is normal in shape and contour. Its wall is normal.

Uterus:- Uterus is retroverted and shows inhomogeneous echopattern. Cervix shows normal echopattern.

Uterus measures:- 6.5x3.5x5.4cm. Endometrial thickness is 5.5mm.

Ovaries:- Both ovaries are normal in size , follicular pattern and show normal stromal echotexture.

Right ovary measures 2.4x1.5cm.

Left ovary measures 2.6x1.4cm.

No adnexal mass.

No free fluid in POD.

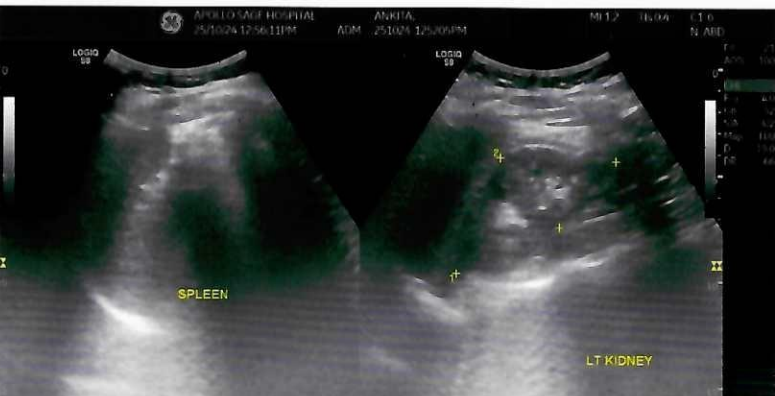
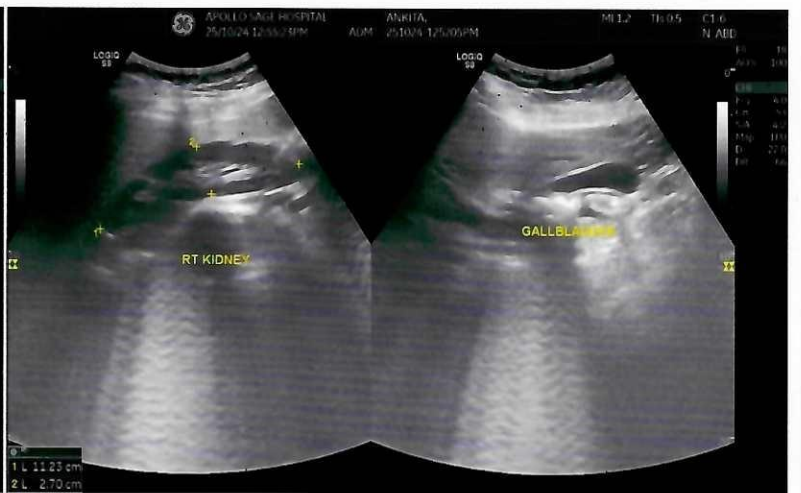
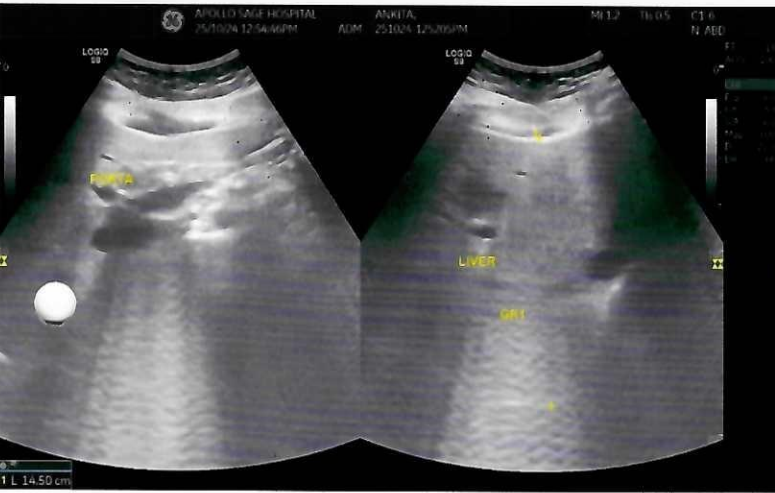
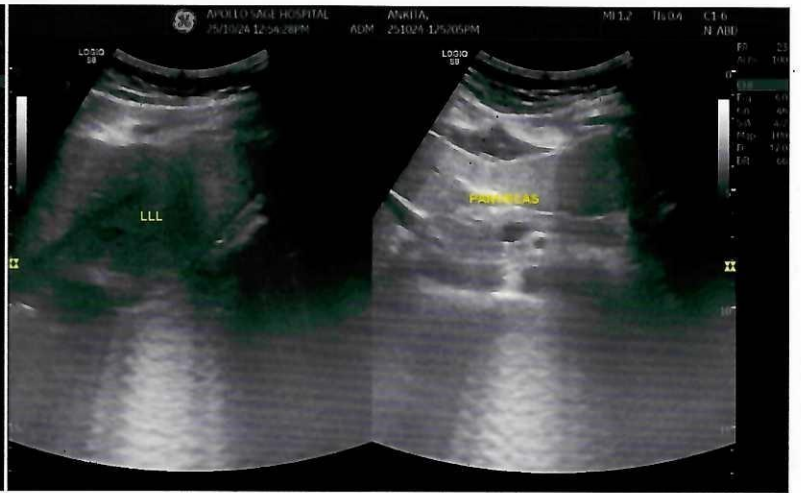
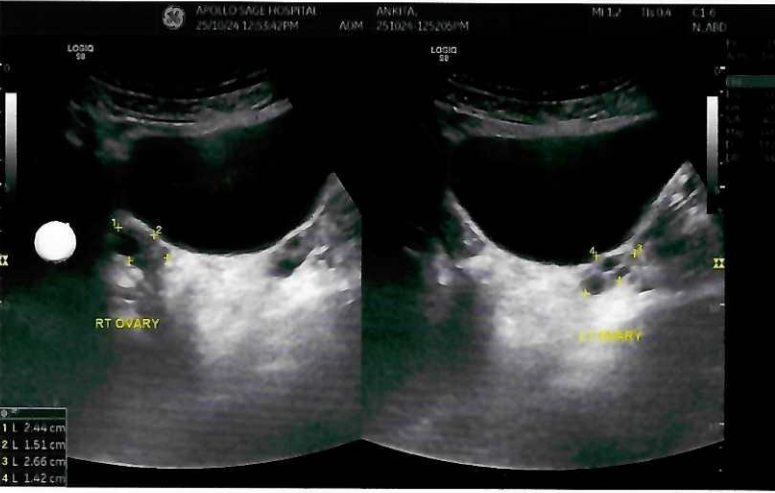
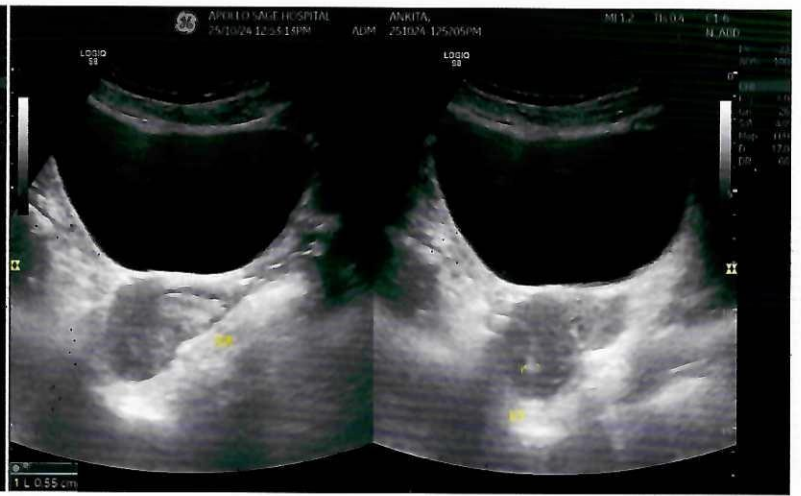
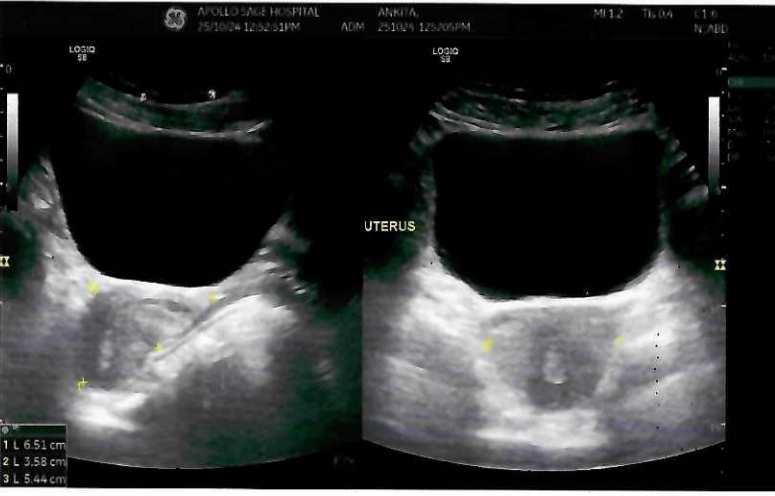
IMPRESSION:- Sonography Study Reveals:-

- **Grade-I fatty liver.**
- **No other significant abnormality detected.**

ADV:- Clinical Correlation.

(Signature)
DR. KRATI KHANDELWAL
CONSULTANT RADIOLOGIST





APOLLO SAGE HOSPITAL
BAWADIYAN KALAN
BHOPAL

Station
Telephone:

EXERCISE STRESS TEST REPORT

Patient Name: SINGH, ANKITA
Patient ID: OP-54223
Height: 154 cm
Weight: 63.2 kg

DOB: 26.01.1989
Age: 35 yrs
Gender: Female
Race: Indian

Study Date: 25.10.2024
Test Type: Treadmill Stress Test
Protocol: BRUCE

Referring Physician: --
Attending Physician: Dr. Akhileshwar Rathore
Technician: Radha Prajapati

Medications:
--

Medical History:
NONE

Reason for Exercise Test:
Screening for CAD

Exercise Test Summary

Phase Name	Stage Name	Time in Stage	Speed [km/h]	Grade [%]	HR [bpm]	BP [mmHg]	Comment
PRETEST	SUPINE	00:11	0.00	0.00	74	130/80	
	STANDING	00:11	0.00	0.00	76	130/80	
	HYPERV.	00:01	0.00	0.00	76	130/80	
	WARM-UP	00:51	1.60	0.00	103	130/80	
EXERCISE	STAGE 1	03:00	2.70	10.00	134	130/80	
	STAGE 2	03:00	4.00	12.00	164	140/80	
	STAGE 3	00:23	5.50	14.00	173	150/80	
RECOVERY		04:10	0.00	0.00	102	130/80	

The patient exercised according to the BRUCE for 6:23 min:s, achieving a work level of Max. METS: 8.10. The resting heart rate of 74 bpm, rose to a maximal heart rate of 173 bpm. This value represents 93 % of the maximal, age-predicted heart rate. The resting blood pressure of 130/80 mmHg, rose to a maximum blood pressure of 150/80 mmHg. The exercise test was stopped due to Target heart rate achieved.

Interpretation


Summary: Resting ECG: abnormal.
Functional Capacity: normal.
HR Response to Exercise: appropriate.
BP Response to Exercise: normal resting BP - appropriate response.
Chest Pain: none.
Arrhythmias: none.
ST Changes: Depression horizontal.
Overall impression: Positive stress test suggestive of ischemia.

Conclusions

-ST-T Changes Noted During Exercise & Recovery Stage
-Positive Stress Test

Physician

Technician



P/N 2009828-021

Vital Signs™

PRINTED IN U.S.A.