

**MEDICAL HEALTH CHECK- UP ASSESMENT FORM**

NAME : Mr / Mrs Shehnaaz Ansari

DATE:  
26/10/24

AGE : 43 yrs

SEX: Male / Female  
 Female

NMU: NMU000  
542410002276.

DOCTOR'S NAME:  
Health package -

TEMP :	<u>97.2</u>	° f	BP :	<u>114/75</u>	mmHg
PULSE :	<u>80</u>	b/m	HEIGHT :	<u>154</u>	cm
RR :	<u>20</u>	b/m	WEIGHT :	<u>51.6</u>	kg
SPO2 :	<u>99</u>	% RA	HGT:	<u>—</u>	

**REMARK:**



# MEDICOVER HOSPITALS

NAVI MUMBAI

## DEPARTMENT OF OPHTHALMOLOGY

DATE: 26/10/21

PATIENT NAME: Mrs Shehroz Ameen AGE / SEX: 43/F

UMR NO: 54241000278

	RE	LE
VA (DISTANCE)	6/6p	6/4.5
VA (NEAR)	N12	N12
COLOUR VISION	Normal	Normal

			SPHERE	CYLINDER	AXIS	VA	
MRx	O D	(R)	+1-	-0.50	90°	6/6	<u>+1.50</u> Nc
	O S	(L)	+1-	-0.50	45°	6/6	<u>+1.50</u> Nc

### HISTORY :

- no H/O spectacle
- no H/O DM or H/O thyroid
- no H/O Ocular pain or CBES

### OCULAR FINDINGS :

- Antseg. BRWC
- DM - BR field

### ADVICE:

1) eel Refresh tears 4-7 x (30) Day



Name : Mrs.SHEHNAZ KHURSHIDANSARI  
Bill No. : MCB54241007168

Age /Sex : 043Y Y(s)/FEMALE  
UMR No. : 542410002276

### LABORATORY REPORT : BIOCHEMISTRY

Parameters	Result	Reference Range	Units
<b>BUN(BLOOD UREA NITROGEN)</b>			
( Bill Date : 26-Oct-2024 09:01 AM	Result ID : RMI241023405)		
BUN (Blood Urea Nitrogen.) <i>Calculated</i>	8	7 - 21.0	mg/dL
<b>' .FT(LIVER FUNCTION TEST)</b>			
( Bill Date : 26-Oct-2024 09:01 AM	Result ID : RMI241023410)		
TOTAL BILIRUBIN <i>DIAZO</i>	0.3	<1.2	mg/dL
DIRECT BILIRUBIN <i>DIAZO</i>	0.1	<=0.20	mg/dL
INDIRECT BILIRUBIN <i>Calculated</i>	0.2	<=1.0	mg/dL
SGPT (ALT) <i>UV without P5P</i>	14	<=33	U/L
SGOT (AST) <i>UV without P5P</i>	20	<= 32	U/L
ALKALINE PHOSPHATASE (ALP) <i>PNPP, AMP Buffer - IFCC Ref.</i>	59	35 - 105	U/L
TOTAL PROTEINS <i>Biuret method</i>	7.7	6.0 - 8.0 g/dL	g/dL
SERUM ALBUMIN <i>Bromcresol Green (BCG)</i>	4.4	3.5 - 5.2 g/dL	g/dL
GLOBULINS <i>Calculated</i>	3.3	2.5 - 3.5 g/dL	g/dL
A/G RATIO <i>Calculation</i>	1.33	1.2 - 2.5	
GAMMA GLUTAMYL TRANSFERASE(GGT) <i>G-glutamyl-carboxy-nitroanilide-IFCC</i>	32	6-42	U/L
<b>T3,T4 AND TSH</b>			
( Bill Date : 26-Oct-2024 09:01 AM	Result ID : RMI241023416)		
T3 <i>ECLIA</i>	90.12	70 - 204	ng/dL

<b>Name</b>	: Mrs.SHEHNAZ KHURSHIDANSARI	<b>Age /Sex</b>	: 043Y Y(s)/FEMALE
<b>Bill No.</b>	: MCB54241007168	<b>UMR No.</b>	: 542410002276

T4 5.13 5.1 - 14.1 ug/dL  
ECLIA


TSH(THYROID STIMULATING HORMONE) 3.01 0.270 - 4.20 uIU/mL  
ECLIA

**PLBS (POST LUNCH BLOOD SUGAR WITH URINE SUGAR)**

( Bill Date : 26-Oct-2024 09:01 AM Result ID : RMI241023885)

PLBS (POST LUNCH BLOOD GLUCOSE) 83

URINE SUGAR NIL

  
**DR. MEHROTRA VISHAL**  
 MD PATHOLOGY

Name : Mrs.SHEHNAZ KHURSHIDANSARI  
Bill No. : MCB54241007168

Age /Sex : 043Y Y(s)/FEMALE  
UMR No. : 542410002276

### LABORATORY REPORT : BIOCHEMISTRY

Parameters	Result	Reference Range	Units
<b>HBA1C (GLYCOSYLATED HAEMOGLOBIN)</b>			
( Bill Date : 26-Oct-2024 09:01 AM Result ID : RMI241023404)			
HBA1C <i>HPLC</i>	5.7	" Normal : < 5.7% Pre diabetic : 5.7 % - 6.5 % Diabetic : > 6.5 %	
<b>SERUM URIC ACID</b>			
( Bill Date : 26-Oct-2024 09:01 AM Result ID : RMI241023409)			
SERUM URIC ACID <i>uricase</i>	3.4	2.4-5.7	mg/dL
<b>BUN / CREATININE RATIO</b>			
( Bill Date : 26-Oct-2024 09:01 AM Result ID : RMI241023411)			
BUN / CREATININE RATIO <i>CALCULATED</i>	13.79	10-20	
<b>SERUM CREATININE</b>			
( Bill Date : 26-Oct-2024 09:01 AM Result ID : RMI241023412)			
CREATININE <i>Jaffe</i>	0.58 *	0.6 - 1.2	mg/dL
<b>LIPID PROFILE</b>			
( Bill Date : 26-Oct-2024 09:01 AM Result ID : RMI241023413)			
TOTAL CHOLESTEROL <i>Enzymatic colorimetric</i>	189	Desirable :: < 200 mg/dL Borderline High :: 200 - 239 mg/dL High risk : > 240 mg/dL	mg/dL
HDL CHOLESTEROL <i>Homogeneous enzymatic colorimetric</i>	43	Low :: < 40 mg/dL High :: > 60 mg/dL	mg/dL
LDL CHOLESTEROL <i>Direct-Enzymatic colorimetric</i>	131 *	Very High : - > 190 mg/dL Optimal : - < 100 mg/dL Near Optimal : 100 - 129 mg/dL High : 160 - 189 mg/dL Borderline High:130-159 mg/dl	mg/dL
VLDL <i>Calculation</i>	20	2 - 30 mg/dL	mg/dL

Name : Mrs.SHEHNAZ KHURSHIDANSARI  
Bill No. : MCB54241007168

Age /Sex : 043Y Y(s)/FEMALE  
UMR No. : 542410002276

SERUM TRYGLYCERIDES 101  
*Enzymatic colorimetric*

< 150 mg/dL mg/dL  
Borderline High : 150 - 199 mg/dL  
High : 200 - 499 mg/dL

CHO/HDL RATIO 4.4 \*  
*Calculation*

Normal : - < 3.5  
High Risk : - > 5.0

LDL/HDL RATIO 3.05


**FBS (FASTING BLOOD GLUCOSE WITH URINE GLUCOSE)**

Bill Date : 26-Oct-2024 09:01 AM Result ID : RMI241023415)

FASTING BLOOD GLUCOSE 91  
*Hexokinase*

Normal Range : 70 - 99 mg/dL  
Impaired Glucose tolerance : 100 -125  
Diabetes Mellitus : >=126

FASTING URINE GLUCOSE NIL

  
DR. MEHROTRA VISHAL  
MD Pathology


<b>Name</b>	: Mrs.SHEHNAZ KHURSHIDANSARI	<b>Age /Sex</b>	: 043Y Y(s)/FEMALE
<b>Bill No.</b>	: MCB54241007168	<b>UMR No.</b>	: 542410002276

**LABORATORY REPORT : BLOOD BANK**

Parameters	Result	Reference Range	Units
<b>BLOOD GROUPING AND RH</b>			
( Bill Date : 26-Oct-2024 09:01 AM		Result ID : RMI241023414)	
BLOOD GROUP <i>Automated microcolumn gel method</i>	O		
RH TYPE	POSITIVE		

**INTERPRETATION**

1. If Rh is Du positive it is best considered as Rh negative as recipient and Rh positive as donor. Proper Cross matching is recommended before transfusion.
2. In case of forward and reverse grouping discrepancy, clinical correlation and repeat sample analysis is recommended.
3. For Infants below 6 months only forward grouping is performed.
4. A sub-grouping is recommended after the age of 6 months.

  
**DR. MEHROTRA VISHAL**  
 MD PATHOLOGY

Name : Mrs.SHEHNAZ KHURSHIDANSARI  
Bill No. : MCB54241007168

Age /Sex : 043Y Y(s)/FEMALE  
UMR No. : 542410002276

### LABORATORY REPORT : CLINICAL PATHOLOGY

Parameters	Result	Reference Range	Units
<b>CUE(COMPLETE URINE EXAMINATION)</b>			
( Bill Date : 26-Oct-2024 09:01 AM Result ID : RMI241023408)			
<b><u>PHYSICAL EXAMINATION</u></b>			
VOLUME	20 ML		ml
COLOUR	PALE YELLOW	PALE YELLOW	
APPEARANCE	CLEAR	CLEAR	
<b><u>CHEMICAL EXAMINATION</u></b>			
DEPOSIT	ABSENT	ANSENT	
SPECIFIC GRAVITY <i>Bromthymol blue</i>	1.015	1.000 - 1.030	
PH <i>Bromthymol blue</i>	5.0	5.0 - 8.0	
PROTEIN <i>Tetra-bromophenol blue/Heat coagulation test</i>	NIL	NIL (<15 mg/dL)	
GLUCOSE <i>Glucose oxidase Peroxidase/Benedict?s test</i>	NIL	NIL (<25 mg/dL)	
UROBILINOGEN <i>Diazonium salt</i>	NIL	NIL	
KETONE <i>Sodium nitroprusside/Rothera?s test.</i>	NIL	NIL (<5 mg/dL)	
BILIRUBIN <i>Dipstick/Fouchets test</i>	NIL	NEGATIVE	
BILE SALT <i>Hays sulphur powder</i>	NIL	NEGATIVE	
BILE PIGMENT <i>Fouchet test</i>	NIL	NEGATIVE	
NITRITE <i>Sulfanilic acid</i>	NIL	NEGATIVE	




<b>Name</b>	: Mrs.SHEHNAZ KHURSHIDANSARI	<b>Age /Sex</b>	: 043Y Y(s)/FEMALE
<b>Bill No.</b>	: MCB54241007168	<b>UMR No.</b>	: 542410002276

LEUCOCYTE ESTERASE	NIL	NEGATIVE	
<b><u>MICROSCOPIC EXAMINATION</u></b>			
PUS CELLS	1-2	0 - 5 /hpf	
EPITHELIAL CELLS	1-2	0 - 5	hpf
RBC	NIL	0 - 5 /hpf	
CAST	NIL	NIL	
<i>Microscopy examination</i>			
CRYSTALS	NIL	NIL	
BACTERIA	NIL		
<i>Microscopic examination</i>			
YEAST	NIL		
<i>Microscopic examination</i>			
AMORPHOUS DEPOSITS	NIL		
<i>Microscopic examination</i>			
MUCUS THREAD	NIL		
<i>Microscopic examination</i>			

**NOTE**

Microscopic examination of urine is carried out on centrifuged urinary sediment.



Dr Neeta Shrivastava  
MBBS, MD, DNB ( Microbiology)

Name : Mrs.SHEHNAZ KHURSHIDANSARI  
Bill No. : MCB54241007168

Age /Sex : 043Y Y(s)/FEMALE  
UMR No. : 542410002276

### LABORATORY REPORT : HAEMATOLOGY

Parameters	Result	Reference Range	Units
<b>CBP(COMPLETE BLOOD PICTURE)</b>			
( Bill Date : 26-Oct-2024 09:01 AM Result ID : RMI241023406)			
R B C COUNT <i>Electrical Impedance</i>	4.64	3.8-4.8	10 <sup>12</sup> /L
HEMOGLOBIN <i>Photometric</i>	11.7 *	12.0 - 15.0	gms/dL
PCV/HCT <i>Calculated</i>	35.6 *	36 - 46	%
MCV <i>Calculated</i>	76.8 *	83 - 101	fl
MCH <i>Calculated</i>	25.2 *	27 - 32	pg
MCHC <i>Calculated</i>	32.8	31.5 - 34.5	g/dL
RDW(cv)	13.6	11.6 - 14.0 %	%
TLC (TOTAL LEUCOCYTE COUNT) <i>Impedance</i>	6.74	4.0 - 10.0	10 <sup>3</sup> /μL
<b><u>DIFFERENTIAL COUNT</u></b>			
NEUTROPHILS <i>DHSS/Microscopy</i>	51	40 - 80 %	
LYMPHOCYTES <i>DHSS/Microscopy</i>	36	20 - 40 %	
MONOCYTES <i>DHSS/Microscopy</i>	07	02 - 10 %	
EOSINOPHILS <i>DHSS/Microscopy</i>	06	00 - 06 %	
BASOPHILS <i>DHSS/Microscopy</i>	00	00 - 01 %	
PLATELET COUNT <i>Electrical Impedance</i>	348	150 - 400 10 <sup>3</sup> /μL	10 <sup>3</sup> /μL

Name : Mrs.SHEHNAZ KHURSHIDANSARI  
Bill No. : MCB54241007168

Age /Sex : 043Y Y(s)/FEMALE  
UMR No. : 542410002276

**ESR**

( Bill Date : 26-Oct-2024 09:01 AM Result ID : RMI241023407)

ESR  
MODIFIED WESTERGREN'S METHOD

15

0 - 20

mm/1st hour

  
DR. MEHROTRA VISHAL  
MD Pathology

<b>Patient ID:</b>	<b>542410002276</b>	<b>Patient Name:</b>	<b>SHEHNAZ KHURSHID ANSARI</b>
<b>Age:</b>	<b>43YRS</b>	<b>Sex:</b>	<b>F</b>
<b>Accession Number:</b>		<b>Modality:</b>	<b>US</b>
<b>Referring Physician:</b>	<b>DMO</b>	<b>Study:</b>	<b>USG ABDOMEN AND PELVIS</b>
<b>Study Date:</b>	<b>26-Oct-2024</b>		

### ULTRASOUND EXAMINATION OF ABDOMEN & PELVIS

The Liver is normal in size (13.2 cm) and shows a normal parenchymal reflectivity. No focal lesion is seen. The Hepatic veins appear normal. There is no evidence of any dilated IHBR. The portal vein appears normal.

The gall bladder is physiologically distended with normal wall thickness. There is no evidence of gallstones. ^ B.D. is of normal caliber.

The Pancreas is normal in size and shows homogeneous reflectivity. There is no evidence of any calcification or ductal dilatation.

The spleen is normal in size and shows a homogeneous echotexture. It measures 7.8 cm in long axis. There is no evidence of any focal lesion.

Both kidneys are normal in position and size. They show normal cortical reflectivity and cortico-medullary distinction.

The Right Kidney measures 9.7 x 3.8 cm. Tiny 3 mm echogenic focus noted in lower polar calyx of right kidney- calculus / concretion.

The Left Kidney measures 8.9 x 4.7 cm.

There is no evidence of hydronephrosis or mass noted.

There is no evidence of ascites.

The Urinary bladder is adequately distended and shows normal wall thickness. No evidence of any intraluminal mass or calculi.

The uterus is Anteverted. It measures 9.4 x 5.2 x 4.2 cm.

The uterine myometrial echotexture is homogeneous. Small oval hypoechoic subserosal fibroid is seen in anterior wall of uterus measuring approximately 2.3 x 1.3 cm.

The Endometrial thickness is 9.2 mm.

Both ovaries are well visualized and appear normal in size and reflectivity.

The Right ovary measures 2.3 x 1.6 cm.

The Left ovary measures 2.6 x 1.7 cm.

There is no evidence of any ovarian or adnexal mass lesion.

No evidence of any fluid collection in the pelvis.

<b>Patient ID:</b>	542410002276	<b>Patient Name:</b>	SHEHNAZ KHURSHID ANSARI
<b>Age:</b>	43YRS	<b>Sex:</b>	F
<b>Accession Number:</b>		<b>Modality:</b>	US
<b>Referring Physician:</b>	DMO	<b>Study:</b>	USG ABDOMEN AND PELVIS
<b>Study Date:</b>	26-Oct-2024		

**IMPRESSION:**

**Tiny right renal concretion.  
Subserosal uterine fibroid.**



**Dr. Garima Shailendra Sharma**  
MBBS, M.D. (Radio Diagnosis),  
DNB, FRCR  
Consultant Radiologist

Date: 26-Oct-2024 12:18:16

<b>Patient ID:</b>	10002276	<b>Patient Name:</b>	SHEHNAZ KHURSHID ANSARI 43YRS/F
<b>Age:</b>		<b>Sex:</b>	O
<b>Accession Number:</b>		<b>Modality:</b>	CR
<b>Referring Physician:</b>		<b>Study:</b>	BREAST
<b>Study Date:</b>	26-Oct-2024		

### X-RAY MAMMOGRAPHY

**INDICATION:** Routine screening.

### MAMMOGRAPHY

Bilateral mammograms were obtained in the oblique mediolateral and craniocaudad projections.

The film markers are placed on the axillary / lateral part of the breast.

Both breasts display scattered areas of fibroglandular densities.

There is no focal spiculated mass lesion seen.

There are no clusters of microcalcification, distortion of the lobular architecture or nipple retraction.

Skin and subcutaneous tissues are normal.

### IMPRESSION :-

**No significant abnormality is seen.**

### **BIRADS Category I (Negative)**

**Suggest a routine screening mammography after one year.**

*(BIRADS CATEGORY : BIRADS O - Requires additional evaluation, I - Negative, II - Benign findings, III - Probably benign findings, IV - Suspicious abnormality, V - Highly suggestive of malignancy, VI - Known biopsy proven malignancy.)*



**Dr. Garima Shailendra Sharma**  
MBBS, M.D. (Radio Diagnosis),  
DNB, FRCR  
Consultant Radiologist

Date: 26-Oct-2024 14:38:03

NM00002276  
43 Years

SHEHNAZ ANSARI  
Female

10/26/2024 12:48:44 PM

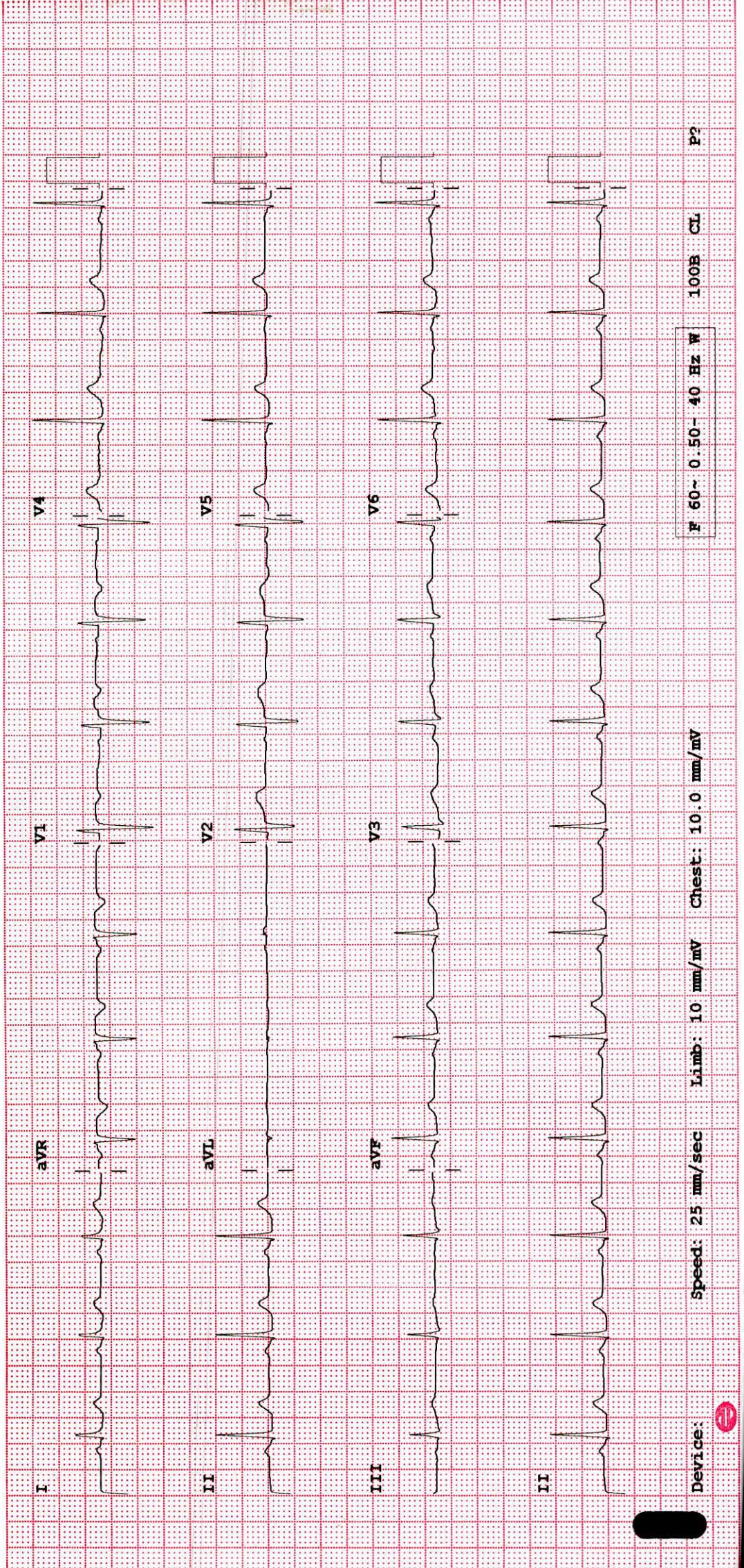
Rate 77 . Sinus rhythm.....normal P axis, V-rate 50- 99

PR 140  
QRS 78  
QT 362  
QTc 410  
--AXIS--  
P 44  
QRS 56  
T 48

12 Lead; Standard Placement

- NORMAL ECG -

Unconfirmed Diagnosis



Device: Speed: 25 mm/sec Limb: 10 mm/mV Chest: 10.0 mm/mV

F 60~ 0.50~ 40 Hz W

100B CL P?

<b>Patient ID:</b>	542410002276	<b>Patient Name:</b>	SHEHNAZ ANSARI
<b>Age:</b>	43 Years	<b>Sex:</b>	F
<b>Accession Number:</b>		<b>Modality:</b>	DX
<b>Referring Physician:</b>		<b>Study:</b>	CHEST
<b>Study Date:</b>	26-Oct-2024		

**X RAY CHEST PA VIEW**

Both lungs are clear.

The frontal cardiac dimensions are normal.

The pleural spaces are clear.


Both hilar shadows are normal in position and density.

No diaphragmatic abnormality is seen.

The soft tissues and bony thorax are normal.

**IMPRESSION:**

- No significant abnormality is seen.



**DR. SUYOG SANGALE**  
**MBBS DMRE**  
**CONSULTANT RADIOLOGIST**

Date: 26-Oct-2024 10:59:10



## 2 D Transthoracic Echocardiography and Color Doppler

NAME	UMR No	REF. BY
MRS. SHEHNAZ ANSARI	2276	HEALTH CHECKUP

DATE	AGE	SEX
26/10/2024	43 YRS.	FEMALE

### ECHO FINDINGS :

No RWMA.

LVEF is 60%.

No LV Diastolic Dysfunction.

Trivial mitral regurgitation.

No aortic regurgitation. No aortic stenosis.

Mild tricuspid regurgitation. No pulmonary hypertension.  
PASP = 30 mm Hg.

IAS & IVS Are Intact.

No Thrombus/ Vegetation/pericardial effusion.

Normal RV systolic function. No hepatic congestion.



**DR ANUP V MAHAJANI**

MBBS, MD (MED), DNB (CARDIOLOGY)

INTERVENTIONAL CARDIOLOGIST

REG NO 2013/05/1759



**MEDICOVER**  
**HOSPITALS**

NAVI MUMBAI

**M-MODE MEASUREMENTS (in Cm)**

LA	3.5
AORTA	2.9
LVID (d)	3.2
LVID (s)	4.3
IVS (d)	1.1
PW (d)	1.0
LVEF %	60

**COLOUR DOPPLER**

Mitral Velocity	AJV	PJV	MS	MR	AS	AR	TR
E < A	1.6	0.5	Nil	Trivial	Nil	Nil	Mild

-----END OF THE REPORT-----

**DR ANUP V MAHAJANI**

**MBBS, MD (MED), DNB (CARDIOLOGY)**

**INTERVENTIONAL CARDIOLOGIST**

**REG NO 2013/05/1759**

