



 भारत सरकार
 Government of India


 आधार

Issue Date: 28/02/2011


 जोगेश चावला
 Jogesh Chawla
 जन्म तिथि / DOB : 24/03/1968
 पुरुष / Male

आधार पहचान का प्रमाण है, नागरिकता का नहीं।
 Aadhaar is a proof of identity, not of citizenship.



3608 6021 7711
 मेरा आधार, मेरी पहचान

Chawla


 भारतीय विशिष्ट पहचान प्राधिकरण
 Unique Identification Authority of India


 आधार

पता: द्वारा: बंसी लाल चावला, डी-124, पहला
 मंजूर, रामप्रस्था कॉलोनी, डीएमपीएस जूनियर
 विद्यालय के सामने, चंदर नगर, गाजियाबाद,
 उत्तर प्रदेश, 201011
 Address: C/O: Bansi Lal Chawla, D-124, 1st
 Floor, Ramprastha Colony, Opposite DMPS
 Junior School, Chander Nagar, Ghaziabad,
 Uttar Pradesh, 201011

File Date: 21/09/2023



3608 6021 7711

 1947
  help@uidai.gov.in
 www.uidai.gov.in

MALIK RADIX HEALTH CARE PVT. LTD.
 C-217, C-218, Nirman Vihar,
 Delhi-110092
 Ph.: 011-49287456, 011-61381379
 Regd. No. 607



Mr. Jogesh Chawla
Age - 55yrs / Male

(Pre-insurance)

20/03/24

Visual $\left\{ \begin{array}{l} 6/9 \\ 6/9 \end{array} \right.$ ~~2/3~~ ~~2/3~~ Mean $\left\{ \begin{array}{l} NS \\ NS \end{array} \right.$

Log 13'
14'

Colour : $\left\{ \begin{array}{l} L \\ N \\ R \end{array} \right.$ (BS)

No other pathology

Dr. Nidhi Gupta
MBBS, MS, DNB
Casualty Ophthalmologist
Malik Radix Healthcare Pvt. Ltd.
DMC No. 121661

Facilities Available

- Multispeciality Hospital - 24 Hours Emergency - X-Ray/ ECG/ Ultrasound/ CT Scan - Dental- Fully Equipped Operation Theatre
- Fully Functional Lab - 24/7 Casualty/ ICU-Nursery 24/7 Pharmacy - Labour Room - All Speciality OPD - Laproscopic Surgery - ECHO - Plastic Surgery



RADIX COSMO DENTAL

(UNIT OF MALIK RADIX HEALTHCARE PVT. LTD.)
C-216, 217, 218, Nirman Vihar, Vikas Marg, Delhi - 110092
Ph. : 011-22508272, 22520249 • M. : 9999254639
E-mail : radixhealthcare@yahoo.co.in • www.radixhealthcare.org



CONSULTANTS ON PANEL

PAEDIATRICS

Dr Ravi Malik (MBBS, MD)
Dr Harit Prasad (MBBS, MD, Pdf)
Dr Ritu Jain (MBBS, MD)

GYNAECOLOGY

Dr Renu Malik (MBBS, MD)
Dr Meena Malhotra (MBBS, MD)
Dr Rajni (MBBS, MD)
Dr Manju Gupta (MBBS, MS)
Dr Vaishali Saini (MBBS, DGO)
Dr Rupam Arora (MBBS, MD)

DENTAL

Dr Shruti Malik (BDS, MDS)
Dr Annu Saini (BDS, MDS)
Dr Rachit Thukral (BDS, MDS)
Dr Mohit Mangla (BDS, MDS)
Dr Tarun Mittal (BDS, MDS)
Dr Geetika Sharma (BDS)
Dr Shilpa Verma (BDS)

CHILD GASTROENTEROLOGY

Dr S. K Mittal (MBBS, MD)

MEDICINE

Dr A S Talwar (MBBS, MD)
Dr Sunny Uppal (MBBS, MD)
Dr Surendra Rajpal (MBBS, MD)

RESPIRATORY MEDICINE /PULMONOLOGY

Dr Abhinav Bhanot (MBBS, DNB)

LAPAROSCOPY SURGERY

Dr Ajay Jain (MBBS, MS)
Dr Deepak Saran (MBBS, MS)
Dr Pradeep Saini (MBBS, MS)
Dr G. S Garg (MBBS, MS)

ORTHOPAEDICS

Dr Vikas Bhardwaj (MBBS, MS ORTHO, DNB)
Dr Prabhat Aggarwal (MBBS, MS ORTHO)
Dr KB Tiwari (MBBS, MS ORTHO)
Dr Deepak Kumar Arora (MBBS, MS ORTHO)

EYE/OPTHALMOLOGY

Dr Nidhi Gupta (MBBS, MS, DNB, PGDM)
Dr Himanshu Singh Pundir (MBBS, MS)

ENT

Dr Sharad Kumar Singhi (MBBS, MS)
Dr Prateek Sharma (MBBS, MS)
Dr Ashok Singh (MBBS, MS)
Dr A K Lahiri (MBBS, MS)

RADIOLOGY(ULTRASOUND)

Dr K K Sinha (MBBS DNRB)
Dr T K Vohra (MBBS, MD)
Dr Rajesh Malhotra (MBBS, MD)
Dr Ashish Tomar (MBBS, MD)

PATHOLOGY

Dr Reema Dahiya (MBBS, MD PATH)
Dr Meenu Aggarwal (MBBS, MD PATH)

ANAESTHESIA

Dr Rajesh Dhall (MBBS, MD)
Dr Rakesh Atrey (MBBS, MD)
Dr R K Arora (MBBS, MD)
Dr Swaraj Garg (MBBS, MD)

DERMATOLOGY

Dr Niharika Jha (MBBS, MD)

PLASTIC & COSMETIC SURGERY

Dr Ayush Jain (MBBS, MS, MCh)

PAEDIATRIC SURGERY

Dr Dharmendra Singh (MBBS, MS, M.Ch)
Dr Satish Aggarwal (MBBS, MS, M.Ch)

PAEDIATRIC NEPHROLOGY

Dr A S Vasudev (MD, Dip.in. Paed.)

NEPHROLOGY

Dr Javed (MBBS, MD, Nephro)

CARDIOLOGY

Dr Nishant Tyagi (MBBS, MD)

NEUROLOGY

Dr Amit Batra (MBBS, MD)

GASTROENTEROLOGY

Dr Deepak Lahoti (MBBS, MD)
Dr Naresh Aggarwal (MBBS, MD)
Dr Ashok Goyal (MBBS, MD)
Dr Ankur Singhal (MBBS, MD)

UROLOGY

Dr Nikhil Sharma (MBBS, Mch)
Dr Ankur Singhal (MBBS, MD)

PSYCHIATRY

Dr Mohit Sharma (MBBS, MD)

PHYSIOTHERAPY

Dr Karti Dwivedi

Dr Ravi Kumar

NUTRITIONIST

Dr Deepika Kohli

Dr Sakshi Rana

CLINICAL PSYCHOLOGIST

Dr. Sarika Singh

Dr. Shruti Malik

BDS, MDS (Endodontics)

+91-9899561092

Name : Jogesh Chawla

Age/Sex : 55y / M

Date : 20/3/24

Timings : 10:00 am. to 2:00 pm.
6:00 pm. to 8:30 pm.

For Appointment

011-45152510
+91-9999254639

CLINICAL EXAMINATION:-

1. TMJ:-

Routine checkup

2. DENTAL STATUS:

M.H. - on medications

- a. Caries Teeth :
- b. Fracture Teeth :
- c. Root Stumps :
- d. Gingivitis :
- e. Periodontitis :
- f. Impacted Teeth :
- g. Malaligned Teeth :

for Parkinson's disease.

0/E

Stains +

Calculus ++

Cervical Abrasion

4

3. ORAL LESIONS:-

AW - OPG

4. DIAGNOSIS:-

Rp
- Hexidine Mouthwash - BD
3 months.

5. TREATMENT PLANNING:

6. FOLLOW UP:-

Referral To Other Consultant: Yes/ No N/A - 27/3/27 at 10:30am
If Yes, please mention the Name:

Doctor's Signature [Signature]

Facilities Available :

- ★ MULTI-SPECIALITY HOSPITAL ★ MODULAR FULLY EQUIPPED OT ★ NURSERY ★ LAPROSCOPIC SURGERY
- ★ 24X7 EMERGENCY ★ OPG ★ DENTAL ★ 24X7 DIAGNOSTICS ★ LABOUR ROOM ★ ECHO ★ EEG ★ DIGITAL X-RAY ★ CT SCAN
- ★ ECG ★ ULTRASOUND ★ RICU/ICU ★ ALL SPECIALITY OPD ★ PLASTIC & COSMETIC SURGERY ★ DIALYSIS ★ PHARMACY

Jogesh Chawla

ID: 8699040368

55 years Male

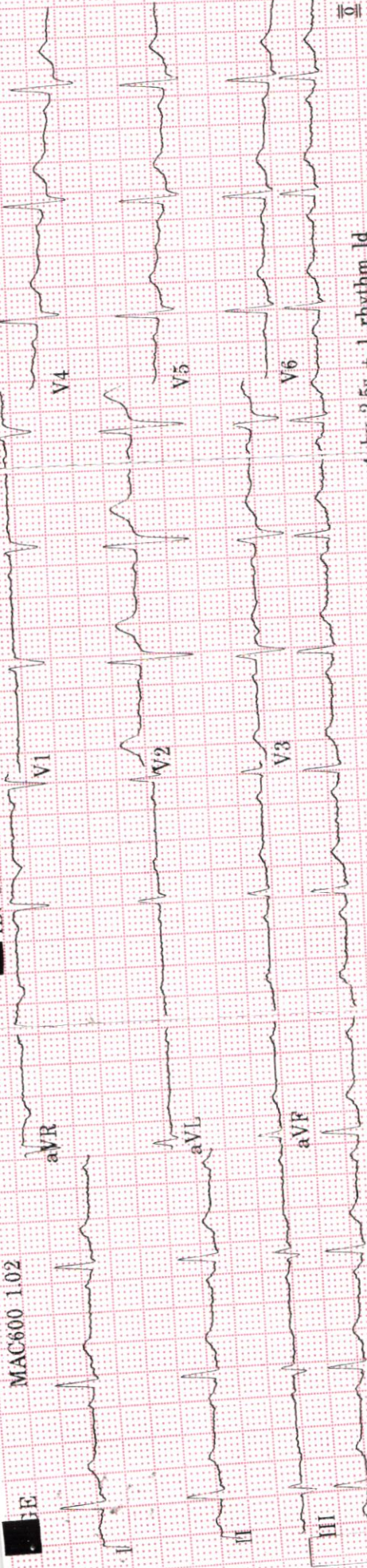
Vent. rate 78 bpm
 QRS duration 88 ms
 QT/QTc 374/426 ms
 PR interval 160 ms
 P duration 90 ms
 RR interval 769 ms
 P-R-T axes 42 37 36

12SL™ v239

MAC600 1.02

0-Mar-2024 9:23:37

ID: 8699040368



MAC600 1.02

4 by 2.5s + 1 rhythm ld

78 bpm

50Hz

10.0 mm/mV

25.0 mm/s

0.16-20Hz

Chawla

Malik Radix HealthCare.

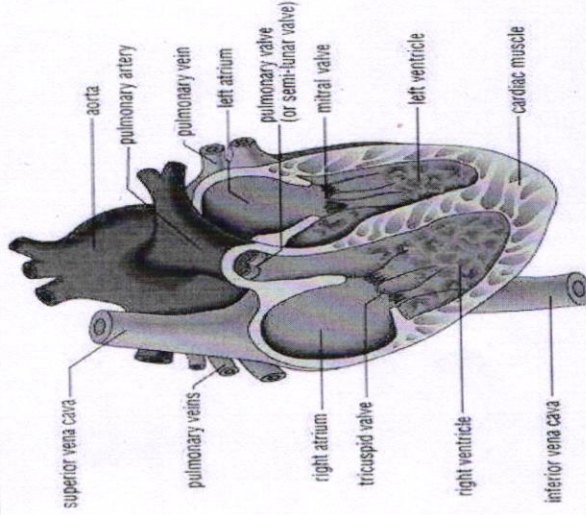
ELECTROCARDIOGRAM

Name: MR. JOGESH CHAWLA

Age & Sex: 55 YR/ MALE

Ref By: MEDIWHEEL

Date: 20/03/2024



ECG FINDINGS:

Rate 78 bpm Rhythm Sinus Mechanism Normal

Axis Normal P Wave Normal PR Interval 0.16/Sec

QRS Complex Normal QT Interval Normal Q Wave Normal

ST Segment Normal T Wave Normal

Conclusion Sinus Rhythm, Normal Axis, WNL.

Doctors Signature Dr. SHEIKH NAZIR AHMED
M.D. "Physician"
PGDCC
DMC-46499



Echocardiogram Report

Patient Name	MR. JOGESH CHAWLA
Date of Test	20/03/2024
Age	55 YRS/ MALE
Ref. by	MEDIWHEEL

Dimensions	Result	Normal Range
AO (ed)	2.9 cm	(2.1 -3.7cm)
LA (es)	3.3 cm	(2.1 -3.7cm)
RVID (ed)	2.0 cm	(1.1-3.0cm)
LVID (ed)	4.2 cm	(3.6 – 5.5 cm)
LVID (es)	3.0 cm	(2.3-3.9cm)
IVS (ed)	1.1 cm	(0.6 – 1-2 cm)
LVPW (ed)	1.1 cm	(0.6 – 1-2 cm)
EF	56 %	
FS	29 %	(28 % - 42 %)

Impression:

- NO REGIONAL WALL MOTION ABNORMALITY SEEN.
- LVEF= 56 %
- NORMAL CHAMBER DIMENSIONS.
- STAGE I LV DIASTOLIC DYSFUCTION.
- NORMAL COLOR FLOW.
- NO INTRA CARDIAC CLOT/MASS/ VEGETATION/PERICARDIAL EFFUSION SEEN.

Dr. Sheikh Nazir Ahmed
 M.D. "Physician" PGDCC
 (Consultant Non – Invasive Cardiologist)

Facilities Available

- Multispeciality Hospital - 24 Hours Emergency - X-Ray/ ECG/ Ultrasound/ CT Scan - Dental- Fully Equipped Operation Theatre
 - Fully Functional Lab - 24/7 Casualty/ ICU-Nursery 24/7 Pharmacy - Labour Room - All Speciality OPD - Laproscopic Surgery -
 ECHO - Plastic Surgery



LAB REPORT

Reg. Date	20/03/2024	Patient Id	2403200002	DOB.	
Name	MR. JOGESH CHAWLA	Gender	M	Perm. ID	
Age	55 Yrs.	Panel	MEDIWHEEL	Reported	20/03/2024 16:01:29
Ref. By	MEDIWHEEL				

Test Name	Result	Units	Ref. Range
MediWheel Full Body Plus Annual Check Ad			

HAEMATOLOGY

COMPLETE HAEMOGRAM

HAEMOGLOBIN (HB%)	11.5	gm/dl	13 - 18
TOTAL LEUCOCYTE COUNT (TLC)	6,200	/cumm	4000 - 11000

DIFFERENTIAL LEUCOCYTE COUNT (DLC)

NEUTROPHIL	51	%	40 - 80
LYMPHOCYTE	40	%	28 - 55
MONOCYTE	05	%	02 - 10
EOSINOPHIL	04	%	01 - 06
BASOPHIL	00	%	0 - 0

ESR (WESTEGREN'S METHOD)	16	mm/1st hr.	0 - 10
R B C COUNT	5.28	Millions/cmm	4.247 - 5.4
P.C.V / HAEMATOCRIT	38.1	%	40 - 54
M C V	72.2	fl.	80 - 100
M C H	21.8	Picogram	27.0 - 31.0
M C H C	30.2	gm/dl	33 - 37
PLATELET COUNT	2.67	Lakh/cu mm	1.50 - 4.50
BLOOD GROUP ABO	" O "		
RH TYPING	Positive		
BLOOD SUGAR FASTING	84.87	mg/dl	70 - 100
BLOOD SUGAR PP	117.71	mg/dl	90 - 140

THYROID PROFILE

Free T3 ELFA	2.61	ng/ml	02 - 04
Free T4 ELFA	1.07	ug/dl	0.8 - 2.7

Checked by : _____
Page 1 Contd...2

If test results are alarming or unexpected, patient is advised to contact the laboratory immediately for possible remedial action.

Facilities Available

- Multispeciality Hospital - 24 Hours Emergency - X-Ray/ ECG/ Ultrasound/ CT Scan - Dental- Fully Equipped Operation Theatre
- Fully Functional Lab - 24/7 Casualty/ ICU-Nursery 24/7 Pharmacy - Labour Room - All Speciality OPD - Laproscopic Surgery - ECHO - Plastic Surgery



LAB REPORT

Reg. Date	20/03/2024	Patient Id	2403200002	DOB.	
Name	MR. JOGESH CHAWLA	Gender	M	Perm. ID	
Age	55 Yrs.	Panel	MEDIWHEEL	Reported	20/03/2024 16:01:29
Ref. By	MEDIWHEEL				

Test Name	Result	Units	Ref. Range
TSH Serum/ELFA	2.540	uIU/ml	0.25 - 5.50 uIU/ml

Interpretation

Clinical Use

- Diagnose Hypothyroidism and Hyperthyroidism
- Monitor T4 replacement or T4 suppressive Therapy
- Quantify TSH levels in the subnormal range

Increased Levels : Primary Hypothyroidism Subclinical Hypothyroidism, TSH dependent, Thyroid Hormone Resistance.

Decreased Levels : Grave's Disease, Autonomous Thyroid Hormone Secretion, TSH Deficiency

LIPID PROFILE

TOTAL CHOLESTEROL	159.60	mg/dL	130.0 - 200.0 (<200)
TRIGLYCERIDES	107.70	mg/dL	80.5 - 150.0 (<150)
H D L CHOLESTEROL DIRECT	37.09	mg/dL	35.0 - 60.0 (<40->59)
V L D L	21.5	mg/dL	4.0 - 30. (23-45)
L D L CHOLESTEROL	101.0	mg/dL	50.0 - 150.0 (50-150)
TOTAL CHOLESTEROL / HDL RATIO	4.3		3.3 - 5.1
LDL / HDL CHOLESTEROL RATIO	2.7		1.5 - 3.5

LIVER FUNCTION TEST (LFT)

BILIRUBIN TOTAL	1.40	mg/dl	0.2 - 1.2
-----------------	------	-------	-----------

Checked by : _____
 Page 2 Contd...3

If test results are alarming or unexpected, patient is advised to contact the laboratory immediately for possible remedial action.

Facilities Available

- Multispeciality Hospital - 24 Hours Emergency - X-Ray/ ECG/ Ultrasound/ CT Scan - Dental- Fully Equipped Operation Theatre
- Fully Functional Lab - 24/7 Casualty/ ICU-Nursery 24/7 Pharmacy - Labour Room - All Speciality OPD - Laproscopic Surgery - ECHO - Plastic Surgery



LAB REPORT

Reg. Date	20/03/2024	Patient Id	2403200002	DOB.	
Name	MR. JOGESH CHAWLA	Gender	M	Perm. ID	
Age	55 Yrs.	Panel	MEDIWHEEL	Reported	20/03/2024 16:01:29
Ref. By	MEDIWHEEL				

Test Name	Result	Units	Ref. Range
CONJUGATED (D. BILIRUBIN)	0.33	mg/dl	0.00 - 0.3
UNCONJUGATED (I.D.BILIRUBIN)	1.07	mg/dl	0.2 - 0.9
SGOT / AST	21.00	IU/L	0 - 35
SGPT / ALT	22.4	IU/L	0 - 35
ALKALINE PHOSPHATASE	107.70	U/L	64 - 306
TOTAL PROTEIN	8.20	gm/dl	6.0 - 8.3
ALBUMIN	4.42	gm/dl	3.2 - 5.0
GLOBULIN	3.78	gm/dl	2.5 - 5.6
A/G RATIO	1.17		0.9 - 2.0
GAMMA GT	19.30	IU/L	0.0 - 45.0
SERUM CREATININE	1.00	mg/dl	0.7 - 1.4
SERUM URIC ACID	5.15	mg/dl	3.4 - 7.0
BLOOD UREA NITROGEN (BUN)	11.05	mg/dl	6.0 - 21.0
BUN/CREAT RATIO	11.05	mg/dl	10 - 20
VITAMIN D 25 HYDROXY CLIA	48.4	ng/ml	
TOTAL PSA Chemiluminescence	4.12	ng/ml	

INTERPRETATION :

Expected Values :

99%	:	of Healthy males	0.0-4.0 ng/ml
80%	:	of Benign prostatic hypertrophy	0.0-4.0 ng/ml
81%	:	of Prostatic Carcinomas	Above 4.0 ng/ml

PSA is reliable tumour marker for already diagnosed prostatic carcinomas. It is uniquely associated only with prostatic tissue, and therefore is specific for it. Baseline levels measured prior to therapeutic intervention and followed later by serial periodical measurements will predict the outcome of therapy. It also helps in early discovery of recurrences, relapses and metastases.

Checked by : _____
 Page 3 Contd...4

If test results are alarming or unexpected, patient is advised to contact the laboratory immediately for possible remedial action.

Facilities Available

- Multispeciality Hospital - 24 Hours Emergency - X-Ray/ ECG/ Ultrasound/ CT Scan - Dental- Fully Equipped Operation Theatre
- Fully Functional Lab - 24/7 Casualty/ ICU-Nursery 24/7 Pharmacy - Labour Room - All Speciality OPD - Laproscopic Surgery - ECHO - Plastic Surgery



LAB REPORT

Reg. Date	20/03/2024	Patient Id	2403200002	DOB.	
Name	MR. JOGESH CHAWLA	Gender	M	Perm. ID	
Age	55 Yrs.	Panel	MEDIWHEEL	Reported	20/03/2024 16:01:29
Ref. By	MEDIWHEEL				

Test Name	Result	Units	Ref. Range
PHYSICAL EXAMINATION			
Urine Routine Examination			
QUANTITY	30	ml.	
COLOUR	Pale Yellow		Pale Yellow
TRANSPARENCY	Clear		
SPECIFIC GRAVITY	1.015		
PH	6.0		
CHEMICAL EXAMINATION			
ALBUMIN	Nil		
SUGAR	Nil		
MICROSCOPIC EXAMINATION			
PUS CELLS	2-3	/HPF	
RBC'S	Nil	/HPF	
CASTS	Nil		
CRYSTALS	NIL		
EPITHELIAL CELLS	2-3	/HPF	
BACTERIA	Nil		
OTHERS	Nil		

Dr. Reema Dahiya
Dr. REEMA DAHIYA
 M.B.B.S, MD (Path.)
 Checked by: _____
 Malik Radix Healthcare Pvt. Ltd.
 C-217, C-218, Nirman Vihar
 Delhi-92

DR. MEENU AGGARWAL
 M.B.B.S, MD (Path.)

If test results are alarming or unexpected, patient is advised to contact the laboratory immediately for possible remedial action.

Facilities Available

- Multispeciality Hospital - 24 Hours Emergency - X-Ray/ ECG/ Ultrasound/ CT Scan - Dental- Fully Equipped Operation Theatre
- Fully Functional Lab - 24/7 Casualty/ ICU-Nursery 24/7 Pharmacy - Labour Room - All Speciality OPD - Laproscopic Surgery - ECHO - Plastic Surgery

R

CHESLEYA 0003 207109 10

TSUCHIAWA A 55Y/M P1209186

REALLY FOR AT THE SITE THE INFORMATION WILL BE



UHID	PT209186	LAB No.	XRY2311011
Name	Mr. JOGESH CHAWLA	Regn. No.	GEN2343359
Age / Sex	55 Yrs / M	Receiving Dt/Time	20-Mar-2024 09:40
		Reporting Dt/Time	20-Mar-2024 09:47 AM



XRAY

CHEST (PA)
 Both lung fields are normal.

Cp angles are clear.

Hila are normal...

Heart size appears within normal limits.

Soft tissue shadows and bony thorax are normal.

IMP- NORMAL CHEST X-RAY

Advised....please correlate clinically.

***** END OF REPORT *****

DR. K.K. SINHA
 M.B.B.S., D.M.R.D.
 SENIOR CONSULTANT
 Reg. No. 25437 (DMC)

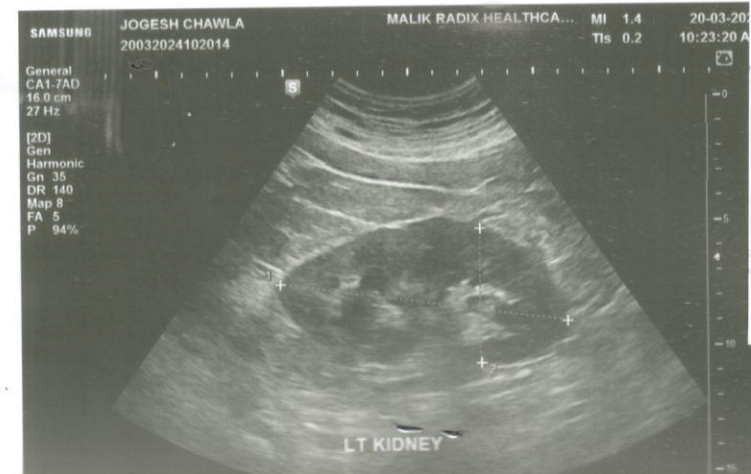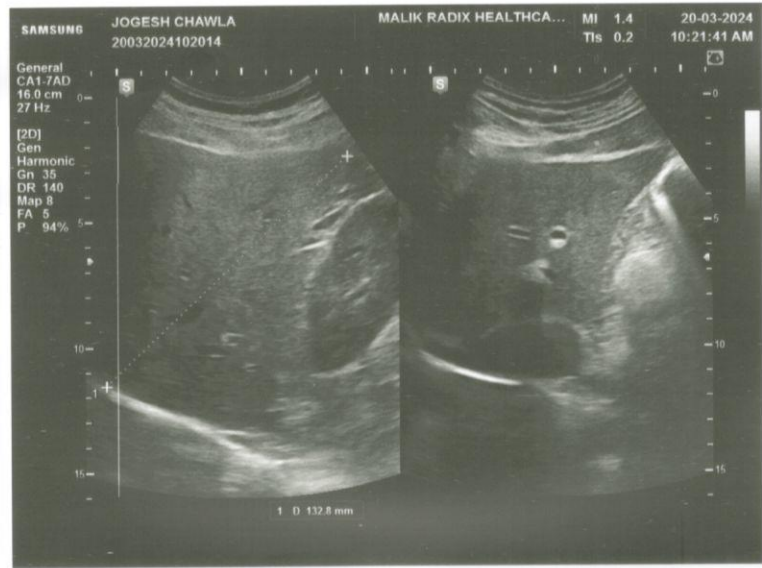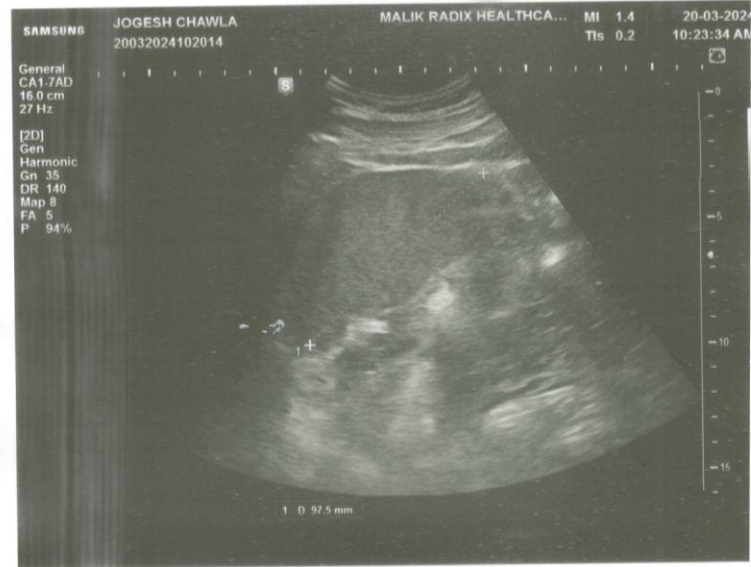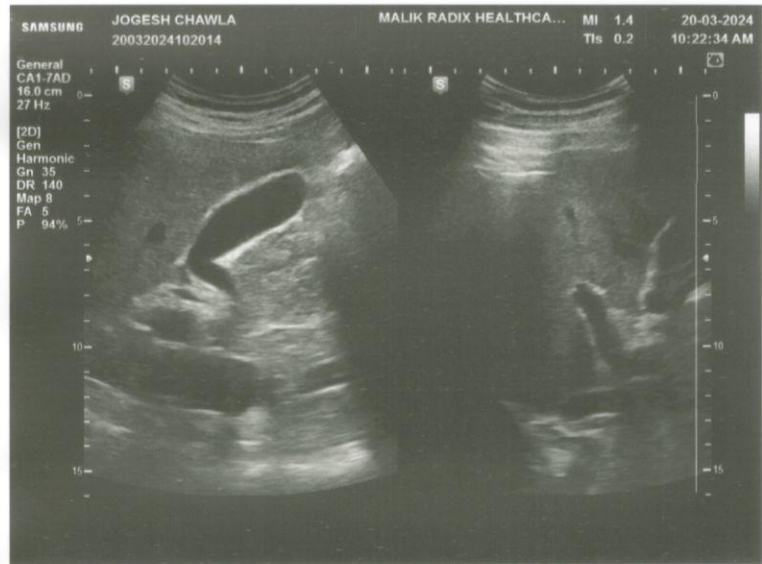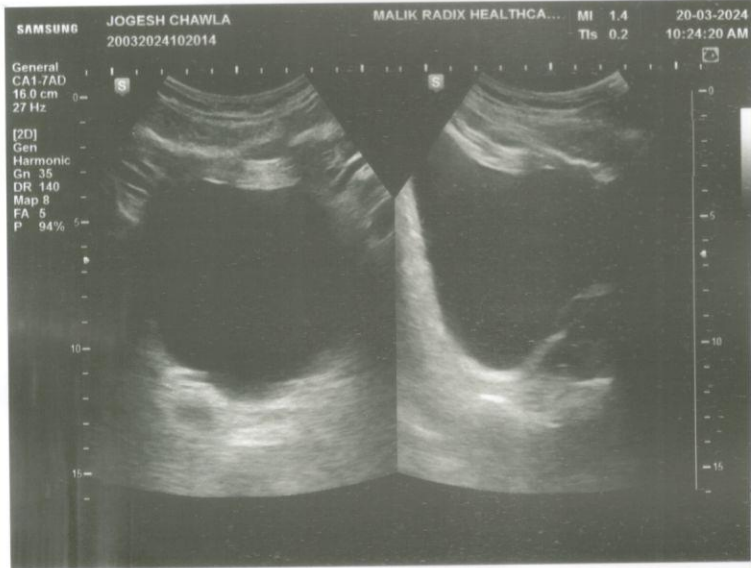
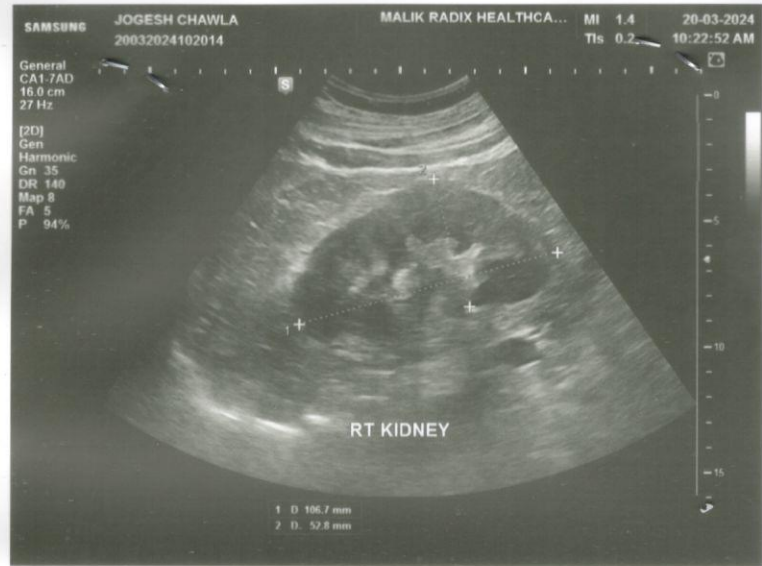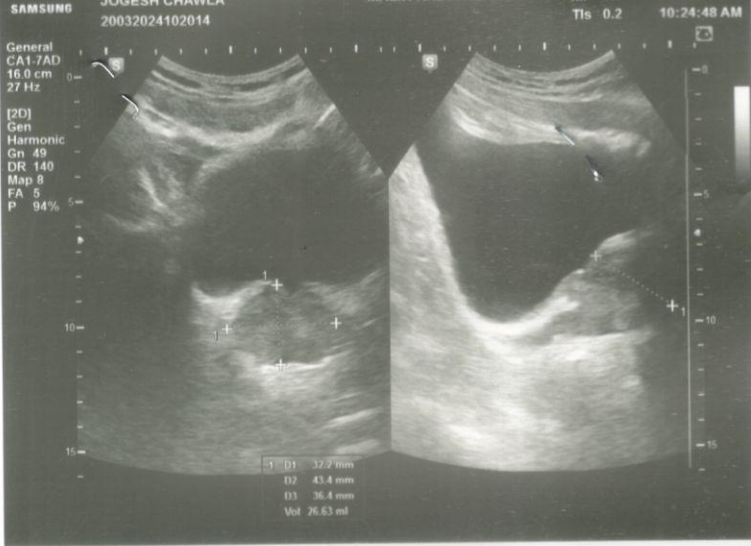DR. RAJESH MALHOTRA
 MBBS, MD (RADIOLOGY)
 CONSULTANT RADIOLOGY
 Reg.No.DMC9299

DR. T. K VOHRA
 MD (RADIOLOGY)
 SENIOR CONSULTANT
 Reg. No. 3272 (DMC)

DR MUKESH KOSHAL
 MBBS, MD (RADIOLOGY)
 CONSULTANT RADIOLOGY
 Reg.No.DMC10407

DR SHREYASH TIWARY
 MBBS, MD (RADIOLOGY)
 CONSULTANT RADIOLOGY
 Reg.No.DMC85802

Facilities Available





NAME	MR. JOGESH CHAWLA	AGE	55 YRS/M
REFD. BY.	HEALTH CHECK UP	DATE	20.03.24

Ultrasound Examination of Whole Abdomen & Pelvis:

Liver: Liver appears normal in size (13.2 cm) with normal outlines and shows normal parenchymal echotexture. No focal SOL is seen in liver. IHBR & portal radicles are normal.

Gallbladder: Gallbladder is well distended. No evidence of cholecystitis or cholelithiasis seen. Common bile duct is normal in course & caliber.

Pancreas: Pancreas shows normal size, outlines & echotexture. No focal lesion is seen. MPD is not dilated.

Spleen: Spleen shows normal size (9.7 cm), outline & echotexture.

Kidneys: Kidneys show normal size, shape, position & echotexture. No calculus/ hydronephrosis or SOL is seen in kidneys. Cortico- medullary differentiation and cortical thickness is normal on both sides.

Right kidney measures -10.6 x 5.2 cm

Left kidney measures -11.5 x 5.4 cm

Great abdominal vessels are normal.

No ascites seen.

No para-aortic lymph nodes seen.

Urinary bladder Urinary bladder is well distended. Walls and lumen appear normal.

Prostate is enlarged in size (26.6 cc) with normal outline and echotexture. No focal lesion is seen.

IMPRESSION:

Grade I Prostatomegaly

Dr Shreyash Tiwary MD (Rad- diag)

Regn. No. DMC 85802

RADIOLOGIST :

Facilities Available