

Patient Name : Mrs. CHINKAL AGRAWAL

Age/Gender : 32 Y/F

UHID/MR No. : CSAR.0000136795

OP Visit No : CSAROPV323705

Sample Collected on :

Reported on : 09-01-2024 19:22

LRN# : RAD2204087

Specimen :

Ref Doctor : SELF

Emp/Auth/TPA ID : PKG10000366

DEPARTMENT OF RADIOLOGY

X-RAY CHEST PA

- Trachea central.
- Mediastinum is central.
- Cardiac silhouette appear normal.
- For visualized lung fields appear normal.
- Bilateral hilum appear normal.
- CP angles are clear.

IMPRESSION : No obvious gross abnormality noted in the x-ray.

DR. RAMESH G
CONSULTANT RADIOLOGIST

ADVICE : Higher imaging techniques to be done, if clinically needed, depending on the clinical condition of the patient for further evaluation.



Patient Name : Mrs. CHINKAL AGRAWAL

Age/Gender : 32 Y/F

Patient Name : Mrs. CHINKAL AGRAWAL

Age/Gender : 32 Y/F

UHID/MR No. : CSAR.0000136795

OP Visit No : CSAROPV323705

Sample Collected on :

Reported on : 09-01-2024 18:59

LRN# : RAD2204087

Specimen :

Ref Doctor : SELF

Emp/Auth/TPA ID : PKG10000366

DEPARTMENT OF RADIOLOGY

ULTRASOUND - WHOLE ABDOMEN

LIVER : Normal in size & echotexture normal. No focal lesion. No intra hepatic biliary duct dilatation. Portal & hepatic veins appear normal. PV: Normal. CBD: Normal.

GALL BLADDER : Minimally distended. No intraluminal calculi seen. Wall thickness is normal.

PANCREAS : Obscured by bowel gas. However the visualized parts of the pancreas appear grossly normal. Para-Aortic areas could not be seen.

SPLEEN : Normal in size & echotexture normal. No focal / diffuse lesions.

KIDNEYS : RIGHT KIDNEY : 10.0 x 1.4 cms, LEFT KIDNEY : 10.1 x 1.5 cms, normal parenchymal thickness. Both kidneys are normal in size and echotexture. No calculi.

No pelvicalyceal dilatation on both sides. Corticomedullary differentiation is well maintained.

URINARY BLADDER : Normal in wall thickness and lumen are normal. Contents clear. No calculus seen.

UTERUS : Anteverted. Normal in size (6.7 x 4.1 x 5.0) and echotexture. Endometrial and myometrium appears normal. Endometrial thickness: 7.5 mm.

POD – clear.

OVARIES : Both ovaries are normal in size & echopattern. No obvious mass noted.

Right Ovary : 2.5 x 1.6

Left Ovary : 2.6 x 1.5

IMPRESSION : No sonologically detectable abnormality seen in the present study.

DR. B M SESHADRI MDRD
CONSULTANT RADIOLOGIST

(The sonography findings should always be considered in correlation with the clinical and other investigation findings where applicable).It is only a professional opinion. Not valid for medico-legal purpose) Higher imaging techniques to be done, depending on the condition of the patient, if clinically needed.

APOLLO CLINIC
CONSENT FORM

Patient name Chinthal Agarwal Age 32 y/F

UHID Number 136795 Company Name Mediwheel

I Mr/Mrs/Ms Chinthal Agarwal Employee of BOB


Company want to inform u that I am ^{later on 27/01/24} not interested in getting CBC Pap Smear

ENT.....And I claim the above statement in my full Consciousness.

Patient signature  Date 09/01/24

5

Name : Mrs. CHINKAL AGRAWAL Age: 32 Y
 Address : sjp Sex: F
 Plan : ARCOFEMI MEDIWHEEL FEMALE AHC CREDIT PAN INDIA OP AGREEMENT

UHID:CSAR.0000136795

 CSAR.0000136795
 OP Number:CSAROPV323705
 Bill No :CSAR-OCR-43774
 Date : 09.01.2024 08:26

Sno	Service Type/ServiceName	Department
1	ARCOFEMI - MEDIWHEEL - FULL BODY HEALTH ANNUAL PLUS CHECK - FEMALE - 2D ECHO - PAN INDIA - FY2324	
<input checked="" type="checkbox"/>	GAMMA GLUTAMYL TRANSFERASE (GGT)	
<input checked="" type="checkbox"/>	2D ECHO - 18	10:30 to 11:00
<input checked="" type="checkbox"/>	LIVER FUNCTION TEST (LFT)	
<input checked="" type="checkbox"/>	GLUCOSE, FASTING - 8	
<input checked="" type="checkbox"/>	HEMOGRAM + PERIPHERAL SMEAR	
	6 GYNAECOLOGY CONSULTATION	
	7 DIET CONSULTATION	
<input checked="" type="checkbox"/>	COMPLETE URINE EXAMINATION	
<input checked="" type="checkbox"/>	URINE GLUCOSE (POST PRANDIAL)	
<input checked="" type="checkbox"/>	PERIPHERAL SMEAR	
<input checked="" type="checkbox"/>	ECG	
<input checked="" type="checkbox"/>	LBC PAP TEST - PAPSURE - 6	
<input checked="" type="checkbox"/>	RENAL PROFILE/RENAL FUNCTION TEST (RFT/KFT)	
<input checked="" type="checkbox"/>	DENTAL CONSULTATION - 15	
<input checked="" type="checkbox"/>	GLUCOSE, POST PRANDIAL (PP), 2 HOURS (POST MEAL) - 8	
<input checked="" type="checkbox"/>	URINE GLUCOSE (FASTING)	
<input checked="" type="checkbox"/>	HbA1c. GLYCATED HEMOGLOBIN	
<input checked="" type="checkbox"/>	X-RAY CHEST PA - 9	
<input checked="" type="checkbox"/>	ENT CONSULTATION - 3	
	20 FITNESS BY GENERAL PHYSICIAN	
<input checked="" type="checkbox"/>	BLOOD GROUP ABO AND RH FACTOR	
<input checked="" type="checkbox"/>	LIPID PROFILE	
<input checked="" type="checkbox"/>	BODY MASS INDEX (BMI) - 10	
	24 OPHTHAL BY GENERAL PHYSICIAN	Eye identifi.
<input checked="" type="checkbox"/>	ULTRASOUND - WHOLE ABDOMEN - 18	9:15
<input checked="" type="checkbox"/>	THYROID PROFILE (TOTAL T3, TOTAL T4, TSH)	2 ltrs of water

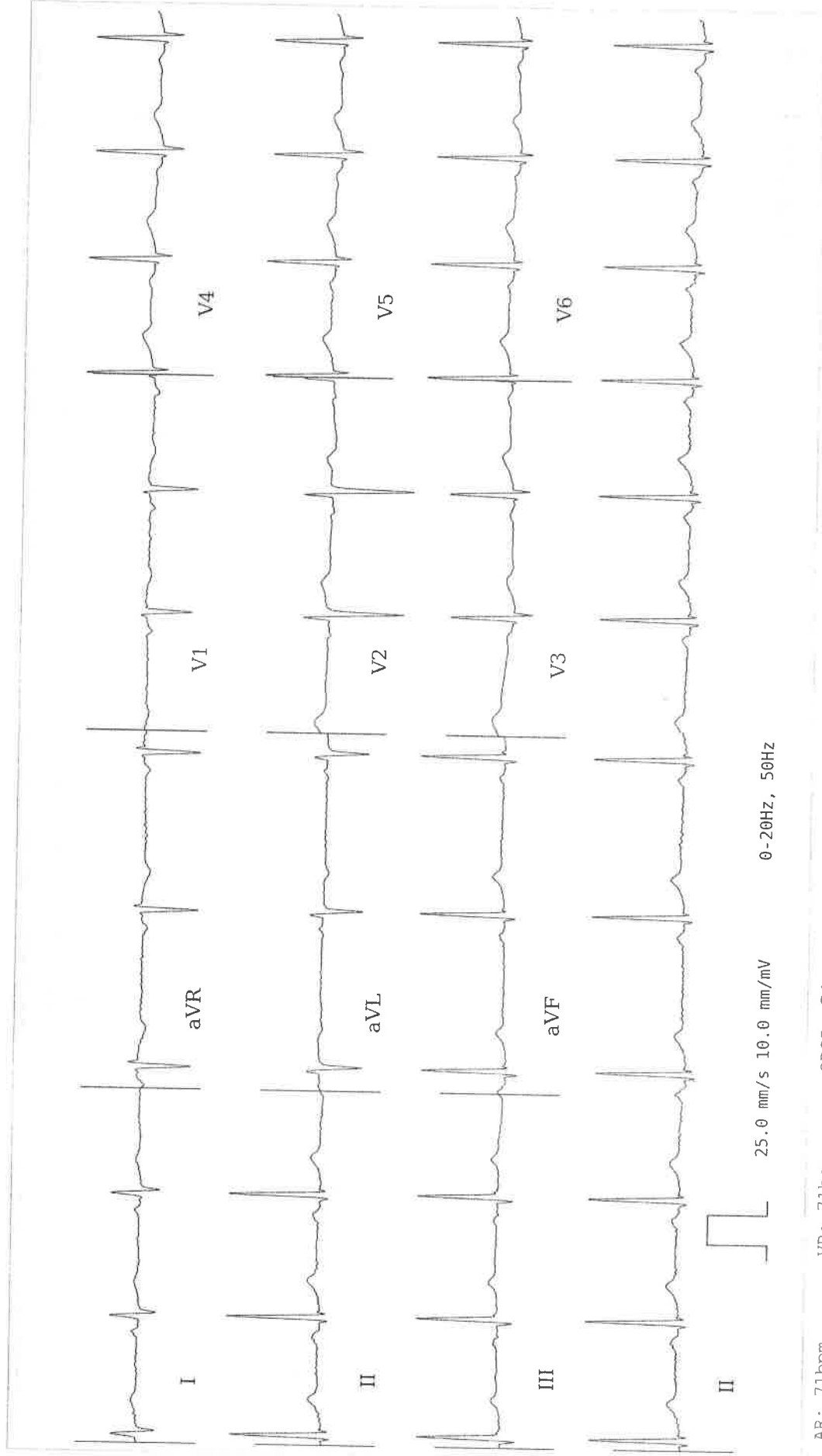
Wt 62.9 kg
 Ht 158 cm
 BP 97/79 mmHg
 P 82b/min
 BMI: 25.1 kg/m²



Apollo Clinic, Kaikondrahalli

Age / Gender: 32/Female
Patient ID: AGRAWAL

Date and Time: 9th Jan 24 11:54 AM



AR: 71bpm VR: 71bpm QRSD: 74ms QT: 372ms QTcB: 404ms PRI: 144ms P-R-T: 57° 86° 70°

ECG Within Normal Limits: Sinus Rhythm, Sinus Arrhythmia Seen. Please correlate clinically.

REPORTED BY

[Signature]
Dr. Chitrali Singh

Disclaimer: Analysis in this report is based on ECG alone and should only be used as an adjunct to clinical history, symptoms and results of other invasive and non-invasive tests and must be interpreted by a qualified physician.

2D, TISSUE AND COLOR DOPPLER ECHOCARDIOGRAPHY REPORT



NAME	MRS. CHINKAL AGARWAL		DATE:9.1.2024	
AGE	32 YEARS	GENDER	FEMALE	
REF BY	DR. SUMANJITA BORA	ID	136795	

MEASUREMENTS

Vital Signs and Body Measurements									
HR	bpm	B.P	mmHg	Height	mm	Weight	kg	BSA	m ²
M - Mode (Parasternal view)					Conventional and Tissue Doppler				
AO	27	mm	LVID - d	40	mm	Mitral Valve	E : 0.9	A : 0.6	m/sec
LA	32	mm	LVID - s	25	mm	Aortic Valve	1.1	-	m/sec
			IVS - d	10	mm	Pulmonary Valve	0.6	-	m/sec
			PW - d	10	mm	E' Septal (TDI)	0.11	-	mm/sec
			EF-	60	%	E' Lateral (TDI)	0.14	-	mm/sec

DESCRIPTIVE FINDINGS: Technically Adequate Study. Normal sinus rhythm During Study

RIGHT ATRIUM	Normal in Size
LEFT ATRIUM	Normal in Size
RIGHT VENTRICLE	Normal in Size Tapse > 18mm
LEFT VENTRICLE	Normal in Size
WALL MOTION ANALYSIS	No RWMA
TRICUSPID VALVE	Normal, PASP= 20 mmHg, Trivial TR
MITRAL VALVE	Normal
PULMONIC VALVE	Normal
AORTIC VALVE	Normal
IAS & IVS	Intact
AORTA	Normal in Size
SYSTEMIC & PULMONARY VEINS	Normally Draining
IVC	Normal
PERICARDIUM	Normal
OTHERS	No Intra Cardiac Thrombus, Tumour or Vegetation

IMPRESSION:

Cardiac Chambers & valves are normal
 Normal PAP
 No RWMA
 Normal Left Ventricular Systolic Function (LVEF-60%)
 No clot/ vegetation/pericardial effusion

**Dr. SUMANJITA BORA, MBBS AMC.PGDCC(Cardiology)
 CONSULTANT CARDIOLOGIST**

Apollo Health and Lifestyle Limited

(CIN - U85110TG2000PLC115819)
 Regd. Office: 1-10-60/62, Ashoka Raghupathi Chambers, 5th Floor, Begumpet, Hyderabad, Telangana - 500 016.
 Ph No: 040-4904 7777, Fax No: 4904 7744 | Email ID: enquiry@apollohl.com | www.apollohl.com

APOLLO CLINICS NETWORK KARNATAKA

Bangalore (Basavanagudi | Bellandur | Electronic City | Fraser Town | HSR Layout | Indira Nagar | JP Nagar | Kundalahalli | Koramangala | Sarjapur Road) **Mysore** (VV Mohalla)

Online appointments: www.apolloclinic.com

TO BOOK AN APPOINTMENT

1860 500 7788

आयकर विभाग
INCOME TAX DEPARTMENT
CHINKAL AGRAWAL
LAXMAN PRASAD

भारत सरकार
GOVT. OF INDIA



18032009

17/02/1991

Permanent Account Number

AOTPA8374A

Chinkal Agrawal

Signature

Fwd: Reminder your health checkup booking is tomorrow

Chinkal Garg <chinkalgrg1721@gmail.com>

Tue 09-01-2024 08:22

To: Sarjapur Apolloclinic <sarjapur@apolloclinic.com>

----- Forwarded message -----

From: **Mediwheel** <wellness@mediwheel.in>

Date: Tue, Jan 9, 2024, 12:41 AM

Subject: Reminder your health checkup booking is tomorrow

To: <chinkalgrg1721@gmail.com>

Cc: <customercare@mediwheel.in>

Dear **MRS. AGRAWAL CHINKAL**,

This is a gentle reminder that your health checkup is scheduled for tomorrow as per the below particular. Please visit the center at any time.

Please follow the following instructions. Please call us at 011-41195959 if you face any issues.

Booking Date : 08/01/2024

Health Check up Name : Mediwheel Full Body Annual Plus

Health Check Code : PKG10000366

Name of Diagnostic/Hospital : Apollo Clinic - Sarjapur Road Bangalore

Address of Diagnostic/Hospital- Apollo Clinic, #769, GYR Chambers, Opp South Indian Bank, Kaikondanahalli, Sarjapur Road -560034

Appointment Date : 09/01/2024

Preferred Time : 8:00am-8:00am

Package Name : Mediwheel Full Body Annual Plus

Tests included in this Package :

- Bmi Check
- Ent Consultation
- Dietician Consultation
- Thyroid Profile
- ESR
- Blood Glucose (Fasting)
- General Physician Consultation
- TMT OR 2D ECHO
- Blood Group
- Blood Glucose (Post Prandial)
- Chest X-ray
- ECG
- USG Whole Abdomen
- Eye Check-up consultation