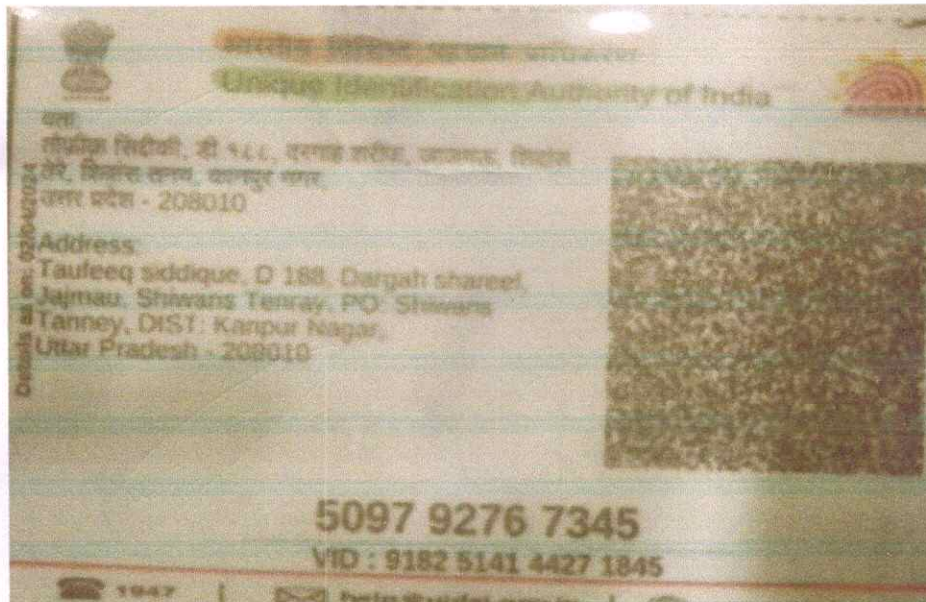
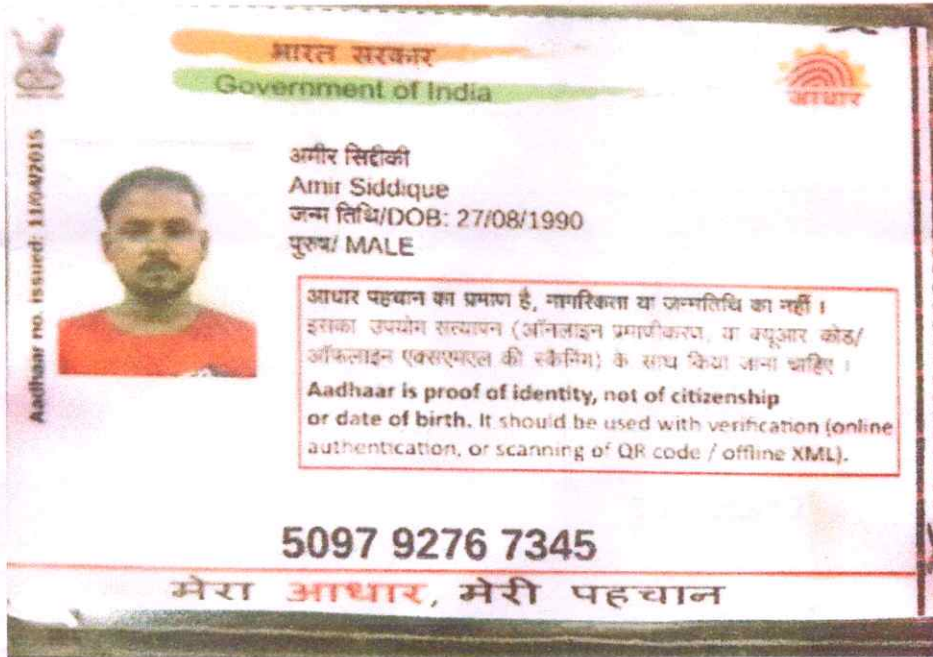

ORIGINAL SEEN AND VERIFIED – 28.09.2024

MR. AMIR SIDDIQUE, AGE: 34 YEARS



*Amir Siddique*  
28/09/2024  
POLICY HOLDER SIGNATURE

TAURUS MEDICARE PVT. LTD.  
TAURUS HOSPITAL  
HOSPITAL SIGN WITH STAMP  
Shivadevi, Kanpur



# TAURUS HOSPITAL

(A Unit of Taurus Medicare Pvt. Ltd.)

208. Safipur 1st Ramadevi G. T. Road, Kanpur-208 007



Phone  
0512 -2400779  
0512 -2400774  
0512 -2400737  
8601955058

## Pathology Report

Lab. No. : 1139	Date : 2024-09-28 10:09:24
Patient Name : Mr. SIDDIQUE AMIR	Guardian Name :
Age/Sex : 34 Years/Male	Address : KANPUR,
Referred By : SELF	
0	

Test Name	Observed Values	Unit	Normal Values
-----------	-----------------	------	---------------

### Clinical

#### URINE R/M

Colour	STRAW	.	
Appearance	CLEAR	.	
Specific Gravity	1.025	.	1.005-1.030
Ph	6.0	.	4.5-8.0
Protien	Nil	.	Nil
Glucose	Nil	.	Nil
Pus Cells	1-2	/hpf	0-5
Epithelial Cells	1-2	/hpf	0-5
RBC	Nil	/hpf	Nil
Casts	Not Seen	.	Not Seen
Crystals	Not Seen	.	Not Seen

### Haematology

#### CBC (Complete Blood Counts)

HB	14.50	mg/dl	11.50 - 17.50 mg/dl
TLC	7700	/CU MM	4000-11000
DLC		%	
NEUTROPHILL	60	%	40.0-80.0
LYMPHOCYTE	33	%	20.0-40.0
MONOCYTE	03	%	2.0-10.0
EOSINOPHILL	04	%	1.0-6.0
BASOPHILL		%	2.00 - 2.00 %
RBC	5.03	U/L	4.7-7.1
PCV	41.8	%	36.0-46.0
MCV	83.1	FL	83.0-101.0
MCH	28.8	%	11-20
MCHC	34.7	g/dl	31.5-34.5
PLatelet count	2.08	lakh/cum	1.50-4.0
RDW-CV	13.1	%	11.6-14.0



*Vishakha*

Dr. Vishakha Pal  
MBBS, DCP (PATH)



# TAURUS HOSPITAL

(A Unit of Taurus Medicare Pvt. Ltd.)

208. Safipur 1st Ramadevi G. T. Road, Kanpur-208 007



Phone  
0512 -2400779  
0512 -2400774  
0512 -2400737  
8601955058

## Pathology Report

Lab. No. : 1139	Date : 2024-09-28 10:09:24
Patient Name : Mr. SIDDIQUE AMIR	Guardian Name :
Age/Sex : 34 Years/Male	Address : KANPUR,
Referred By : SELF	
0	

Test Name	Observed Values	Unit	Normal Values
<b>Biochemistry</b>			
<b>Lipid Profile (With Direct - HDL &amp; L)</b>			
Cholestrol	189.20	mg/dl	0.00 - 200.00 mg/dl
triglycerides	104.27	mg/dl	0.00 - 150.00 mg/dl
HDL	53.21	mg/dl	30.00 - 65.00 mg/dl
LDL	99.79	mg/dl	0.00 - 130.00 mg/dl
VLDL	24.0	mg/dl	2.00-30.00
Cholesterol/HDL Ratio	3.55	.	<4.00
LDL/HDL cholesterol Ratio	1.87	.	<3.50
HDL/LDL Cholestrol Ratio	0.53	.	<3.50

## Blood Chemistry

### L.F.T.

BILI TOTAL	0.59	mg/dl	0-2.0 mg/dl
BILI DIRECT	0.19	mg/dl	0-0.20 mg/dl
BILI (IND)	0.40	mg/dl	0.20-0.60mg/dl
SGPT(ALT)	17.64	IU/L	up-45 IU/L
SGOT	22.79	IU/L	up-35 IU/L
ALP(ALKALINE PHOSPHATASE)	70.69	IU/L	54-119 IU/L
TOTAL PROTEIN	6.34	g/dl	6.4-8.3 g/dl
ALBUMIN(ALB)	3.41	g/dl	3.5-4.6 g/dl



*Vishakha*

Dr. Vishakha Pal  
MBBS,DCP( PATH)

Affiliated with CGHS/CAPF/TPA



# TAURUS HOSPITAL

(A Unit of Taurus Medicare Pvt. Ltd.)

208. Safipur 1st Ramadevi G. T. Road, Kanpur-208 007



Phone  
0512 -2400779  
0512 -2400774  
0512 -2400737  
8601955058

## Pathology Report

Lab. No. : 1139	Date : 2024-09-28 10:09:24
Patient Name : Mr. SIDDIQUE AMIR	Guardian Name :
Age/Sex : 34 Years/Male	Address : KANPUR,
Referred By : SELF	
0	

Test Name	Observed Values	Unit	Normal Values
<b>Blood Chemistry</b>			
<b>KFT</b>			
CRET	1.03	mg/dl	0.70 - 1.40 mg/dl
UREA	41.69	mg/dl	15.00 - 45.00 mg/dl
BUN	19.28	mg/dl	5.00 - 25.00 mg/dl
UAC	6.12	mg/dl	2.50 - 7.50 mg/dl
<b>Haematology</b>			
ESR-Wintrobe (Erythrocyte Sedimentation Rate)	09	mm/hr.	
<b>Hormones &amp; Related Test</b>			
<b>T3, T4 (Total) &amp; TSH 3rd Generation</b>			
T3	2.79	.	1.30-3.10nmol/L
T4	81.46	.	66.00-181.00nmol/L
TSH	3.99	.	0.45-4.50MIU/L
<b>Serology</b>			
Blood Group ABO+ Rh	"B" POSITIVE	.	gh



Dr. Vishakha Pal  
MBBS,DCP( PATH)

Affiliated with CGHS/CAPF/TPA



# TAURUS HOSPITAL

(A Unit of Taurus Medicare Pvt. Ltd.)

208. Safipur 1st Ramadevi G. T. Road, Kanpur-208 007



Phone  
0512 -2400779  
0512 -2400774  
0512 -2400737  
8601955058

## Pathology Report

Lab. No.	: 1140	Date	: 2024-09-28 10:09:14
Patient Name	: Mr. SIDDIQUE AMIR	Guardian Name	:
Age/Sex	: 34 Years/Male	Address	: JAJMAU KANPUR,
Referred By	: SELF		
	0		

Test Name	Observed Values	Unit	Normal Values
<b>Biochemistry</b>			
blood sugar (pp)	101.8	1	



*Vishakha*  
Dr. Vishakha Pal  
MBBS, DCP (PATH)

Affiliated with CGHS/CAPF/TPA



# TAURUS HOSPITAL

(A Unit of Taurus Medicare Pvt. Ltd.)

208. Safipur 1st Ramadevi G. T. Road, Kanpur-208 007



Phone  
0512 -2400779  
0512 -2400774  
0512 -2400737  
8601955058

## Pathology Report

Lab. No. : 1139	Date : 2024-09-28 10:09:24
Patient Name : Mr. SIDDIQUE AMIR	Guardian Name :
Age/Sex : 34 Years/Male	Address : KANPUR,
Referred By : SELF	
0	

Test Name	Observed Values	Unit	Normal Values
<b>Biochemistry</b>			
BLOOD SF	77.44	mg/dl	70-100
<b>Haematology</b>			
HbA1C	6.3	g/dl	< 5.6 % Normal 5.7-6.4% Pre-Diabetes >6.5 % Diabetes 6.5-7.0% Good control 7.0-8.0% Poor control >8.0% Bad control



*Vishakha*

Dr. Vishakha Pal  
MBBS,DCP( PATH)



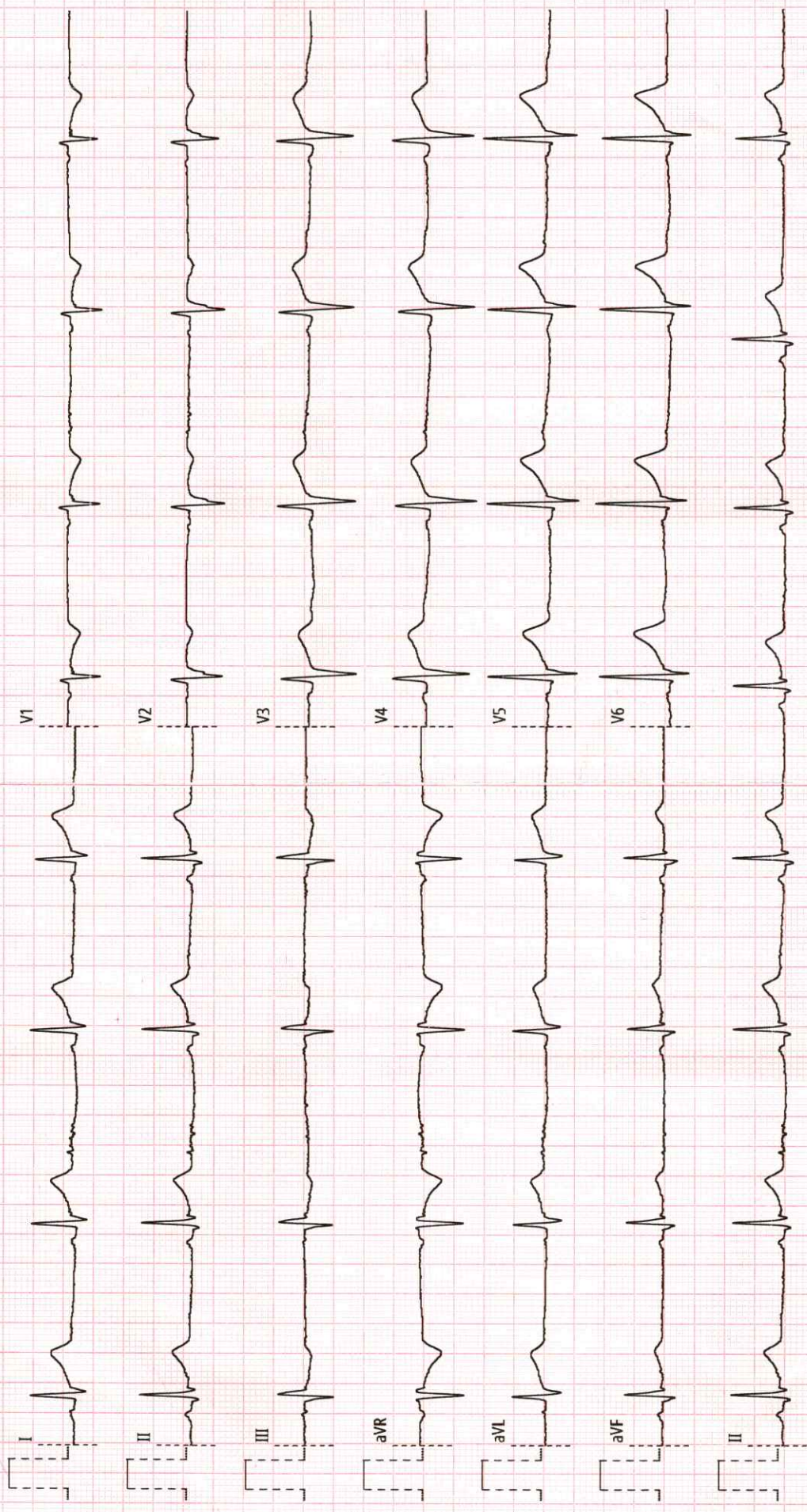
# ECG report

Confirm and sign: \_\_\_\_\_

<<Interpretations >>  
 Sinus bradycardia with sinus arrhythmia  
 — Interpretation made without knowing patients gender/age —  
 Inferior infarct - age undetermined  
 Septal T wave abnormality  
 ~ is nonspecific  
 Abnormal ECG

HR : 49 bpm  
 PR : 134 ms  
 QRS : 98 ms  
 QT/QTc : 442/423 ms  
 P/QRS/T : 42/36/19°  
 RV5/SV1 : 1.048/0.487 mv  
 RV5+SV1 : 1.535 mv

ID : 20240928080159  
 Name : Amir  
 Gender : M  
 Age :  
 Dept :  
 Bed No :





# Affiliated with CGHS / CAPF TOURUS HOSPITAL

(A Unit of Taurus Medicare Pvt. Ltd.)

208, Safipur 1st Ramadevi, G. T. Road, Kanpur-208 007

Ph.: 0512-2400779, 2400774, 2400737, 8601955058 • E-mail: tourushospital@gmail.com



28/9/24

AMIR SIDDIQUE

34/m

gdecho

Normal size LA/LV, RA/RV

• NO RWMA

• NO MR/TRIAR

• NO PE / Apical clot

• IVC  $\approx$  11mm collapsing  $\approx$  70% resp

• LVEF - 60%







Affiliated with CGHS / CAPF  
**TOURUS HOSPITAL**

(A Unit of Taurus Medicare Pvt. Ltd.)

208, Safipur 1st Ramadevi, G. T. Road, Kanpur-208 007

Ph.: 0512-2400779, 2400774, 2400737, 8601955058 • E-mail: tourushospital@gmail.com



<i>Patient Name</i>	SIDDIQUE AMIR	<i>Patient ID</i>	280924-1
<i>Age/D.O.B</i>	34 YRS	<i>Gender</i>	M
<i>Ref Doctor</i>	SELF	<i>Date</i>	28 Sep 24

## XRAY RADIOGRAPH CHEST - PA

### Observations

Prominent bronchovascular markings are noted in bilateral lung fields.  
The cardiac silhouette is normal.  
Both hila are normal.  
No focal lung lesion is seen.  
Soft tissues of the chest wall are normal.  
No mediastinal abnormality is visible.  
Cardiothoracic ratio is normal.

### Impression

Prominent bronchovascular markings are noted in bilateral lung fields.

Reported By,

*Mr. Farid Khan*

Dr. Farid Khan

MBBS, MD

Consultant Radiologist

MPMC-23324





## Kanpur, Uttar Pradesh, India

208, SAFIPUR 2, RAMA DEVI, Ramadevi, Ayodhya Market, Near Malik Complex, Lal Bungalow, Jajmau Sub Metro City, Kanpur, Uttar Pradesh 208007, India

Lat 26.413978°

Long 80.384295°

28/09/24 09:50 AM GMT +05:30

