

Dr. Vimmi Goel
MBBS, MD (Internal Medicine)
Sr. Consultant Non Invasive Cardiology
Reg. No: MMC- 2014/01/0113

Preventive Health Check up
KIMS Kingsway Hospitals
Nagpur
Phone No.: 7499913052



Name : Mr. Kamalakar. Bordekar. Date : 13/01/24

Age : 54 Sex : M F Weight : 55.8 kg Height : 165.9 inc BMI : 20.3

BP : 130/80 mmHg Pulse : 78 bpm RBS : _____ mg/dl

SpO2 - 99%



KIMS - Kingsway Hospitals
(A Unit of SPANV Medisearch Lifesciences Pvt. Ltd.)

44, Kingsway, Near Kasturchand Park, Nagpur,
Maharashtra, India - 440001.

Ph No.: 1800 266 8346 | Mobile No.: +91-7126789100

Email : assistance@kimshospitals.com | Website : www.kimshospitals.com

DEPARTMENT OF OPHTHALMOLOGY OUT PATIENT ASSESSMENT RECORD

KAMALKAR BORKAR 51Y(S) 5M(S) 7D(S)/M UMR2324033724 9284380468	CONSULT DATE : 13-01-2024 CONSULT ID : OPC2324102459 CONSULT TYPE : VISIT TYPE : NORMAL TRANSACTION TYPE : CASH	DR. ASHISH PRAKASHCHANDRA KAMBLE MBBS, MS, FVRS, FICO CONSULTANT DEPT OPHTHALMOLOGY
---	--	---

VITALS

Temp : Pulse : BP (mmHg) : spO2 : Pain Score : Height :
-- °F -- /min -- %RA -- /10 -- cms

Weight : BMI :
-- kgs --

CHIEF COMPLAINTS

ROUTINE EYE CHECK UP

MEDICATION PRESCRIBED

#	Medicine	Route	Dose	Frequency	When	Duration
1	SOFTVISC ULTRA 10ML EYE DROPS	Topical	1-1-1-1	Every Day	After Food	60 days
Instructions : BOTH EYES ✓						
Composition : SODIUM HYALURONATE 0.3% WV+STABILIZED OXYCHLORO COMPLEX 0.01% WV						

NOTES

GLASS PRESCRIPTION :-

DISTANCE VISION

EYE	SPH	CYL	AXIS	VISION
RIGHT EYE	+1.25	00	00	6/6p
LEFT EYE	+1.25	00	00	6/6

NEAR ADDITION

RIGHT EYE	+2.00D	N6
LEFT EYE	+2.00D	N6

REMARK:-

DEPARTMENT OF RADIOLOGY & IMAGING SCIENCE

NAME	KAMALKAR BORKAR	STUDY DATE	13-01-2024 10:29:34
AGE/ SEX	51Y 5M 8D / M	HOSPITAL NO.	UMR2324033724
ACCESSION NO.	BIL2324069428-17	MODALITY	DX
REPORTED ON	13-01-2024 12:37	REFERRED BY	Dr. Vimmi Goel

X-RAY CHEST PA VIEW

Both the lung fields are clear.

Heart and Aorta are normal.

Both hilar shadows appear normal.

Diaphragm domes and CP angles are clear.

Bony cage is normal.

IMPRESSION -No pleuro-parenchymal abnormality seen.



DR R.R KHANDELWAL

SENIOR CONSULTANT

MD, RADIODIAGNOSIS [MMC-55870]

PATIENT NAME:	MR. KAMLAKAR BORKAR	AGE /SEX:	51Y/M
UMR NO:	2324033724	BILL NO:	2324069428
REF BY	DR. VIMMI GOEL	DATE:	13/01/2024

USG WHOLE ABDOMEN

LIVER is normal in size, shape and echotexture.

No evidence of any focal lesion seen. Intrahepatic biliary radicals are not dilated.

PORTAL VEIN and CBD are normal in course and caliber.

GALL BLADDER is physiologically distended. No sludge or calculus seen.

Wall thickness is within normal limits.

PANCREAS is normal in shape, size and echotexture.

SPLEEN is normal in shape, size and echotexture. No focal lesion seen.

Both KIDNEYS are normal in shape, size and echotexture.

No evidence of calculus or hydronephrosis seen.

URETERS are not dilated.

BLADDER is partially distended. No calculus or mass lesion seen.

Prostate is normal in size, shape and echotexture.

There is no free fluid or abdominal lymphadenopathy seen.

IMPRESSION:

No significant abnormality seen.

Suggest clinical correlation / further evaluation.



DR. R.R. KHANDELWAL
SENIOR CONSULTANT
MD RADIO DIAGNOSIS [MMC-55870]

Kingsway Hospitals
44 Kingsway, Mohan Nagar,
Near Kasturchand Park, Nagpur

Station
Telephone:

EXERCISE STRESS TEST REPORT

Patient Name: Mr. Kamlakar, Borkar
Patient ID: 033724
Height:
Weight:
Study Date: 13.01.2024
Test Type: Treadmill Stress Test
Protocol: BRUCE

DOB: 06.10.1972
Age: 51 yrs
Gender: Male
Race: Indian
Referring Physician: Mediwheel HCU
Attending Physician: Dr. Vimmi Goel
Technician: --

Medications:

Medical History:
NIL

Reason for Exercise Test:

Screening for CAD

Exercise Test Summary:

Phase Name	Stage Name	Time in Stage	Speed (mph)	Grade (%)	HR (bpm)	BP (mmHg)	Comment
PRETEST	SUPINE	00:05	0.00	0.00	73	120/80	
	WARM-UP	00:05	0.00	0.00	73		
EXERCISE	STAGE 1	03:00	1.70	10.00	109		
	STAGE 2	03:00	2.50	12.00	129	140/80	
	STAGE 3	03:00	3.40	14.00	141	150/80	
	STAGE 4	00:22	4.20	16.00	144		
RECOVERY		01:00	0.00	0.00	125	150/80	
		02:00	0.00	0.00	113	130/80	
		00:15	0.00	0.00			

The patient exercised according to the BRUCE for 9:22 min:s, achieving a work level of Max. METS: 11.20. The resting heart rate of 73 bpm rose to a maximal heart rate of 146 bpm. This value represents 86 % of the maximal, age-predicted heart rate. The resting blood pressure of 120/80 mmHg, rose to a maximum blood pressure of 150/80 mmHg. The exercise test was stopped due to Target heart rate achieved.

Interpretation:

Summary: Resting ECG: normal.

Functional Capacity: normal.

HR Response to Exercise: appropriate.

BP Response to Exercise: normal resting BP - appropriate response.

Chest Pain: none.

Arrhythmias: none.

ST Changes: none.

Overall impression: Normal stress test.

Conclusions:

TMT is negative for inducible ischemia.


Dr. VIMMI GOEL
MBBS, MD
Sr. Consultant Non Invasive Cardiology
Reg. No. 2014/01/0113

MR. KAMALKAR BORKAR
Male

13-Jan-24 1:15:24 PM
KIMS-KINGSWAY HOSPITALS

51 Years

PBC DEPT.

Rate 71 : Sinus rhythm.....normal P axis, V-rate 50- 99
ST elev, probable normal early repol pattern.....ST elevation, age<55

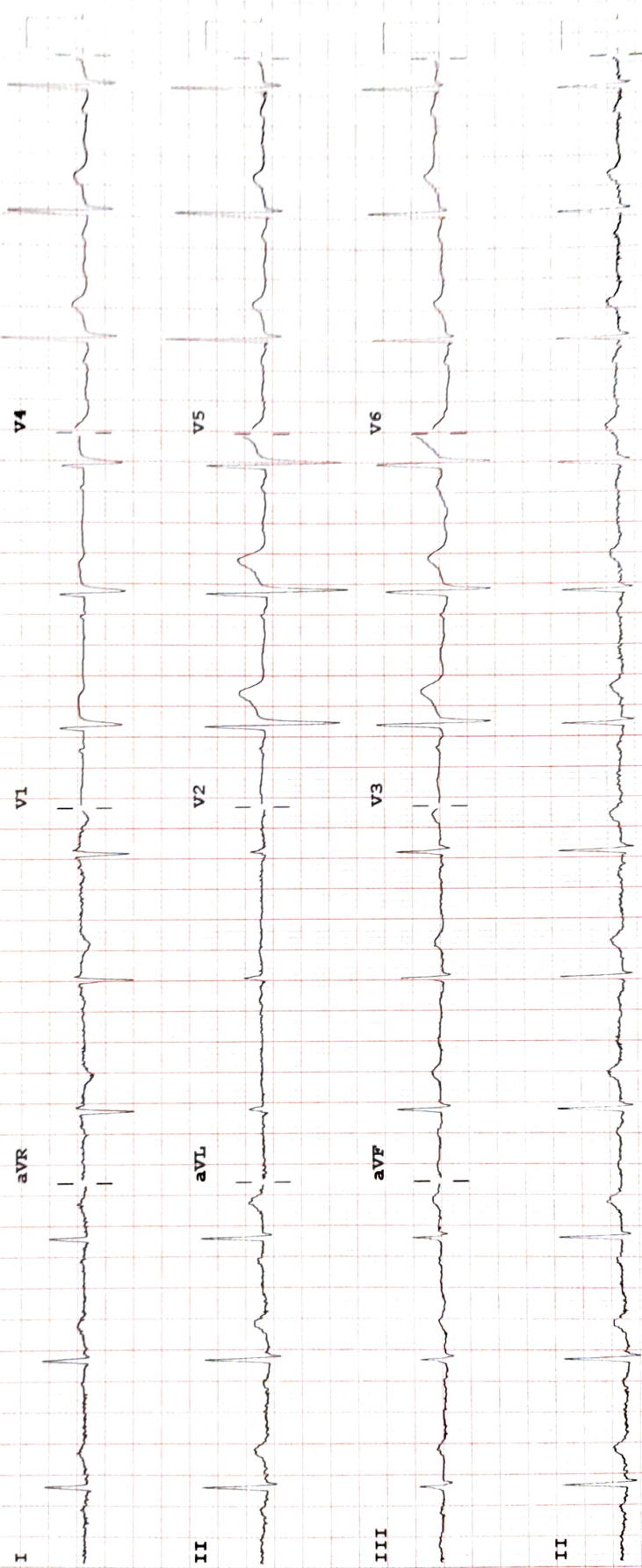
PR 157
QRSd 87
QT 369
QTc 401

--AXIS--
P 41
QRS 47
T 54

12 Lead; Standard Placement

- NORMAL ECG -

Unconfirmed Diagnosis



Device:

Speed: 25 mm/sec

Limb: 10 mm/mV

Chest: 10.0 mm/mV

F 50~ 0.50-150 Hz W

100B CL

P?