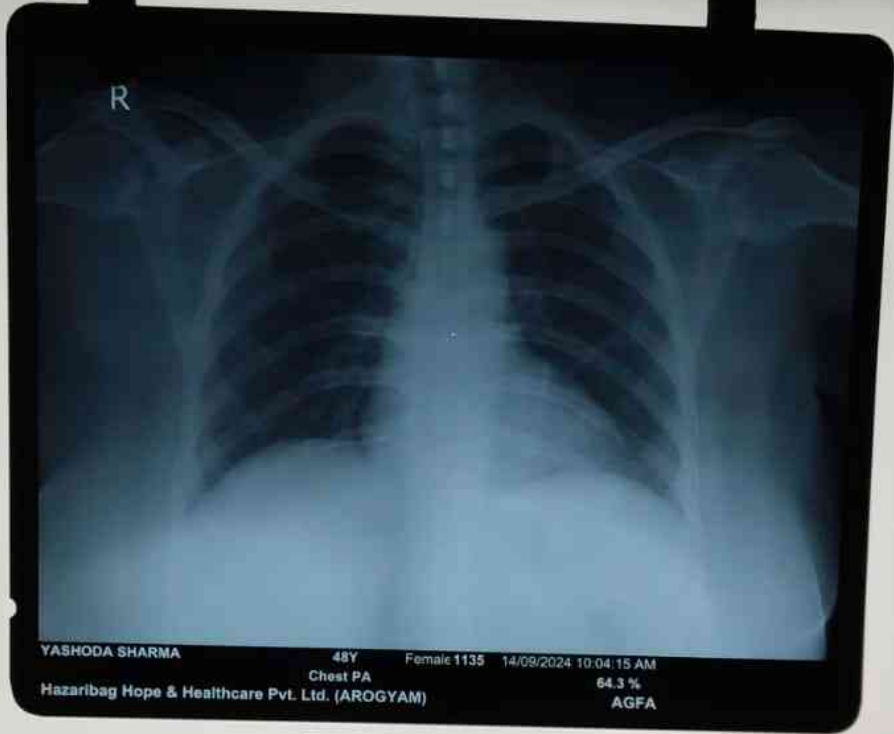





Super Speciality Hospital
(A Unit of Hazaribag Hope and Health Care Pvt. Ltd.)

HZB AROGYAM SUPER SPECIALITY HOSPITAL

ECHOCARDIOGRAPHY REPORT

Name: YASHODA SHARMA 48 YRS,

Age:

PRN

No: YASHO91_07655

Sex: Female

Date: 14/09/2024

2D & M-MODE MEASUREMENTS

IVSd	0.9 cm
LVIDd	4.2 cm
LVPWd	0.9 cm
IVSs	1.1 cm
LVIDs	2.8 cm
LVPWs	1.1 cm
Ao Diam	1.8 cm
LA Diam	3.1 cm

2D & M-MODE CALCULATIONS

EDV(Teich)	78 ml
ESV(Teich)	30 ml
EF(Teich)	61 %
%FS	33 %
SV(Teich)	48 ml
RWT	0.42
LA/Ao	1.76

MITRAL VALVE

MV E Vel	0.63 m/s
MV DecT	231 ms
MV Dec Slope	2.7 m/s ²
MV A Vel	0.78 m/s
MV E/A Ratio	0.81
E' Sept	0.06 m/s
E/E' Sept	10.21

AORTIC VALVE

TRICUSPID VALVE

TR Vmax	2.48 m/s
TR maxPG	24.58 mmHg

PULMONARY VALVE


COMMENTS:

NO RWMA
NORMAL VALVES
NO MR / AR / PR
NO PAH / TR
NORMAL LV SYSTOLIC AND DIASTOLIC FUNCTION, LVEF-61%
NO EFFUSION / THROMBUS / VEGETATION

FINAL IMPRESSION:

NORMAL ECHO STUDY




DR. RAVI RANJAN
MD(PHYSICIAN)
DIP. CARDIOLOGY

Address :- Zila Parisad Bhawan, District Board Chowk, Hazaribag - 825301 (Jharkhand)

☎ 06546-260500/501 ☎ 7319942219 ☎ hzbarogyam@gmail.com ☎ www.hzbarogyam.com

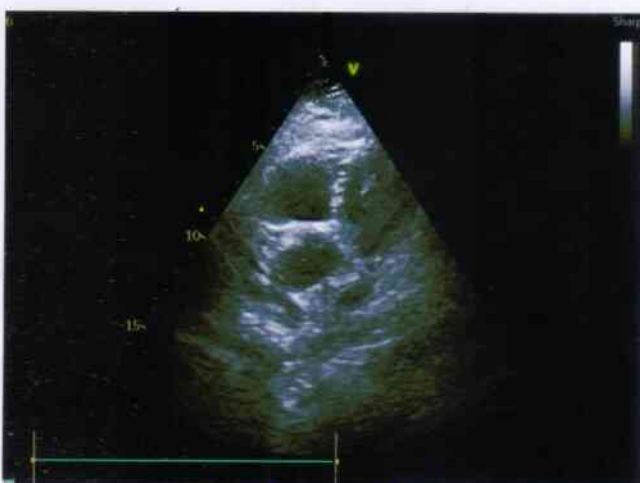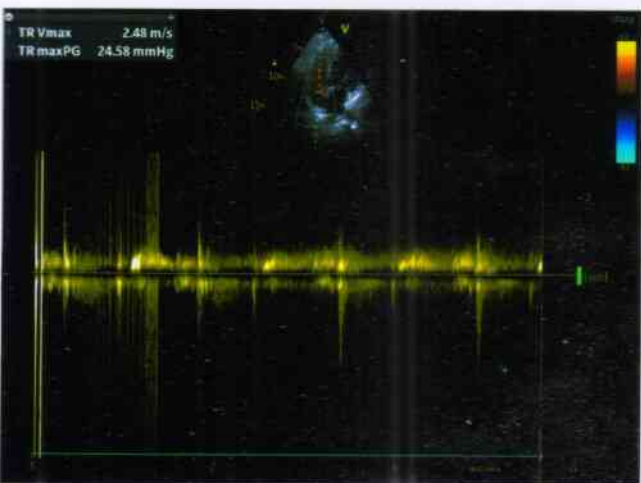
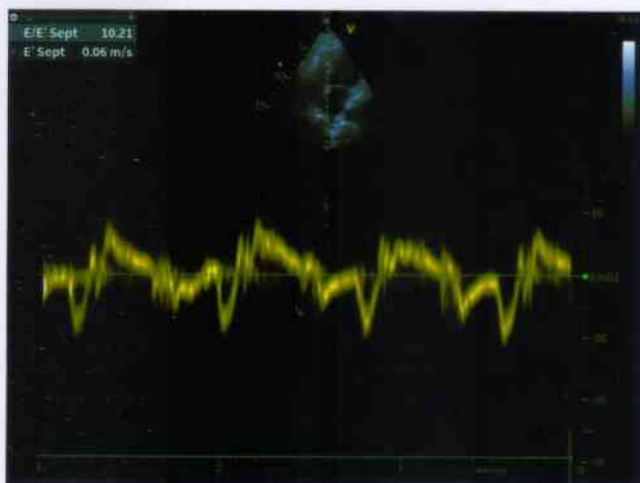
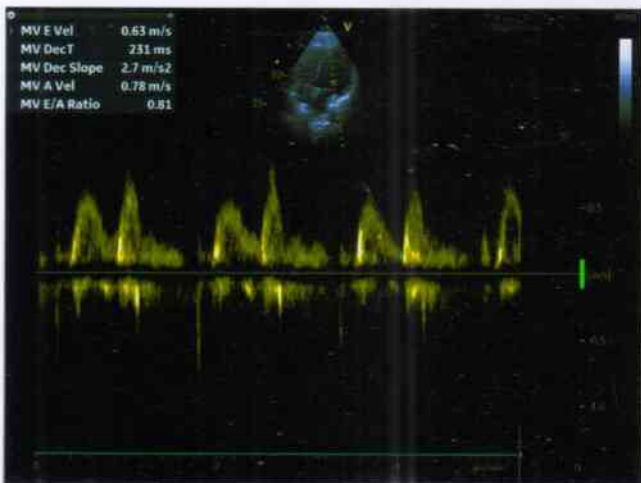
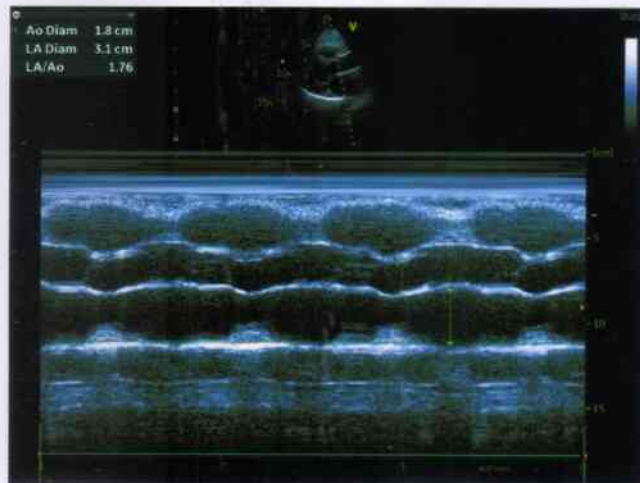
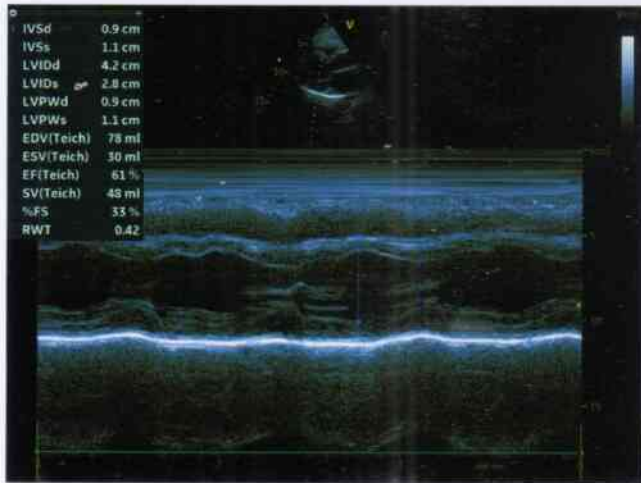
HZB AROGYAM SUPER SPECIALITY HOSPITAL

Name : YASHODA SHARMA 48 YRS,

Age :

Sex : Female

Date : 14/09/2024



Print Date: 14/09/2024



Super Speciality Hospital
(A Unit of Hazaribag Hope and Health Care Pvt. Ltd.)

Name of patient : YashodaSharma Age :48yrs Sex : F Date : 14/09/2024
Referred by : MO Arogyam
Indication : Pain abd.
Technique : 3.5 MHz transabdominal transducer with color and multiherz options.
USG of : Whole abdomen.
This ultrasonographic study reveals,

LIVER : Normal in size (133.0mm).Parenchymal echotexture is normal.No SOL or focal lesion seen in hepatic parenchyma.Intrahepatic biliary redicals is not dilated.

GALL BLADDER : Contracted (P.P).
CBD : Normal in coarse and caliber.

SPLEEN : Normal in size in bipolar length.It shows normal echogenicity of its parenchyma.
The splenic vein is not dilated.

PANCREAS : Normal in shape,size and echotexture.No cystic or mass lesion seen.PD is not dilated.

UPPER RETROPERITONEUM : Aorto-mesentric angle and surrounding structure shows no lymphadenopathy.
UPPER GI TRACT :Gastro-esophagal junction, pyloro-duodenal regionand jejunal loops appears normal.

RIGHT KIDNEY : Normal in size.Cortical echotexture appears normal.Pelvi-calyceal system of right kidney is not dilated.Cortico medullary differentiation intact.Hilum is normal shows normal flow.Capsule appears regular margine.No calculus or mass lesion seen in right kidney.

LEFT KIDNEY : Normal in size.Cortical echotexture appears normal.Pelvi-calyceal system of left kidney is not dilated.Cortico medullary differentiation intact.Hilum is normal shows normal flow.Capsule appears regular margine.No calculus or mass lesion seen in left kidney.

URETERS : B/L ureter are not dilated,Hence not visualized.

UBL : Wall appears normal in thickness and smoothness.Lumen appears echofree.

UTERUS : Normal in size(89.4 x 40.2 mm).Anteverted in position.Endometrium appears normal.
Myometrium appears normal.Cervix appears echogenic.No fibromyoma is seen.

OVARY : B/L ovary appears within normal limit.No adnexal lesion seen.

OTHERS : No ascites or pleural effusion is seen.

IMPRESSION : *This ultrasonographic study reveals. --Normal size uterus with echogenic cervix.-- Cervicitis.
* Otherwise normal study of whole abdomen.

SUGGESTION :-Correlate clinically.

The reliability of ultrasound is about 80%.The opinion mention above should be correlate with clinical findings and other investigation modality for a final diagnosis.This is not valid for medical legal purpose.

Dr. Ravikant
MBBS (RIMS) DMRD (MMC,CHENNAI)
Reg.No -4270



SONOLOGIST

Address :- Zila Parisad Bhawan, District Board Chowk, Hazaribag - 825301 (Jharkhand)

☎ 06546-260500/501 ☎ 7319942219 ☎ hzbarogyam@gmail.com ☎ www.hzbarogyam.com



Super Speciality Hospital
(A Unit of Hazaribag Hope and Health Care Pvt. Ltd.)

Name of patient : YashodaSharma Age :48yrs Sex : F Date : 14/09/2024
Referred by : MO Arogyam
Indication : Pain
Technique : 7.5 MHz linear transducer with color and multiherz options.

USG OF : B/L breast

RIGHT BREAST :Focal fatty infiltration of about 23.6 x 15.1 mm seen in right axillia. Prominent fibroglandular parenchyma is seen.All the four quadrants, nipple and areola appears within normal limit.

LEFT BREAST :All the four quadrants, axilliary tail, nipple and areola appears within normal limit. **Prominent fibroglandular parenchyma is seen.**

No calcification or mass lesion seen in B/L breast parenchyma.No lymphadenopathy could visualised.

IMPRESSION :-*This ultrasonographic study reveals, -- **Prominent fibroglandular parenchyma seen in b/l breast with focal fatty infiltration seen in right axillia.**

SUGGESTION :- Correlate clinically.

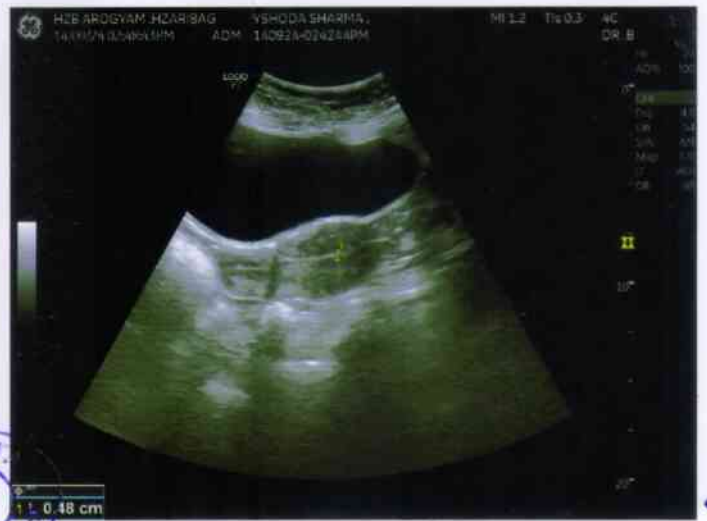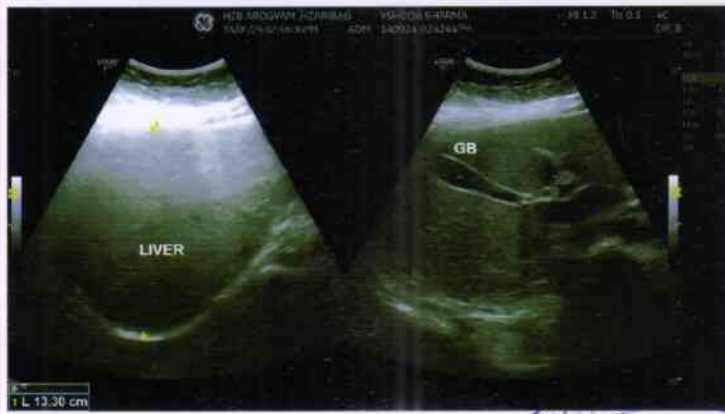
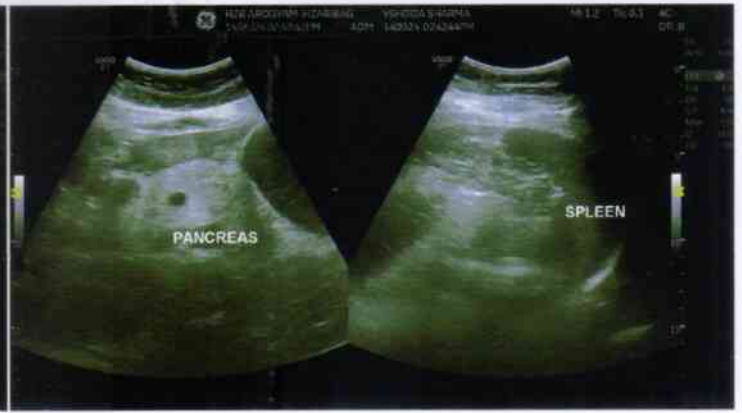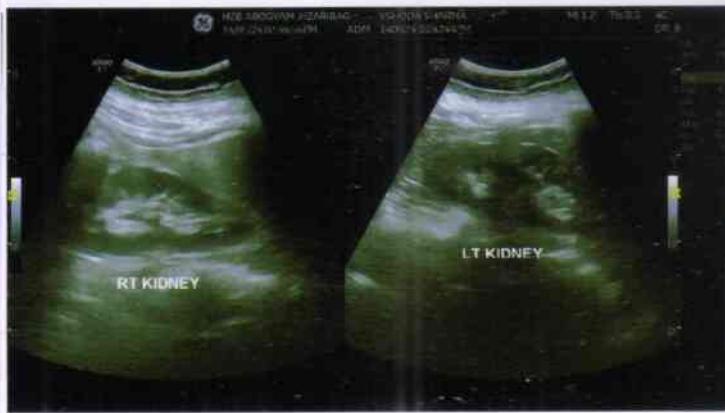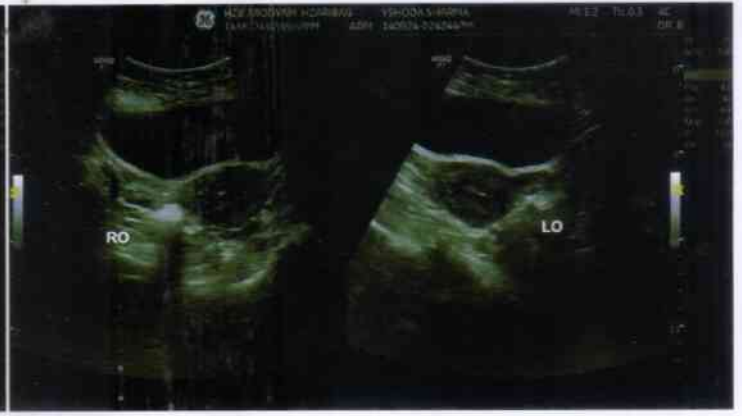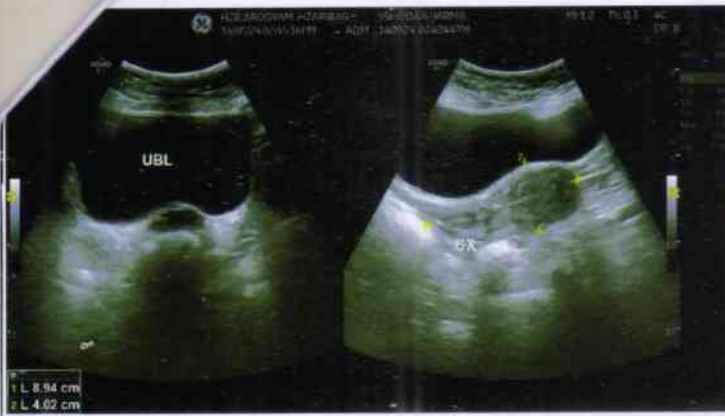The reliability of ultrasound is about 80%. The opinion mention above should be correlate with clinical findings and other investigation modality for a final diagnosis.This is not valid for medico-legal purpose.


SONOLOGIST

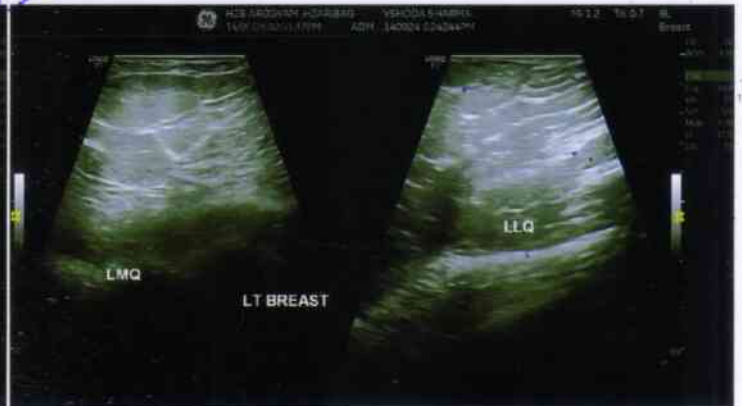
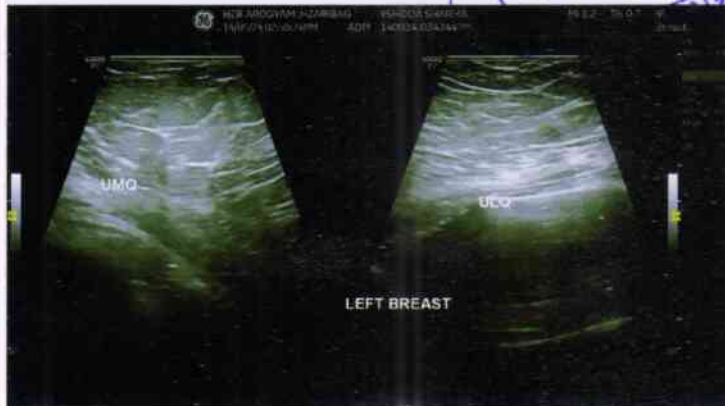

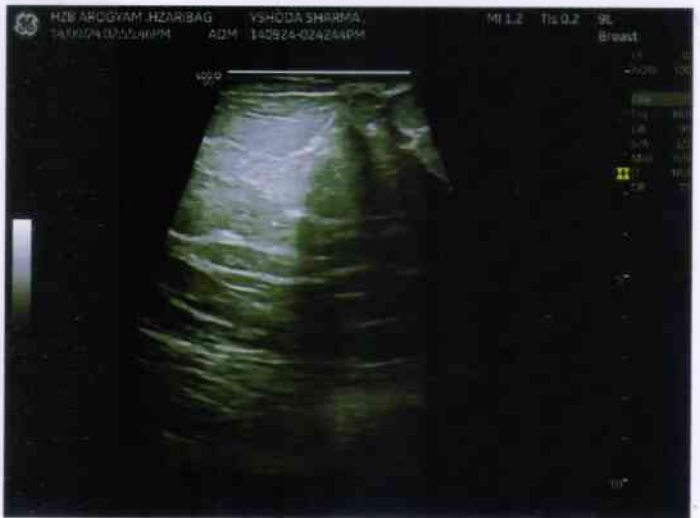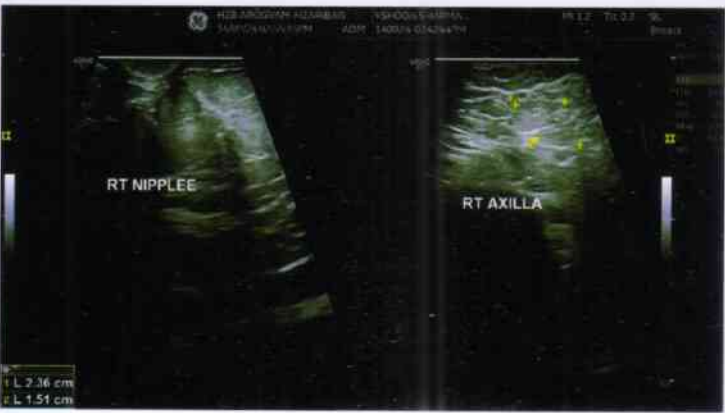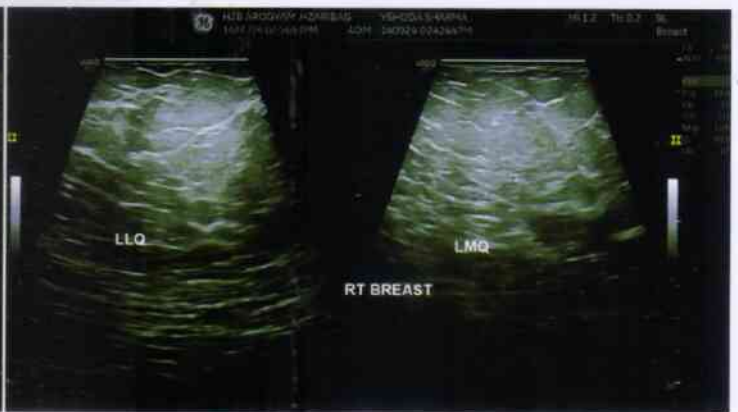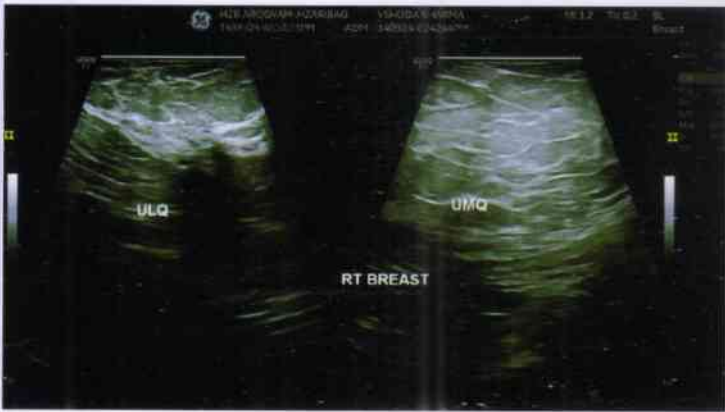
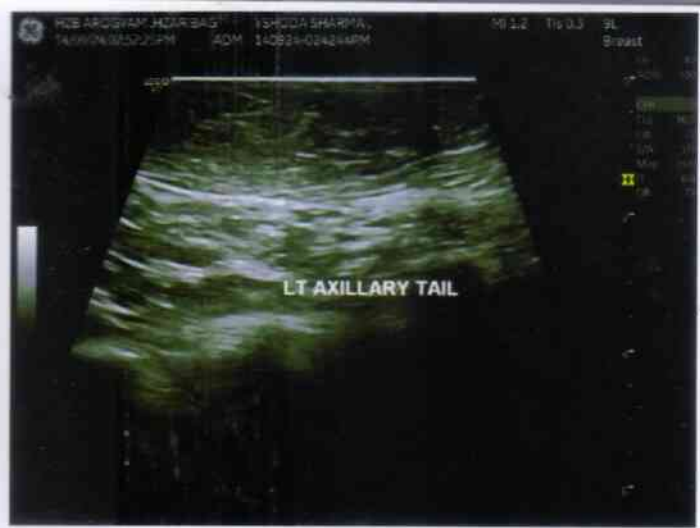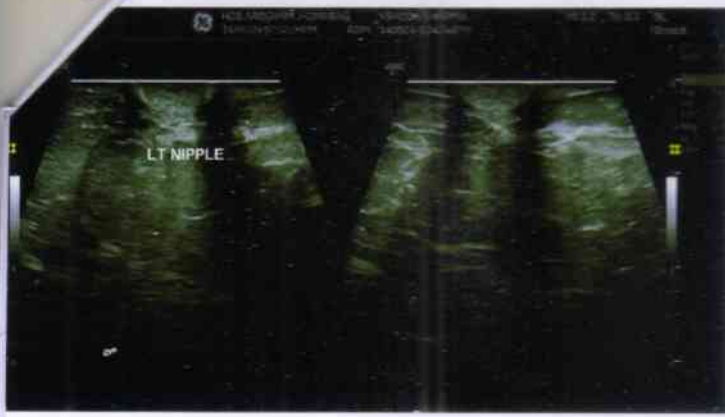Address :- Zila Parisad Bhawan, District Board Chowk, Hazaribag - 825301 (Jharkhand)

☎ 06546-260500/501 📞 7319942219 ✉ hzbarogyam@gmail.com 🌐 www.hzbarogyam.com



HZBAROC
Arogyam







Super Speciality Hospital
(A Unit of Hazaribag Hope and Health Care Pvt. Ltd.)



HZB7 140924

Name : MRS. YASHODA SHARMA
Sent By : M/O AROGYAM HOSPITAL
Ref. By : M/O AROGYAM

LAB ID : HZB7
Age/Sex : 48 Yrs. / F
Printed : 16/09/2024 09:44:49

Sample Collection : 14/09/2024 11:25:04
Sample Received : 14/09/2024 11:25:04
Report Released : 14/09/2024 15:00:31

T3T4TSH (THYROID FUNCTION TEST)

Test	Result	Unit	Biological Ref. Range
Total T3	1.42	ng/ml	0.69-2.15 ng/ml
<i>Serum, Method: CLIA</i>			
Total T4	11.20	µg/dl	4.5-14.5 µg/dl
<i>Serum, Method: CLIA</i>			

TSH (Thyroid Stimulating Hormone)	2.82	µIU/ml	0.30-4.50 µIU/ml
<i>Serum, Method: CLIA</i>			

NOTE	MAGLUMI 800 (SNIBE)		
-------------	----------------------------	--	--

FOR PREGNANT WOMEN	T3 (ng/dl)	T4 (ng/dl)	TSH (uIU/ml)
1st TRIMESTER	71-175	6.5-10.1	0.05-3.70
2st TRIMESTER	91-195	7.5-10.3	0.31-4.35
3st TRIMESTER	104-182	6.3-9.7	0.41-5.18

(Collected At: 14/09/2024 11:25:04, Received At: 14/09/2024 11:25:04, Reported At: 14/09/2024 15:00:31)

----- End Of Report -----



Anjana

Dr. Anjana
MBBS, MD(Patho),RIMS



Address :- Zila Parisad Bhawan, District Board Chowk, Hazaribag - 825301 (Jharkhand)

☎ 06546-260500/501 ☎ 7319942219 ☎ hzbarogyam@gmail.com ☎ www.hzbarogyam.com



Super Speciality Hospital
(A Unit of Hazaribag Hope and Health Care Pvt. Ltd.)



Name: MRS. YASHODA SHARMA
Age/Sex: 48 Years / Female
Referrer: DR. HZB AROGYAM HOSPITAL

UHID: ASH-2425-1135
Case No: H545

Registered On: 14-09-2024 10:14 AM
Collected On: 14-09-2024 10:34 AM
Received On: 14-09-2024 10:34 AM
Reported On: 14-09-2024 12:31 PM

Haematology

TEST	VALUE	UNIT	REFERENCE
CBC			
BLOOD COUNT & INDICES			
Hemoglobin	13.6	g/dL	12.5-15.0 g/dL
Total Leucocytes Count	6820	/cumm	4000-11000 /cumm
Total RBCs	4.5	10 ⁶ /μL	4.2-5.5 10 ⁶ /μL
HCT (PCV)	41	%	37-47 %
R.D.W. - CV	14	%	12-15%
R.D.W. - SD	45	fL	39-46 fL
MCH	30.22	pg	27-32 pg
MCHC	33.17	g/dL	32.5-36 g/dL
MCV	91.11	fL	80-96 fL
Platelet			
Platelet Count	1.55	/ul	1.5-4.5 /ul
MPV	12	fL	3-12 fL
DIFFERENTIAL WBC COUNT			
Neutrophils	52	%	40-70 %
Lymphocytes	34	%	18-40 %
Monocytes	08	%	2-10 %
Eosinophils	06	%	1-6 %
Basophils Percentage	00	%	0-1 %
Neutrophils - Absolute Count	3546.40	/cmm	1500 - 8000 / cmm
Lymphocytes - Absolute Count	2318.80	/cmm	1000-4800 / cmm
Monocytes - Absolute Count	H 545.60	/cumm	40-440 /cumm
Eosinophils - Absolute Count	409.20	/cumm	0-800 /cumm
@TOTAL	100.00		

please co related cilinicaly

Dr R.K Mahali

Dr R.K Mahali
MBBS, MD (RIMS, RANCHI)



Anajana

Dr. Anajana
MBBS, MD(Patho), RIMS

Biochemist Signature

Pathologist Signature

Address :- Zila Parisad Bhawan, District Board Chowk, Hazaribag - 825301 (Jharkhand)

06546-260500/501 7319942219 hzbarogyam@gmail.com www.hzbarogyam.com



Super Speciality Hospital
(A Unit of Hazaribag Hope and Health Care Pvt. Ltd.)



Name: MRS. YASHODA SHARMA
Age/Sex: 48 Years / Female
Referrer: DR. HZB AROGYAM HOSPITAL

UHID: ASH-2425-1135 Registered On: 14-09-2024 10:14 AM
Case No: H545 Collected On: 14-09-2024 10:34 AM
Received On: 14-09-2024 10:34 AM
Reported On: 14-09-2024 12:31 PM

Haematology

TEST	VALUE	UNIT	REFERENCE
ESR (Westergreen)	10.0	mm/hr	0 - 29

HZB AROGYAM HOSPITAL

please co related cilinicaly



Dr R.K Mahali

Dr R.K Mahali
MBBS, MD (RIMS, RANCHI)



Anajana

Dr. Anajana
MBBS, MD(Patho), RIMS

Biochemist Signature Address: Zila Parisad Bhawan, District Board Chowk, Hazaribag - 825301 (Jharkhand)

06546-260500/501 7319942219 hzbarogyam@gmail.com www.hzbarogyam.com



Super Speciality Hospital
(A Unit of Hazaribag Hope and Health Care Pvt. Ltd.)



Name: MRS. YASHODA SHARMA
Age/Sex: 48 Years / Female
Referrer: DR. HZB AROGYAM HOSPITAL

UHID: ASH-2425-1135
Case No: H545

Registered On: 14-09-2024 10:14 AM
Collected On: 14-09-2024 10:34 AM
Received On: 14-09-2024 10:34 AM
Reported On: 14-09-2024 12:31 PM

Biochemistry

TEST	VALUE	UNIT	REFERENCE
LIPID PROFILE			
Serum Cholesterol(Total)	L 152		Desirable: <200 Borderline high = 200-239 High: > 240
Serum Triglyceride(TG)	175	mg/dl	
HDL Cholesterol	55	mg/dl	30-80 mg/dl
LDL Cholesterol	L 62.00	mg/dl	Optimal: <100; Near Optimal: 100-129; Borderline High: 130-159; High: 160-189; Very high: >190
CHOL./HDL Chol. Ratio	L 2.76		Optimal: <3.5 Near Optimal: 3.5 - 5.0 High >5.0
Non HDL Cholestrol	97.00	mg/dL	0 - 160
TC/HDL Ratio	2.76		
VLDL	H 35.00	mg/dl	5 - 30
LDL Chol/HDL Chol Ratio	L 1.13	mg/dl	Optimal: <2.5 Near Optimal: 2.5-3.5 High >3.5
Total Lipid	582.34		350 - 750

Interpretation :

1. Triglycerides: When triglycerides are very high greater than 1000 mg/dL, there is a risk of developing pancreatitis in children and adults. Triglycerides change dramatically in response to meals, increasing as much as 5 to 10 times higher than fasting levels just a few hours after eating.
2. HDL-Cholesterol: HDL- C is considered to be beneficial, the so-called "good" cholesterol, because it removes excess cholesterol from tissues and carries it to the liver for disposal.

please co related cilinicaly

Dr R.K Mahali

Dr R.K Mahali
MBBS, MD (RIMS, RANCHI)

Biochemist Signature



Anajana
Dr. Anajana
MBBS, MD(Patho), RIMS
Pathologist Signature



Super Speciality Hospital
(A Unit of Hazaribag Hope and Health Care Pvt. Ltd.)



Name: MRS. YASHODA SHARMA
Age/Sex: 48 Years / Female
Referrer: DR. HZB AROGYAM HOSPITAL

UHID: ASH-2425-1135
Case No: H545

Registered On: 14-09-2024 10:14 AM
Collected On: 14-09-2024 10:34 AM
Received On: 14-09-2024 10:34 AM
Reported On: 14-09-2024 12:31 PM

Biochemistry

TEST	VALUE	UNIT	REFERENCE
LIVER FUNCTION TEST (LFT)			
BILIRUBIN			
Bilirubin Total	0.6	mg/dl	0-1.0 mg/dl
Bilirubin Direct	H 0.3	mg/dl	0-0.25 mg/dl
Bilirubin Indirect	0.30	mg/dl	0-0.55 mg/dl
ENZYMES			
SGPT	15	IU/L	0-42 IU/L
SGOT	20	IU/L	0 - 42
Alkaline Phosphatase	80	IU/L	80-190IU/L
SERUM PROTEIN			
Total Protein	7.5	g/dL	6.6-8.3 g/dl
Albumin	4.0	g/dL	3.5-5.0 g/dl
Globulin	3.50	g/dL	2.3-3.5 g/dl
A/G Ratio	1.14		0.90-2.00

Interpretation :

- In an asymptomatic patient, Non-alcoholic fatty liver disease (NAFLD) is the most common cause of increased AST, ALT levels. NAFLD is considered as hepatic manifestation of metabolic syndrome.
- In most types of liver disease, ALT activity is higher than that of AST; exception may be seen in Alcoholic Hepatitis, Hepatic Cirrhosis, and Liver neoplasia. In a patient with Chronic liver disease, AST: ALT ratio>1 is highly suggestive of advanced liver fibrosis.
- In known cases of Chronic Liver disease due to Viral Hepatitis B & C, Alcoholic liver disease or NAFLD, Enhanced liver fibrosis (ELF) test may be used to evaluate liver fibrosis.
- In a patient with Chronic Liver disease, AFP and Des-gamma carboxyprothrombin (DCP)/PIVKA II can be used to assess the risk for the development of Hepatocellular Carcinoma.

please co related clinically

Dr R.K Mahali

Dr R.K Mahali
MBBS, MD (RIMS, RANCHI)
Biochemist, Signature



Dr. Anejana
MBBS, MD(Patho), RIMS
Pathologist Signature



Super Speciality Hospital
(A Unit of Hazaribag Hope and Health Care Pvt. Ltd.)



Name: MRS. YASHODA SHARMA
Age/Sex: 48 Years / Female
Referrer: DR. HZB AROGYAM HOSPITAL

UHID: ASH-2425-1135
Case No: H545

Registered On: 14-09-2024 10:14 AM
Collected On: 14-09-2024 10:34 AM
Received On: 14-09-2024 10:34 AM
Reported On: 14-09-2024 12:31 PM

Biochemistry

TEST	VALUE	UNIT	REFERENCE
KFT(Kidney Function Test)			
Urea	25	mg/dl	10.0 - 45.0 mg/dl
Method:	Urease-GLDH, Fixed Time		
Creatinine	0.8	mg/dl	0.7-1.5 mg/dl
Method:	enzymatic		
BUN/Creatinine ratio	H 31.25	mg/dl	5-20 mg/dl
Method:	calculation		
Uric Acid	3.8	mg/dl	3.4-7.0 mg/dl
Method:	Uricase-Toos		
S. Sodium	148.0	meq/L	135-155 meq/L
Method:	(abl800)		
S. Potassium	4.3	meq/L	3.5-5.3 mEq/L
Method:	RADIOMETER(abl800)		
S. Calcium	9.8	mg/dl	8.7-11.0 mg/dl
Method:	RADIOMETTER(abl800)		

please co related cilinicaly

Dr R.K Mahali
MBBS, MD (RIMS, RANCHI)



Dr. Anajana
MBBS, MD (Patho), RIMS

Biochemist Signature: Dr. Parisad Bhawan, District Board Chowk, Hazaribag - 825301 (Jharkhand) Pathologist Signature

06546-260500/501 7319942219 hzbarogyam@gmail.com www.hzbarogyam.com



Super Speciality Hospital
(A Unit of Hazaribag Hope and Health Care Pvt. Ltd.)



Name: MRS. YASHODA SHARMA
Age/Sex: 48 Years / Female
Referrer: DR. HZB AROGYAM HOSPITAL

UHID: ASH-2425-1135 Registered On: 14-09-2024 10:14 AM
Case No: H545 Collected On: 14-09-2024 10:34 AM
Received On: 14-09-2024 10:34 AM
Reported On: 14-09-2024 12:31 PM

Biochemistry

TEST	VALUE	UNIT	REFERENCE
POST PRANDIAL BLOOD SUGAR			
Post Prandial Blood Sugar	H 180.0	mg/dl	0 - 140
Blood Sugar Fasting	H 115	mg/dl	70-110

HZB AROGYAM HOSPITAL

please co related cilinicaly

Dr R.K Mahali

Dr R.K Mahali
MBBS, MD (RIMS, RANCHI)



Dr. Anajana
Dr. Anajana
MBBS, MD(Patho), RIMS

Address: Elite Parisad Bhawan, District Board Chowk, Hazaribag - 825301 (Jharkhand)

06546-260500/501 7319942219 hzbarogyam@gmail.com www.hzbarogyam.com



Super Speciality Hospital
(A Unit of Hazaribag Hope and Health Care Pvt. Ltd.)



Name: MRS. YASHODA SHARMA
Age/Sex: 48 Years / Female
Referrer: DR. HZB AROGYAM HOSPITAL

UHID: ASH-2425-1135
Case No: H545

Registered On: 14-09-2024 10:14 AM
Collected On: 14-09-2024 10:34 AM
Received On: 14-09-2024 10:34 AM
Reported On: 14-09-2024 12:31 PM

Serology & Immunology

TEST	VALUE	UNIT	REFERENCE
Blood Group & Rh			
Blood Group			
ABO	AB		
H Factor	POSITIVE		

HZB AROGYAM HOSPITAL

please co related cilinicaly

Dr R.K Mahali
MBBS, MD (RIMS, RANCHI)



Dr. Anajana
MBBS, MD(Patho), RIMS

Address: Zila Parisad Bhawan, District Board Chowk, Hazaribag - 825301 (Jharkhand)

06546-260500/501 7319942219 hzbarogyam@gmail.com www.hzbarogyam.com



Super Speciality Hospital
(A Unit of Hazaribag Hope and Health Care Pvt. Ltd.)



Name: MRS. YASHODA SHARMA
Age/Sex: 48 Years / Female
Referrer: DR. HZB AROGYAM HOSPITAL

UHID: ASH-2425-1135 Registered On: 14-09-2024 10:14 AM
Case H545 Collected On: 14-09-2024 10:34 AM
No: Received On: 14-09-2024 10:34 AM
Reported On: 14-09-2024 12:31 PM

Clinical Pathology

TEST	VALUE	UNIT	REFERENCE
URINE ROUTINE EXAMINATION			
PHYSICAL EXAMINATION..			
Quantity	20ML		
Colour	STRAW		
Specific Gravity	1.010		1 - 1.03
Transperancy	CLEAR		
Chemical Examination(URINE)			
PH	6.0		
Sugar	NIL		
Albumin	NIL		
Bile Salt	NEGATIVE		
Bile Pigment	NEGATIVE		
ketones	NEGATIVE		
Occult Blood	NEGATIVE		
MICROSCOPIC EXAMINATION(URINE)			
Pus Cells	0-2	Cells / hpf	
Epithelial cells	A FEW	Cells / hpf	
RBC	NIL	Cells / hpf	
Casts	NIL		
Crystals	NIL		
Bacteria	NIL		
Yeast Cells	NIL		
Other findings	NIL		

~ End Of Report ~

please co related cilinicaly

Dr R.K Mahali
MBBS, MD (RIMS, RANCHI)

Biochemist Signature



Dr. Anajana
MBBS, MD(Patho), RIMS

Pathologist Signature

Address :- Zila Parisad Bhawan, District Board Chowk, Hazaribag - 825301 (Jharkhand)

06546-260500/501 7319942219 hzbarogyam@gmail.com www.hzbarogyam.com

Prescription of glass for cont. use:

for DV:

R/E: - 0.50 Dyl x 160° - 6/6

Y/E: Plano glass - 6/6

for NV:

Add to above

R/E: + 1.50 Dyl - 20/6

Q



NAME

KUMAR

ISO 9001 : 2015 Certified Hospital

14_SEP_2024 AM 11:18
NO. 1411

Medical Retina



MULTI SPECIALITY HOSPITAL
(A Unit of Hazaribag Hope and Health Care Pvt. Ltd.)

SN: 4783835

REF. DATA

VD: 12.00 CYL: MIX

<R> S C A
+ 0.50 + 0.50 161
+ 0.50 + 0.50 161
+ 0.50 + 0.50 160
+ 0.50 + 0.50 161

-S. E. + 0.75
<L> S C A
+ 0.75
+ 0.75
+ 0.75
+ 0.75
S. E. + 0.75

PD: 57.5

TOPCON

HZB AROGYAM HOSPITAL

LIP

2024

22.04

Past History :-

Blood Pressure Pulse BMI

Chief complaints :-

yo - DV.
Watering

History & Examinations :-

6/9 (P)

⊙ K/yo DM2 on medication.

Vu < 6/6

O/E:

Ext - O/E - NAD
Fundus (O/E) = WNL.

Su
Hb, Ac

Ado
1) 2/3

Tearwet - (S/L)
o-o-o

2) T. Retinoid CX

1 x 1 - 30 2.



Dr. Jayesh

BDS, MDS (Oral & Maxillo Facial Surgery)

ISO 9001 : 2015 Certified Hospital



MULTI SPECIALITY HOSPITAL
(A Unit of Hazaribag Hope and Health Care Pvt. Ltd.)

OUT DOOR PATIENT SLIP

Date of Consultation :- 14/09/2024

Full Name :- Mrs Yashoda.

Age / Sex :- 48Y/P

Current Medications :-					Past History :-
Height	Weight	Blood Pressure	Pulse	BMI	

Chief complaints :- Pt has come for routine Dental check up

History & Examinations :- H/o Diabetes since yrs ↓ med.
o/e Ca ++ STT Cerebral
Restored $\frac{76}{67}$
DRC $\frac{8}{4}$ Buccal

OPG. , Scaling
- DOPA 1st $\frac{1}{45}$

Scaling
Ultrasoft brush 1-57
Stalin R. for the part 1-57
Hexidine m/wash 1-57x15day

Dr Jayesh



OUT DOOR PATIENT SLIP

Date of Consultation :- 14/09/24

Full Name :- Yashoda Sharma .

Age / Sex :- 47y / F

Current Medications :-				Past History :-	
				SPO ₂ .	
Height	Weight	Blood Pressure	Pulse	BMI	
		130/90 mmHg.	79/8	28.2	

Chief complaints :-

old pt. of D.M

History & Examinations :-

Diabetic Diet

R

1) Crestor 20 —
 • 1H at bed time.

2) Lipicard 160 —
 • 1H day at bed time.

3) Vdapa - M (10/1000) - 15 H
 • 1 H day

Monitor
Blood Sugar

Rajabertty
14/09/24



OUT DOOR PATIENT SLIP

Date of Consultation :- 14/09/2024

Full Name :- Rashmi Sharma

Age / Sex :- 47 / F

Current Medications :-					Past History :- KIDNEY T2DM (T. Glycemia T. hbA1c)
Height	Weight	Blood Pressure	Pulse	BMI	
		120/90	78		

Chief complaints :- Pt case for Cervical Root GWT examination on exam

History & Examinations :-
neck soft
→ lymphatic palpable
no tenderness
→ no neck rigidity

Provisional Diagnosis

Finds no of abnormality.
Pt is clinically fit in Cervical examination



Dr. Sudha Bhengra
MBBS, D.G.O.

ISO 9001 : 2015 Certified Hospital



MULTI SPECIALITY HOSPITAL
(A Unit of Hazaribag Hope and Health Care Pvt. Ltd.)

OUT DOOR PATIENT SLIP

Date of Consultation :- 14/09/2024

Full Name :- Yaswadey Sengupta

Age / Sex :- 48 yr / F

Current Medications :-					Past History :-
Height	Weight	Blood Pressure	Pulse	BMI	

Chief complaints :-

White discharge - 6 month
Pain waist -

History & Examinations :-

2 children - 19 yr / LSCS
15 yr

Scanty Menses
LMP - 12.9.24

Adv

Adv

F. Folli

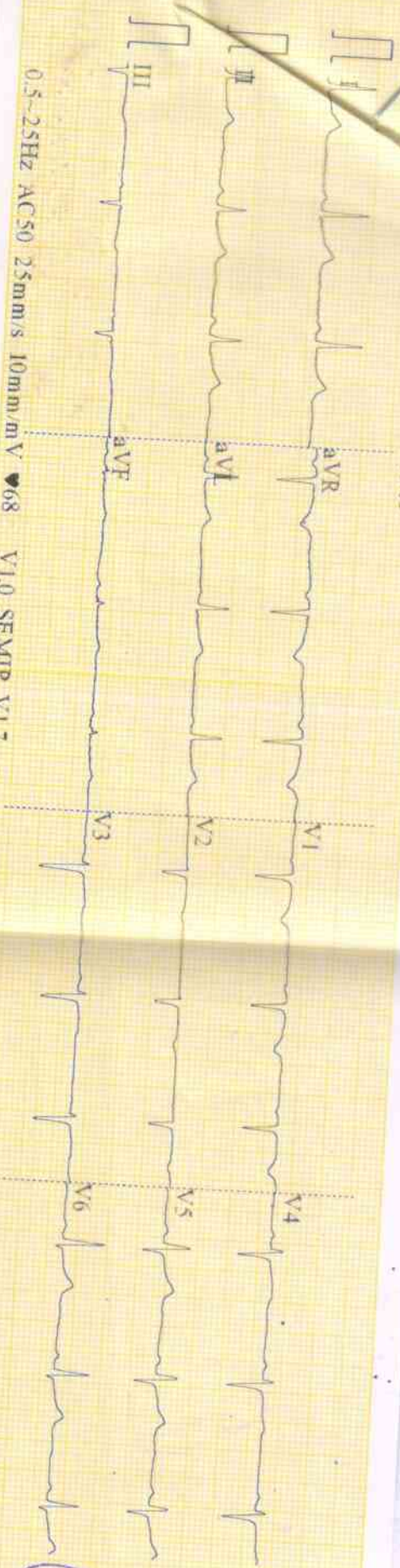
Pap Smear

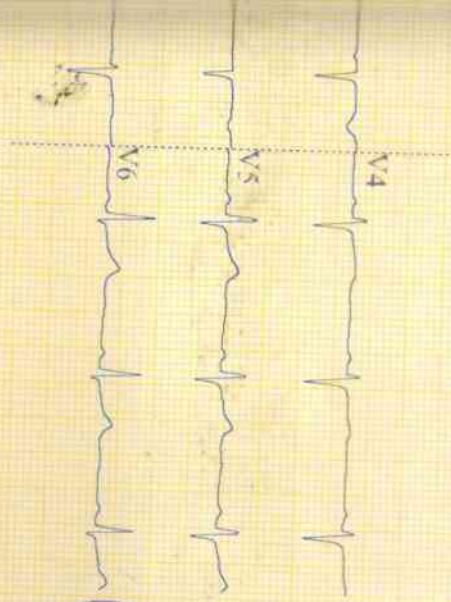


ID: JSS1012214 09-14-2024 10:18:09

0.5-25Hz AC50 25mm/s 10mm/mV 68 V1.0 SEMIP V1.7

Character





ID: 155102214

Male
Years

mmHg

kg

Diagnosis Information:
Sinus Rhythm
Suspect Anteroseptal Myocardial
Infarction?(V1, V2)
Flattened T Wave(V4)
Low Voltage(Chest Leads)

HR 68 bpm
PR 124 ms
QRS 71 ms
QTc 399.427 ms
PQRST 3911.26 °
RV5SV1 0.5220606 mV

Report Confirmed by:

Issue Date: 16/01/2012



Yeshoda Sharma
DOB: 31/05/1976
Female

4858 2221 0644

मेरा आधार, मेरी पहचान

Address: W/O Sanjay Kumar Sharma, Road No-8, Ward No-7, Nalapar, Kumhar Toll, Bhanupuri Chowk, Hazaribag, Hazaribagh, Jharkhand, 825301



4858 2221 0644

1947 help@uidai.gov.in www.uidai.gov.in

Sanjayksharma3172@gmail.com

Yeshoda Sharma