



# PANACEA HOSPITAL

B 36/44 F.K KABIR NAGAR, DURGAKUND  
TOLLFREE NO-18001233070. Whatsapp No - 8795832852  
www.piire.org  
panaceaquery@gmail.com|panaceahospitalit@gmail.com



## OP Slip

Print Date : 21-Mar-2024 10:34AM



UHID No :- UD-23240007009      OP No :- OP-23240021489      OP Date :- 21 Mar 2024 10:33AM  
 Patient Name :- Mr SHARDESHWAR MISHRA      Age/Sex :- 50 Y/Male      Mobile No :- 9415359759  
 Father :- LATE KRISHNA PRASAD MISHRA      Department :- GENERAL MEDICINE  
 Pay Type :- Cr      Consultant :- Dr Pallavi Mishra (MBBS,MD,MBBS)  
 Token No :- NOR. - 2      Paid/Bal :- 0.00 /1000.00  
 Patient Type :- Normal  
 Address :- FLAT NO 222 SECOND FLOOR D BLOC K RUDRA TOWER APPARTEMENT KARAMJEETPUR SUNDAERPUR  
 PO: HINDU VISHWA VIDHYALAYA ,varanasi

BP 110/80  
 height :- 179  
 Weight (kg) :- 99.4  
 BMI :-  
 WC 113  
 NC 42  
 CH 106  
 SpO2 96  
 PR 70  
 PPRK 430

Rx

Δ Diabetes  
 • Dyslipidemia  
 • HbA1c

✓  
 Pr 21.28

Tab. Diabimorone 1um  
 Ts. Atorvastatin 20mg A/D  
 Ts. Zestoretic 1um  
 Ts. Amlo 5mg

*[Signature]*  
 DR. Pallavi Misra  
 MBBS, MD(GENERAL MEDICINE)  
 MCI Reg. No.52033

Printed By : Ms. Anjali Prajapati

Created By : Ms. Anjali Prajapati



# PANACEA HOSPITAL

B 36/44 F.K KABIR NAGAR, DURGAKUND  
TOLLFREE NO-18001233070. Whatsapp No - 8795832852  
www.piire.org  
panaceaquery@gmail.com|panceahospitalit@gmail.com



## OP Slip

Print Date : 21-Mar-2024 10:36AM



<b>UHID No</b> :- UD-23240007009	<b>OP No</b> :- OP-23240021489	<b>OP Date</b> :- 21 Mar 2024 10:33AM
<b>Patient Name</b> :- Mr SHARDESHWAR MISHRA	<b>Age/Sex</b> :- 50 Y/Male	<b>Mobile No</b> :- 9415359759
<b>Father</b> :- LATE KRISHNA PRASAD MISHRA	<b>Department</b> :- DENTAL	
<b>Pay Type</b> :- Cr	<b>Consultant</b> :- Dr SHRUTI MISHRA (AA)	
<b>Token No</b> :- NOR. - 2	<b>Paid/Bal</b> :- 0.00 /1000.00	
<b>Patient Type</b> :- Normal		
<b>Address</b> :- FLAT NO 222 SECOND FLOOR D BLOC K RUDRA TOWER APPARTEMENT KARAMJEETPUR SUNDAERPUR PO: HINDU VISHWA VIDHYALAYA ,varanasi		

**BP** :-  
**height** :-  
**Weight (kg)** :-  
**BMI** :-

**Rx** c/c - Patient came for routine dental Checkup.

c/c. Calculus / stains + +  
proximal caries + +

r/c - polishing & scaling  
used gum paint & mouth  
wash

**Dr. SHRUTI MISHRA**  
BDS, (DENTIST)  
MCI Reg. No. (A-09784)

Printed By : Ms. Anjali Prajapati

Created By : Ms. Anjali Prajapati



# PANACEA HOSPITAL

B 36/44 F.K KABIR NAGAR, DURGAKUND  
TOLLFREE NO-18001233070. Whatsapp No - 8795832852  
www.piire.org  
panaceaquery@gmail.com|panaceahospitalit@gmail.com



## OP Slip

Print Date : 21-Mar-2024 10:34AM



UHID No :- UD-23240007009      OP No :- OP-23240021489      OP Date :- 21 Mar 2024 10:33AM  
 Patient Name :- Mr SHARDESHWAR MISHRA      Age/Sex :- 50 Y/Male      Mobile No :- 9415359759  
 Father :- LATE KRISHNA PRASAD MISHRA      Department :- DERMATOLOGY  
 Pay Type :- Cr      Consultant :- Dr DR ASHUTOSH MISHRA (MBBS,MD)  
 Token No :- NOR. - 2      Paid/Bal :- 0.00 /1000.00  
 Patient Type :- Normal  
 Address :- FLAT NO 222 SECOND FLOOR D BLOC K RUDRA TOWER APPARTEMENT KARAMJEETPUR SUNDAERPUR  
 PO: HINDU VISHWA VIDHYALAYA ,varanasi

### Rx

BP :-  
 height :-  
 Weight (kg) :-  
 BMI :-

*Rx*

- Methocel long reb 2 reb @  
 $\frac{2 \text{ hr or } 1}{15 \text{ min } 25}$
- Methocel 10 r. lot 1  
 $\frac{5 \text{ min } 25}{\text{then wash}}$
- Arthropin 50mg reb  
 $\frac{1 \text{ or } 2}{\text{step}}$
- Tracolum cream C:
- neem soap
- Blood purifier but low < 15

*Ads*  
 ① Pankaj Singh  
 ② LPT  
 ③ RFT



Printed By : Ms. Anjali Prajapati

Created By : Ms. Anjali Prajapati



# PANACEA HOSPITAL

B 36/44 F.K KABIR NAGAR, DURGAKUND  
TOLLFREE NO-18001233070. Whatsapp No - 8795832852  
www.piire.org  
panaceaquery@gmail.com|panaceahospitalit@gmail.com



## OP Slip

Print Date : 21-Mar-2024 10:35AM



UHID No :- UD-23240007009      OP No :- OP-23240021489      OP Date :- 21 Mar 2024 10:33AM

Patient Name :- Mr SHARDESHWAR MISHRA      Age/Sex :- 50 Y/Male      Mobile No :- 9415359759

Father :- LATE KRISHNA PRASAD MISHRA      Department :- OPHTHALMOLOGY

Pay Type :- Cr      Consultant :- Dr SANTOSH VERMA (MBBS,MS)

Token No :- NOR. - 2      Paid/Bal :- 0.00 /1000.00

Patient Type :- Normal

Address :- FLAT NO 222 SECOND FLOOR D BLOC K RUDRA TOWER APPARTEMENT KARAMJEETPUR SUNDAERPUR  
PO: HINDU VISHWA VIDHYALAYA ,varanasi

BP :-  
height :-  
Weight (kg) :-  
BMI :-

### Rx

VA { 6/6' --- 6/6      ✗  
      6/12' --- 6/6'      ✗

Neuv { +2.25 DS } N6.  
      +2.25 DS

BE:- Refractive error i presbyopia

φ BE

1-6. Oultance - Tos.

Printed By : Ms. Anjali Prajapati

Created By : Ms. Anjali Prajapati

Dr. SANTOSH VERMA  
MBBS, MS (Ophthalmology) Page 1 of 1  
MCI Reg. No. 09-34327

**Facilities:**

All clinical Biomedical & Hematology Investigations including Bone Marrow Examination  
VPT, Podiascan & Complete Foot Care (First Time in Purvanchal)  
All Hormonal Investigation by Chemiluminescent Method  
Visceral Fat by (AB-140) Ambulatory BP Monitoring  
CGMS & Insulin Pump Available  
PFT, 2D-ECHO (Color Doppler), Holter, TMT, Cardiac-3 available  
VIA, VILI, Colposcopy available  
Special Endocrinological Investigation Protocols.

ISO 9001:2008 Certified  
Mobile: 9389994334, 9554572190, 9453837595



# Panacea Pathology

## Clinical Reference Lab

Persistence, Preparedness and Precision  
EQAS (CMC Vellore Attached) & IQAS System  
पूर्वांचल की सर्वोत्तम गुणवत्ता वाली पैथोलॉजी

**UHID No** :- UD-23240007009 **Booking No/Date** :- 54 / 21-Mar-2024 12:48 PM  
**Patient Name** :- Mr SHARDESHWAR MISHRA **Age/Sex** :- 50 Y/M  
**Father** :- LATE KRISHNA PRASAD MISHRA **OP No** :- OP-23240021489  
**Address** :- FLAT NO 222 SECOND FLOOR D BLOC K RUDRA TOWER APPARTEMENT KARAMJEETPUR SUNDAERPUR PO: HINDU VISHWA VIDHYALAYA , varanasi **Mobile No** :- 9415359759  
**Consultant** :- Dr Pallavi Mishra (MBBS,MD)

### HAEMATOLOGY

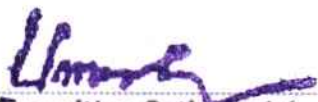
#### CBC

HAEMOGLOBIN <i>DefaultMethod / test Machine</i>	14.9	13.00 - 16.00	gm/dl
TLC <i>Methology / Carm</i>	7,800	4000.00 - 11000.00	Cells/cumm.
DLC DIFFERENTIAL LEUCOCYTE COUNT			
NEUTROPHILS	48	40.00 - 75.00	%
LYMPHOCYTES	38	20.00 - 45.00	%
EOSINOPHILS	06	1.00 - 6.00	%
MONOCYTES	08	2.00 - 10.00	%
BASOPHILS	00	<1-2	%
PLATELET COUNT	1.00	1.50 - 4.10	lacs /cumm
PCV	46.4	33.00 - 42.00	%
RBC <i>Methology / Carm</i>	4.91	4.50 - 5.50	million/cumm
MCV(MEAN CELL VOLUME)	94.4	83.00 - 101.00	fl
MCH(MEAN CELL HAEMOGLOBIN)	30.3	27.00 - 32.00	pg
MCHC	32.1	31.50 - 35.00	gm%
RDW-CV	13.6	11.00 - 16.00	%
RDW-SD	52.3	37.00 - 57.00	fl

Lab Technician

Timing : 24/7 hrs

This Report is not valid for medico legal purpose

  
Consulting Pathologist  
DR. UMESH KUMAR  
MBBS, MD (PATHOLOGY)  
MVA Pathology

Note: These tests have technical limitations. Clinico-pathological interpretation is necessary. In case of any disparity test may be repeated immediately.

Address : 36/44 FK Kabir Nagar, Durgakund, Varanasi – 221005

Email: [dramishra@gmail.com](mailto:dramishra@gmail.com), [drpallaviojha@gmail.com](mailto:drpallaviojha@gmail.com) Website: [panaceahospital.org](http://panaceahospital.org)

**Facilities:**

All clinical Biomedical & Hematology Investigations including Bone Marrow Examination  
 VPT, Podiascan & Complete Foot Care (First Time in Purvanchal)  
 All Hormonal Investigation by Chemiluminescent Method  
 Visceral Fat by (AB-140) Ambulatory BP Monitoring  
 CGMS & Insulin Pump Available  
 PFT, 2D-ECHO (Color Doppler), Holter, TMT, Cardiac-3 available  
 VIA, VILI, Colposcopy available  
 Special Endocrinological Investigation Protocols.

ISO 9001:2008 Certified  
 Mobile: 9389994334, 9554572190, 9453837595



# Panacea Pathology

## Clinical Reference Lab

Persistence, Preparedness and Precision  
 EQAS (CMC Vellore Attached) & IQAS System  
 पूर्वांचल की सर्वोत्तम गुणवत्ता वाली पैथोलॉजी

**UHID No** :- UD-23240007009 **Booking No/Date** :- 54 / 21-Mar-2024 12:48 PM  
**Patient Name** :- Mr SHARDESHWAR MISHRA **Age/Sex** :- 50 Y/M  
**Father** :- LATE KRISHNA PRASAD MISHRA **OP No** :- OP-23240021489  
**Address** :- FLAT NO 222 SECOND FLOOR D BLOC K RUDRA TOWER APPARTEMENT KARAMJEETPUR SUNDAERPUR PO: HINDU VISHWA VIDHYALAYA , varanasi **Mobile No** :- 9415359759  
**Consultant** :- Dr Pallavi Mishra (MBBS,MD)

### URINE EXAMINATION

#### URINE ROUTINE EXAMINATION

##### PHYSICAL EXAMINATION

QUANTITY	25	ml
COLOR <i>Methology</i>	STRAW	CLEAR YELLOW
APPEARANCE <i>DefaultMethod</i>	CLEAR	CLEAR

##### CHEMICAL EXAMINATION

SPECIFIC GRAVITY	1.015	1.01 - 1.03
PH	5.5	4.60 - 8.00
GLUCOSE	NIL	60.00 - 100.00 mg/dl
PROTEIN-	NIL	

##### MICROSCOPIC EXAMINATION

PUS CELLS	NIL	2.00 - 3.00 /HPF
RBCS ( RED BLOOD CELLS)	NIL	4.50 - 5.50 /HPF
EPITHELIAL CELLS	01-02	/HPF
CASTS	ABSENT	ABSENT
CRYSTALS	ABSENT	ABSENT

Lab Technician

Consulting Pathologist

DR. UMESH KUMAR  
 MBBS, MD (PATHO)  
 MCI Reg. No. 41

Timing : 24/7 hrs

This Report is not valid for medico legal purpose

Note: These tests have technical limitations. Clinico-pathological interpretation is necessary. In case of any disparity test may be repeated immediately.

Address : 36/44 FK Kabir Nagar, Durgakund, Varanasi – 221005

Email: [dramishra@gmail.com](mailto:dramishra@gmail.com), [drpallaviojha@gmail.com](mailto:drpallaviojha@gmail.com) Website: [panaceahospital.org](http://panaceahospital.org)

**Facilities:**

All clinical Biomedical & Hematology Investigations including Bone Marrow Examination  
 VPT, Podiascan & Complete Foot Care (First Time in Purvanchal)  
 All Hormonal Investigation by Chemiluminescent Method  
 Visceral Fat by (AB-140) Ambulatory BP Monitoring  
 CGMS & Insulin Pump Available  
 PFT, 2D-ECHO (Color Doppler), Holter, TMT, Cardiac-3 available  
 VIA, VILI, Colposcopy available  
 Special Endocrinological Investigation Protocols.

ISO 9001:2008 Certified  
 Mobile: 9389994334, 9554572190, 9453837595



# Panacea Pathology

## Clinical Reference Lab

Persistence, Preparedness and Precision  
 EQAS (CMC Vellore Attached) & IQAS System  
 पूर्वांचल की सर्वोत्तम गुणवत्ता वाली पैथोलॉजी

**UHID No** :- UD-23240007009 **Booking No/Date** :- 54 / 21-Mar-2024 12:48 PM  
**Patient Name** :- Mr SHARDESHWAR MISHRA **Age/Sex** :- 50 Y/M  
**Father** :- LATE KRISHNA PRASAD MISHRA **OP No** :- OP-23240021489  
**Address** :- FLAT NO 222 SECOND FLOOR D BLOC K RUDRA TOWER APPARTEMENT KARAMJEETPUR SUNDAERPUR PO: HINDU VISHWA VIDHYALAYA , varanasi **Mobile No** :- 9415359759  
**Consultant** :- Dr Pallavi Mishra (MBBS,MD)

### HAEMATOLOGY

**ESR** 12.0 0.00 - 15.00 mm at 1 hr  
**HBA1C -(BY GOLD STANDARD METHOD :HPLC)** 6.1 Normal: 4.0 - 5.4 %  
 Prediabetic : 5.5 -6.3  
 Diabetes mellitus := 6.4

### BIOCHEMISTRY

#### BLOOD SUGAR FASTING

**GLUCOSE** 122.0 60.00 - 100.00 mg/dl  
**PRE-DIABETICS(IMPAIRED FASTING TOLER)** - 100.00 - 125.00 mg/dl  
**DIABETICS** - upto 126 mg/dl  
**TARGET IN DM** - 80.00 - 130.00 mg/dl

### BIOCHEMISTRY

#### PPBS(POST PRANDIAL BLOOD SUGAR)

**POST PRANDIAL BLOOD GLUCOSE(2 HR AFTER MEAL)** 138.0 110.00 - 150.00 mg/dl  
**IGT(2 HR 75GM GLUCOSE)** --- 140.00 - 199.00 mg/dl  
**DIABETES** ---- upto200 mg/dl  
**TARGET IN DM** --- 80.00 - 130.00 mg/dl

### BIOCHEMISTRY

#### RFT (RENAL FUNCTION TESTS)

Lab Technician

Timing : 24/7 hrs

This Report is not valid for medico legal purpose

Consulting Pathologist  
 DR. UMESH KUMAR  
 MBBS,MD (PATHOLOG)  
 MCI Reg. No. 4124

Note: These tests have technical limitations. Clinico-pathological interpretation is necessary. In case of any disparity test may be repeated immediately.

Address : 36/44 FK Kabir Nagar, Durgakund, Varanasi - 221005

Email: [dramishra@gmail.com](mailto:dramishra@gmail.com), [drpallaviojha@gmail.com](mailto:drpallaviojha@gmail.com) Website: [panaceahospital.org](http://panaceahospital.org)

**Facilities:**

All clinical Biomedical & Hematology Investigations including Bone Marrow Examination  
 VPT, Podiascan & Complete Foot Care (First Time in Purvanchal)  
 All Hormonal Investigation by Chemiluminescent Method  
 Visceral Fat by (AB-140) Ambulatory BP Monitoring  
 CGMS & Insulin Pump Available  
 PFT, 2D-ECHO (Color Doppler), Holter, TMT, Cardiac-3 available  
 VIA, VILI, Colposcopy available  
 Special Endocrinological Investigation Protocols.

ISO 9001:2008 Certified  
 Mobile: 9389994334, 9554572190, 9453837595



# Panacea Pathology

## Clinical Reference Lab

Persistence, Preparedness and Precision  
 EQAS (CMC Vellore Attached) & IQAS System  
 पूर्वांचल की सर्वोत्तम गुणवत्ता वाली पैथोलॉजी

**UHID No** :- UD-23240007009 **Booking No/Date** :- 54 / 21-Mar-2024 12:48 PM  
**Patient Name** :- Mr SHARDESHWAR MISHRA **Age/Sex** :- 50 Y/M  
**Father** :- LATE KRISHNA PRASAD MISHRA **OP No** :- OP-23240021489  
**Address** :- FLAT NO 222 SECOND FLOOR D BLOC K RUDRA TOWER APPARTEMENT KARAMJEETPUR SUNDAERPUR PO: HINDU VISHWA VIDHYALAYA , varanasi **Mobile No** :- 9415359759  
**Consultant** :- Dr Pallavi Mishra (MBBS,MD)

SERUM CREATININE	1.28	0.60 - 1.60	mg/dl
URIC ACID	4.98	3.60 - 7.70	mg/dl
<b>LFT (LIVER FUNCTION TESTS)</b>			
TOTAL BILIRUBIN	0.57	0.00 - 1.20	mg/dl
DIRECT BILIRUBIN	0.21	0.00 - 0.30	
INDIRECT BILIRUBIN	0.36	0.20 - 0.70	mg/dl
SGOT	22.0	2.00 - 31.00	U/L
SGPT	24.0	10.00 - 45.00	U/L
ALKALINE PHOSPHATASE	79.0	25.00 - 140.00	U/L
TOTAL PROTIENS	6.8	6.60 - 8.70	g/dl
ALBUMIN	3.9	3.50 - 5.20	gm%
GLOBULIN	2.9	1.50 - 3.60	gms/dl
A/G RATIO	1.34	2:1	RATIO
YGGT	19.0	10.00 - 50.00	U/L
BUN	13.0	7.00 - 21.00	mg/dl

### LIPID PROFILE

Lab Technician

Timing : 24/7 hrs

This Report is not valid for medico legal purpose

Note: These tests have technical limitations. Clinico-pathological interpretation is necessary. In case of any disparity test may be repeated immediately.

Address : 36/44 FK Kabir Nagar, Durgakund, Varanasi – 221005

Email: [dramishra@gmail.com](mailto:dramishra@gmail.com), [drpallaviojha@gmail.com](mailto:drpallaviojha@gmail.com) Website: [panaceahospital.org](http://panaceahospital.org)

Consulting Pathologist

DR. UMESH KUMAR  
 MBBS, MD (PATHOLOGY)  
 M.O. Pathology  
 MCI Reg. No. 41415



**Facilities:**

All clinical Biomedical & Hematology Investigations including Bone Marrow Examination  
 VPT, Podiascan & Complete Foot Care (First Time in Purvanchal)  
 All Hormonal Investigation by Chemiluminescent Method  
 Visceral Fat by (AB-140) Ambulatory BP Monitoring  
 CGMS & Insulin Pump Available  
 PFT, 2D-ECHO (Color Doppler), Holter, TMT, Cardiac-3 available  
 VIA, VILI, Colposcopy available  
 Special Endocrinological Investigation Protocols.

ISO 9001:2008 Certified  
 Mobile: 9389994334, 9554572190, 9453837595



# Panacea Pathology

## Clinical Reference Lab

Persistence, Preparedness and Precision  
 EQAS (CMC Vellore Attached) & IQAS System  
 पूर्वांचल की सर्वोत्तम गुणवत्ता वाली पैथोलॉजी

**UHID No** :- UD-23240007009 **Booking No/Date** :- 54 / 21-Mar-2024 12:48 PM  
**Patient Name** :- Mr SHARDESHWAR MISHRA **Age/Sex** :- 50 Y/M  
**Father** :- LATE KRISHNA PRASAD MISHRA **OP No** :- OP-23240021489  
**Address** :- FLAT NO 222 SECOND FLOOR D BLOC K RUDRA TOWER APPARTEMENT KARAMJEETPUR SUNDAERPUR PO: HINDU VISHWA VIDHYALAYA , varanasi **Mobile No** :- 9415359759  
**Consultant** :- Dr Pallavi Mishra (MBBS,MD)

TOTAL CHOLESTROL	178.0	Desirable : - &lt; 200 mg/dL Borderline: - 200 - 239 mg/dL High : - &gt; 240mg/dL	mg/dl
TRIGLYCERIDES	<u>212.0</u>	35.00 - 160.00	mg/dl
HDL CHOLESTROL	49.0	35.30 - 79.50	mg/dl
LDL CHOLESTROL	86.6	&lt;130	mg/dl
VLDL	42.40	&lt;40	mg/dl
CHOLESTROL/ HDL RATIO	3.63	&lt;3.0 LOW RISK, 3.0-5.0 AVG RISK, &gt;5.0 HIGH RISK	ratio
LDL/HDL RATIO	1.77	&lt;3	ratio

### IMMUNOLOGY

#### THYROID PROFILE (T3,T4,TSH)

T3	0.93	0.60 - 1.81	ng/ml
T4	6.2	4.50 - 10.90	ug/dl
TSH	1.52	0.39 - 6.10	uIU/mL

**PSA, TOTAL** 0.54 0.00 - 4.00 ng/ml

### PARASITOLOGY

#### STOOL ROUTINE

Lab Technician

Timing : 24/7 hrs

This Report is not valid for medico legal purpose

Note: These tests have technical limitations. Clinico-pathological interpretation is necessary. In case of any disparity test may be repeated immediately.

Address : 36/44 FK Kabir Nagar, Durgakund, Varanasi - 221005

Email: [dramishra@gmail.com](mailto:dramishra@gmail.com), [drpallaviojha@gmail.com](mailto:drpallaviojha@gmail.com) Website: [panaceahospital.org](http://panaceahospital.org)

  
 Consulting Pathologist  
 DR. UMESH KUMAR  
 MBBS, MD (PATHOLOGY)  
 M.D. Pathology  
 MCI Reg. No. 414

**Facilities:**

All clinical Biomedical & Hematology Investigations  
including Bone Marrow Examination  
VPT, Podiascan & Complete Foot Care (First Time in Purvanchal)  
All Hormonal Investigation by Chemiluminescent Method  
Visceral Fat by (AB-140) Ambulatory BP Monitoring  
CGMS & Insulin Pump Available  
PFT, 2D-ECHO (Color Doppler), Holter, TMT, Cardiac-3 available  
VIA, VILI, Colposcopy available  
Special Endocrinological Investigation Protocols.

ISO 9001:2008 Certified

Mobile: 9389994334, 9554572190, 9453837595



# Panacea Pathology

## Clinical Reference Lab

Persistence, Preparedness and Precision  
EQAS (CMC Vellore Attached) & IQAS System  
पूर्वाचल की सर्वोत्तम गुणवत्ता वाली पैथोलॉजी

**UHID No** :- UD-23240007009 **Booking No/Date** :- 54 / 21-Mar-2024 12:48 PM  
**Patient Name** :- Mr SHARDESHWAR MISHRA **Age/Sex** :- 50 Y/M  
**Father** :- LATE KRISHNA PRASAD MISHRA **OP No** :- OP-23240021489  
**Address** :- FLAT NO 222 SECOND FLOOR D BLOC  
K RUDRA TOWER APPARTEMENT  
KARAMJEETPUR SUNDAERPUR PO:  
HINDU VISHWA VIDHYALAYA , varanasi **Mobile No** :- 9415359759  
**Consultant** :- Dr Pallavi Mishra (MBBS,MD)

### GROSS EXAMINATON


COLOR <i>Methology</i>	YELLOW	CLEAR YELLOW	
CONSISTANCY	NORMAL		
BLOOD	ABSENT		
MUCUS	ABSENT		
<b><u>MICROSCOPIC EXAMINATON</u></b>			
OVA OR EGGS OF HELMINTHS	ABSENT		
CYST OF PROTOZOA	ABSENT		
PUS CELLS	03-04	2.00 - 3.00	/HPF
RBC <i>Methology / Carm</i>	NIL	4.50 - 5.50	million/cumm

\* END OF REPORT \*

Lab Technician

Timing : 24/7 hrs

This Report is not valid for medico legal purpose

  
Consulting Pathologist  
DR. UMESH KUMAR  
MBBS, MD (PATHOLOGIST)  
M.C. Pathology  
M.C. Reg. No. 41453

Note: These tests have technical limitations. Clinico-pathological interpretation is necessary. In case of any disparity test may be repeated immediately.

Address : 36/44 FK Kabir Nagar, Durgakund, Varanasi – 221005

Email: [dramishra@gmail.com](mailto:dramishra@gmail.com), [drpallaviojha@gmail.com](mailto:drpallaviojha@gmail.com) Website: [panaceahospital.org](http://panaceahospital.org)

**Facilities:**

All-clinical Biomedical & Hematology Investigations including Bone Marrow Examination  
VPT, Podiascan & Complete Foot Care (First Time in Purvanchal)  
All Hormonal Investigation by Chemiluminescent Method  
Visceral Fat by (AB-140) Ambulatory BP Monitoring  
CGMS & Insulin Pump Available  
PFT, 2D-ECHO (Color Doppler), Holter, TMT, Cardiac-3 available  
VIA, VILI, Colposcopy available  
Special Endocrinological Investigation Protocols.

ISO 9001:2008 Certified

Mobile: 9389994334, 9554572190, 9453837595

**Panacea Pathology****Clinical Reference Lab**

Persistence, Preparedness and Precision  
EQAS (CMC Vellore Attached) & IQAS System  
पूर्वाचल की सर्वोत्तम गुणवत्ता वाली पैथोलॉजी

<b>UHID No</b>	:- UD-23240007009	<b>Booking No/Date</b>	:- 62 / 21-Mar-2024 12:56 PM
<b>Patient Name</b>	:- Mr SHARDESHWAR MISHRA	<b>Age/Sex</b>	:- 50 Y/M
<b>Father</b>	:- LATE KRISHNA PRASAD MISHRA	<b>OP No</b>	:- OP-23240021489
<b>Address</b>	:- FLAT NO 222 SECOND FLOOR D BLOC K RUDRA TOWER APPARTEMENT KARAMJEETPUR SUNDAERPUR PO: HINDU VISHWA VIDHYALAYA , varanasi	<b>Mobile No</b>	:- 9415359759
<b>Consultant</b>	:- Dr Pallavi Mishra (MBBS,MD)		

**HAEMATOLOGY****BLOOD GROUP ABO & RH FACTOR**

BLOOD GROUP	"O"
RH FACTOR	POSITIVE

**\* END OF REPORT \*****Lab Technician****Timing : 24/7 hrs****This Report is not valid for medico legal purpose****Consulting Pathologist****Dr. UMESH KUMAR**  
MBBS MD (PATHOLOGY)  
MCI Reg. No. 4147

Note: These tests have technical limitations. Clinico-pathological interpretation is necessary. In case of any disparity test may be repeated immediately.

Address : 36/44 FK Kabir Nagar, Durgakund, Varanasi – 221005

Email: [dramishra@gmail.com](mailto:dramishra@gmail.com), [drpallaviojha@gmail.com](mailto:drpallaviojha@gmail.com) Website: [panaceahospital.org](http://panaceahospital.org)



# PANACEA HOSPITAL



*A shelter for many hearts A Home for many lives*

(An ISO 9001:2008 Certified Organisation)  
Lab Attached with CMC Under EQAS Scheme

Dept. of Radiodiagnosis - 32 Slice CT Scan, 3D/4D USG, 2D ECHO, Colour Doppler, Intervention Procedures, Digital X-Ray

**NAME: MR. SHARDESHWAR MISHRA**  
**REF BY: DR.ASHUTOSH MISHRA(MD)**

**AGE/SEX:50Y/MYRS/MALE**  
**DATE: 21/03/2024**


### Echo - Cardiography

MITRAL VALVE Doppler	AML - Normal morphology MV Flow - E - 0.7 A-0.8 E/A=1.22	PML - Normal morphology MVA - 3.0 cm <sup>2</sup> Mitral Regurgitation - No
TRICUSPID VALVE Doppler	Normal TV Flow - No	Tricuspid Regurgitation - No
PULMONARY VALVE Doppler	Normal PV Flow - No	Pulmonary Regurgitation - No
AORTIC VALVE Doppler	Trileaflet-No AV Flow - no	Aortic Regurgitation - No
MEASUREMENT	Aorta - 30.3 (20-38) mm IVS ed - 8.0 (6-12) mm LVID ed - 34.8 (35-55) mm LVPW ed - 19.4 (6-12) mm OA - 1.2 (> 5) mm	LA - 34.8 (24-32) mm IVS es - 19.4 (6-12) mm LVID es - 25.1 (24-40) mm LVPW es - 16.0 (6-12) mm EPSS - 4 (< 9) mm

**CONCLUSION** All cardiac chamber dimensions are WNL  
No valvular abnormalities  
Good LV systolic function present Modified Simpson's method (4C, 2C) (LVEF-55%)  
No diastolic dysfunction present (E/A = 1.22)  
No RWMA  
No pericardial effusion  
Intact IAS / IV  
No PAH  
No intra cardiac mass /thrombus /vegetation

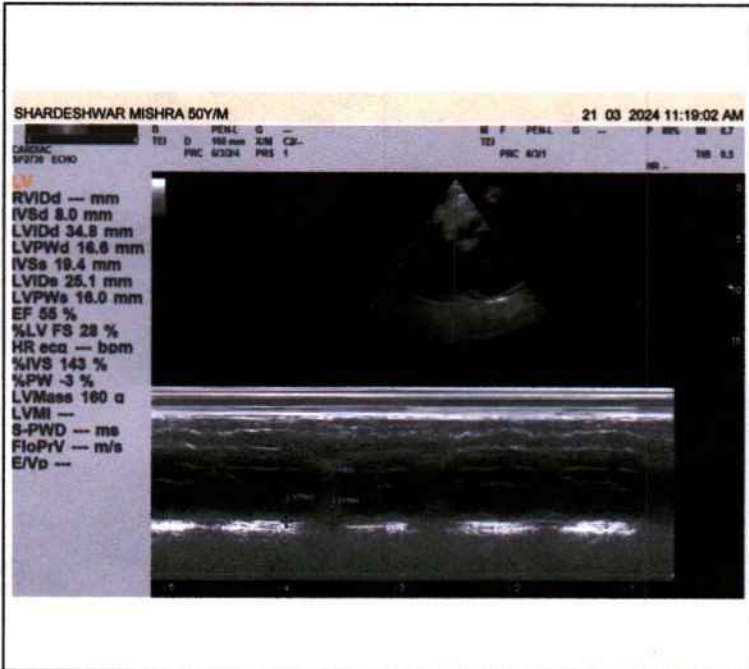
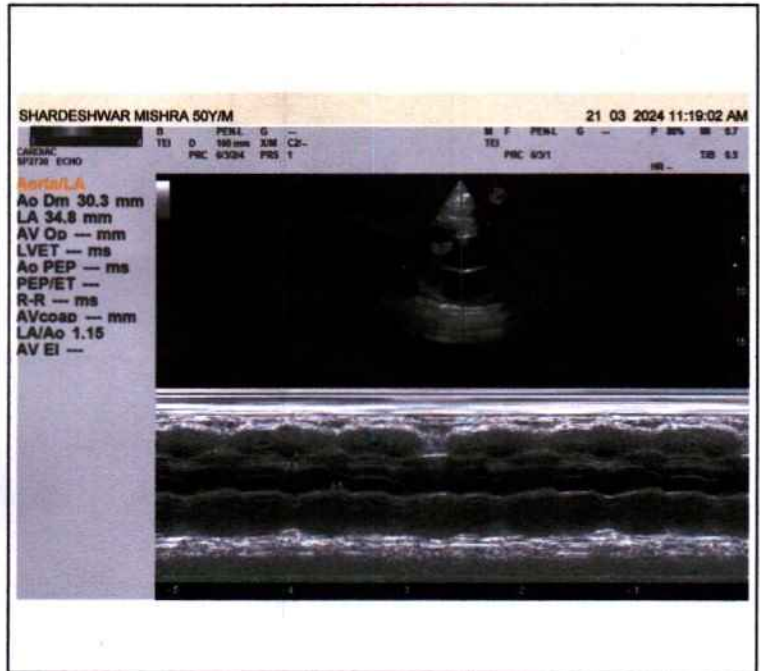
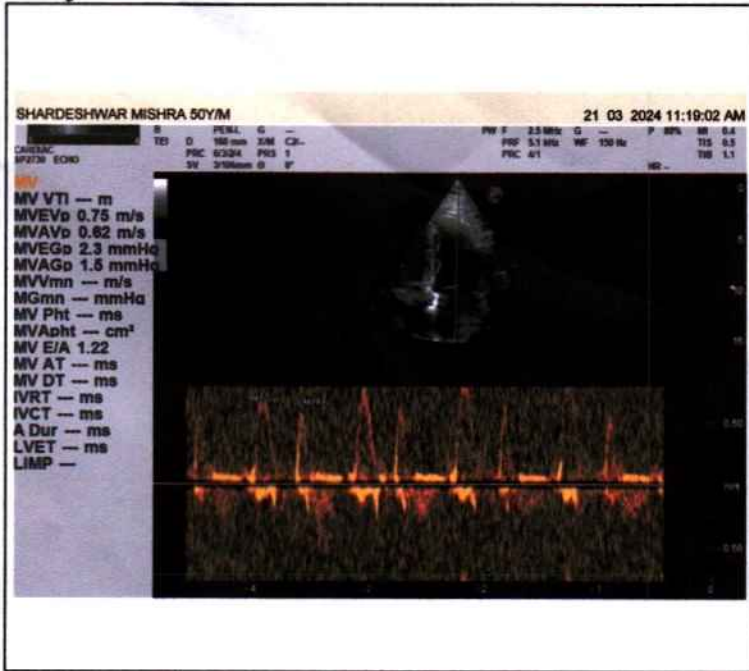
**IMPRESSION** Normal Echocardiogram

  
Niraj Mishra  
Physician Assistant  
(PIIRE)

  
DR. Pallavi Misra  
MBBS, MD (GENERAL MEDICINE)  
Echocardiography Specialist, MCh  
MCI Reg. No. 52033  
Women Cardiologist  
Diabetocardiologist

Disclaimer: This report is not valid for Madicolegal or Judicial Purpose. Radiological diagnosis is solely interpretation of images produced by tissue & may not be always conclusive.

Address : B36/44 B4 Kabir Nagar (Near Sanjay Shiksha Niketan), Durgakund, Varanasi  
Mobile : 9554572190 / 9453837595 / Recpn, 9389994334  
Email : dramishra@gmail.com, drpallaviojha@gmail.com, Website : www.piire.org





# PANACEA HOSPITAL



*A shelter for many hearts A Home for many lives*

(An ISO 9001:2008 Certified Organisation)  
Lab Attached with CMC Under EQAS Scheme

Dept. of Radiodiagnosis - 32 Slice CT Scan, 3D/4D USG, 2D ECHO, Colour Doppler, Intervention Procedures, Digital X-Ray

NAME: SHARRDESHWAR MISHRA  
REF.DR. DR.ASHUTOSH MISHRA

AGE/SEX: 50 YRS/MALE  
DATE: 21/03/2024

## ULTRA SOUND WHOLE ABDOMEN REPORT

- Liver:** Liver is normal in size measuring approx 147mm with **diffuse increased echogenicity of liver parenchyma – Grade I fatty liver.** Intra hepatic biliary radicals are normal. Portal venous channels are normal.
- Gall bladder:** Normally distended with echo free lumen.
- Portal vein:** Normal in course and caliber
- CBD diameter:** Visualized part normal in course & caliber
- Pancreas:** Normal in size, shape & echogenicity. Margins are smooth & regular. No diffuse/ focal lesion seen. Pancreatic duct not visualized.
- Spleen:** Normal in size, shape & echogenicity. Margins are smooth & regular. No diffuse / focal lesion seen. Splenic vessels at hilum is normal.
- Kidney:** Both normal in size, shape echogenicity & position. Cortical-medullary differentiation is maintained. Pelvicalyceal system normal. No evidence of any calculus/mass lesion seen. No hydronephrosis/ hydroureter seen. No suprarenal mass lesion.
- Urinary bladder:** Normally distended with normal wall thickness. No echogenic foci lumen or diverticula seen. Both VUJ appears normal. No evidence of calculus / mass lesion seen.
- Prostate:** Normal in size, shape & echogenicity.
- Others:** No free fluid in peritoneal cavity.  
No free fluid in bilateral pleural cavity.  
No evidence of significantly enlarged retroperitoneal/ mesenteric lymph nodes noted.

### **IMPRESSION: -**

- **GRADE I FATTY LIVER.**

Please correlate clinically and further investigations.

- Note: (1) This report is not valid for medico-legal purposes.  
(2) In case of any discrepancy due typing error, please get it Rectified immediately.

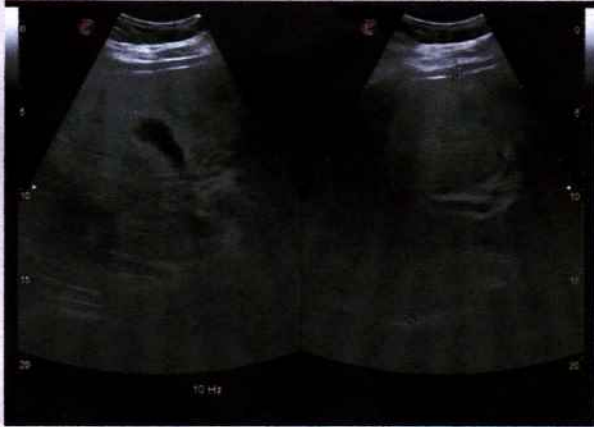  
Dr. ~~Rahul Kumar Tiwari~~  
MBBS, MD (Radiology) (Diagnosis)  
Reg. No. 57557

SHARDESHWAR MISHRA 50Y/M

21 03 2024 11:21:24 AM

TEI D GEN M G  
ABDOMINAL AC2541 ABD PRC 192/35 PRS 4

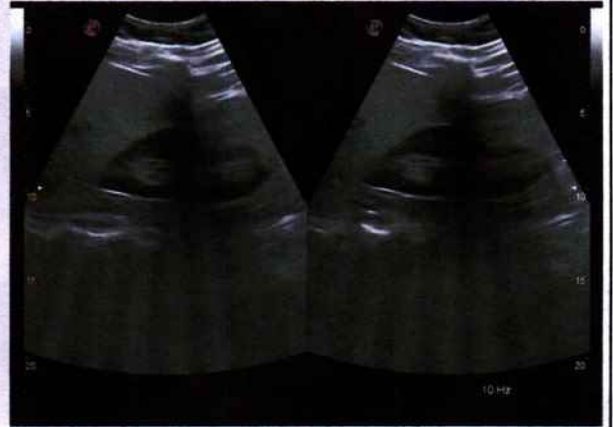D1  
147.6 mm



SHARDESHWAR MISHRA 50Y/M

21 03 2024 11:21:24 AM

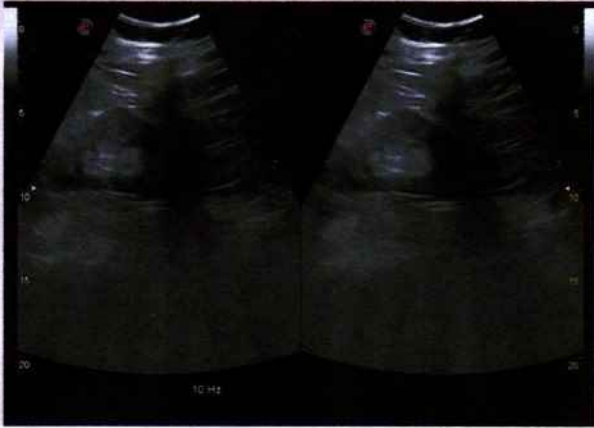
TEI D GEN M G  
ABDOMINAL AC2541 ABD PRC 192/35 PRS 4



SHARDESHWAR MISHRA 50Y/M

21 03 2024 11:21:24 AM

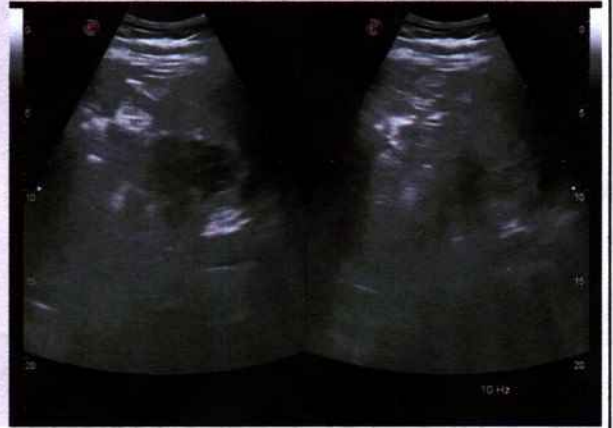
TEI D GEN M G  
ABDOMINAL AC2541 ABD PRC 192/35 PRS 4



SHARDESHWAR MISHRA 50Y/M

21 03 2024 11:21:24 AM

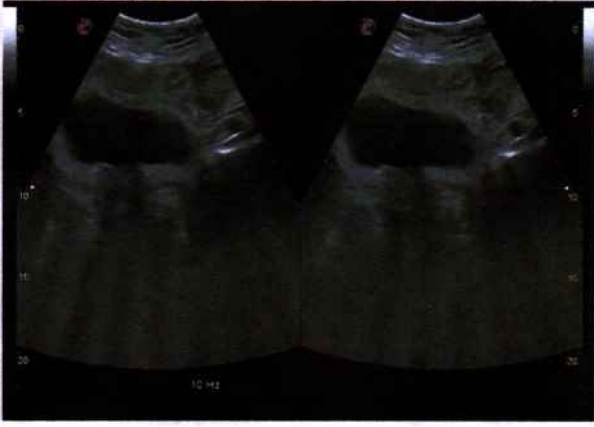TEI D GEN M G  
ABDOMINAL AC2541 ABD PRC 192/35 PRS 4



SHARDESHWAR MISHRA 50Y/M

21 03 2024 11:21:24 AM

TEI D GEN M G  
ABDOMINAL AC2541 ABD PRC 192/35 PRS 4





Call Now - 1800-123-3070

# PANACEA HOSPITAL



*A shelter for many hearts A Home for many lives*

(An ISO 9001:2008 Certified Organisation)  
Lab Attached with CMC Under EQAS Scheme

Dept. of Radiodiagnosis - 32 Slice CT Scan, 3D/4D USG, 2D ECHO, Colour Doppler, Intervention Procedures, Digital X-Ray

<b>PATIENT'S NAME</b>	: <b>SHRDESHWAR MISHRA</b>	<b>AGE</b> 50Y/ <b>SEX</b> :M
<b>REF. BY</b>	: <b>Dr. ASHUTOSH MISHRA(MD)</b>	<b>DATE</b> :21/03/2024

## X-RAY CHEST (PA VIEW)

- Bilateral lung fields appear normal.
- Trachea and mediastinum appear normal in position.
- Both hila appear normal in size and are symmetrical.
- Transverse cardiac diameter is within normal limits.
- Great vessels appear normal
- Both CP angles appear clear. Normal position and contour diaphragms noted.
- Bony rib cage and soft tissue shadows appear normal.

## IMPRESSION

- **No obvious abnormality noted in the chest radiograph.**

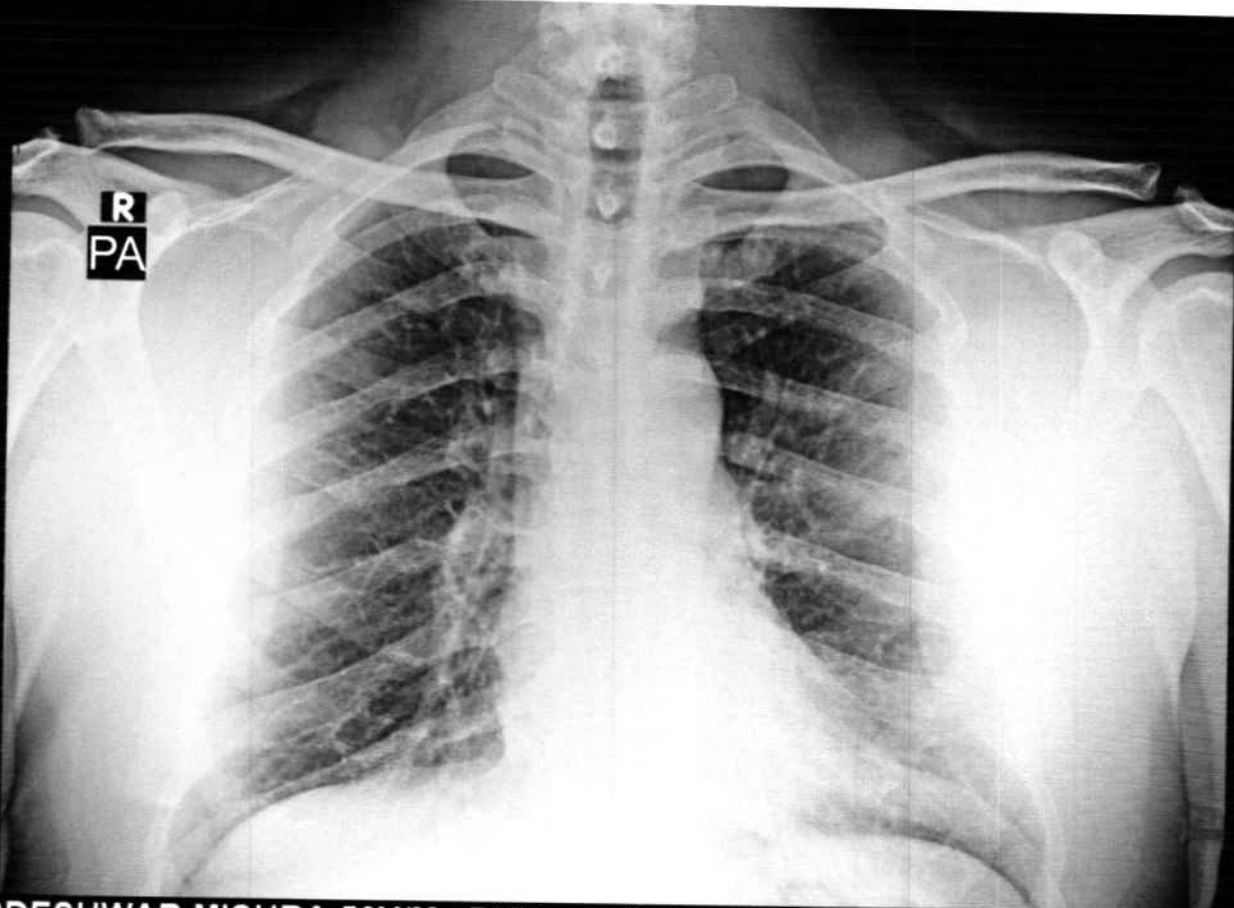*Thanks for reference.*

*Radiologist*  
Dr. Ranvir Kumar Tiwari  
MBBS, MD (Radiology)  
Reg. No. 57557

Disclaimer: This report is not valid for Madicolegal or Judicial Purpose. Radiological diagnosis is solely interpretation of images produced by tissue & may not be always conclusive.

Address : B36/44 B4 Kabir Nagar (Near Sanjay Shiksha Niketan), Durgakund, Varanasi  
Mobile : 9554572190 / 9453837595 / Recpn, 9389994334  
Email : dramishra@gmail.com, drpallaviojha@gmail.com, Website : www.piire.org





SHRDESHWAR MISHRA 50Y/M 7009 M CHEST P.A. 21-Mar-24 11:03 AM

PANACEA HOSPITAL, KABIR NAGAR, DURGAKUND, VARANASI

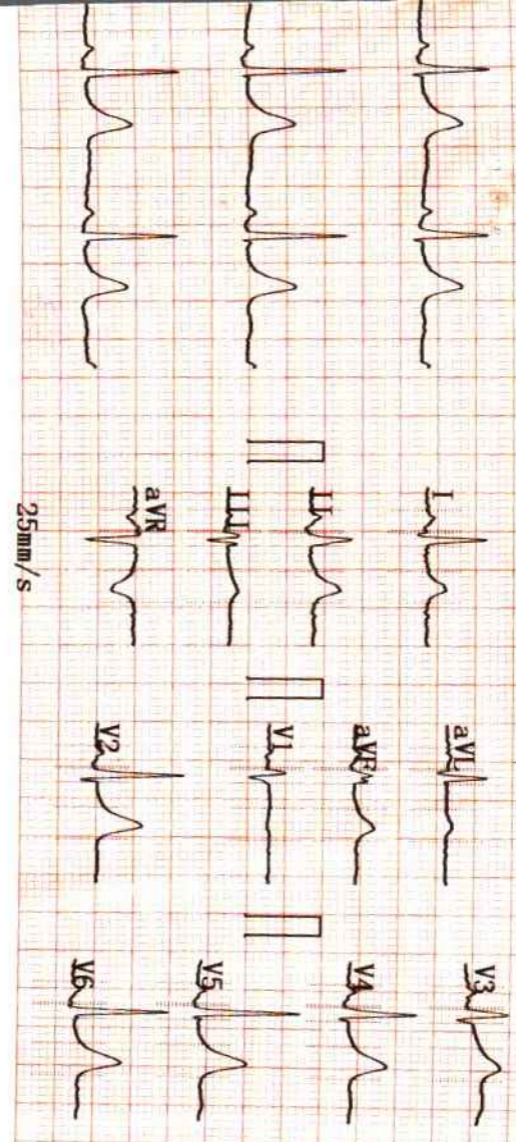
10mm/mV  
10mm/mV  
10mm/mV

2024-03-21 11:08

<< Conclusions >>

Normal Sinus Rhythm;  
Cardiac electric axis normal;

\*\*Report need physician confirm\*\*

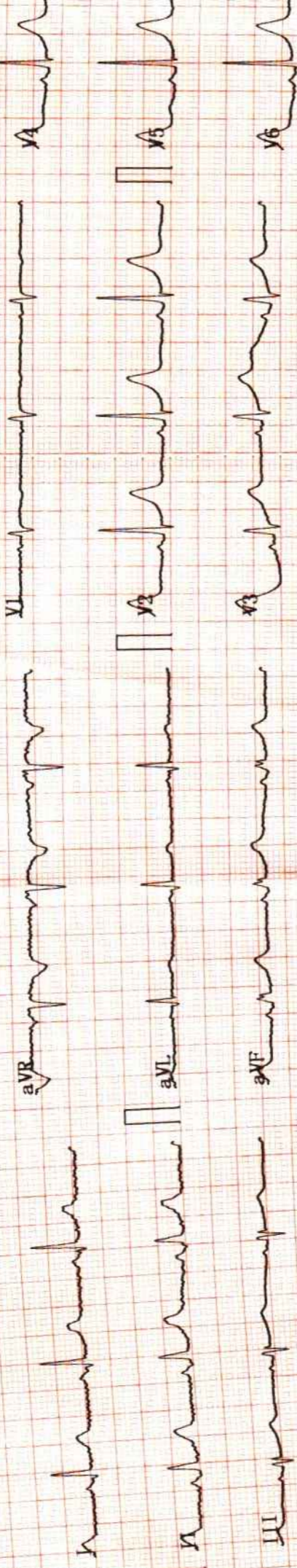


ID	:	:
Name	:	Shardeshwar
Sex	:	M
Height	:	179
SYS	:	
DIA	:	
HR	:	72
PR Interval	:	122
P Duration	:	107
QRS Duration	:	74
T Duration	:	168
QT/QTc	:	377/411
P/QRS/T Axis	:	52.5/36.0/57.7
R (V5) /S (V1)	:	1.38/0.25
R (V5) +S (V1)	:	1.64

**DR. Parvati Misra**  
MBBS, MD(GENERAL MEDICINE)  
MCI Reg. No.52033

Physician

AUTO 10mm/mV



25mm/s AC50Hz+EMG35Hz+DFT