

**MEDICOVER****HOSPITALS**

NAVI MUMBAI

Name : Mr. DADARAO ATHWALE
 Bill No. : MCB54241101844

Age /Sex : 29 Y / M
 UMR No. : 542411000416

LABORATORY REPORT : BIOCHEMISTRY

Parameters	Result	Reference Range	Units
LIPID PROFILE			
(Bill Date : 09-Nov-2024 08:31 AM Result ID : RMI241106232)			
TOTAL CHOLESTEROL <i>Enzymatic colorimetric</i>	169	Desirable : < 200 mg/dL Borderline High : 200 - 239 mg/dL High risk : > 240 mg/dL	mg/dL
HDL CHOLESTEROL <i>Homogeneous enzymatic colorimetric</i>	44	Low : < 40 mg/dL High : > 60 mg/dL	mg/dL
LDL CHOLESTEROL <i>Direct-Enzymatic colorimetric</i>	110 *	Very High : - > 190 mg/dL Optimal : - < 100 mg/dL Near Optimal : 100 - 129 mg/dL High : 160 - 189 mg/dL Borderline High:130-159 mg/dl	mg/dL
VLDL <i>Calculation</i>	14	2 - 30 mg/dL	mg/dL
SERUM TRYGLYCERIDES <i>Enzymatic colorimetric</i>	70	< 150 mg/dL Borderline High : 150 - 199 mg/dL High : 200 - 499 mg/dL	mg/dL
CHO/HDL RATIO <i>Calculation</i>	3.84 *	Normal : - < 3.5 High Risk : - > 5.0	
LDL/HDL RATIO	2.5		
SERUM CREATININE			
(Bill Date : 09-Nov-2024 08:31 AM Result ID : RMI241106234)			
CREATININE <i>Jaffe</i>	0.91	0.8 - 1.3	mg/dL
BUN / CREATININE RATIO			
(Bill Date : 09-Nov-2024 08:31 AM Result ID : RMI241106235)			
BUN / CREATININE RATIO <i>CALCULATED</i>	14.2	10-20	
LFT(LIVER FUNCTION TEST)			
(Bill Date : 09-Nov-2024 08:31 AM Result ID : RMI241106236)			
TOTAL BILIRUBIN <i>DIAZO</i>	0.5	<1.2	mg/dL





MEDICOVER

HOSPITALS

NAVI MUMBAI

Name : Mr. DADARAO ATHWALE
 Bill No. : MCB54241101844

Age / Sex : 59Y YRS / MALE
 UMR No. : 542411000416

DIRECT BILIRUBIN <i>DIAZO</i>	0.2	<=0.20	mg/dL
INDIRECT BILIRUBIN <i>Calculated</i>	0.3	<=1.0	mg/dL
SGPT (ALT) <i>UV without PSP</i>	30	<=41	U/L
SGOT (AST) <i>UV without PSP</i>	18	<=40	U/L
ALKALINE PHOSPHATASE (ALP) <i>PNPP, AMP Buffer - FCC Ref.</i>	81	40-129 U/L	U/L
TOTAL PROTEINS <i>Duret method</i>	7.3	6.0 - 8.0 g/dL	g/dL
SERUM ALBUMIN <i>Bromocresol Green (BCG)</i>	4.5	3.5 - 5.2 g/dL	g/dL
GLOBULINS <i>Calculated</i>	2.8	2.5 - 3.5 g/dL	g/dL
A/G RATIO <i>Calculation</i>	1.60	1.2 - 2.5	
GAMMA GLUTAMYL TRANSFERASE(GGT) <i>G-glutamyl-carboxy-nitrosotide-FCC</i>	26	6-42	U/L

SERUM URIC ACID

Bill Date : 09-Nov-2024 08:31 AM Result ID : RMI241106237

SERUM URIC ACID <i>uricase</i>	5.4	3.4-7.0	mg/dL
-----------------------------------	-----	---------	-------

BUN(BLOOD UREA NITROGEN)

(Bill Date : 09-Nov-2024 08:31 AM Result ID : RMI241106241)

BUN (Blood Urea Nitrogen.) <i>Calculated</i>	13	7 - 21.0	mg/dL
---	----	----------	-------

Mehrotra
 DR MEHROTRA VISHAL
 MD PATHOLOGY



**MEDICOVER****HOSPITALS**

NAVI MUMBAI

Name : Mr. DADARAO ATHWALE
Bill No. : MCB54241101844Age / Sex : 59 YRS / MALE
UMR No. : 542411000416**LABORATORY REPORT : BIOCHEMISTRY**

Parameters	Result	Reference Range	Units
HBA1C (GLYCOSYLATED HAEMOGLOBIN)			
(Bill Date : 09-Nov-2024 08:31 AM Result ID : RMI241106231)			
HBA1C HPLC	7.8 *	" Normal : < 5.7% Pre diabetic : 5.7 % - 6.5 % Diabetic : > 6.5 %	
FBS (FASTING BLOOD GLUCOSE WITH URINE GLUCOSE)			
(Bill Date : 09-Nov-2024 08:31 AM Result ID : RMI241106233)			
FASTING BLOOD GLUCOSE Hexokinase	145 *	Normal Range : 70 - 99 Impaired Glucose tolerance : 100 -125 Diabetes Mellitus : >=126	mg/dL
FASTING URINE GLUCOSE	NIL		
T3,T4 AND TSH			
(Bill Date : 09-Nov-2024 08:31 AM Result ID : RMI241106242)			
T3 ECLIA	119.6	70 - 204	ng/dL
T4 ECLIA	9.20	5.1 - 14.1	ug/dL
TSH(THYROID STIMULATING HORMONE) ECLIA	1.64	0.270 - 4.20	uIU/mL
PSA (PROSTATE SPECIFIC ANTIGEN).			
(Bill Date : 09-Nov-2024 08:31 AM Result ID : RMI241106243)			
PROSTATE SPECIFIC ANTIGEN (PSA) ECLIA	0.613	0-4.0	ng/mL
PLBS (POST LUNCH BLOOD SUGAR WITH URINE SUGAR)			
(Bill Date : 09-Nov-2024 08:31 AM Result ID : RMI241106807)			
PLBS (POST LUNCH BLOOD GLUCOSE)	231		
URINE SUGAR	+		





MEDICOVER

HOSPITALS

NAVI MUMBAI

Name : Mr. DADARAO ATHWALE
Bill No. : MCB54241101844

Age /Sex : 59 Yrs MALE
UMR No. : 542411000416


DR. MEHROTRA VISHAL
MD Pathology





MEDICOVER

HOSPITALS

NAVI MUMBAI

Name : Mr. DADARAO ATHWALE
Bill No. : MCB54241101844

Age /Sex
UMR No.

89 Yrs / MALE
542411000416

LABORATORY REPORT : BLOOD BANK

Parameters Result Reference Range Units

BLOOD GROUPING AND RH

(Bill Date : 09-Nov-2024 08:31 AM Result ID : RMI241106251)

BLOOD GROUP O
Automated microcolumn gel method

RH TYPE POSITIVE

INTERPRETATION

1. If Rh is Du positive it is best considered as Rh negative as recipient and Rh positive as donor. Proper Cross matching is recommended before transfusion.
2. In case of forward and reverse grouping discrepancy, clinical correlation and repeat sample analysis is recommended.
3. For Infants below 6 months only forward grouping is performed.
4. A sub-grouping is recommended after the age of 6 months.

Mehrotra Vishal
DR. MEHROTRA VISHAL
MD PATHOLOGY



**MEDICOVER****HOSPITALS**

NAVI MUMBAI

Name : Mr. DADARAO ATHWALE
 Bill No. : MCB54241101844

Age /Sex : 59 Y M (M) DALE
 UMR No. : 542411000418

LABORATORY REPORT : CLINICAL PATHOLOGY

Parameters	Result	Reference Range	Units
CUE(COMPLETE URINE EXAMINATION)			
(Bill Date : 09-Nov-2024 08:31 AM Result ID : RMI241106238)			
<u>PHYSICAL EXAMINATION</u>			
VOLUME	30 ML		ml
COLOUR	Pale yellow	PALE YELLOW	
APPEARANCE	CLEAR	CLEAR	
<u>CHEMICAL EXAMINATION</u>			
DEPOSIT	ABSENT	ANSENT	
SPECIFIC GRAVITY <i>Bromthymol blue</i>	1.025	1.000 - 1.030	
PH <i>Bromthymol blue</i>	5.5	5.0 - 8.0	
PROTEIN <i>Tetra-bromophenol blue/Leuc coagulation test</i>	NIL	NIL (<15 mg/dL)	
GLUCOSE <i>Glucose oxidase Peroxidase/Benedict's test</i>	+	NIL (<25 mg/dL)	
UROBILINOGEN <i>Diazotium salt</i>	NIL	NIL	
KETONE <i>Sodium nitroprusside/Rothera's test</i>	NIL	NIL (<5 mg/dL)	
BILIRUBIN <i>Dipstick/Fouchet's test</i>	NIL	NEGATIVE	
BILE SALT <i>Heays sulphur powder</i>	NIL	NEGATIVE	
BILE PIGMENT <i>Fouchet test</i>	NIL	NEGATIVE	
NITRITE <i>Sulfanilic acid</i>	NIL	NEGATIVE	





MEDICOVER

HOSPITALS

NAVI MUMBAI

Name : Mr. DADARAO ATHWALE
Bill No. : MCB54241101844

Age / Sex : 59 Yrs / MALE
UMR No. : 542411000416

LEUCOCYTE ESTERASE	NIL	NEGATIVE	
<u>MICROSCOPIC EXAMINATION</u>			
PUS CELLS	1-2	0 - 5 /hpf	
EPITHELIAL CELLS	1-2	0 - 5	hpf
RBC	NIL	0 - 5 /hpf	
CAST	NIL	NIL	
<i>Microscopy examination</i>			
CRYSTALS	NIL	NIL	
BACTERIA	NIL		
<i>Microscopic examination</i>			
YEAST	NIL		
<i>Microscopic examination</i>			
AMORPHOUS DEPOSITS	NIL		
<i>Microscopic examination</i>			
MUCUS THREAD	NIL		
<i>Microscopic examination</i>			

NOTE

Microscopic examination of urine is carried out on centrifuged urinary sediment.

Dr Neeta Shrivastava
MBBS, MD, DNB (Microbiology)



**MEDICOVER****HOSPITALS**

NAVI MUMBAI

Name : Mr. DADARAO ATHWALE
 Bill No. : MCB54241101844

Age /Sex : 89 Yrs / Male
 UMR No. : 542411000416

LABORATORY REPORT : HAEMATOLOGY

Parameters	Result	Reference Range	Units
ESR			
(Bill Date : 09-Nov-2024 08:31 AM Result ID : RMI241106239)			
ESR MODIFIED WESTERGRENS METHOD	06	0 - 10	mm/1st hour

CBP (COMPLETE BLOOD PICTURE)

(Bill Date : 09-Nov-2024 08:31 AM Result ID : RMI241106240)

R B C COUNT Electrical Impedance	5.44	4.5 - 5.5 $10^{12}/L$	$10^{12}/L$
HEMOGLOBIN Photometric	14.8	13.0 - 17.0	gms/dL
PCV/HCT Calculated	48.9	40 - 50	%
MCV Calculated	89.8	83 - 101	fL
MCH Calculated	27.3	27 - 32	pg
MCHC Calculated	30.4 *	31.5 - 34.5	g/dL
RDW(cv)	15.4 *	11.6 - 14.0 %	%
TLC (TOTAL LEUCOCYTE COUNT)	7.00	4.0 - 10.0	$10^3/\mu l$

Impedance

DIFFERENTIAL COUNT

NEUTROPHILS DHSS/Microscopy	62	40 - 80 %
LYMPHOCYTES DHSS/Microscopy	30	20 - 40 %
MONOCYTES DHSS/Microscopy	05	02 - 10 %
EOSINOPHILS DHSS/Microscopy	03	00 - 06 %





MEDICOVER

HOSPITALS

NAVI MUMBAI

Name : Mr. DADARAO ATHWALE
Bill No. : MCB54241101844

Age /Sex : 29 Y (M)
UMR No. : 542411000416

BASOPHILS
DHSS/Microscopy

00


00 - 01 %

PLATELET COUNT
Electrical Impedance

227

150 - 400 $10^3/\mu\text{L}$

$10^3/\mu\text{L}$


DR. MEHROTRA VISHAL
MD Pathology



Patient ID:	542411000416	Patient Name:	DADARAO ATHWALE
Age:	59YRS	Sex:	M
Accession Number:		Modality:	US
Referring Physician:	DMO	Study:	USG ABDOMEN PELVIS
Study Date:	09-Nov-2024	Study Time:	11:57:07

USG ABDOMEN & PELVIS

The Liver is normal in size (13.3 cm) and shows normal echotexture. No focal lesion is seen. The Hepatic veins appear normal. There is no IHBR dilatation. The portal vein appears normal.

The gall bladder is well distended with normal wall thickness. There is no evidence of gallstones. C.B.D. is of normal caliber.

The Pancreas is normal in size and echotexture.

The spleen is normal size (8.6 cm). No focal lesion is seen.

The Right Kidney measures 9.7 x 3.0 cm.

The Left Kidney measures 9.0 x 4.2 cm.

Both kidneys are normal in size, shape and echotexture. They shows normal cortical echogenicity with maintained cortico-medullary distinction.

There is no evidence of a calculus, hydronephrosis, or hydroureter.

The Urinary bladder is adequately distended and shows normal wall thickness. No evidence of any intraluminal mass or calculi.

The uterus is normal in size and echotexture. It measures 6.3 x 3.5 x 3.4 cm.

A 4.4 x 3.6 cm sized subserosal fibroid is seen along right lateral wall of uterus. The Endometrial thickness is 6.5 mm.

Both ovaries are well visualized and appear normal in size and echotexture.

The Right ovary measures 1.8 x 1.6 cm

The Left ovary measures 3.0 x 2.0 cm

There is no evidence of any ovarian or adnexal mass lesion.

Visualised bowel loops are unremarkable.

There is no evidence of significant lymphadenopathy.

No ascitis is seen.



Patient ID:	542411000416	Patient Name:	DADARAO ATHWALE
Age:	59YRS	Sex:	M
Accession Number:		Modality:	US
Referring Physician:	DMO	Study:	USG ABDOMEN PELVIS
Study Date:	09-Nov-2024	Study Time:	11:57:07

IMPRESSION:

- **Subserosal uterine fibroid as described.**
- **No other significant abnormality is seen.**

DR. ANUPKUMAR AGRAWAL
Consultant & HOD Radiology
MBBS, MD

Date: 09-Nov-2024 12:33:11

Patient ID:	542411000416	Patient Name:	DADARAO ATHAVALE
Age:	59 Years	Sex:	M
Accession Number:		Modality:	DX
Referring Physician:		Study:	CHEST
Study Date:	09-Nov-2024		

X RAY CHEST PA VIEW

Both lungs are clear.

The frontal cardiac dimensions are normal.

The pleural spaces are clear.

Both hilar shadows are normal in position and density.

No diaphragmatic abnormality is seen.

The soft tissues and bony thorax are normal.

Impression:

- **No significant abnormality is seen.**



Dr. Garima Shalendra Sharma
MBBS, MD (Radio Diagnosis),
DNB (RCH)
Consultant Radiologist

Date: 09-Nov-2024 10:16:12

Rate 61 Sinus rhythm.....Normal P axis, V-rate 50-99
 PR 160 Abnormal R-wave progression, early transition.....QRS area>0 in V2
 QRS 83 Borderline T wave abnormalities.....T/QRS ratio < 1/20 or flat T
 QT 361
 QTc 364

WNL

--AXIS--

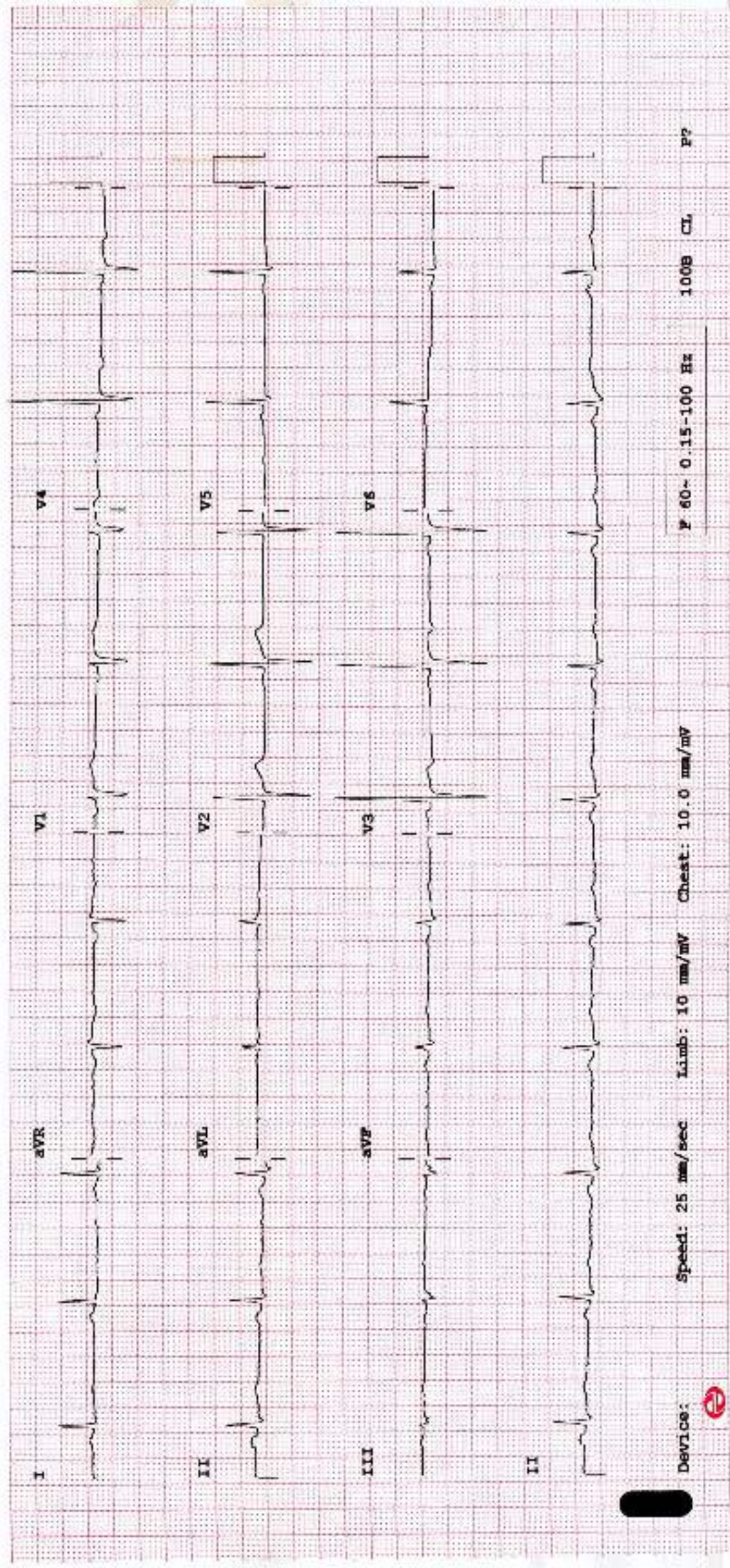
P 40
 QRS 14
 T 57

W

12 Lead: Standard Placement

- BORDERLINE ECG -

Unconfirmed Diagnosis



Device: Speed: 25 mm/sec Limb: 10 mm/mV Chest: 10.0 mm/mV

P 60~ 0.15-100 Hz 100B CL P?



2D ECHO CARDIOGRAPHY WITH COLOR DOPPLER

<i>Name</i>	: Mr. Dadarao Athawale	Date:- 09/11/2024
<i>Age / Sex</i>	: 59 Yrs / Male	UMR No. 00416
<i>Referred By</i>	: Health check up	

FINDINGS:

- No left ventricle regional wall motion abnormality.
- Normal left ventricle systolic function. LVEF = 60%.
- Grade I left ventricle diastolic dysfunction.
- Trivial mitral regurgitation.
- No aortic regurgitation. No aortic stenosis.
- Mild tricuspid regurgitation. No pulmonary hypertension.
PASP = 30 mm Hg.
- No left ventricle clot / vegetation / pericardial effusion.
- Intact IAS and IVS.
- Normal left atrium and left ventricle dimensions.
- Normal right atrium and right ventricle dimensions.
- Normal right ventricle systolic function. No hepatic congestion.

IMP:

- Grade I left ventricle diastolic dysfunction.
- No RWMA.
- Trivial MR . Mild TR. No PH.
- Normal LV and RV systolic function.

DR. KESHAV KALE
DNB (Cardiology), MD (Medicine), MBBS
PhD (Cardiology), MNAMS, LL.B (Law)
FSCAI (USA), AFACC (USA), FESC (EU)
Consultant & Interventional Cardiologist





MEDICOVER
HOSPITALS

NAVI MUMBAI

M-MODE MEASUREMENTS:

LA	34	mm
AO root	29	mm
AO CUSP SEP	18	mm
LVID(s)	32	mm
LVID(d)	41	mm
IVS(d)	10	mm
LVPW(d)	10	mm
RVID(d)	29	mm
RA	31	mm
LVEF	60	%

	PEAK	MEAN	Vmax	Gradient of Regurgitation
MITRAL	N			Trivial
AORTIC	7			Nil
TRICUSPID	30			Mild
PULMONERY	4.1			Nil





MEDICOVER HOSPITALS

DEPARTMENT OF OPHTHALMOLOGY

NAVI MUMBAI

DATE: 9/11/24

PATIENT NAME: Mr. Dadasao Athwale

AGE / SEX

59 / m

UMR NO: S42411 800416

	RE	LE
VA (DISTANCE)	6/9	6/9
VA (NEAR)	N18	N18
COLOUR VISION	(N)	(N)

		SPHERE	CYLINDER	AXIS	VA	
MRx	O D (8)	+ 0.50	—	—	6/9	+ 2.50 → N6
	O S (4)	+ 0.50	—	—	6/9	+ 2.50 → N6

HISTORY :

W/o DM (+) ∴ 8-10 yrs on PP

No W/O HT/Thyroid

W/o spectacle use (+) for near.

OCULAR FINDINGS :

(BE) - Ant seg WNL

Disc < 0.3
0.3

ADVICE:

Refresh Tears 4x tid (77) X (months)
Fundoscopy ilv/o HT

mon-fri 11am to 2pm

AS
CDR. ANUSHREE VANIKAR





MEDICOVER
HOSPITALS

MEDICOVER HOSPITALS

MEDICAL HEALTH CHECK- UP ASSESMENT FORM

NAME : Mr / Mrs Dadanna Athwal

DATE: 09/11/24

AGE : 59 Yrs / M

SEX: Male / Female

NMU: NMU000 542411000416

DOCTOR'S NAME:

TEMP :	<u>97.7</u>	° f	BP :	<u>139/89</u>	mmHg
PULSE :	<u>70</u>	b/m	HEIGHT :	<u>158</u>	cm
RR :	<u>20</u>	b/m	WEIGHT :	<u>87.9</u>	kg
SPO2 :	<u>98</u>	%	HGT:	<u>---</u>	

REMARK:



**MEDICOVER
HOSPITALS**

NAVI MUMBAI

Dabanoo Athvale, Mtl, says

c/o routine check up =

O/E S+1, Ca-1

Ash,

Scaling & polishing

Dr. Binola Singh

