


Name : Mrs. Supriya Sabbavarapu Address : Bangalore Plan : ARCOFEMI MEDIWHEEL FEMALE AHC CREDIT PAN INDIA OP AGREEMENT	Age : 38 Y Sex : F	UHID :CINR.0000161745  OP Number :CINROPV216757 Bill No :CINR-OCR-93121 Date : 22.01.2024 08:02
---	---	---

Sno	Service Type/ServiceName	Department
1	ARCOFEMI - MEDIWHEEL - FULL BODY HEALTH ANNUAL PLUS CHECK - FEMALE - 2D ECHO - PAN INDIA - FY2324	
1	GAMMA GLUTAMYL TRANSFERASE (GGT)	
2	D ECHO -9 7AM	
3	LIVER FUNCTION TEST (LFT)	
4	GLUCOSE, FASTING	
5	HEMOGRAM + PERIPHERAL SMEAR	
6	GYNABCOLOGY CONSULTATION -3	
7	DIET CONSULTATION	
8	COMPLETE URINE EXAMINATION	
9	URINE GLUCOSE(POST PRANDIAL)	
10	PERIPHERAL SMEAR	
11	ECG -6	
12	LBC PAP TEST- PAPSURE -3	
13	RENAL PROFILE/RENAL FUNCTION TEST (RFT/KFT)	
14	DENTAL CONSULTATION	
15	GLUCOSE, POST PRANDIAL (PP), 2 HOURS (POST MEAL)	
16	URINE GLUCOSE(FASTING)	
17	HbA1c, GLYCATED HEMOGLOBIN	
18	X-RAY CHEST PA -10	
19	ENT CONSULTATION	
20	FITNESS BY GENERAL PHYSICIAN	
21	BLOOD GROUP ABO AND RH FACTOR	
22	LIPID PROFILE	
23	BODY MASS INDEX (BMI)	
24	OPHTHAL BY GENERAL PHYSICIAN	
25	ULTRASOUND - WHOLE ABDOMEN -9	
26	THYROID PROFILE (TOTAL T3, TOTAL T4, TSH)	

27 - Niramai Breast Screening -15

2949

Date : 22-01-2024
 MR NO : CINR.0000161745
 Name : Mrs. Supriya Sabbavarapu
 Age/ Gender : 38 Y / Female

Department : GENERAL
 Doctor :
 Registration No :
 Qualification :

Consultation Timing: 08:01

Height : 157-cm	Weight : 62.6 kg	BMI : 25.39 kg/m ²	Waist Circum : 83-cm
Temp : 98.6 °f	Pulse : 79 bpm	Resp : 18 bpm	B.P : 118/70 mmHg

General Examination / Allergies
 History

Jan 2020

Clinical Diagnosis & Management Plan

*SSyn 1.1, LCB - 2 yrs Im cycles
 PE Lapp - Oct 22nd
 Rame x periods
 - Pap smear
 - Sin*

Follow up date:

Doctor Signature

Mrs. Supriya S

38y/F

Height :	Weight :	BMI :	Waist Circum :
Temp :	Pulse :	Resp :	B.P :

General Examination / Allergies
History

Clinical Diagnosis & Management Plan

Arcopiani - Atc

Ears: NTD

Nose: NTD

Throat: NTD

Follow up date:

R. Ravindranath

Dr. RAVINDRANATH KUDVA **Doctor Signature**

M.B.B.S., D.L.O.

E.N.T. SURGEON

BOOK YOUR APPOINTMENT TODAY!
KMC REG. No : 18554

Whatsapp Number : 970 100 3333

Toll Number : 1860 500 7788

Website : www.apolloclinic.com

OPHTHAL PRESCRIPTION

PATIENT NAME: *Supriya Subhavanapu* DATE: *22/1/24*

UHID NO: *CINR0000161745*

AGE: *38y*

OPTOMETRIST NAME: Ms. Swathi

GENDER: *Female*

This is to certify that I have examined

years and findings of his/her eye examination are as follows,

	RIGHT EYE				LEFT EYE			
	SPH	CYL	AXIS	BCVA	SPH	CYL	AXIS	BCVA
Distance	<i>-1.00</i>	<i>-</i>	<i>-</i>	<i>6/6</i>	<i>-0.75</i>	<i>-</i>	<i>-</i>	<i>6/6</i>
Add	<i>-</i>	<i>-</i>	<i>-</i>	<i>Ms</i>	<i>-</i>	<i>-</i>	<i>-</i>	<i>NC</i>

PD - RE: *-* - LE: *-* -

Colour Vision: *Normal*

Remarks:

Apollo clinic Indiranagar

Supriya
ID: 161745

24.07.1985
38 Years

Female


22.01.2024 10:32:41
APOLLO CLINIC
INDIRANAGAR
BANGALORE

Location:
Room:
Order Number:
Indication:
Medication 1:
Medication 2:
Medication 3:

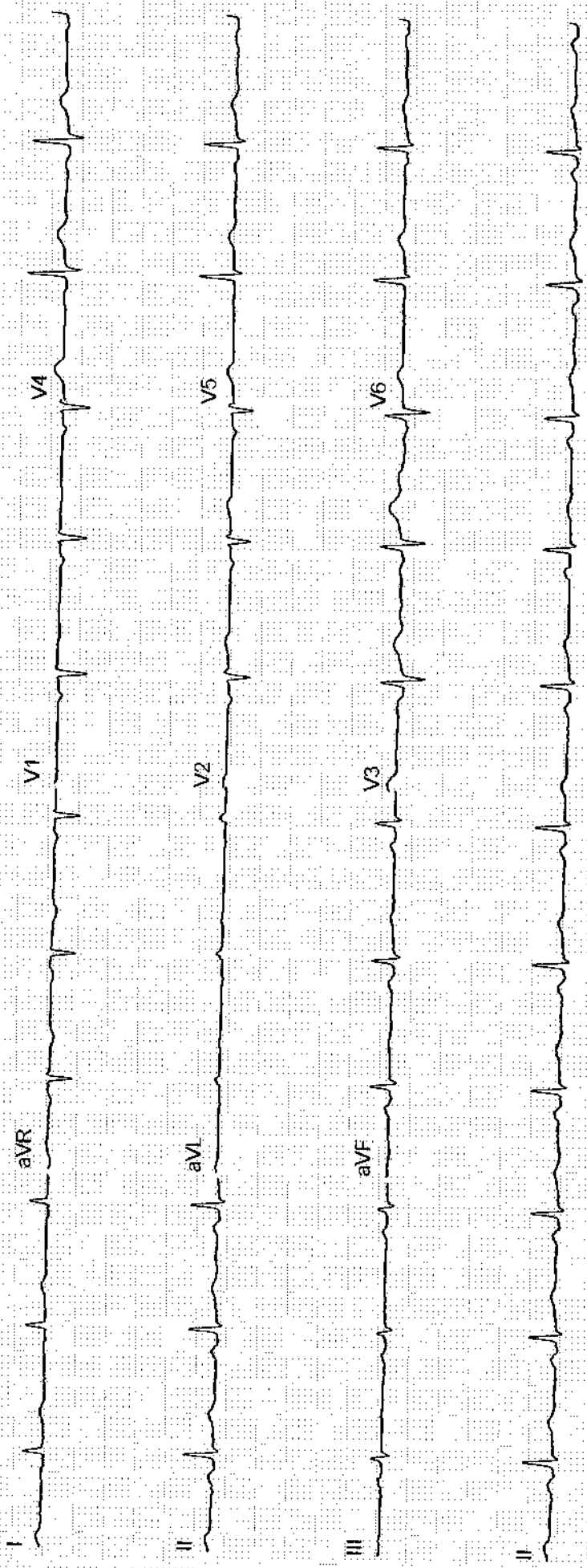
70 bpm
/ / mmHg

QRS 76 ms
QT/QTc/Baz 386 / 416 ms
PR 162 ms
P 94 ms
RR/PP 854 / 857 ms
P/QRS/T 71 / 47 / 27 degrees

Technician:
Ordering Ph:
Referring Ph:



Dr. M. SUDHAKAR RAO
M.D. (General Medicine)
M.B.B.S.
Consultant to C.I. Apollo Indiranagar
153/3, MG Road, Indiranagar, Bangalore - 560025



NAME: MRS SUPRIYA	AGE/SEX: 38/F	OP NUMBER: 161745
Ref By : SELF	DATE: 22-01-2024	

M mode and doppler measurements:

CM	CM	M/sec	
AO: 2.5	IVS(D): 0.7	MV: E Vel: 0.9	A Vel : 0.7
LA: 2.8	LVIDD(D): 3.7	AV Peak: 0.8	
	LVPW(D):0.9	PV peak:3.7	
	IVS(S): 1.0		
	LVID(S):2.3		
	LVEF: 60%		
	LVPW(S): 1.2		

Descriptive findings:

Left Ventricle	Normal
Right Ventricle:	Normal
Left Atrium:	Normal
Right Atrium:	Normal
Mitral Valve:	Normal
Aortic Valve:	Normal
Tricuspid Valve:	Normal
IAS:	Normal
IVS:	Normal
Pericardium:	Normal

IVC:	Normal
Others	---

IMPRESSION :

Normal cardiac chamber and valves

No Regional wall motion abnormality

No MR/AR/TR

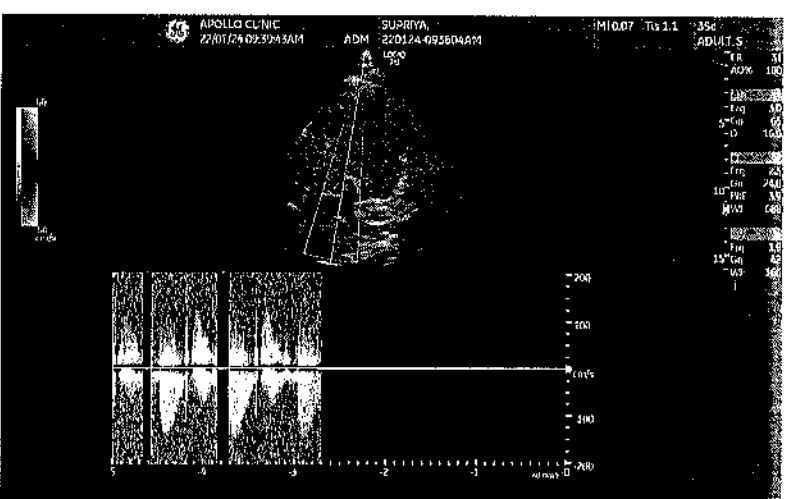
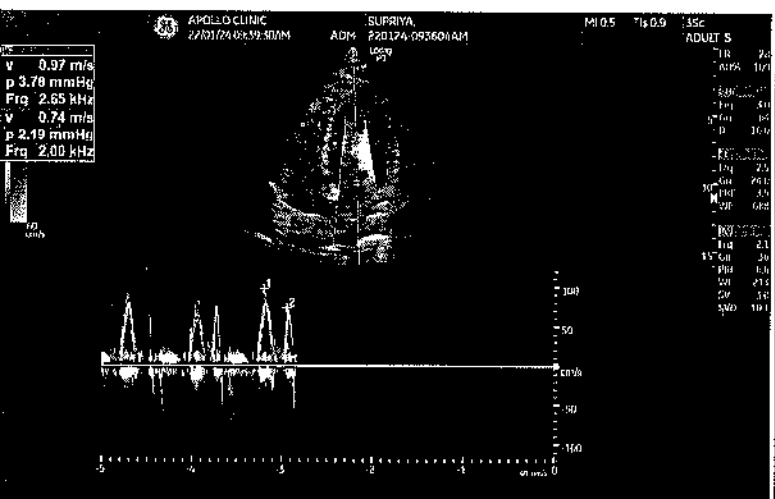
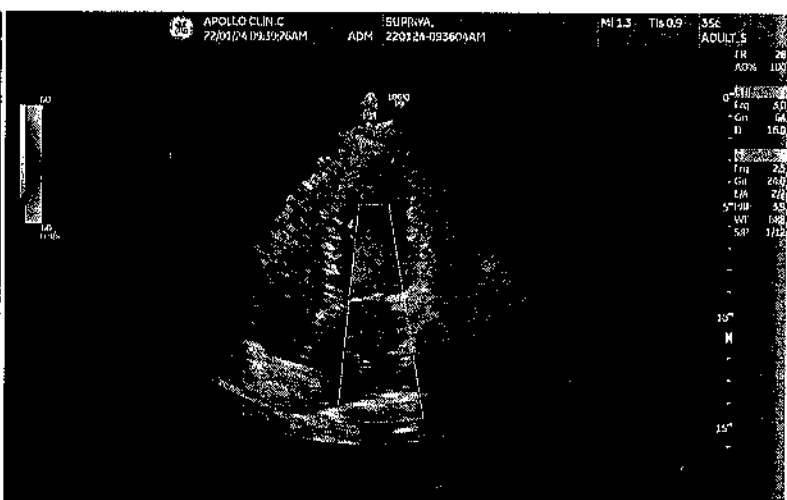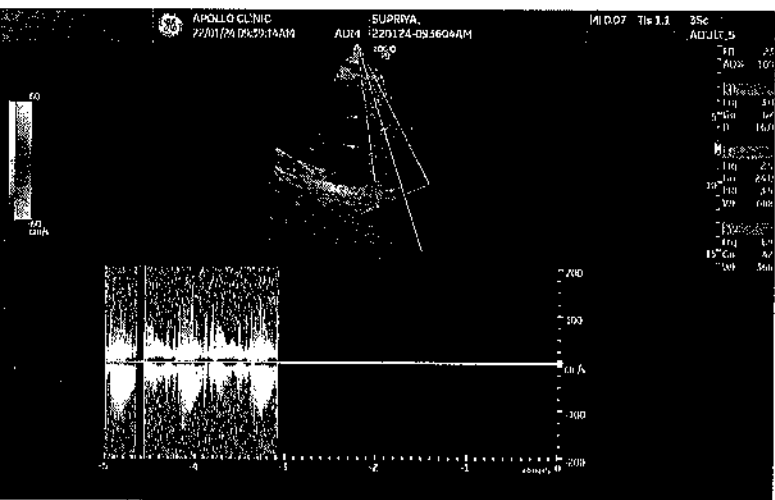
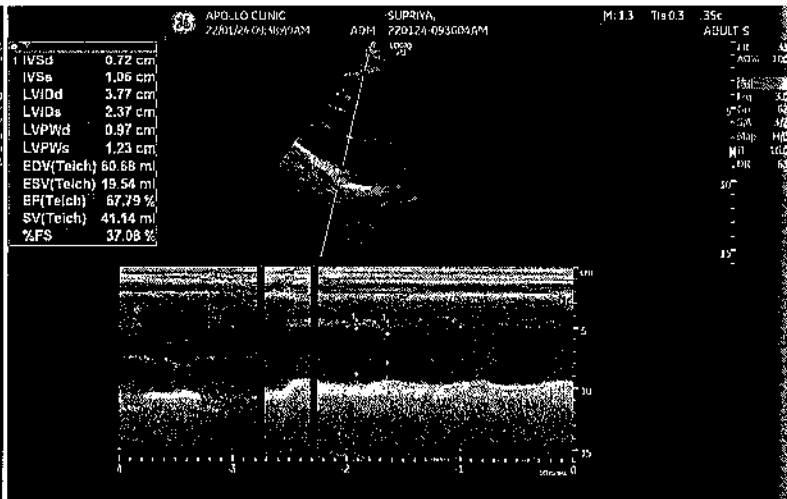
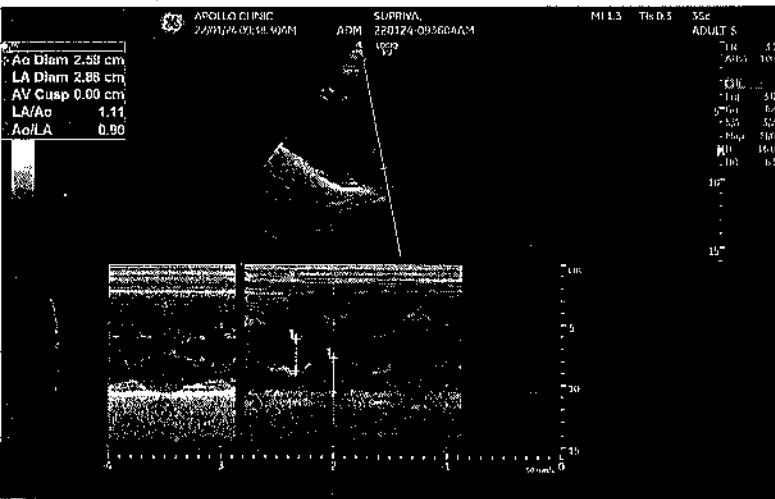
No clot/vegetation/pericardial effusion

Normal LV systolic function - LVEF= 60%

DR ROCKEY KATHERIA MD,DM

CONSULTANT CARDIOLOGIST

RK
Dr. ROCKEY KATHERIA
MBBS, MD, DM(Cardio)
Consultant Cardiologist
KMC Reg No. 94738
Apollo Clinic





LETTER OF APPROVAL / RECOMMENDATION

To,

The Coordinator,
Mediwheel (Arcofemi Healthcare Limited)
Helpline number: 011- 41195959

Dear Sir / Madam,

Sub: Annual Health Checkup for the employees of Bank of Baroda

This is to inform you that the following employee wishes to avail the facility of Cashless Annual Health Checkup provided by you in terms of our agreement.

PARTICULARS	EMPLOYEE DETAILS
NAME	MS. SABBAVARAPU SUPRIYA
EC NO.	94425
DESIGNATION	JOINT MANAGER
PLACE OF WORK	BANGALORE, TUMKUR ROAD
BIRTHDATE	24-07-1985
PROPOSED DATE OF HEALTH CHECKUP	22-01-2024
BOOKING REFERENCE NO.	23M94425100084906E

This letter of approval / recommendation is valid if submitted along with copy of the Bank of Baroda employee id card. This approval is valid from **19-01-2024** till **31-03-2024** The list of medical tests to be conducted is provided in the annexure to this letter. Please note that the said health checkup is a **cashless facility** as per our tie up arrangement. We request you to attend to the health checkup requirement of our employee and accord your top priority and best resources in this regard. The EC Number and the booking reference number as given in the above table shall be mentioned in the invoice, invariably.

We solicit your co-operation in this regard.

Yours faithfully,


Sd/-

Chief General Manager
HRM Department
Bank of Baroda

(Note: This is a computer generated letter. No Signature required. For any clarification, please contact Mediwheel (Arcofemi Healthcare Limited))

SUGGESTIVE LIST OF MEDICAL TESTS

FOR MALE	FOR FEMALE
CBC	CBC
ESR	ESR
Blood Group & RH Factor	Blood Group & RH Factor
Blood and Urine Sugar Fasting	Blood and Urine Sugar Fasting
Blood and Urine Sugar PP	Blood and Urine Sugar PP
Stool Routine	Stool Routine
Lipid Profile	Lipid Profile
Total Cholesterol	Total Cholesterol
HDL	HDL
LDL	LDL
VLDL	VLDL
Triglycerides	Triglycerides
HDL / LDL ratio	HDL / LDL ratio
Liver Profile	Liver Profile
AST	AST
ALT	ALT
GGT	GGT
Bilirubin (total, direct, indirect)	Bilirubin (total, direct, indirect)
ALP	ALP
Proteins (T, Albumin, Globulin)	Proteins (T, Albumin, Globulin)
Kidney Profile	Kidney Profile
Serum creatinine	Serum creatinine
Blood Urea Nitrogen	Blood Urea Nitrogen
Uric Acid	Uric Acid
HBA1C	HBA1C
Routine urine analysis	Routine urine analysis
USG Whole Abdomen	USG Whole Abdomen
General Tests	General Tests
X Ray Chest	X Ray Chest
ECG	ECG
2D/3D ECHO / TMT	2D/3D ECHO / TMT
Stress Test	Thyroid Profile (T3, T4, TSH)
PSA Male (above 40 years)	Mammography (above 40 years) and Pap Smear (above 30 years).
Thyroid Profile (T3, T4, TSH)	Dental Check-up consultation
Dental Check-up consultation	Physician Consultation
Physician Consultation	Eye Check-up consultation
Eye Check-up consultation	Skin/ENT consultation
Skin/ENT consultation	Gynaec Consultation



Patient Name : Mrs. Supriya Sabbavarapu

Age/Gender : 38 Y/F

UHID/MR No. : CINR.0000161745

OP Visit No : CINROPV216757

Sample Collected on :

Reported on : 22-01-2024 15:01

LRN# : RAD2213560

Specimen :

Ref Doctor : SELF

Emp/Auth/TPA ID : 9865899996

DEPARTMENT OF RADIOLOGY

X-RAY CHEST PA

Both lung fields and hila are normal .

No obvious active pleuro-parenchymal lesion seen .

Both costophrenic and cardiophrenic angles are clear .

Both diaphragms are normal in position and contour .

Thoracic wall and soft tissues appear normal.

CONCLUSION :

No obvious abnormality seen



Dr. DHANALAKSHMI B
MBBS, DMRD
Radiology

Patient Name	: Mrs. Supriya Sabbavarapu	Age/Gender	: 38 Y/F
UHID/MR No.	: CINR.0000161745	OP Visit No	: CINROPV216757
Sample Collected on	:	Reported on	: 22-01-2024 12:30
LRN#	: RAD2213560	Specimen	:
Ref Doctor	: SELF		
Emp/Auth/TPA ID	: 9865899996		

DEPARTMENT OF RADIOLOGY

ULTRASOUND - WHOLE ABDOMEN

LIVER: Appears normal in size, shape and echopattern. No focal parenchymal lesions identified. No evidence of intra/extrahepatic biliary tree dilatation noted. Portal vein appears to be of normal size.

GALLBLADDER: Moderately distended. No definite calculi identified. No evidence of abnormal wall thickening noted.

SPLEEN: Appears normal in size, shape and echopattern. No focal parenchymal lesions identified.

PANCREAS: Obscured by bowel gas. However, the visualized portion appear normal.

KIDNEYS: Both kidneys appear normal in size, shape and echopattern. Corticomedullary differentiation appears maintained. No evidence of calculi or hydronephrosis on either side.

Right kidney measuring 9.2x3.8 cm.

Left kidney measuring 10.2x4.4cm.

URINARY BLADDER: Distended and appears normal. No evidence of abnormal wall thickening noted.

UTERUS: **Retroverted** and appears normal in size. Myometrial echoes appear normal. The endometrial lining appears intact. Endometrium measures 9 mm.

OVARIES:

Right ovary measuring 3.9x2.0x2.2cm. (volume 9cc)

Left ovary measuring 4.0x2.3x2.4cm. (volume 12cc)

No free fluid is seen.

IMPRESSION:

- 1. RETROVERTED UTERUS.**
- 2. MULTIPLE SMALL CYSTS SEEN IN PERIPHERY OF BOTH OVARY MEASURING 4x4mm. (PCOD)**

Dr. RAMESH G
MBBS DMRD
RADIOLOGY