



- 3D/4D Sonography
- Liver Elastography
- ECHO
- Dental & Eye Checkup
- Mammography
- Treadmill Test
- PFT
- Full Body Health Checkup
- X-Ray
- ECG
- Audlometry
- Nutrition Consultation

□ RADIOLOGY □ HEALTH CHECK UP □ PATHLOGY □ CARDIO DIAGNOSTIC

MER- MEDICAL EXAMINATION REPORT

Date of Examination	22/04/2024		
NAME	VAIBHAVI KABIRA		
AGE	23	Gender	FEMALE
HEIGHT(cm)	165	WEIGHT (kg)	88
B.P.	122/80/70		
ECG	REPORT ATTACHED		
X Ray	REPORT ATTACHED		
Vision Checkup	Color Vision : NA		
	Far Vision Ratio : NA		
	Near Vision Ratio : NA		
Present Ailments	NA		
Details of Past ailments (If Any)	NA		
Comments / Advice : She/He is Physically Fit	PHYSICALLY FIT		

Dr. Vipul Ghavda
MD (Internal Medicine)
Reg.No. G- 18004

Signature with Stamp of Medical Examiner



NAME :	VAIBHAVI KABIRA	DATE :	22-Apr-24
AGE/SEX:	23Y/F	REG.NO :	00
REFERRED BY: HEALTH CHECKUP			

X-RAY CHEST - PA VIEW

- Both lung fields are clear.
- No evidence of consolidation or Koch's lesion seen.
- Both CP_p angles are clear.
- Heart size is within normal limit.
- Both dome of diaphragm appear normal.
- Bony thorax under vision appears normal.

**DR. TEJAS PATEL (DNB)
CONSULTANT RADIOLOGIST**

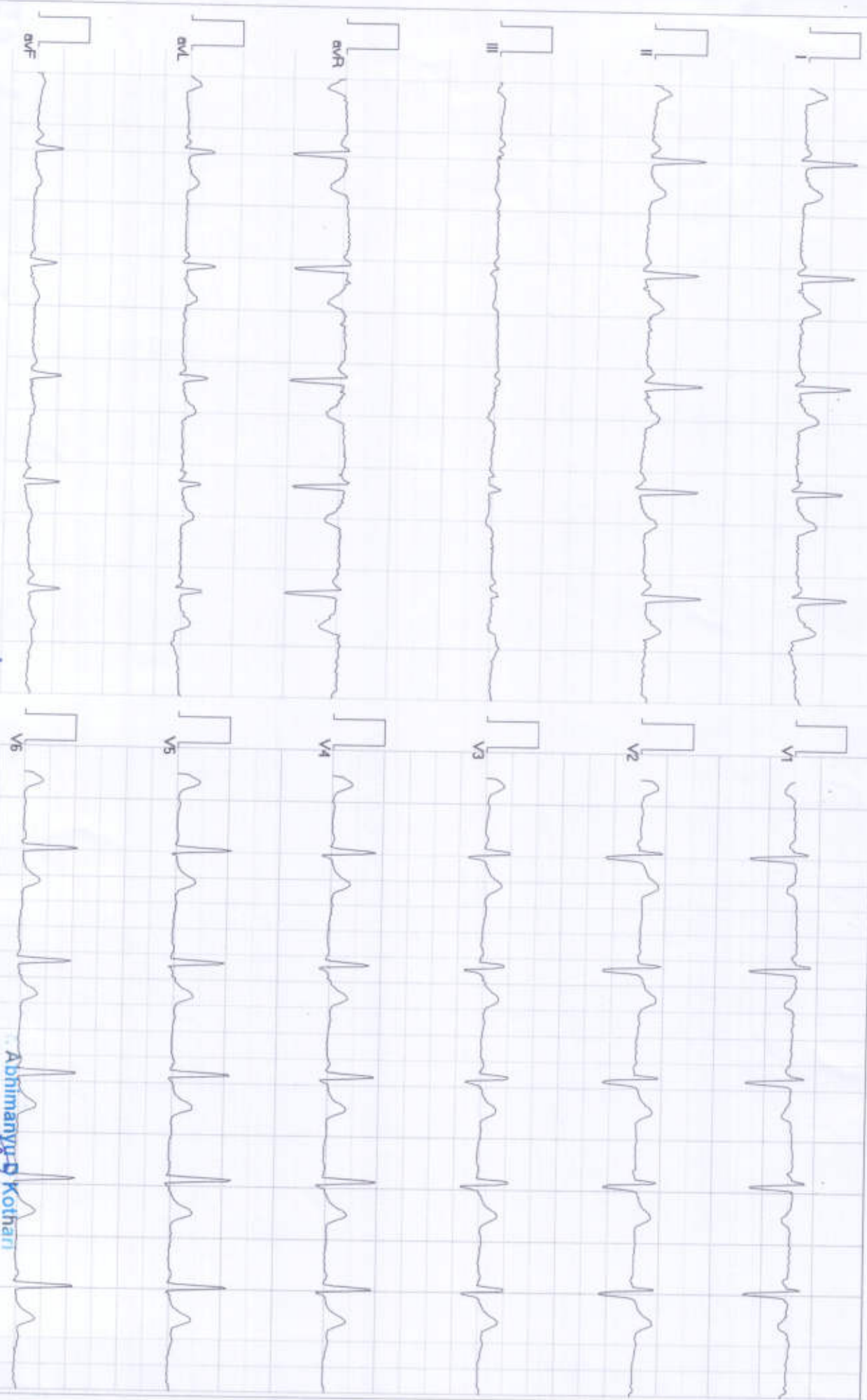
Dr. Tejas Patel
Diplomate N. B.
G-33659

CONCEPT DIAGNOSTIC

2184 / KABIRA VAIBHAVI NARESHBHAI / 23 Yrs / F / 165Cms. / 88Kgs. / Smoker

Heart Rate : 70 bpm / Tested On : 22-Apr-24 09:28:16 / HF 0.05 Hz - LF 35 Hz / Notch 50 Hz / Sn 1.00 Cm/mV / Sw 25 mm/s

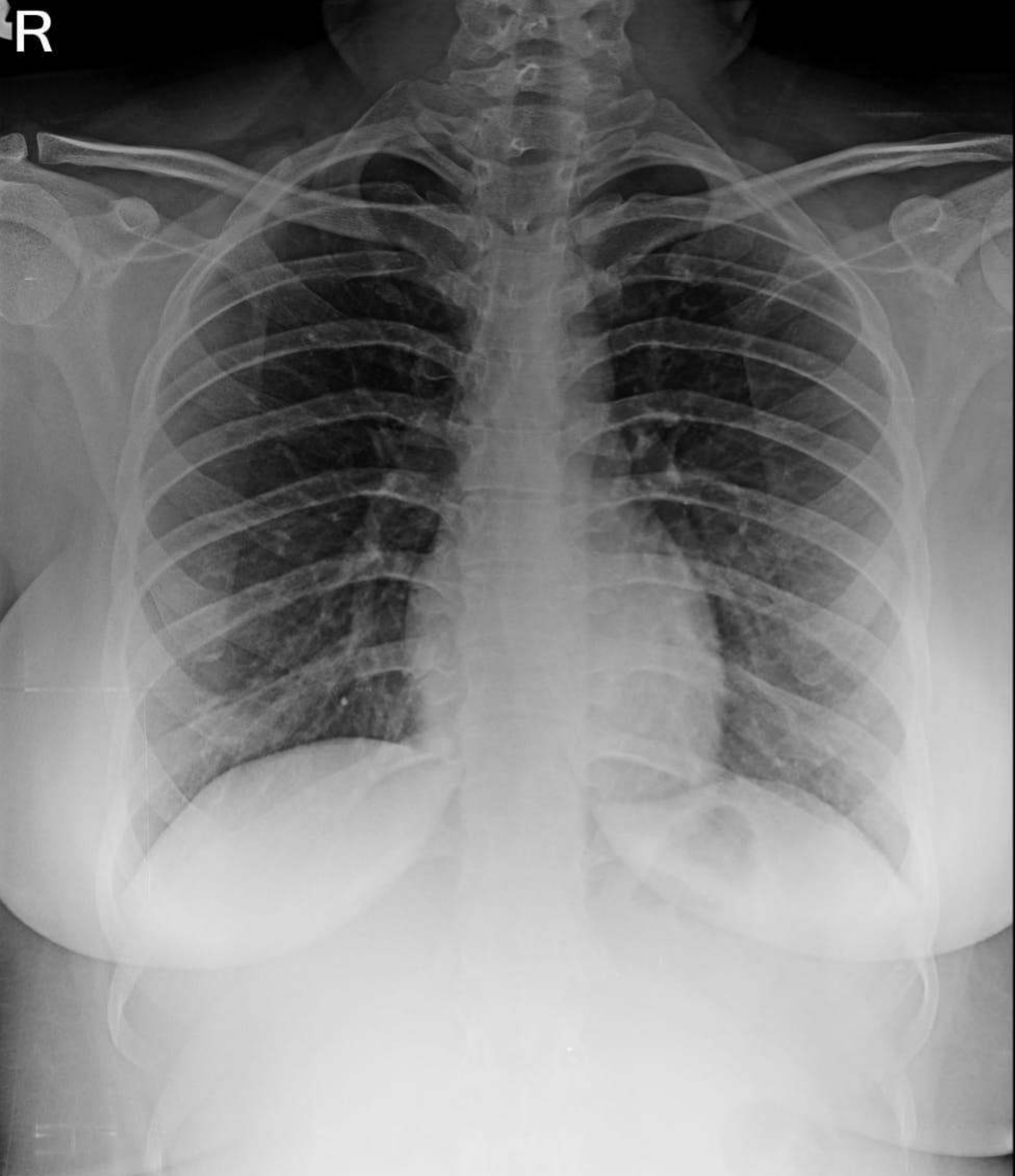ECG



Abhimanyu D. Kotnani

Normal

Reported by: **Dr. Abhimanyu D. Kotnani**
Interventional Cardiologist
Regd. No. G 29383



VAIBHAVI KABIRA 23Y/F F CHEST,FRN PA 22-Apr-24 09:43 AM
CONCEPT DIAGNOSTIC